

# Uncommon Locations and Presentations of Hydatid Cyst

Sachar S, Goyal S<sup>1</sup>, Goyal S<sup>2</sup>, Sangwan S<sup>3</sup>

Departments of Radio-Diagnosis and Imaging, and <sup>1</sup>Surgery, Muzaffarnagar Medical College, Begrajpur, Muzaffarnagar, Uttar Pradesh, <sup>2</sup>Department of Pathology, Dr. Ram Manohar Lohia Postgraduate Institute of Medical Sciences, New Delhi, <sup>3</sup>Department of Surgery, MM Institute of Medical Sciences and Research, Mulana, Haryana, India

## Address for correspondence:

Dr. Sunder Goyal,  
Department of Surgery,  
Muzaffarnagar Medical College,  
Begrajpur, Opposite Industrial  
Area, Delhi-Meerut Highway,  
Muzaffarnagar, Uttar Pradesh, India.  
E-mail: goyal.sunder@yahoo.in

## Abstract

**Background:** Hydatid disease (HD) is an ancient disease and even was known to Hippocrates. This disease involves all human parts and most common affected organs are liver and lungs. Incidence of unusual site is about 8-10%. The clinical picture depends upon the involved organs, its effects on adjacent structures, complications due to secondary infection, rupture, and anaphylaxis caused by hydatid cysts. **Aim:** The aim of this study was to find out incidence of unusual location of hydatid cyst in the human body. **Materials and Methods:** A retrospective study of HD was carried in a medical college between July 2007 and June 2012. A total 79 cases of HD were treated during this period. Information on clinical presentation and management were reviewed, and results presented as summary statistics. **Results:** Sixty one cases were of liver HD, and 11 were with hydatid lung disease. Fifty cases were with right lobe involvement, and rest 11 were with both lobe involvement. Out of 11 lung hydatid only one case was with bilateral lung involvement. Only eight cases of HD of uncommon locations and presentations were encountered during this period. First case presented with left hypochondriac mass as splenic HD, second with pelvic HD along with obstructive uropathy, third with non-functioning right kidney with bilateral psoas muscles HD, fourth with HD involving mesentery, fifth with pelvic pain due to right ovary HD, sixth with simultaneous involvement of the liver and right subdiaphragmatic region, seventh with HD of right inguinal region, and eighth with hydatid cyst of the left kidney. Even though, there was no mortality found in these patients, there was high morbidity. **Conclusion:** We conclude that *Echinococcus granulosus* can affect any organ in the body from head to toe, and a high suspicion of this disease is justified in endemic regions. Moreover, medical treatment should be given in the pre-operative period as well as in the post-operative period for 4-6 weeks.

**Keywords:** Hydatid disease, Ovary, Psoas muscle, Renal, Spleen, Unusual locations

## Introduction

Hydatid disease (HD) is endemic in the Middle East Africa, South America, New Zealand, Australia, Turkey, and Southern Europe, but foci are common in almost every part of the world including India where the highest prevalence is reported in Andhra Pradesh, Tamil Nadu, and Jammu and Kashmir. Infestation by *Echinococcus granulosus* in humans

most commonly occurs in the liver (55-70%) followed by the lung (18-35%); the two organs can be affected simultaneously in about 5-13% of cases. Incidence of unusual sites is about 8-10%. Incidence of HD involving the spleen, kidney, peritoneal cavity, skin and muscles is about 2% each and incidence of the heart, brain, vertebral column, ovaries, pancreas, gallbladder, thyroid gland, breast, and bones involvement is about 1% each.<sup>[1]</sup> The clinical picture depends upon the involved organs, its effects on adjacent structures, complications due to secondary infection, rupture and anaphylaxis caused by hydatid cyst. This benign disease can cause substantial morbidity and mortality. The aim of this study is to highlight the fact that this disease should be suspected in cystic lesions involving any organ in the body, especially in endemic areas like India. Even though, hydatid cysts can affect any organ, the disease is uncommon in the organs cited here.

## Access this article online

### Quick Response Code:



Website: [www.amhsr.org](http://www.amhsr.org)

DOI:  
10.4103/2141-9248.133476

## Materials and Methods

A retrospective study was carried out in our medical college during July 2007 to June 2012. A total 79 cases of HD were treated during this period. Information of clinical presentation and management was reviewed. As a retrospective study, approval to use the data was obtained from the relevant authorities, but no formal ethical clearance was sought.

Clinical features, examination, blood counts (eosinophilia), serological test (indirect hemagglutination [IHA] test), ultrasound, and computed tomography (CT) confirmed the diagnosis. All patients were given albendazole in the pre-operative period and then were operated to minimize the chances of post-operative recurrence. Pain was most important presenting symptom. In two cases, presenting symptoms were due to compression on adjacent organs.

## Results

Sixty one cases were of liver HD and 11 were of hydatid lung disease. Fifty cases were with right lobe involvement and rest 11 were with both lobe involvement. Out of 11 lung hydatid only one case was with bilateral lung involvement. Only eight cases of hydatid cysts at uncommon locations and presentations were recorded as shown in Table 1. Eosinophilia was present in all eight cases. IHA test (serology) was positive in seven cases out of eight cases. Five cases were of primary HD of uncommon site and in rest three cases there was past history of liver HD.

Open surgery was done in all cases except in one case in which spleen sparing laparoscopic peri-splenectomy was carried out. Total cystectomy was done in most of the cases except in cases where cyst was adherent with important structure such as ureter, blood vessels or nerves. Marsupialization with omentoplasty was carried out in cases with residual cyst cavity. Nephrectomy was done along with total cystectomy in one case.

All patients were given albendazole 15 mg/kg/day for 4 weeks. In most of the cases, there were no post-operative complications except in one case where there was post-operative pelvic collection which was drained percutaneous (ultrasound guided). There was no mortality and superficial wound infection was present in two cases only. All patients were followed upto 6 months only. There was no incidence of recurrence in any of the above case during this period. A long term follow could not be done due to poverty and long distance as all these patients belonged to low-economical status.

## Discussion

Hippocrates was first to illustrate a liver hydatid cyst and pioneered techniques of treatment.<sup>[2]</sup> More than 80-90% of hydatid cysts occur in the liver, lungs, or both. Hydatid cysts have been reported infrequently in the spleen, kidney,

peritoneal cavity, skin and muscles and rarely involve the heart, brain, vertebral column, ovaries, pancreas, gallbladder, thyroid gland, breast, and bones.<sup>[1]</sup> Clinical presentation of HD depends upon the size, site and depth of the lesion. Eosinophilia is expected in all patients with parasitic infestations this was seen in all our cases. HD is diagnosed mainly by history, examination and by radiological imaging. Imaging tools ultrasonography (USG) can diagnose HD pre-operatively and CT scan can confirm all the cases.<sup>[3]</sup> Combination of USG and CT scan is most helpful imaging diagnostic tools.<sup>[4]</sup> On CT their appearance varies: They may show a “spoke wheel” pattern or a water lily sign. When cysts are healed or in an inactive state, they appear as multiple cystic lesions or with calcification in the peritoneum.<sup>[5]</sup>

Different serological tests are done for the diagnosis, screening, and post-operative follow-up for recurrence. These tests consist of the hydatid immunoelectrophoresis, enzyme-linked immunosorbent assay (ELISA), latex agglutination and IHA test.<sup>[6]</sup> The ELISA test has a sensitivity of 80-100% and specificity of 88-96% in hepatic cysts, 50-56% sensitivity in lung HD and 25-65% in HD of other organs. But these tests may be negative because the capsule isolates the parasite from the host's immune system. In our study, serology (IHA) was positive in seven out of eight cases.

### Pathophysiology of spread of disease

Usually parasites spread via portal blood stream. Other routes of spread may be lymphatic invasion by the parasite, and retrograde migration from the vena cava to the subclavian vein.<sup>[6]</sup> HD can also involve any organ of abdomen due to hematogenous route or due to peritoneal fluid circulation phenomenon.

Peritoneal cavity has a normal circulation of peritoneal fluid due to various compartments in abdomen. A small amount of peritoneal fluid continuously circulates normally in abdomen. The movement of the diaphragm and peristalsis of bowel regulate the movement of fluid in this circulatory pathway. It mostly flows up in the right paracolic gutter, which is deeper and wider than the left. It is partially cleared by the subphrenic lymphatics. Fluid stays in these watershed regions in the peritoneal cavity: The ileocolic region, the root of the sigmoid mesentery, and the Pouch of Douglas. The spread of HD can be along the areas of peritoneal fluid circulation and may result in spontaneous intraperitoneal seeding.<sup>[5]</sup>

Incidence of HD involving the spleen is about 2-2.5%. It can occur primarily or in association with hepatic, pulmonary, or multi-organ hydatidosis.<sup>[7]</sup>

A primary HD of the retroperitoneum is a distinct clinical entity that must be considered when caring for a patient with a retroperitoneal mass in endemic regions. Incidence of peritoneal involvement is about 12%. Clinical features include flank pain, abdominal mass and non-specific symptoms such

**Table 1: Location, different form of presentations, eosinophilia, serology, imaging investigations, and management of all the nine cases**

Serial no. and location	Age (years)/ sex	Clinical features	Eosinophilia (%)	Serology (indirect hemagglutination test)	Imaging (USG/CECT)	Management and complications
First-splenic hydatid cyst	26/F	Pain and mass left hypochondrium of 2 months duration	9	Positive	CECT showing big splenic hydatid cyst [Figure 1]	Laparoscopic pericystectomy (splenic tissue sparing surgery) done. No post-operative complications
Second-pelvic hydatid cyst with B/L hydronephrosis with uropathy	50/M	Urinary symptoms and lump in right lumbar region of 6 months duration with acute renal failure with generalized oedema with deranged renal function (High blood urea and high serum creatinine)	8	Negative	CECT showing pelvic hydatid cyst with B/L hydronephrosis [Figure 2a and b]	B/L PCN done to correct renal failure. Laparotomy done. Cyst was adherent with ureters, bladder, and rectum. Partial excision of pelvic cyst with omentoplasty. Patient recovered without any post-operative complications
Third-B/L psoas muscle hydatid cyst with giant hydronephrosis right kidney	65/M	Dragging pain and ballotable mass in right flank for the last 6 months	8	Positive	CECT showed B/L psoas muscle hydatid cyst. Right large cyst causing right giant hydronephrosis [Figure 3]	Nephrectomy with total excision of right psoas hydatid cyst with help of per-operative USG. No post-operative complications
Fourth-mesenteric hydatid cyst	40/F	Lump and pain abdomen for last 1 year	10	Positive	USG showed large sized mesenteric hydatid cyst [Figure 4a and b]	Laparotomy with total excision of cyst. No post-operative complications
Fifth-right ovarian hydatid cyst	56/F	Pain right half of pelvis for the last 9 months. There was past H/O liver hydatid surgery	7	Positive	USG showed an ovarian cyst? Hydatid cyst in view of HD history [Figure 5]	Laparotomy-marsupialization of cyst due to adhesions with rectum. with omentoplasty. No post-operative complications except for superficial wound infection
Sixth-hydatid cyst of liver and sub-diaphragmatic space	45/F	Left costal region dull pain for the last 7 months	6	Positive	CECT showing liver hydatid cyst with left subdiaphragmatic hydatid cyst pushing down spleen [Figure 6]	Laparotomy with pericystectomy of liver cyst with marsupialization of subdiaphragmatic cyst. There was pelvic collection in post-operative period. Ultrasound guided percutaneous drainage was done
Seventh-hydatid cyst of inguinal region	50/F	Vague lump with dull pain right inguinal region for the last 11 months. Previous H/O surgery for liver HD	6	Positive	CECT showed hydatid cyst in right inguinal region [Figure 7]	Extraperitonea exploration with deroofting of cyst due to adhesions with external iliac vessels. There was per operative minor injury to external iliac vein which was repaired. No other post-operative complications
Eighth-hydatid cyst of left kidney	38/F	Pain over left renal region for the last 6 months. Past H/O surgery for liver hydatid cyst	9	Positive	USG showed small left renal cyst [Figure 8]	Treated with chemotherapy only. Patient improved

USG: Ultrasonography, CECT: Contrast-enhanced computed tomography, PCN: Percutaneous nephrolithotomy, HD: Hydatid disease

as nausea and vomiting. It should be treated after the diagnosis is confirmed without any delay because of secondary spillages due to rupture and other possible complications.<sup>[8]</sup>

Diaphragmatic and subdiaphragmatic localization of hydatid cyst is very rare, with incidence of 1%, and most of these are usually associated with liver disease (as in our case).<sup>[9]</sup>

Pelvic HD is unusual, and the reported incidence is HD is about 2.25%.<sup>[10]</sup> Due to its location in a fixed cavity, it presents with pressure effects on adjacent organs such as the urinary bladder (most common) or rectum. Urinary symptoms may be retention of urine, frequency of micturation or as obstructive uropathy and renal failure.<sup>[11]</sup> We also had a case of primary pelvic hydatid cyst with obstructive uropathy with non-functioning right kidney with acute renal failure.

Location in muscular tissue accounts for 2-3% of all cases. Hydatid cyst located at the right psoas muscle, obstructing the right pelviureteric junction (PUJ) and ureter resulting in giant hydronephrosis is a rare occurrence and only one case has been reported in literature so far.<sup>[12]</sup> We also present a rare case of bilateral psoas muscles hydatid cyst causing giant hydronephrotic right kidney due to compression of the right PUJ and ureter.

Hydatid cyst of the ovary is quiet uncommon, and the incidence is about 0.2-2.25%.<sup>[13]</sup>

Renal HD is also rare entity (1-3%) and cysts are usually unilateral and located in the upper or lower pole. 18% of renal hydatid cysts may rupture into the collecting system, leading to acute colic and hydatiduria. However, primary HD of these structures is extremely rare.<sup>[14]</sup>

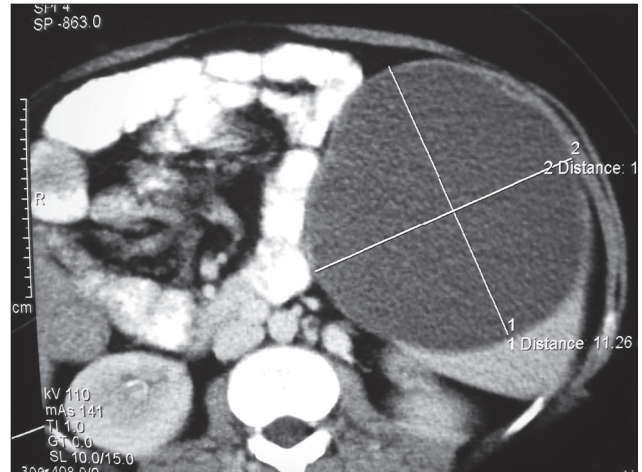
Primary soft-tissue involvement by hydatid cyst is unusual even in endemic areas, and the incidence is about 0.5-4.7%. The frequency of osseous involvement in hydatid cyst is 1-2.4%. It is most commonly seen in the spine and pelvis.<sup>[15]</sup>

Other uncommon site, which are not encountered by us are listed in Table 2.

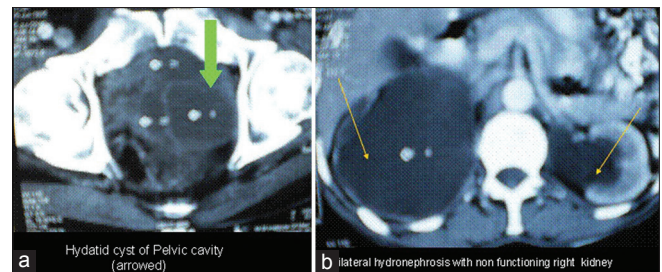
**Management**

Treatment of HD is mainly surgical (open as well as laparoscopic). Laparoscopic procedure involves: Aspiration, installation of

scolicidal, deroofing, removal of all contents and converting the cyst into a big size non-dependant cavity. However, pre- and post-operative 1-month courses of albendazole and 2 weeks of praziquantel should be considered in order to sterilize the cyst, to decrease the chance of anaphylaxis, to decrease the tension in the cyst wall (thus reducing the risk of spillage during surgery) and to reduce the recurrence rate post-operatively.<sup>[6]</sup> Intra-operatively, the use of gauge pieces soaked with hypertonic saline or 10% betadine solutions were used to surround the cyst before

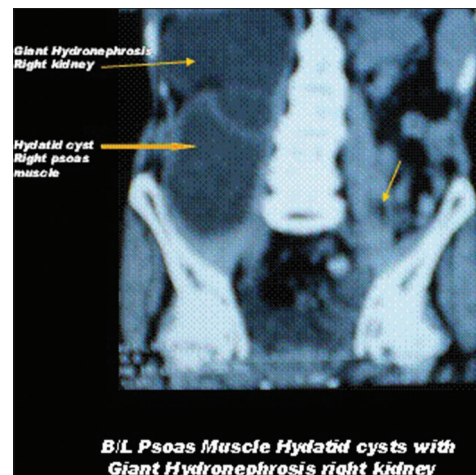


**Figure 1:** Contrast-enhanced computed tomography showing splenic hydatid cyst

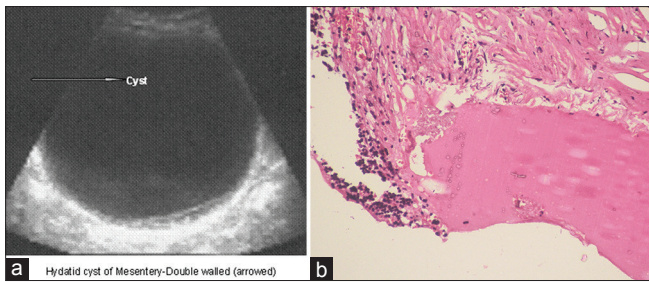


**Figure 2:** (a) Contrast-enhanced computed tomography showing pelvic hydatid cyst, (b) Contrast-enhanced computed tomography showing B/L hydronephrosis

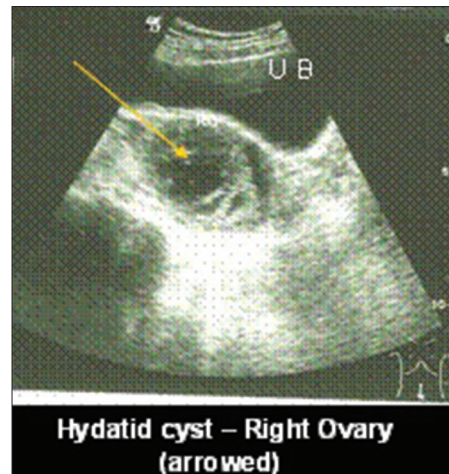
Table 2: Other unusual site not in our study		
Name of organs	Incidence (%)	Reported by
Brain	2	Greenberg <i>et al.</i> , 2001 <sup>[16]</sup>
Thyroid	1	McManus <i>et al.</i> , 2003 <sup>[11]</sup>
Breast	1	McManus <i>et al.</i> , 2003 <sup>[11]</sup>
Heart	1	McManus <i>et al.</i> , 2003 <sup>[11]</sup>
Gall bladder	≤1	Raza <i>et al.</i> , 2003, <sup>[17]</sup> Mushtaque <i>et al.</i> , 2011 <sup>[18]</sup>
Pancreas	0.5-0.8	Palaivelu, 2007, <sup>[19]</sup> Moosavi <i>et al.</i> , 2007 <sup>[20]</sup>
Uterus and adnexia	0.5-1	Palaivelu, 2007, <sup>[19]</sup> Arora <i>et al.</i> , 2005 <sup>[21]</sup>
Seminal vesicle	0.1-3	Safioleas <i>et al.</i> , 2006, <sup>[22]</sup> Vasileios <i>et al.</i> , 2002 <sup>[23]</sup>
Bones and spine	0.1-3	Drimousis <i>et al.</i> , 2006 <sup>[24]</sup>
Muscle	2	Arora <i>et al.</i> , 2011 <sup>[25]</sup>
Skin and subcutaneous tissue	1-2	Zulfikaroglu <i>et al.</i> , 2005, <sup>[26]</sup> Dirican <i>et al.</i> , 2008 <sup>[27]</sup>



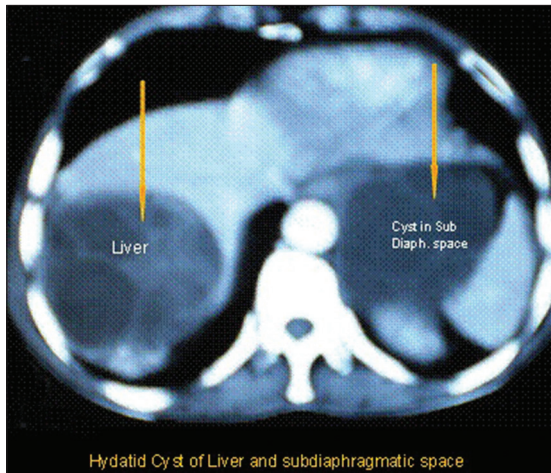
**Figure 3:** Contrast-enhanced computed tomography showing B/L psoas muscle hydatid disease with right giant hydronephrosis



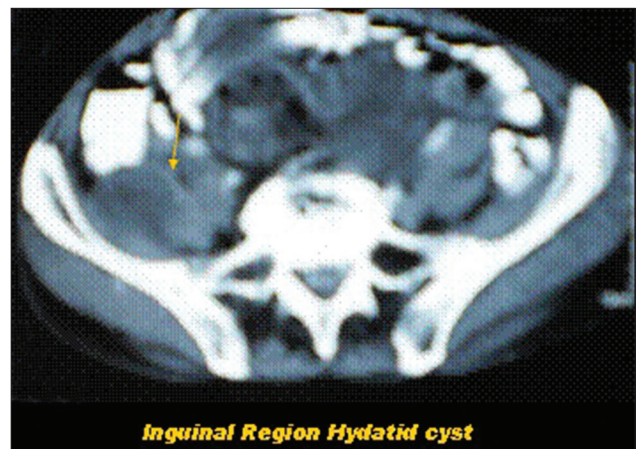
**Figure 4:** (a) Ultrasonography showing big mesenteric hydatid cyst, (b) Histopathology of wall of hydatid cyst



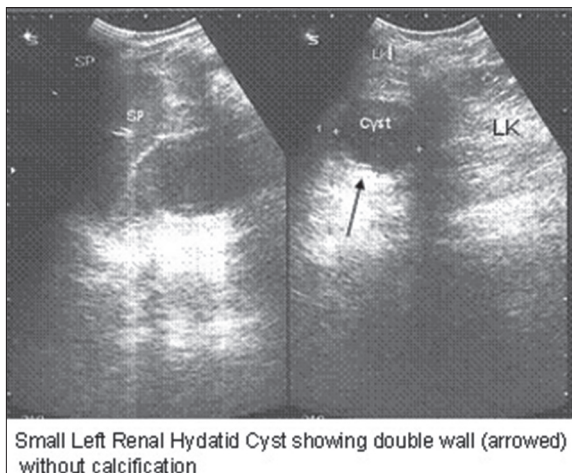
**Figure 5:** Ultrasonography showing right ovarian hydatid cyst



**Figure 6:** Contrast-enhanced computed tomography showing liver hydatid with left subdiaphragmatic cyst



**Figure 7:** Contrast-enhanced computed tomography showing hydatid cyst of right inguinal region



**Figure 8:** Ultrasonography showing small hydatid cyst of left kidney with typical "rim sign"

opening the cavities. These scoliceids kill the daughter cysts and therefore, prevent further spread or anaphylactic reaction.<sup>[6]</sup>

While surgery still remains as the standard for cystic echinococcosis treatment, there have been a number of studies that suggest that percutaneous drainage of cyst - puncture, aspiration, injection of hypertonic saline and absolute alcohol, reaspiration with chemotherapy is more effective than surgery in terms of disease recurrence, and morbidity and mortality.<sup>[28]</sup>

In the case of alternative medical therapy using chemotherapy alone, albendazole is used with an adult dosage of 400 mg orally, twice a day for 1-5 months and a pediatric dosage of 15 mg/kg/day (maximum of 800 mg) for 1-6 months.<sup>[29]</sup>

In addition to the above mentioned treatments, percutaneous thermal ablation of the germinal layer in the cyst by means of a radiofrequency ablation device is a recent technique on which studies are being done to develop it as a new treatment modality. This form of treatment is quite new and needs much more testing before being widely used.<sup>[30]</sup>

Even though, mortality directly due to echinococcosis is very low, it can produce a very disabling morbidity. A mortality rate between 0.29% and 0.6% has been reported. The recurrence rate of this disease is still relatively high accounting for about 10%.

### Conclusion

We conclude that *E. granulosus* can affect any organ in the body from head to toe except hair and nails. A high index of

suspicion is required for pre-operative diagnosis of HD in unusual locations, and it should be considered in the differential diagnosis for any cystic mass found in patients from endemic areas. Moreover, medical treatment should precede and follow the surgical intervention.

## References

- McManus DP, Zhang W, Li J, Bartley PB. Echinococcosis. *Lancet* 2003;362:1295-304.
- Kouskos E, Chatziantoniou J, Chrissafis I, Anitsakis C, Zamtrakis S. Uncommon locations of hydatid cysts. *Singapore Med J* 2007;48:e119-21.
- Czermak BV, Unsinn KM, Gotwald T, Niehoff AA, Freund MC, Waldenberger P, *et al.* *Echinococcus granulosus* revisited: Radiologic patterns seen in pediatric and adult patients. *AJR Am J Roentgenol* 2001;177:1051-6.
- Pedrosa I, Saíz A, Arrazola J, Ferreirós J, Pedrosa CS. Hydatid disease: Radiologic and pathologic features and complications. *Radiographics* 2000;20:795-817.
- Thambidurai L, Santhosham R, Dev B. Hydatid cyst: Anywhere, everywhere. *Radiol Case Rep* 2011;6:486.
- Mushtaque M, Mir MF, Malik AA, Arif SH, Khanday SA, Dar RA. Atypical localizations of hydatid disease: Experience from a single institute. *Niger J Surg* 2012;18:2-7.
- Murtaza B, Gondal ZI, Mehmood A, Shah SS, Abbasi MH, Tamimy MS, *et al.* Massive splenic hydatid cyst. *J Coll Physicians Surg Pak* 2005;15:568-70.
- Aydinli B, Ozturk G, Polat KY, Atamanalp SS, Ozbey I, Onbas O, *et al.* Extravisceral primary hydatid cyst of the retroperitoneum. *ANZ J Surg* 2007;77:455-9.
- Isik AF, Sagay S, Ciftci A. Diaphragmatic hydatid disease. *Acta Chir Belg* 2006;106:96-7.
- Emir L, Karabulut A, Balci U, Germiyanoğlu C, Erol D. An unusual cause of urinary retention: A primary retrovesical echinococcal cyst. *Urology* 2000;56:856.
- Kohli A, Gupta RK, Poptani H, Roy R. *In vivo* proton magnetic resonance spectroscopy in a case of intracranial hydatid cyst. *Neurology* 1995;45:562-4.
- Kandhrah E, Semercioz A, Metin A, Eroglu M, Uysal B. Non-functioning kidney resulted from primary hydatid cyst of the psoas muscle. *MMJ* 2006;19:145-6.
- Tampakoudis P, Assimakopoulos E, Zafarakas M, Tzeveleki P, Kostopoulou E, Bontis J. Pelvic echinococcus mimicking multicystic ovary. *Ultrasound Obstet Gynecol* 2003;22:196-8.
- Polat P, Kantarci M, Alper F, Suma S, Koruyucu MB, Okur A. Hydatid disease from head to toe. *Radiographics* 2003;23:475-94.
- Kizilkaya E, Silit E, Basekim C, Karsli AF. Hepatic, extrahepatic soft tissue and bone involvement in hydatid disease. *Turk J Diagn Interv Radiol* 2002;8:101-4.
- Greenberg SM. *Handbook of Neurosurgery*. 1<sup>st</sup> ed. New York: Thieme Medical Publisher; 2001. p. 238-9.
- Raza MH, Harris SH, Khan R. Hydatid cyst of gall bladder. *Indian J Gastroenterol* 2003;22:67-8.
- Mushtaque M, Malik AA, Malik RA. Hydatid cyst of the gall bladder: A rare location. *East J Med* 2011;16:83-6.
- Palaivelu C. Laparoscopic management of hydatid cysts of liver. *Art of Laparoscopic Surgery-Textbook and Atlas*. Dehli Jaypee Publishers; 2007. p. 757-83.
- Moosavi SR, Kermany HK. Epigastric mass due to a hydatid cyst of the pancreas. A case report and review of the literature. *JOP* 2007;8:232-4.
- Arora M, Gupta CR, Jindal S, Kapoor N. An unusual case of hydatid cyst of broad ligament. *J Indian Acad Clin Med* 2005;6:86-7.
- Safioleas M, Stamatakos M, Zervas A, Agapitos E. Hydatid disease of the seminal vesicle: A rare presentation of hydatid cyst. *Int Urol Nephrol* 2006;38:287-9.
- Vasileios R, Athanasios P, Stavros T. Echinococcal cyst of the seminal vesicles: A case-report and literature review. *Int Urol Nephrol* 2002;34:527-30.
- Drimousis PG, Stamou KM, Koutras A, Tsekouras DK, Zografos G. Unusual site of recurrent musculoskeletal hydatid cyst: Case report and brief review of the literature. *World J Gastroenterol* 2006;12:5577-8.
- Arora V, Nijjar IS, Gill KS, Singh G. Case report: Primary hydatid cyst of muscle – A rare site. *Indian J Radiol Imaging* 2006;16:239-41.
- Zulfikaroglu B, Koc M, Ozalp N, Ozmen MM. A rare primary location of echinococcal disease: Report of a case. *Ups J Med Sci* 2005;110:167-71.
- Dirican A, Unal B, Kayaalp C, Kirimlioglu V. Subcutaneous hydatid cysts occurring in the palm and the thigh: Two case reports. *J Med Case Rep* 2008;2:273.
- Eckert J, Deplazes P. Biological, epidemiological, and clinical aspects of echinococcosis, a zoonosis of increasing concern. *Clin Microbiol Rev* 2004;17:107-35.
- Pawlawski Z, Eckert SJ, Vuitton DA, Ammann RW, Kern P, Craig PS, *et al.* Echinococcosis in humans: Clinical aspects, diagnosis and treatment. In: Eckert J, Gemmell MA, Meslin F-X, Pawlawski ZS, editors. *WHO/OIE Manual on Echinococcus in Humans and Animals: A Public Health Problem of Global Concern*. Paris, France: World Organisation for Animal Health; 2011. p. 20-66.
- Brunetti E, Filice C. Radiofrequency thermal ablation of echinococcal liver cysts. *Lancet* 2001;358:1464.

**How to cite this article:** Sachar S, Goyal S, Goyal S, Sangwan S. Uncommon locations and presentations of hydatid cyst. *Ann Med Health Sci Res* 2014;4:447-52.

**Source of Support:** Nil. **Conflict of Interest:** None declared.