

# Suprapubic transvesical single-port technique for control of lower end of ureter during laparoscopic nephroureterectomy for upper tract transitional cell carcinoma

Rajesh K. Ahlawat, Gagan Gautam<sup>1</sup>

Division of Urology and Renal Transplantation, Medanta Kidney and Urology Institute, Medanta, the Medicity, Gurgaon, India, <sup>1</sup>Section of Urology, University of Chicago Medical Center, Chicago, IL, USA

## ABSTRACT

**Context:** Various minimally invasive techniques – laparoscopic, endoscopic or combinations of both – have been described to handle the lower ureter during laparoscopic nephroureterectomy but none has received wide acceptance.

**Aims:** We describe an endoscopic technique for the management of lower end of ureter during laparoscopic nephroureterectomy using a single suprapubic laparoscopic port.

**Materials and Methods:** Transurethral resectoscope is used to make a full thickness incision in the bladder cuff around the ureteric orifice from 1 o'clock to 11 o'clock. A grasper inserted through the transvesical suprapubic port is used to retract the ureter to complete the incision in the bladder cuff overlying the anterior aspect of the ureteric orifice. The lower end of ureter is subsequently sealed with a clip applied through the port. This is followed by a laparoscopic nephrectomy and the specimen is removed by extending the suprapubic port incision. Our technique enables dissection and control of lower end of ureter under direct vision. Moreover, surgical occlusion of the lower end of the ureter prior to dissection of the kidney may decrease cell spillage. The clip also serves as a marker for complete removal of the specimen.

**Results:** Three patients have undergone this procedure with an average follow up of 19 months. Operative time for the management of lower ureter has been 35, 55 and 40 minutes respectively. A single recurrence was detected on the opposite bladder wall after 9 months via a surveillance cystoscopy. There has been no residual disease or any other locoregional recurrence.

**Conclusions:** The described technique for management of lower end of ureter during laparoscopic nephroureterectomy adheres to strict oncologic principles while providing the benefit of a minimally invasive approach.

**Key words:** Laparoscopic nephroureterectomy, lower end ureter, transitional cell carcinoma, transvesical port, upper urinary tract, ureterectomy

## INTRODUCTION

Transitional cell carcinoma (TCC) of the upper tract comprises less than 5% of all urothelial tumors.<sup>[1]</sup> While open nephroureterectomy (ONU) has been the

gold standard for the management of localized upper tract TCC, the laparoscopic approach for this procedure (LNU) is rapidly gaining acceptance. Oncologic results with LNU in terms of bladder recurrences, metastatic incidence, and cancer-specific survival have been comparable to open surgery, while providing minimally invasive surgery (MIS) benefits in terms of lower morbidity and quicker recovery.<sup>[2]</sup>

The technique of NU is best considered as two separate procedures – nephrectomy and the removal of lower end of ureter with surrounding bladder cuff. The controversy of the nephrectomy component seems to have rested with laparoscopic management outscoring open surgery with its MIS benefits. The management of distal ureter, however, has remained the most challenging and controversial feature of both open and laparoscopic procedures due to highlighted risks of retroperitoneal, peritoneal, and port-site metastases.

**For correspondence:** Dr. Rajesh K Ahlawat, Division of Urology and Renal transplantation, Medanta Kidney and Urology Institute, Medanta, the Medicity, Gurgaon 122 001, India. E-mail: rajesh.ahlawat@gmail.com

### Access this article online

Quick Response Code:	Website:
	www.indianjurol.com
	DOI:
	10.4103/0970-1591.82836

The oncology purists dictate that the best nephroureterectomy procedure would do a complete en-bloc resection of the kidney and ureter with surrounding bladder cuff, and avoidance of tumor seeding. There is no controversy regarding the fact that failure to completely remove the lower end of ureter or the surrounding bladder cuff risks high recurrence in the remnant, and thus is an essential part of the procedure. Opening the bladder to achieve this, however, risks the seepage of urine with potential implantation of viable cancer cells. A closed technique without opening the urinary system, theoretically, would be the best, but has not been accepted due to high incidence of positive margins and bladder recurrences, attributed to the method's inconsistency in removing the complete intramural ureter and bladder cuff segments.<sup>[3]</sup> There is also an increased risk of injury to opposite ureter on using extravesical stapling device. The classical open transvesical technique of securing the lower end has been the gold standard even though it transgresses urothelium and requires a second incision when combined with open nephrectomy.

There have been consistent attempts to innovate minimally invasive methods as alternative to open lower end management. The “pluck” and “intussusception” techniques were popularized in ONU settings to avoid the second incision. Although there are enthusiasts of “pluck” methods in combination with LNU,<sup>[4]</sup> multiple reports of local recurrences over last two decades have fuelled newer innovations to deal with the lower end.<sup>[5]</sup> The failure of “pluck” technique can be explained due to difficulty to confirm total ureterectomy in “pluck” methods due to an absence of an identifying “tag” at the lower end. Moreover, the lower end of ureter is unsecured and open, thereby allowing seepage of urine into the wound. The minimally invasive methods described in the last decade have tried to emulate the open surgery steps with some combination of transurethral endoscopy, suprapubic transvesical ports, and hand assistance.<sup>[1,6,7]</sup> While all these methods succeed in removing the intramural ureter with bladder cuff en-bloc with the kidney specimen, the methods disagree in the level of control of ureter to prevent passage of viable TCC cells down to the bladder or the wound, and in sequence whether the kidney or the lower ureteric end is to be dealt with first.

We describe a, minimally invasive surgical technique adhering to basic oncologic principles to manage the lower end of ureter.

## MATERIALS AND METHODS

We use the described technique in patients with unilateral upper tract high-grade TCC. Initial imaging and endoscopic evaluation excludes the disease in bladder and the contralateral upper tract. Patients with TCC in the intramural part of ipsilateral ureter are not considered for this procedure. The patients are consented and prepared

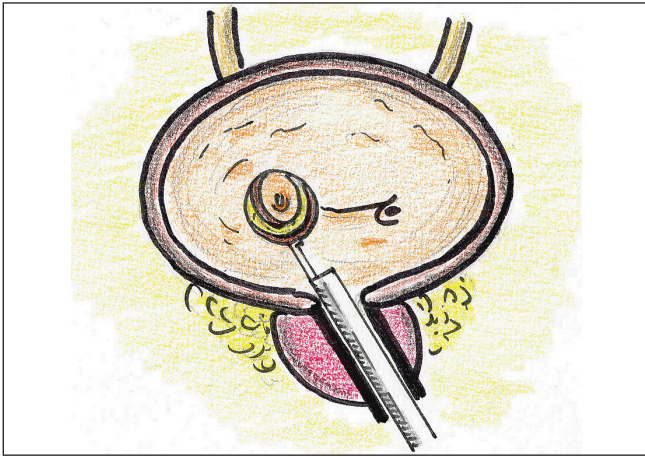
as any other laparoscopic renal surgery. The patient is anesthetized with muscle relaxants. Single surgeon with an assistant performs the procedure. The lower ureteric end is dealt first, and the procedure carried out in three steps.

Step I [Figure 1]: The patient is draped in lithotomy position. A 26F continuous flow resectoscope is introduced transurethrally with an attached Collings knife. Glycine is used as irrigant with stand height of 60 cm above pubic symphysis, and the diathermy is set at 90 W pure cutting and 60 W coagulating. The incision line, about a cm around the right ureteric meatus, is marked with coagulating current. Incision is then deepened with cutting current. While the bladder wall overlying the intramural ureter is cut partly, rest of the bladder incision from 1 to 11 o' clock is deepened to reach perivesical loose areolar tissue. Bladder wall thickness is judged in lower half of the circular incision, and then carried toward the upper end on either side. The procedure is stopped short of completing the full thickness bladder incision over intramural part of ureter [Figure 2].

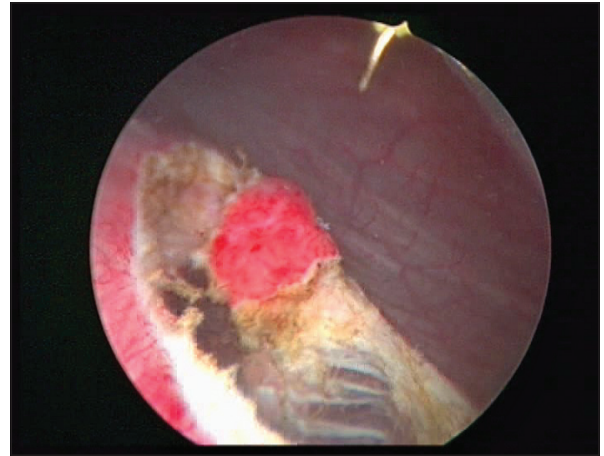
Step II [Figure 3]: Bladder is filled with the resectoscope outlet closed. A needle puncture just above symphysis pubis is seen entering bladder under vision. It is followed with a 5-mm vertical skin incision at the same site, cutting the underlying rectus sheath also in the midline. A 5-mm threaded laparoscopic trocar is placed in the bladder in line of the initial needle puncture and its outlet is connected to low-pressure suction. A 5-mm grasper is introduced into bladder under vision [Figure 4]. The dissected bladder cuff is held with the grasper and retracted inferomedially and inferolaterally to stretch remaining bladder muscle fibers to be cut with Collings knife [Figure 5]. The freed lower end of ureter is now retracted into the bladder to release intramural attachments [Figure 6], as done in transvesical mobilization for reflux surgery, till ureter is completely free.

Step III [Figure 7]: Resectoscope is removed and replaced with cystoscope with a 30-degree telescope and the biopsy forceps. Flow and the suction are adjusted to keep the vision just clear enough to identify structures. The end of the cystoscope is kept just below and lateral to the dissected ureter, looking up toward the suprapubic port. End of the dissected ureter, held till now with the grasper through the suprapubic port, is transferred to the grip with transurethral biopsy forces. The grasper is exchanged with a 5-mm hem-o-lock applicator, and the ureter is doubly secured just proximal to the held distal end [Figure 8]. Ureter is now released, which recoils to the open bladder hiatus. Suprapubic port and the cystoscope are removed. A 22F two-way Foley's catheter is placed via urethra and connected to gravity drainage.

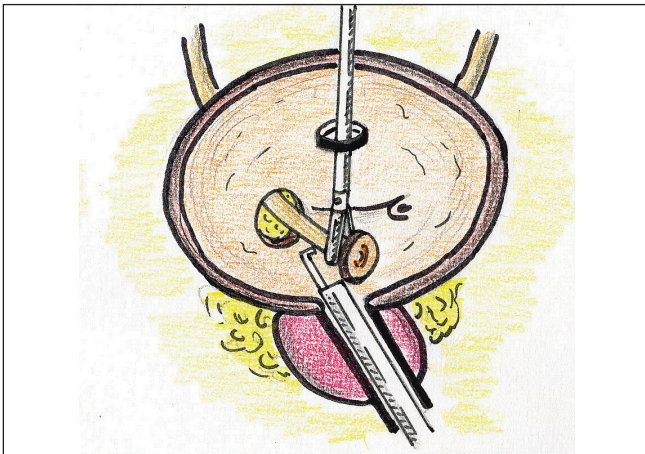
Patient is, then, placed in standard lateral kidney position for transperitoneal laparoscopic radical nephrectomy. After completing the nephrectomy, the ureter is traced to the lower end with surrounding tissues. Some tissue bands



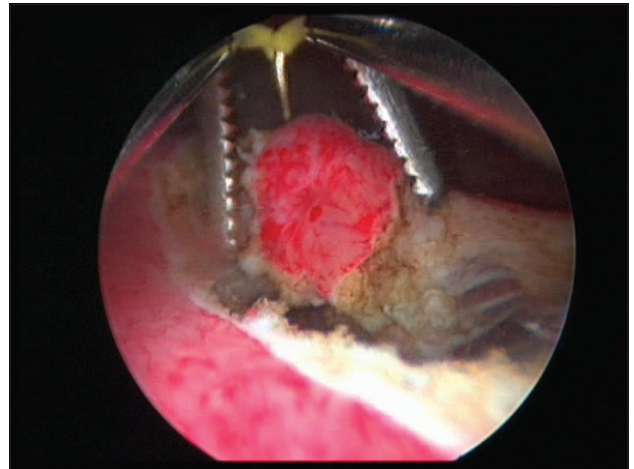
**Figure 1:** Dissection of bladder cuff around the ureteric meatus with Collings knife via resectoscope placed transurethrally



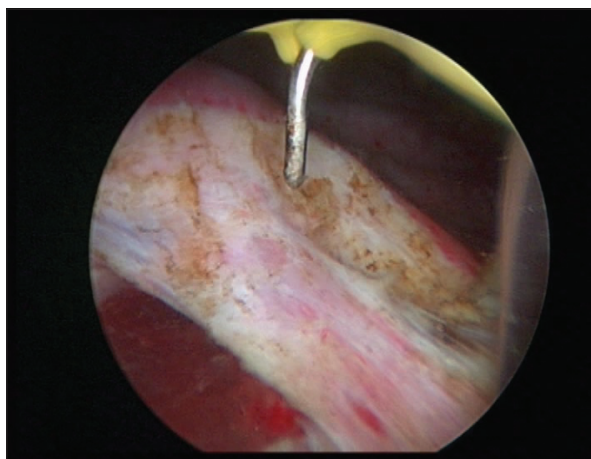
**Figure 2:** Endoscopic view of the dissected bladder cuff with fibers still attaching it at 12 o'clock



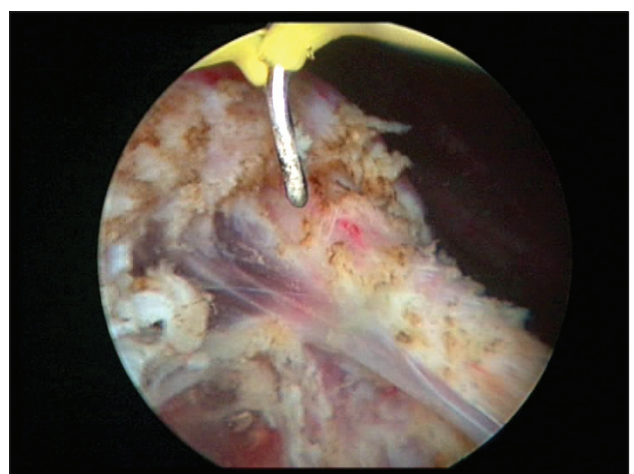**Figure 3:** Complete mobilization of intramural ureter with resectoscope and Collings knife, while ureter is retracted with grasper via transvesical port



**Figure 4:** Endoscopic view of grasper introduced via transvesical port



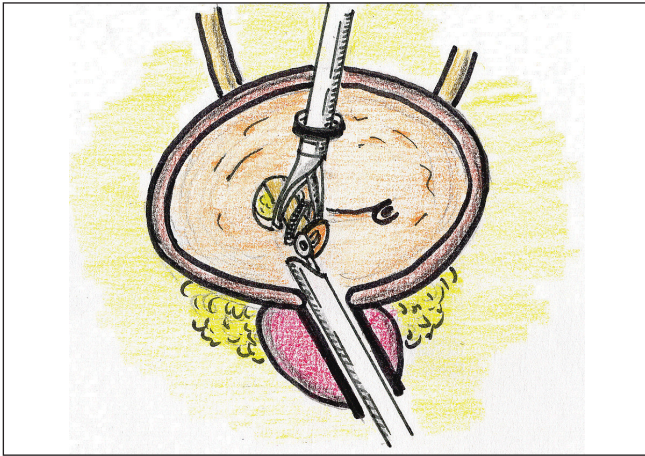
**Figure 5:** Ureter is retracted inferomedially to stretch remaining attached bladder fibers which are cut with Collings knife



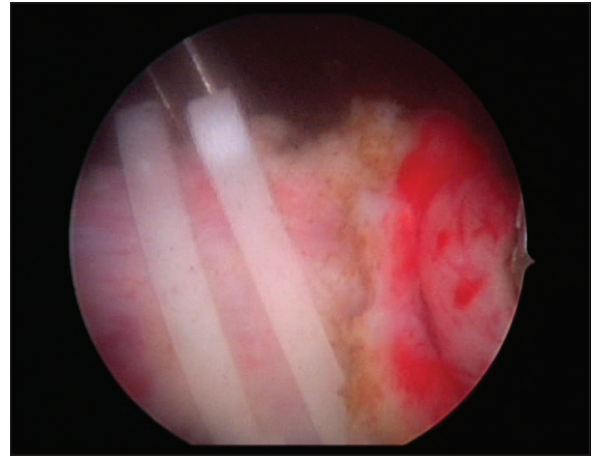
**Figure 6:** Dissection is done till ureter is completely free of all attachments

in retrovesical part of the ureter are easily dissected by retraction on ureter, and the clips applied at lower end soon come into view. Whole specimen en-bloc is trapped in an impervious bag. The suprapubic small incision for the port

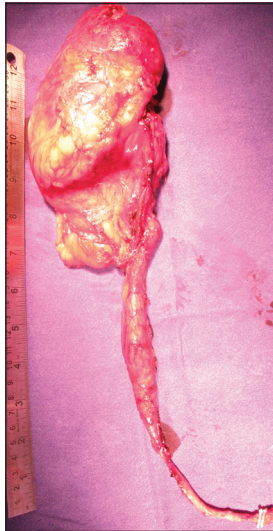
in step II is extended up for 6–8 cm. The bagged specimen is removed via the midline incision [Figure 9], and closure done after leaving retrovesical drain exiting just above right anterior superior iliac spine.



**Figure 7:** Resectoscope is exchanged for a cystoscope and forceps to grasp the bladder cuff end of ureter, while clip applicator via the transvesical port seals its lower end



**Figure 8:** Clips in place to seal lower end. Note the biopsy forceps being used to hold the bladder cuff at 3 o'clock



**Figure 9:** Completely removed nephroureterectomy specimen with clips at lower end

Histopathology and disease characteristics are recorded. Perioperative parameters have been noted prospectively in all patients. The patient is discharged with urethral catheter *in situ*. The urethral catheter is removed as outpatient on seventh postoperative day after a cystogram under fluoroscopy. All patients have been followed with abdominal imaging and check cystoscopies as per protocol.

## RESULTS

Three patients have undergone nephroureterectomy using the described technique. The lower end in two other cases of upper tract TCC was managed with open extravesical technique during this period. While one of latter cases had involvement of intramural part of ureter and tumor protruding out of ureteric orifice, the second case had synchronous bladder tumors.

Three cases managed with presented technique have been followed for 36, 12, and 9 months, respectively. A 10-mm suprapubic port was used to access the bladder in the first case, but a 5-mm port sufficed in cases 2 and 3 after the availability of a 5-mm hem-o-lock applicator. Average operating time was 160 minutes, and estimated blood loss averaged 230 ml. The management of the bladder end consumed 40, 55, and 30 minutes, respectively, in three cases. Postoperative hospital stay was 3 days in cases 1 and 3, and 4 days in case 2. Cystogram on seventh postoperative day revealed no signs of leak in any patient.

The first and third case had disease localized in the pelvicaliceal system on right and left side, respectively. Second case had multiple ureteric tumors in right upper ureter. Histopathology revealed pT3 (invasion of renal pelvis) in case 1, and pT1 high-grade TCC in cases 2 and 3. The first case has been given gemcitabine- and cisplatin-based chemotherapy. There has been no regional or local residual or recurrent disease in cases 1 and 3. Single low-grade cystoscopic recurrence at opposite bladder wall was noted in case 2 nine months postoperatively.

## DISCUSSION

Controversy regarding the lower ureteric management as part of nephroureterectomy has largely been due to the threat of implantation of TCC cells. The risk is low but real. In a large collective experience with 10,912 laparoscopic oncologic procedures from 19 institutions, port-site metastases occurred in 0.5% of operated cases, and were limited to LNU apart from a single case of RPLND. There were none from RCC and prostate cancer.<sup>[8]</sup> The inefficacy of partial cystectomy for TCC bladder and high incidence of local recurrences and peritoneal carcinomatosis following rupture of the bladder during TURBT are also indicators of the risk of TCC cell implantation.<sup>[9]</sup> Detachment of the ureteric meatus and the surrounding bladder cuff from the

bladder exposes the raw area and the retroperitoneum to the seepage of urine containing viable TCC cells, thereby risking implantation during LNU. Hence, the management of the lower end during LNU still remains a controversial topic in urological practice.

TCC is a multifocal disease. Synchronous bladder or upper tract disease may occur in 39% of patients with ureteric TCC and 24% of those with renal TCC.<sup>[10]</sup> A metachronous bladder recurrence occurs in 12.5–37.5% of patients with an upper tract TCC treated with surgery.<sup>[11]</sup> It is, therefore, imperative to exclude the disease in the bladder and the opposite renal unit before planning nephroureterectomy. Once the disease is confined to a single unit, the number of viable cells to reach a critical mass for implantation is dependent upon the grade of disease and the degree of manipulation of the diseased area before taking control of the distal end. Such manipulation may be intraluminal, as may occur with placements of ureteric catheters and stents, and during surgical handling in nephroureterectomy. During the attempted improvements over the earlier “pluck” and “intussusception” techniques, the importance of distal control has been realized. Gonzalez *et al.* controlled the upper ureter in laparoscopic view in the technical description of the case with renal pelvic tumor.<sup>[7]</sup> There were no local pelvic or peritoneal metastasis in 49 LNUs by Kurzer *et al.* with low control of ureter in laparoscopic vision. However, this technique was confined to pelvic and upper ureteral tumors only, while the lower ureteral tumors were managed by open technique.<sup>[1]</sup> Gill *et al.* further improved on it with control of the ureter at the vesical end, with no retroperitoneal or port-site metastasis. All cases of upper tract TCC were, thus, eligible except those with disease in intramural ureter, or distal to it.<sup>[6]</sup>

The sequence whether the lower ureteric end or the kidney should be tackled first may be argued. The gold standard open method deals with the kidney first, and the lower end is tackled in the end via an open cystotomy. “Lower end first” approach has been used with minimally invasive methods like “pluck” technique. The argument against “kidney first” would be the release of viable cells while handling the kidney and ureter. Although there is no raw area for implant at this time, this release of TCC cells may potentially explain some of the local recurrences in the bladder seen early postoperatively,<sup>[11]</sup> and may find the wound for implant after the cystotomy. The contact implant of TCC cells may occur even without a wound.<sup>[12]</sup> The “lower end first,” as in Gill’s technique, makes it possible to clip the ureter at its lowest end avoiding any possibility of cell spillage from the diseased unit while manipulating the kidney or ureter later during nephroureterectomy. The upper tract manipulation with an open lower end has been blamed for failures seen after the “pluck” technique, the earlier “lower end first” method.<sup>[6]</sup> Although the concept is theoretically sound, whether clipping the lower end before renal manipulation

would translate into lower bladder recurrences is a question that may be answered only with randomized trials and longer follow-up.

Manipulations like ureteric catheterization and barbotage may increase the number of shed TCC cells (as done for cytological diagnosis of the disease).<sup>[13]</sup> Whether intraluminal manipulations in the described techniques in literature may increase the shed load of TCC cells may also be debated. Kurzer *et al.* had a double-J stent in 18 of their 49 cases at the time of LNU, 7 of which developed bladder tumors postoperatively within a median follow-up of 10 months.<sup>[1]</sup> Gill *et al.* precede the ureteric meatal dissection with placement of a ureteric catheter till pelvis, although they did not report any retroperitoneal or port-site metastasis. It would, however, be desirable to avoid any intraluminal manipulations before taking control of the ureter at its lowest end, in order to avoid release of tumor cells, as is the case with extraluminal handling.

All minimally invasive procedures have been criticized for leaving cystotomy site without proper closure, allowing extravasation of urine to occur. While the ureteric hiatus is closed during the gold standard open surgery, the bladder has been left with the catheter drainage for 7 days without primary closure with most minimally invasive methods with no added morbidity.<sup>[1]</sup> Suprapubic ports, as in the present and some other recent described techniques, leave another bladder rent, albeit much smaller, adding to the criticism of these techniques. There is no or little risk of leaking urine, or potentially viable TCC cells if the disease has been excluded in the bladder and the opposite kidney, and the ipsilateral ureter has been clipped watertight. The conservative management of extraperitoneal bladder rupture with pelvic trauma has similar outcome to that of patients treated with primary closure.<sup>[14]</sup> All experiences with conservative management of cystotomy in LNU setting have also shown that the bladder shows no signs of leakage with radiologic tests within 7 days. Bladder perforations occur during 1.5–5% of transurethral resection of superficial bladder tumors.<sup>[15]</sup> Conservative management is successful in most such cases. It has been, interestingly, observed that all extravesical recurrences or evidence of metastatic disease occurred when the perforation was managed with open surgery.<sup>[9]</sup>

The ureteric catheter and stent in the bladder make the intravesical part of the procedure technically demanding. Kurzer *et al.* noted that the presence of the stent made cystoscopic excision more “taxing.”<sup>[1]</sup> Gill *et al.* emphasize the use of ureteric catheter via urethra, threaded through the endloop via one of the suprapubic ports, and the resectoscope being passed by the side of the ureteric catheter to accomplish cuff excision.<sup>[6]</sup> All the paraphernalia make the procedure cumbersome. There have been consistent attempts to simplify such combined endoscopic and

transvesical methods.<sup>[16]</sup> The presented technique too is a similar attempt using the same basic principles. There is no technical difficulty in separating the bladder muscle fibers and reaching perivesical plane from 1 to 11 o' clock using Collings knife without any assistance. The need, then, is to retract the ureter to separate the muscle fibers overlying it near 12 o'clock position, and then pull it inside bladder to release the intramural part. Single suprapubic port with a grasper suffices for this purpose in step 2 of our procedure, and later for step 3 to clip the lower ureteric end. Size of this single suprapubic port depends on the size of grasper and clip applicator available; thus a 5-mm port should suffice in most settings.

The technique described by us achieves the oncologic objectives of complete excision of bladder cuff and lower ureter with early control of the lower end prior to upper tract manipulation. It is a minimally invasive technique, which can potentially decrease patient morbidity and can be accomplished cost-effectively using routine endourological instrumentation. The technique uses a single suprapubic port, and avoids transluminal and extraluminal manipulation of the tumor containing upper tract. It seals the lowest end of ureter, thus making the procedure acceptable to all cases with unilateral TCC irrespective of the site, except rare cases where the disease is protruding out of ureteric orifice. The disadvantage is that it leaves the patient with two cystostomy sites for conservative healing. Small numbers of upper tract TCC cases even at a referral center make any randomized trials difficult, and would require multi-institutional combined studies to prove, or disprove, the potential benefits of these aspects of newer minimally invasive methods to deal with lower end of ureter during nephroureterectomy.

## CONCLUSIONS

The single suprapubic transvesical port approach has the potential of offering a minimally invasive approach for tackling the lower end of ureter in upper tract TCC while adhering to basic oncological principles of early control without prior manipulation of upper tract and complete excision of the lower end, as well as allowing en-bloc removal of the specimen with identification of the clipped lower end. A further prospective analysis of this technique in comparison with other methods is warranted prior to recommending its widespread applicability.

## REFERENCES

1. Kurzer E, Leveillee RJ, Bird VG. Combining hand assisted laparoscopic

- nephroureterectomy with cystoscopic circumferential excision of the distal ureter without primary closure of the bladder cuff - Is it safe? *J Urol* 2006;175:63-8.
2. Gill IS, Sung GT, Hobart MG, Savage SJ, Meraney AM, Schweizer DK, *et al.* Laparoscopic radical nephroureterectomy for upper tract transitional cell carcinoma: The Cleveland clinic experience. *J Urol* 2000;164:1513-22.
3. Matin SF, Gill IS. Recurrence and survival following laparoscopic radical nephroureterectomy with various forms of bladder cuff control. *J Urol* 2005;173:395-400.
4. Palou J, Rosales A, Salvador J, Villavicencio H. Re: Comparison of hand assisted and standard laparoscopic radical nephroureterectomy for the management of localized transitional cell carcinoma. *J Urol* 2004;172:773-4.
5. Hetherington JW, Ewing R, Philip NH. Modified nephroureterectomy: a risk of tumor implantation. *Br J Urol* 1986;58:368-70.
6. Gill IS, Soble JJ, Miller SD, Sung GT. A novel technique for management of the en bloc bladder cuff and distal ureter during laparoscopic nephroureterectomy. *J Urol* 1999;161:430-4.
7. Gonzalez CM, Batler RA, Schoor RA, Hairston JC, Nadler RB. A novel endoscopic approach towards resection of the distal ureter with surrounding bladder cuff during hand assisted laparoscopic nephroureterectomy. *J Urol* 2001;165:483-5.
8. Micali S, Celia A, Bove P, De Stefani S, Sighinolfi MC, Kavoussi LR, *et al.* Tumor seeding in urological laparoscopy: An international survey. *J Urol* 2004;171:2151-4.
9. Skolarikos A, Chrisofos M, Ferakis N, Papatsoris A, Dellis A, Deliveliotis C. Does the management of bladder perforation during transurethral resection of superficial bladder tumors predispose to extravesical tumor recurrence? *J Urol* 2005;173:1908-11.
10. Yousem DM, Gatewood OM, Goldman SM, Marshall FF. Synchronous and metachronous transitional cell carcinoma of the urinary tract: prevalence, incidence, and radiographic detection. *Radiology* 1988;167:613-8.
11. Oehlschläger S, Baldauf A, Wiessner D, Gellrich J, Hakenberg OW, Wirth MP. Bladder tumor recurrence after primary surgery for transitional cell carcinoma of the upper urinary tract. *Urol Int* 2004;73:209-11.
12. Yu DS, Harn HJ, Lee WH, Ma CP. Transitional cell carcinoma of the labia minor: evidence of contact implantation of bladder cancer. *J Urol* 1996;155:1699.
13. Dodd LG, Johnston WW, Robertson CN, Layfield LJ. Endoscopic brush cytology of the upper urinary tract: evaluation of its efficacy and potential limitations in diagnosis. *Acta Cytol* 1997;41:377-84.
14. Santucci RA, McAninch JW. Bladder injuries: evaluation and management. *Braz J Urol* 2000;26:408-14.
15. Collado A, Chéchile GE, Salvador J, Vicente J. Early complications of endoscopic treatment for superficial bladder tumors. *J Urol* 2000;164:1529-32.
16. Sesmero JH, Redondo CC, Delgado MC, Royo FC, Tesedo VR, Oceja JM. Intravesical sealing of the distal ureter in nephroureterectomy. *Arch Esp Urol* 2010;63:223-9.

**How to cite this article:** Ahlawat RK, Gautam G. Suprapubic transvesical single-port technique for control of lower end of ureter during laparoscopic nephroureterectomy for upper tract transitional cell carcinoma. *Indian J Urol* 2011;27:190-5.

**Source of Support:** Nil, **Conflict of Interest:** None declared.