

By Altering Ocular Immune Privilege, Bone Marrow–derived Cells Pathogenically Contribute to DBA/2J Pigmentary Glaucoma

Jun-Song Mo,¹ Michael G. Anderson,² Meredith Gregory,¹ Richard S. Smith,^{2,3} Olga V. Savinova,^{2,3} David V. Serreze,² Bruce R. Ksander,¹ J. Wayne Streilein,¹ and Simon W.M. John^{2,3,4}

¹The Schepens Eye Research Institute, Harvard Medical School, Boston, MA 02114

²The Jackson Laboratory, Bar Harbor, ME 04609

³The Howard Hughes Medical Institute, Bar Harbor, ME 04609

⁴Tufts University School of Medicine, Boston, MA 02111

Abstract

Pigment dispersion syndrome causes iris pigment release and often progresses to elevated intraocular pressure and pigmentary glaucoma (PG). Because melanin pigment can have adjuvant like properties and because the *Gpnmb* gene, which contributes to pigment dispersion in DBA/2J (D2) mice, is expressed in dendritic cells, we tested the hypothesis that ocular immune abnormalities participate in PG phenotypes. Strikingly, we show that D2 eyes exhibit defects of the normally immunosuppressive ocular microenvironment including inability of aqueous humor to inhibit T cell activation, failure to support anterior chamber (AC)-associated immune deviation, and loss of ocular immune privilege. Histologic analysis demonstrates infiltration of inflammatory leukocytes into the AC and their accumulation within the iris, whereas clinical indications of inflammation are typically very mild to undetectable. Importantly, some of these abnormalities precede clinical indications of pigment dispersal, suggesting an early role in disease etiology. Using bone marrow chimeras, we show that lymphohematopoietic cell lineages largely dictate the progression of pigment dispersion, the ability of the eye to support induction of AC-associated immune deviation, and the integrity of the blood/ocular barrier. These results suggest previously unsuspected roles for bone marrow–derived cells and ocular immune privilege in the pathogenesis of PG.

Key words: inflammation • immune tolerance • delayed hypersensitivity • anterior chamber • leukocytes

Introduction

Pigment dispersion syndrome (PDS)* is characterized by the deposition of abnormally liberated iris pigment within the anterior chamber (AC) and aqueous humor (AqH) drainage structures. PDS is medically important as it is very

common among both glaucoma patients and the general population (a population screen of 654 Caucasians detected PDS in 2.45% of this population, none were previously aware of the condition; reference 1). Many cases (>35%) progress to develop elevated intraocular pressure (IOP) and pigmentary glaucoma (PG; 2–4). The molecular mechanisms causing PDS and determining whether or not it progresses to PG are not known. PDS demonstrates simple inheritance in some families, but in others it is more complex and appears sporadic (5, 6).

DBA/2J (D2) mice develop a form of PG with similarities to human PDS (7). Iridial pigment dispersal in D2 mice is first clinically evident at 5–6 mo. By 9–10 mo, iris depigmentation is pronounced and increased IOP is common, resulting in AC enlargement and glaucoma (7). The depigmenting iris disease of D2 mice is genetically separable into

J.-S. Mo and M.G. Anderson contributed equally to this work.

Address correspondence to Simon W.M. John, The Howard Hughes Medical Institute, The Jackson Laboratory, 600 Main Street, Bar Harbor, ME 04609. Phone: 207-288-6475; Fax: 207-288-6079; E-mail: swmj@jax.org; or J. Wayne Streilein, The Schepens Eye Research Institute, Harvard Medical School, 20 Staniford Street, Boston, MA 02114. Phone: 617-912-7422; Fax: 617-912-0115; E-mail: waynes@vision.eri.harvard.edu

*Abbreviations used in this paper: AC, anterior chamber; ACAID, AC-associated immune deviation; AqH, aqueous humor; BALB, BALB/c mice; D2, DBA/2J mice; DH, delayed hypersensitivity; IOP, intraocular pressure; IPD, iris pigment dispersion; ISA, iris stromal atrophy; PDS, pigment dispersion syndrome; PG, pigmentary glaucoma; SFM, serum-free medium.

two distinct phenotypes, iris pigment dispersion (IPD) and iris stromal atrophy (ISA), which are caused by mutations in the *Gpnmb* and *Tyrp1* genes, respectively (8, 9). TYRP1 is believed to participate in melanosomal melanin synthesis, whereas GPNMB is less well characterized but also present in melanosomes (10–12). Because pigment dispersion caused by *Gpnmb* mutation has strong similarities to human PDS, including a pattern of radial iris depigmentation considered a hallmark of human PDS, D2 mice provide a valuable resource for defining factors that may contribute to human PG (7, 8, 13).

In addition to a melanosomal component to the D2 disease, several intriguing observations suggest that pigment dispersal in D2 eyes might involve immune dysfunction. Foremost of these is that *Gpnmb* is expressed in some types of dendritic cells (14, 15), a potent professional APC normally resident in the iris (16, 17). Furthermore, TYRP1, as well as melanin itself, have been identified as antigens relevant to inflammatory eye disease (18, 19) and melanin can also exhibit adjuvant-like properties (18, 20). Although D2 mice with altered GPNMB and TYRP1 function could theoretically support aberrant immune reactions through a number of different pathways, a role of the immune system in D2 pigment dispersion has not previously been addressed.

Here, we test the novel hypothesis that ocular immune abnormalities contribute to the pathogenesis of pigment dispersion in D2 mice. We present multiple lines of evidence for compromised ocular immune privilege, which is accompanied by a mild but chronic inflammatory response in D2 eyes. Importantly, we show that the genotype of bone marrow–derived cells in D2 mice determines the presence or absence of the prominent pigment dispersion associated with mutation of *Gpnmb* through mechanisms related to ocular immune privilege. These results demonstrate that cells of bone marrow origin pathogenically contribute to abnormal pigment dispersion. By implication, these data suggest that previously unsuspected immune abnormalities may amplify the level of pigment dispersion and therefore increase the likelihood of PDS progression to PG in humans.

Materials and Methods

Animal Husbandry. Female D2, C57BL/6J (B6), and B6D2F1/J (B6D2F1) mice were obtained from The Jackson Laboratory. BALB/c (BALB) mice were obtained from The Schepens Eye Research Institute's animal breeding facility. D2 mice and D2 bone marrow chimeras used in studies of AqH and AC-associated immune deviation (ACAID) induction were aged at The Jackson Laboratory under previously described environmental conditions (7, 8), and shipped to The Schepens Eye Research Institute for experimentation. All animals were treated according to the guidelines of the Association for Research in Vision and Ophthalmology for use of animals in research. All experimental protocols were approved by the Animal Care and Use Committee of The Schepens Eye Research Institute or The Jackson Laboratory. Where appropriate, mice were anesthetized using intraperitoneal

injection of ketamine (Ketalar; Parke-Davis) and xylazine (Rompun; Phoenix Pharmaceutical).

AqH Collection and Analysis. AqH was collected, pooled (2 μ l/eye, 6–10 eyes/pool), and centrifuged at 4,000 rpm for 4 min (21). Protein concentration was determined using 1 μ l of the supernatant (BCA; Pierce Chemical Co.), and the remaining supernatant was frozen immediately at -70°C until used in the T cell proliferation assay. The sediment after centrifugation was resuspended in 20 μ l PBS and 10 μ l was used to count cells using a hemocytometer. Remaining cells from each age group were combined, stained with Giemsa, and subjected to differential analysis. FACS[®] profiles of AqH were collected by labeling the pooled AqH of 10 eyes from 6-mo-old female D2 mice with conjugated mAb.

Flow Cytometry. The conjugated mAb used for FACS[®] analysis of AqH preparations were against murine MHC class II FITC (M5/114; The Jackson Laboratory Flow Cytometry Service), murine CD11b PE (BD Biosciences), and murine CD11c APC (BD Biosciences). The mAbs used to analyze bone marrow chimeras were against murine MHC class I H-2K^d PE (SF1-1.1; BD Biosciences) and murine H-2K^b FITC (28-13-3s; The Jackson Laboratory Flow Cytometry Service). Labeling was assessed by multicolor flow cytometry (FACScan[™] or FACScalibur[®]; BD Biosciences) and analyzed using the CellQuest 3.3 data reduction system (BD Biosciences).

Anti-CD3 Stimulated Assay for In Vitro T Cell Proliferation. T cells were isolated from single cell suspensions of spleens from naive BALB mice using a T cell enrichment column (R&D Systems). Enriched T cells were resuspended in serum-free medium (SFM). Using a 96-well V-shaped bottom plate (Corning), 2.5×10^4 enriched T cells in 10 μ l SFM and 5 μ l AqH or PBS were added per well and cultured for 1 h, followed by the addition of 10 μ l hamster anti-mouse CD3e IgG (2C11, 2.5 μ g/ml; BD Biosciences) in 10 μ l SFM or 10 μ l SFM alone. Cells were pulsed with 2.5 μ l 20 mCi/ml [³H]thymidine for the final 8 h of the 48-h incubation (37°C, 5% CO₂-95% humidified air mixture) and [³H]thymidine incorporation measured in cpm.

Induction of OVA-specific ACAID. OVA was injected (50 μ g in 2 μ l HBSS) into the AC of one eye of mice. 7 d later, these mice were immunized subcutaneously with 100 μ g OVA emulsified 1:1 in CFA (total volume 100 μ l). Positive control mice received subcutaneous immunization without any previous exposure to OVA. After another 7 d, 200 μ g/10 μ l OVA was injected intradermally into one ear pinna, and swelling of the injected ear was assessed 24 h later using an engineer's micrometer (Mitutoyo 227-101). Negative controls received only intrapinnae injections of OVA. Ear swelling is expressed as (24-h measurement of the ear) – (0-h measurement of the ear).

Intracamerular Tumor Growth. After making an incision at the center of the cornea with the tip of a 30-G needle, 3 μ l air was injected into the AC, followed by 2 μ l suspended CT26.WT (10^4) or T lymphoma L5178Y-R (2×10^3) cells. The remaining 1 μ l air served to seal the incision. AC growth of tumors was monitored using a slit-lamp biomicroscope (21).

Clinical and Histologic Analysis. Eyes were examined with a slit-lamp biomicroscope and photographed with a 40 \times objective lens. Phenotypic assessment of iris atrophy, dispersed pigment, and transillumination was performed according to previously described criteria (7, 9). Fluorescein leakage studies used mice intraperitoneally injected with 25% sodium fluorescein at a dose of 0.01 ml per 5–6 g body weight (Akorn Inc.; reference 22). Histologic analyses used hematoxylin and eosin–stained sections of eyes

fixed in phosphate-buffered glutaraldehyde paraformaldehyde mixture (7, 9).

Generation and Analysis of Bone Marrow Chimeras. Bone marrow chimeras were generated as follows: 4–8-wk-old female D2 and B6D2F1 mice were lethally irradiated (1,000 rad from a ¹³⁷Cs source) and then received 200 μ l intravenous injections containing 5×10^6 T cell-depleted bone marrow cells from the indicated donor strains. Donor marrow was depleted of T lymphocytes with 10 μ g/ml purified mAbs to CD4 (GK1.5; The Jackson Laboratory Flow Cytometry Service) and CD8a (53-6.72; The Jackson Laboratory Flow Cytometry Service). Peripheral blood extracted from the lateral tail vein of chimeras was assessed by multicolor flow cytometry to determine the degree of chimerism. Eyes of chimeras were assayed at 3–5-wk intervals.

Gene Abbreviations. The official full names of genes (with abbreviated protein designations used here in parentheses) are: glycoprotein (transmembrane) nmb (GPNMB); tyrosinase-related protein 1 (TYRP1); transforming growth factor, beta 2 (TGF β 2); tumor necrosis factor (ligand) superfamily, member 6 (CD95L); and tumor necrosis factor receptor superfamily, member 6 (CD95).

Results

Compromised Ocular Immunosuppression: Altered Microenvironment. Normal AqH is strongly immunosuppressive and profoundly inhibits T cell activation in vitro (23). We tested AqH from D2 and control BALB mice for capacity to suppress anti-CD3-driven T cell proliferation in vitro (Fig. 1). As expected, AqH from BALB eyes completely suppressed T cell proliferation whereas D2 AqH never inhibited T cell proliferation and actually displayed mitogenic activity, demonstrating the existence of a compromised intraocular immunosuppressive environment. Similar results were obtained using BALB and D2 AqH at concentrations of 3, 10, and 20%. AqH from D2 eyes lacked immunosuppressive properties at both 2 and 4 mo, ages that actually precede clinically detectable pigment dispersion.

Compromised Ocular Immunosuppression: Deficient ACAID. Ocular immune privilege expresses itself in part through a form of eye-dependent tolerance termed ACAID (24). Injection of antigenic material into the AC of wild-type mice induces a deviant systemic immune response that is devoid

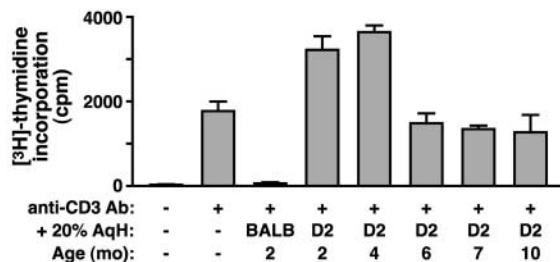


Figure 1. D2 AqH lacks immunosuppressive properties. T cells were added to medium containing AqH at various concentrations, as shown here for 20% AqH from BALB or D2 mice of the indicated ages. Cells were stimulated with anti-CD3 antibodies for 48 h and assayed for [³H]thymidine incorporation into proliferating cells. Single pools of AqH were used for each age in the assay, each pool consisting of 6–10 eyes. Values are mean cpm \pm SEM of three to six wells.

of the effectors causing immunogenic inflammation: T cells that mediate delayed hypersensitivity (DH) and B cells that secrete complement-fixing antibodies. Thus, in contrast to antigens injected subcutaneously, antigens injected into the AC do not normally result in DH upon subsequent challenge with the same antigen, whether encountered in the eye or elsewhere. When ocular immune privilege is compromised, the capacity to support ACAID is usually abolished as well. Next, we examined whether eyes of aging D2 mice were capable of supporting ACAID induction (Fig. 2). As anticipated, OVA injected into the AC of control BALB eyes led to a profound impairment of OVA-specific DH (Fig. 2 A). OVA injected into the AC of 2-mo-old D2 mice moderately impaired the development and expression of DH (Fig. 2 B), whereas injection of OVA into AC of 4- or 6-mo-old D2 mice failed completely to inhibit OVA-specific DH (Fig. 2, C and D). These results suggest that a functional breakdown of conditions supporting immune privilege exists in D2 eyes before the onset of clinical disease.

Compromised Ocular Immunosuppression: Innate Immune Privilege. Although immunosuppressive properties of AqH and the capacity to support ACAID induction are reliable

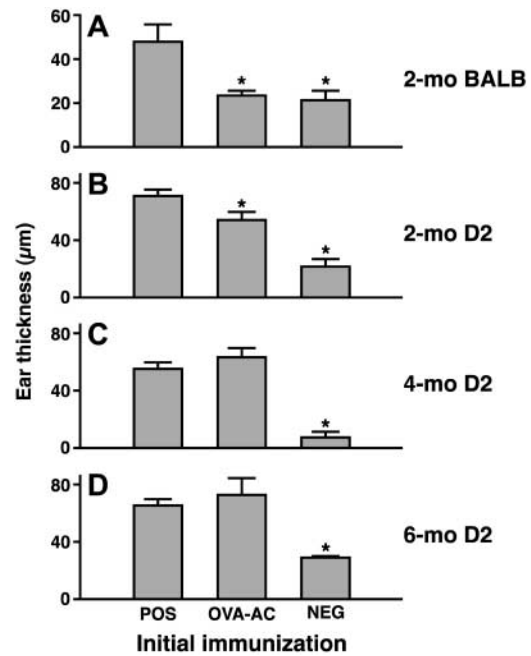


Figure 2. Deficient ACAID induction in D2 mice. ACAID induction was assessed in aged cohorts of mice, as shown here for (A) 2-mo-old BALB mice, (B) 2-mo-old D2 mice, (C) 4-mo-old D2 mice, or (D) 6-mo-old D2 mice. 50 μ g OVA was injected into the AC (OVA-AC). 1 wk later the mice were immunized subcutaneously with OVA plus CFA and challenged with intrapinnae injections of OVA after an additional 7 d. DH responses are indicated by increased ear thickness 24 h after challenge. Positive controls (POS) received only immunizations of OVA plus CFA injected subcutaneously, but no injections of OVA into AC. Negative controls (NEG) were naive mice receiving only intrapinnae challenges. Mean ear swelling responses \pm SEM (five mice per group) are presented. *, values significantly lower than positive controls ($P < 0.05$, Student's t test).

corollaries of ocular immune privilege, they do not test directly if immune privilege is present and intact. Our next experiments evaluated whether ocular immune privilege is retained in D2 mice as they acquire IPD.

Innate immune privilege can be tested by examining the fate of mice receiving AC injections of syngeneic tumors. TGF β 2, a key immunomodulatory factor constitutively present within AqH, blocks the ability of CD95L to trigger neutrophil cytolytic activity and cytokine release in the normal AC (25). Therefore, tumor cells expressing CD95L that are implanted in the AC are not vulnerable to destruction by CD95⁺ neutrophils and these recipients succumb to progressive tumor growth and metastasis (26). By contrast, when implanted into nonprivileged sites, CD95L⁺ tumor cells activate CD95⁺ neutrophils and are rejected by these innate immune effectors (the activated neutrophils), permitting recipient survival. To assess the integrity of innate ocular immune privilege in D2 mice at 2 and 7 mo, CD95L⁺ or CD95L⁻ DBA/2-derived T lymphoma L5178Y-R tumor cells were injected into the AC (Fig. 3 A). Regardless of age, D2 recipients of CD95L⁻ tumor cells developed progressively growing tumors and 100% of these mice died by 18 d (not depicted). Similarly, 2-mo-old D2 recipients of CD95L⁺ tumor cells succumbed to their tumors, indicating that innate immune privilege was intact. By contrast, a high proportion (>50%) of 7-mo-old D2 mice were able to contain the intraocular growth of CD95L⁺ tumor cells, and these mice survived. Thus, innate immune privilege appears to be intact in eyes of 2-mo-old D2 mice, but is compromised by 7 mo.

Compromised Ocular Immunosuppression: Adaptive Immune Privilege. Adaptive immune privilege can be tested by examining the fate of histoincompatible tumor cells injected

into the AC. Ocular immune privilege is revealed when histoincompatible tumors grow progressively in the AC, but are rejected when implanted subcutaneously (27). For these experiments, CT26.WT, a chemically induced colon carcinoma cell line derived from BALB mice, was selected because this mouse strain shares with D2 the same *H2* haplotype, *H2^d*, but differs from D2 at multiple minor histocompatibility loci. CT26.WT tumor cells were injected either into the AC or subcutaneous space (positive control for rejection) of D2 mice at 2 and 7 mo. As negative controls, CT26.WT cells were similarly injected into 2-mo-old syngeneic BALB mice. CT26.WT cells never formed tumors after injection into the subcutaneous space of D2 mice, although they readily formed tumors at this site in BALB mice. This indicates that systemic immunity of D2 mice is capable of detecting and destroying histoincompatible tumor cells placed at a nonimmune privileged site. By contrast, CT26.WT cells formed progressively growing tumors in the AC of 2-mo-old D2 (Fig. 3 B) and BALB mice. Moreover, the rate of tumor growth was comparable in both sets of recipients (not depicted). This indicates that eyes of 2-mo-old D2 mice offer adaptive immune privilege to histoincompatible tumor cells. However, CT26.WT tumor cells that formed tumors in the eyes of 7-mo-old D2 mice exhibited a significant delay in the onset of tumor growth compared with that observed in 2-mo-old D2 (Fig. 3 B). Because delayed outgrowth of histoincompatible tumor cells is an expression of compromised immune privilege, this result indicates adaptive immune privilege attenuates in the eyes of older D2 mice. Importantly, our tumor growth experiments show deficits in both adaptive and innate immune privilege in 7-mo-old D2 mice, an age when iris pigment dispersion is aggressive.

Compromised Ocular Immunosuppression: Deficient Blood/Ocular Barrier. An intact blood/ocular barrier is believed to be an important component of normal ocular immune privilege. Normal AqH contains extremely low levels of protein and no leukocytes, indicating that barriers normally exclude virtually all plasma proteins and leukocytes from entering the ocular microenvironment. AqH from 2-mo-old D2 eyes contained barely detectable amounts of protein, similar to levels found in AqH of normal BALB eyes. However, AqH from 4-mo-old D2 mice contained slightly elevated levels of protein and these levels continued to rise through the ages tested (Fig. 4 A). No rise of protein levels occurred in AqH from older BALB mice. We first detected leukocytes in AqH of 6-mo-old D2 mice with higher numbers of inflammatory cells present at 7 mo (Fig. 4 B). The predominant leukocyte present at 6 mo was the neutrophil whereas mononuclear cells predominated at 7 mo (Fig. 4 C). Ingested melanin was frequently seen in the cytoplasm of these mononuclear cells. FACS[®] analysis of AqH at 6 mo revealed that the infiltrating leukocytes stained positive for CD11b, CD11c, and MHC class II (including MHC class II⁺ CD11b⁺ CD11c⁻ and MHC class II⁺ CD11b⁺ CD11c⁺ phenotypes; not depicted). These phenotypes indicate that macrophages and dendritic cells are present. AqH collected from 10-mo-

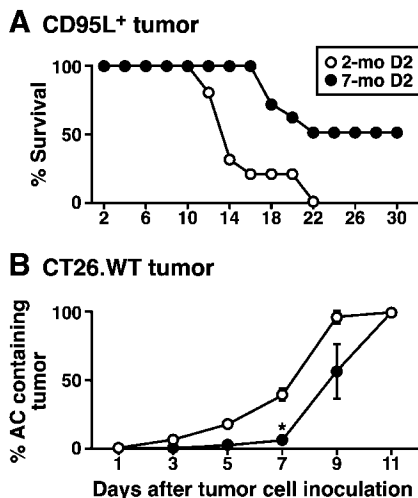


Figure 3. Compromised innate and adaptive immune privilege to intracameral tumor cells in aged D2 mice. (A) CD95L⁺ tumor cells were injected into the AC of 2- and 7-mo-old D2 mice. Percentage of recipients surviving through 30 d are indicated. (B) CT26.WT tumor cells were injected into the AC of 2- and 7-mo-old D2 mice. Percentage of AC filled with tumor is indicated through 11 d after tumor injection. *, a significant difference ($P < 0.05$, Student's *t* test).

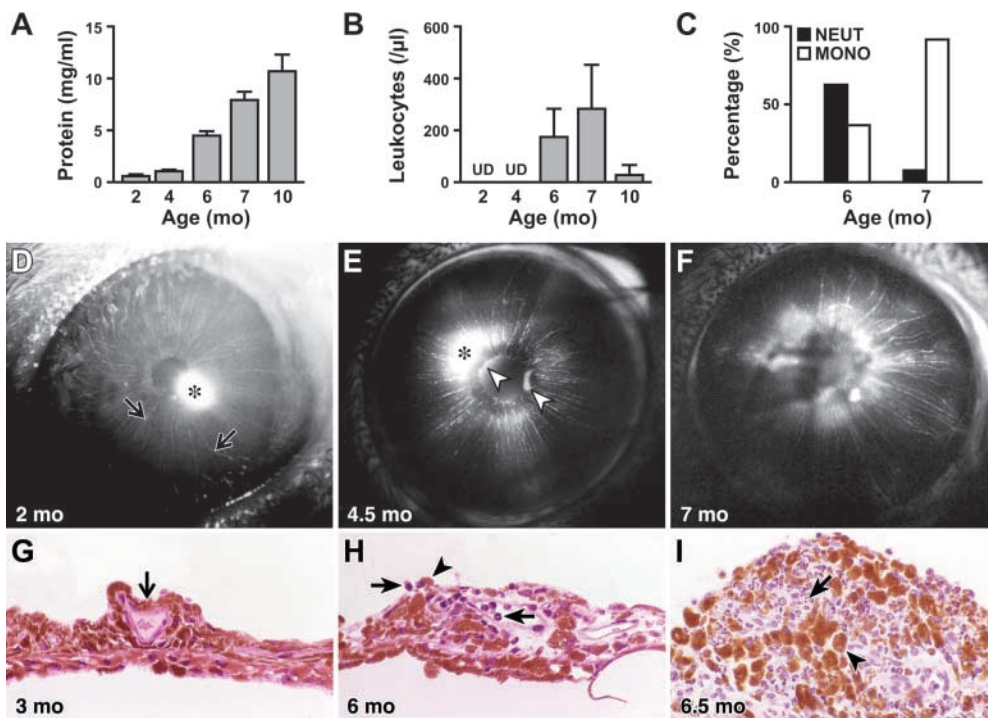


Figure 4. Breakdown of blood/ocular barrier integrity and leukocyte infiltration of D2 eyes. AqH collected from D2 mice at indicated ages was analyzed for: (A) protein content, (B) leukocyte content, and (C) proportion of leukocytes that were neutrophils and mononuclear cells. Values represent mean \pm SEM of 10 mice. (D–F) Fluorescein was injected intravenously into D2 mice and the presence of fluorescein within and outside intraocular vessels was assessed. The * indicate artifacts caused by light source reflections. (D) Before 4 mo, eyes show only intravascular fluorescein (thin arrows). (E and F) After 4 mo, eyes showed extravascular fluorescein emerging from behind the pupil (open arrowheads) and extravascular fluorescein diffusely staining the iris stroma. (G–I) Histologic sections of D2 eyes, revealing leukocyte margination and iris infiltration. (G) At 3 mo, D2 irides appear normal and vessels lack leuko-

cyte margination (thin arrow). (H) At 5 mo and beyond, neutrophils (thick arrow) and macrophages (filled arrowhead) are present in the AC and on the anterior surface of iris. H illustrates leukocyte margination (thick arrow) occurring in an iris vessel. (I) After 6 mo, the peripupillary border of the iris becomes thickened and is comprised of pigment-bearing macrophages (filled arrowhead) and neutrophils (thick arrow). Even in severely affected eyes such as the one shown in I, iridial thickening is limited to the peripupillary margin. Original magnification: $\times 630$. UD, undetectable; NEUT, neutrophils; MONO, mononuclear cells.

old D2 mice contained even higher levels of protein but very few leukocytes, suggesting that the intraocular inflammatory response had abated. Leukocytes were never detected in AqH of BALB mice at any age. These results strongly suggest that D2 mice experience breakdown of the blood/ocular barrier at ~ 4 mo, after which inflammatory leukocytes enter the AC. This inflammatory response is sustained for several months, but declines as the mice reach 10 mo. At no time during this interval did the eyes of these mice become red or show evidence of severe inflammation.

To directly assess the functional integrity of the blood/ocular barrier in D2 mice, we performed fluorescein angiography on 2–7-mo-old mice. As expected, no evidence of fluorescein vascular leakage from intraocular vessels was observed in control BALB and B6 mice, and before 4 mo, no fluorescein leakage occurred in eyes of D2 mice (Fig. 4 D). In D2 older than 4 mo, fluorescein leakage was observed in some eyes, entering the AC from behind the iris (Fig. 4 E) and from the iris stroma (Fig. 4 F). By 7 mo all D2 eyes exhibited fluorescein leakage ($n = 10$ of 10 eyes), directly demonstrating that breakdown of the blood/ocular barrier accompanies the pigment dispersion that results in glaucoma in these mice.

Leukocyte Margination and Iris Infiltration. We examined eyes from aging D2 mice for histologic indications of iris infiltration by inflammatory cells. Through 3 mo, we detected no inflammatory cells in the iris or AC of any D2

mice (Fig. 4 G). By 5 mo, however, and increasingly so by 7 mo, eyes of D2 mice demonstrated a mild but consistent inflammatory response in the anterior segment. In 5- and 6-mo-old eyes, when clinical iris disease is barely detectable, mononuclear cells and neutrophils marginated along the walls of iris vessels and were present both in the iris and on the iris surface (Fig. 4 H). The number of these cells increased through 7 mo, when pigment dispersion is rampant, at which time macrophages were the most abundant infiltrating leukocyte. In these older D2 mice, macrophages containing melanin were present in the AC and accumulated in the iris stroma, especially at the pupillary border (Fig. 4 I) and in the trabecular meshwork. These data demonstrate that leukocyte infiltration of the iris is an early feature of D2 pigment dispersion.

D2 Bone Marrow Is Necessary for Severe Pigment Dispersion and Glaucomatous Progression. The D2 iris depigmentation is initiated by a form of melanosomal toxicity with *Gpnmb* mutation causing profound dispersal of pigment and *Tyrrp1* mutation causing iris stromal atrophy accompanied by mild dispersal of pigment clumps into the AC (8, 9). Because D2 eyes have compromised immune privilege and the iris is infiltrated with leukocytes, we tested if bone marrow genotype affects the severity of pigment dispersion occurring in eyes facing iris insults resulting from *Gpnmb* and *Tyrrp1* mutation. Bone marrow contains progenitors for hematopoietic lineages, causing reconstituted recipients to develop leukocyte lineages with cells of the donor genotype. To test

the effects of bone marrow genotype, we reconstituted D2 mice with B6D2F1 or D2 (control) marrow and followed them clinically for indications of iris disease (Figs. 5 and 6). Additionally, B6D2F1 mice were reconstituted with D2 marrow. B6D2F1 mice have wild-type iris morphology and did not develop iris disease after reconstitution with D2 marrow, indicating that the progeny of D2 bone marrow alone are not capable of causing the disease. As expected, lethally irradiated D2 recipients reconstituted with D2 marrow developed transillumination defects (resulting from iris depigmentation), severe pigment dispersion, thickening of the pupillary border at 6 mo, and glaucomatous AC enlargement. The severity and onset of these phenotypes were identical to unmanipulated D2 mice (7–9). By contrast, D2 mice reconstituted with B6D2F1 marrow exhibited significant reduction of iris depigmentation. The rescuing effect of B6D2F1 marrow resulted in strikingly less transillumination than in mice with D2 marrow at both 6 (compare Fig. 5 I with E) and 10 mo (compare Fig. 5 J with F). These mice never developed the peripupillary iris

thickening typically observed in D2 at 6 mo. When observed at 10 mo of age these recipients never developed severe pigment dispersion characteristic of IPD (compare Fig. 6 I with F). Importantly, B6D2F1 marrow also prevented the enlargement of the AC in D2 recipients at 10 mo (compare Fig. 5 K with G). The AC normally becomes enlarged due to elevated IOP in D2 mice at this age. The absence of AC enlargement shows that not only has the iris disease been ameliorated in bone marrow–reconstituted mice, but the glaucomatous progression toward PG has been suppressed as well.

Despite the striking rescue of pigment dispersion and peripupillary iris thickening associated with the D2-derived *Gpnmb*^{R150X} mutation (8, 9), bone marrow genotype did not affect all components of the D2 iris disease. D2 reconstituted with B6D2F1 marrow still displayed a small degree of transillumination (Fig. 5, I and J) and iris stromal atrophy (Fig. 6, H and I). In these mice, iris stromal atrophy that is associated with the D2-derived *Tyrrp1*^b mutation appeared to be unchanged.

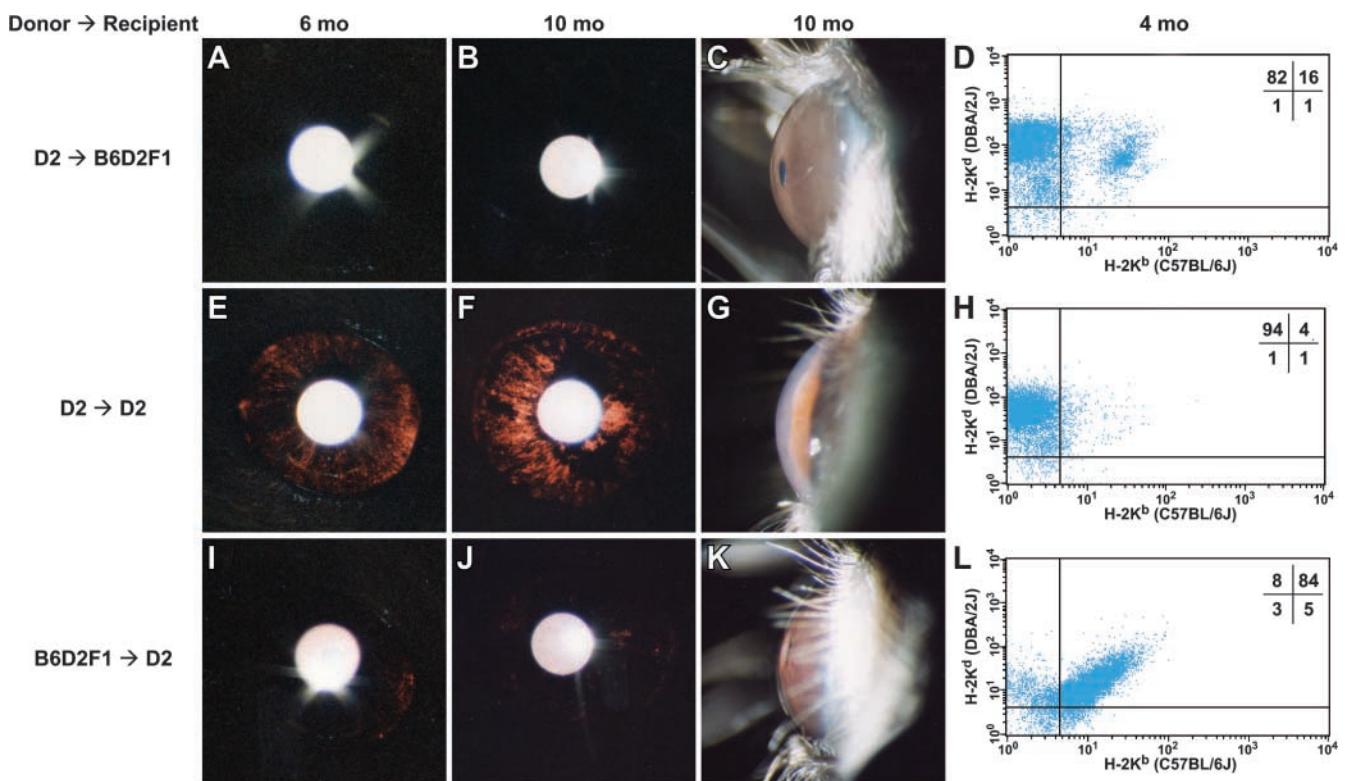


Figure 5. B6D2F1 bone marrow suppresses depigmentation and AC enlargement. Representative eyes of bone marrow chimeras of indicated strains and ages. Glaucoma in D2 mice is typically associated with a pigment-dispersing iris disease, resulting in changes to the morphology of the iris. Subsequently, dispersed pigment becomes aberrantly deposited on a variety of structures including the surface of the iris, lens, and cornea. Dispersed pigment is also deposited in the AqH drainage structures, leading to increased IOP and enlargement of the AC (the space between the iris and cornea). The two left columns show transilluminating views assaying the degree of iris depigmentation, detectable as red areas within the image where reflected light is passing through the iris. The third and fourth columns show AC dimensions and representative FACS[®] profiles. (A–D) B6D2F1 recipients of D2 marrow show no signs of depigmentation at any age and ACs of normal dimension with a closely juxtaposed cornea and iris ($n = 12$ mice at 4 mo, 11 mice at 6 mo, and 8 mice at 10 mo). (E–H) D2 recipients of D2 marrow–developed iris disease and signs of glaucoma following a time course and severity indistinguishable from unmanipulated D2 mice. These eyes developed moderate to severe iris transillumination and very enlarged ACs typical of mice with increased IOP. Reconstitution is presumed based on the survival of the mice after lethal irradiation ($n = 12$ mice at 4 mo, 12 mice at 6 mo, and 8 mice at 10 mo). (I–L) Iris disease in D2 recipients of B6D2F1 marrow was significantly suppressed at all ages, as shown by relatively mild degrees of transillumination and ACs of normal dimension ($n = 12$ mice at 4 mo, 11 mice at 6 mo, and 9 mice at 10 mo).

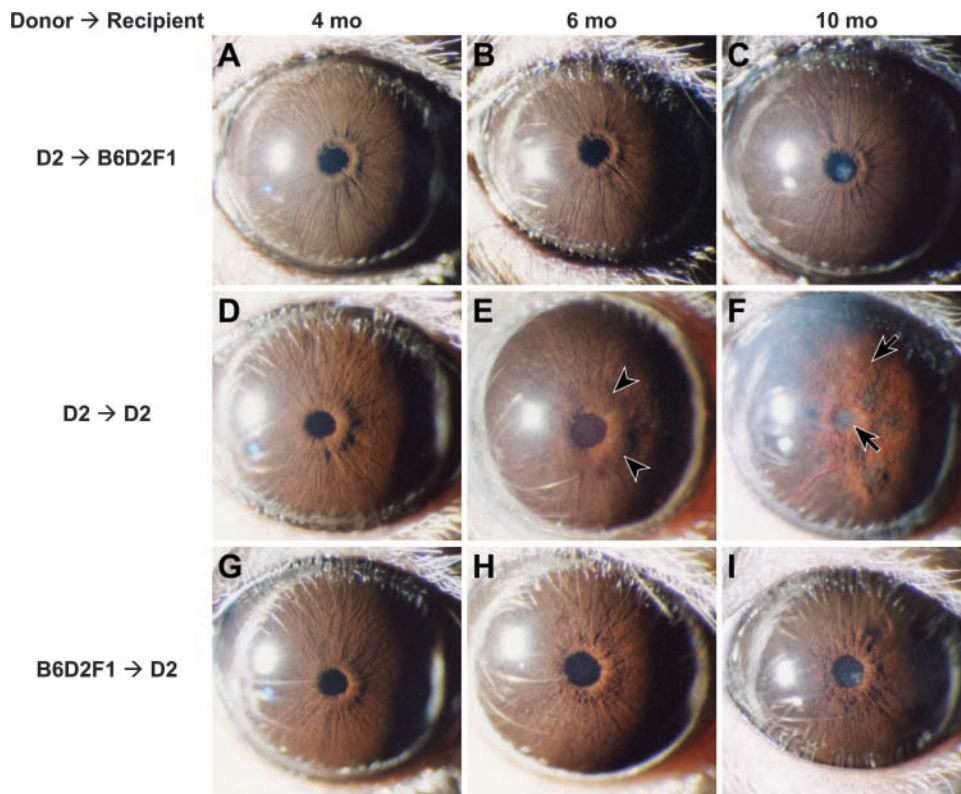


Figure 6. B6D2F1 bone marrow suppresses peripupillary thickening and severe pigment dispersion. Eyes of bone marrow chimeras of indicated strains and ages. Representative eyes from each cohort and age are shown, the number of mice per cohort are the same as for Fig. 5. All images are from clinical slit-lamp examination with broad beam illumination to assay for the presence of dispersed pigment within the AC and iris stromal morphology. (A–C) B6D2F1 recipients of D2 marrow maintain normal iris morphology at all ages. (D–F) Eyes from D2 recipients of D2 marrow exhibit a characteristic disease progression. At 4 mo, irides exhibit predisease morphology, 6-mo irides develop a significant thickening surrounding the pupil (arrowheads), and 10-mo irides become severely atrophic. Dispersed pigment is visible on the lens and AC structures (arrows) and iris atrophy is pronounced, particularly in the peripupillary margin. (G–I) Eyes from D2 recipients of B6D2F1 marrow are characterized by a less severe phenotype. At 4 mo, irides show no signs of disease, at 6-mo irides lack the pronounced peripupillary thickening characteristic of un-

manipulated D2 eyes, and 10-mo irides maintain significant overall integrity and lack the presence of large amounts of dispersed pigment typically observed on the lens, cornea, and iris. The peripupillary margin of 6- and 10-mo irides is mildly atrophic.

B6D2F1 Bone Marrow Restores ACAID and Integrity of the Blood/Ocular Barrier. To further characterize the rescuing effect of B6D2F1 bone marrow on D2 recipients, a cohort of these chimeric mice was analyzed at 6 mo for immune status of the ocular microenvironment and immune privilege. In addition to alleviating pigment dispersion, there was little indication of the type and extent of inflammation typically observed in eyes of D2 mice. AqH from chimeric D2 recipients of B6D2F1 bone marrow contained no leukocytes and barely detectable amounts of protein, revealing that the blood/ocular barrier was intact. Moreover, the eyes of the chimeric mice readily supported ACAID induction (Fig. 7 A). However, not all of the ocular immune abnormalities observed in D2 mice were corrected. AqH from chimeric D2 mice reconstituted with B6D2F1 bone marrow failed to suppress anti-CD3-driven T cell proliferation in vitro (Fig. 7 B).

Discussion

Our current experiments document fundamental new aspects of pigment dispersion in D2 mice. We show that D2 eyes destined to develop pigment dispersion and PG have multiple abnormalities related to ocular immune privilege. AqH from affected D2 mice contains elevated protein levels and their iris vessels leaked fluorescein dye, indicating a breakdown in the blood/ocular barrier. AqH from D2 eyes also contained leukocytes (initially predominated

by neutrophils, then mononuclear cells) reflecting the mild but sustained inflammation of the iris detected by histologic study. Both innate and adaptive immune privilege were compromised in eyes of 7-mo-old D2 mice tested with appropriate challenges of tumor cells. This array of findings implicates immune aberrations and inflammation in the pathogenesis of pigment dispersion in D2 mice.

Although the above results suggest participation of immune and inflammatory factors in the pathogenesis of pigment dispersion in D2 mice, they do not address whether they are primary disease characteristics or secondary consequences of pigment dispersion. Melanin pigment has potent adjuvant-like properties (20) and enhances intraocular inflammation in experimental autoimmune uveitis (18). Furthermore, melanosomal proteins are themselves potentially immunogenic (28, 29). Thus, it seemed reasonable that dispersed pigment could contribute to a loss of ocular immune privilege in D2 mice. Contradicting this idea, we found that some of the immune abnormalities (lack of immunosuppressive properties of AqH at 2 mo and altered ACAID induction at 2 and 4 mo) substantially precede pigment dispersion. Further evidence against this idea is provided by our bone marrow chimera experiments. These experiments show that reconstitution of irradiated D2 mice with B6D2F1 marrow rescues the prominent pigment dispersion phenotype (IPD) that is caused by *Gpnmb* mutation. However, bone marrow reconstitution did not rescue the iris stromal atrophy phenotype caused by *Typr1* muta-

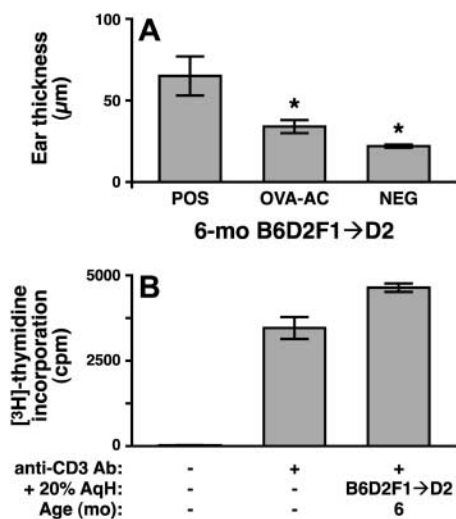


Figure 7. B6D2F1 bone marrow restores ACAID induction but not AqH immunosuppressive properties. (A) In contrast to unmanipulated D2 mice, 6-mo-old D2 mice reconstituted with B6D2F1 marrow (B6D2F1→D2) have a normal capacity to induce ACAID (compare with Fig. 2). Mean ear swelling responses \pm SEM (five mice per group) are presented. *, values significantly lower than positive controls ($P < 0.05$, Student's *t* test). (B) Similar to unmanipulated D2 mice, 6-mo-old D2 mice reconstituted with B6D2F1 marrow also contain AqH lacking immunosuppressive properties (compare with Fig. 1). T cells were added to medium containing 20% AqH, stimulated with anti-CD3 antibodies for 48 h, and assayed for [³H]thymidine incorporation. Values are mean cpm \pm SEM of three to six wells.

tion. Thus, low levels of clinically detectable, liberated pigment persist in the eyes of the bone marrow chimeras. Despite the low level of liberated pigment, these chimeras are rescued with respect to: (a) integrity of the blood/ocular barrier, (b) leukocyte infiltration into the AqH, and (c) ability to induce ACAID. This argues that the suppressible immune ocular abnormalities detectable early in the disease are not secondary to pigment dispersion.

The results of our radiation bone marrow chimera experiments establish a causal relationship between the documented immune and inflammatory factors and the pathogenesis of pigment dispersion in D2 mice. Irradiated D2 mice reconstituted with B6D2F1 bone marrow cells failed to develop the full range and severity of pigment dispersion characteristic of unmanipulated D2 mice or irradiated D2 mice reconstituted with D2 bone marrow. D2 mice reconstituted with B6D2F1 marrow showed significantly less pigment dispersion, iris transillumination, and peripupillary swelling. Bone marrow contains progenitors of the immune system that can account for the correction of the immune abnormalities in the bone marrow chimeras. There is no evidence that bone marrow-derived lineages could directly rescue an inherent defect in pigmented cells of the iris. Therefore, the prominent rescue of iris disease observed in D2 recipients of B6D2F1 bone marrow indicates that some component(s) of the suppressible immune ocular abnormalities is directly pathogenic. Given the documented expression of *Gpnmb* in some types of dendritic

cells (14, 15) and the dependency of ACAID on cells positive for F4/80 (predominantly dendritic cells and macrophages; 17, 30–32), we hypothesize that the prominent pigment dispersion rescued here by bone marrow reconstitution might be a consequence of lack of GPNMB function in D2 dendritic cells that have the *Gpnmb*^{R150X} mutation. Future experiments will directly test this hypothesis.

There are also components of the D2 ocular disease that appear to be insensitive to the genotype of bone marrow-derived lineages. First, the D2 mice reconstituted with B6D2F1 bone marrow maintained a degree of transillumination and iris atrophy indicative of the iris stromal atrophy phenotype that is caused by mutation of *Tyrp1*. In contrast to GPNMB, TYRP1 is thought to be melanocyte specific (10, 33) and has not been documented in bone marrow-derived lineages of the immune system. Second, the AqH of D2 mice reconstituted with B6D2F1 bone marrow remained incapable of suppressing T cell activation in vitro. This may result from either the small percentage of residual parental D2 bone marrow-derived cells in these mice, or may reflect the consequence of a nonbone marrow-derived ocular cell type that remains mutant in the eyes of these chimeras (possibly iris pigment epithelial cells that normally secrete factors that inhibit T cell proliferation). In either case, the rescue of the IPD phenotype despite the continued inability of AqH to suppress T cell proliferation indicates that this inability is not sufficient to induce the prominent pigment dispersion associated with IPD.

The factors causing human PDS and conspiring to determine whether or not it progresses to elevated IOP and PG are unknown. The pigment dispersion phenotype in D2 mice involves melanosomes, the specialized organelles of melanin pigment production containing both TYRP1 and GPNMB. Our previous studies suggest that mutations in *Tyrp1* and *Gpnmb* allow cytotoxic by-products of melanin synthesis to leave melanosomes in abnormally high quantities, resulting in melanocyte insult, cell injury, depigmentation, and iris atrophy (8, 9). Importantly, the current studies clearly demonstrate that the genotype of bone marrow-derived cells determines the level of pigment dispersion associated with these melanosomal insults in otherwise identical eyes. Thus, multiple hits can synergize to either cause or exacerbate the severity of the prominent pigment dispersion phenotype, IPD. One hit arises from a melanocyte insult predisposing toward pigment release, which in D2 mice results from a genetically determined melanosomal defect. Another hit arises from the immune system and determines the overall level of depigmentation and course of progression. Our finding that enlargement of the AC was curtailed in D2 mice reconstituted with B6D2F1 bone marrow further suggests that multiple hits are necessary for progression of the disease to PG.

Synergistic interactions between melanosomal defects and the immune system may also contribute to iris pigment dispersion in human PDS and may explain the complex pattern of occurrence in many families. Roles of melanosome-derived insults, immune abnormalities, and bone marrow-derived cells in human PDS are not defined. Ul-

trastructurally, abnormal melanosomes are present in the iris of some human PDS patients (34, 35). Similar melanosome abnormalities exist in D2 mice as young as 5 d after birth and are present in the iris (36 and unpublished data). This suggests that melanosomal disturbances might be involved in both the human and mouse diseases. Importantly, the form of inflammation observed in D2 eyes is mild, lacking redness and severe inflammation. If present in human PDS, a similarly mild inflammatory response might be subclinical on routine examination. Pigment-laden macrophages are present in the eyes of some human PDS/PG patients (35, 37, 38). Our current studies suggest that these cells and other bone marrow-derived lineages should not be excluded as active participants in the disease.

In conclusion, we present evidence for immune aberrations and sustained, mild inflammation in eyes of D2 mice and propose that a similar, and previously unsuspected, set of abnormalities may occur in human PDS/PG. PG is a relatively early onset and difficult to treat form of glaucoma. Our studies suggest that developing treatments to decrease the amount of dispersed pigment and/or reduce inflammatory responses might be beneficial as new therapies to prevent progression to glaucoma.

We thank M. Ortega and A. Snow for animal care; M. Pierce for technical assistance with bone marrow reconstitution; T. Duffy of The Jackson Laboratory Flow Cytometry Service for assistance with FACS[®] analysis; D. Roopenian for helpful discussions and J. Smith for assistance in preparing the manuscript. Managerial and laboratory support from Dr. J. Doherty is greatly appreciated. CT26.WT cells were provided by N.P. Restifo (National Institutes of Health [NIH], Bethesda, MD) and DBA/2-derived T lymphoma L5178Y-R tumor cells transfected with CD95L were provided by A. Marshak-Rothstein (Boston University, Boston, MA).

Some of this work was supported by NIH grant EY 05678 and a grant from The Glaucoma Foundation (both to J.W. Streilein). Scientific support services at The Jackson Laboratory are funded by a grant from the National Cancer Institute. S.W.M. John is an Associate Investigator of The Howard Hughes Medical Institute.

Submitted: 25 November 2002

Revised: 26 March 2003

Accepted: 3 April 2003

References

- Ritch, R., D. Steinberger, and J.M. Liebmann. 1993. Prevalence of pigment dispersion syndrome in a population undergoing glaucoma screening. *Am. J. Ophthalmol.* 115:707–710.
- Richter, C.U., T.M. Richardson, and W.M. Grant. 1986. Pigmentary dispersion syndrome and pigmentary glaucoma. A prospective study of the natural history. *Arch. Ophthalmol.* 104:211–215.
- Migliazzo, C.V., R.N. Shaffer, R. Nykin, and S. Magee. 1986. Long-term analysis of pigmentary dispersion syndrome and pigmentary glaucoma. *Ophthalmology.* 93:1528–1536.
- Farrar, S.M., M.B. Shields, K.N. Miller, and C.M. Stoup. 1989. Risk factors for the development and severity of glaucoma in the pigment dispersion syndrome. *Am. J. Ophthalmol.* 108:223–229.
- Campbell, D.G., and R.M. Schertzer. 1996. Pigmentary glaucoma. In *The Glaucomas*. R. Ritch, M.B. Shields, and T. Krupin, editors. Mosby, St. Louis. 975–991.
- Andersen, J.S., A.M. Pralea, E.A. DelBono, J.L. Haines, M.B. Gorin, J.S. Schuman, C.G. Mattox, and J.L. Wiggs. 1997. A gene responsible for the pigment dispersion syndrome maps to chromosome 7q35–q36. *Arch. Ophthalmol.* 115:384–388.
- John, S.W.M., R.S. Smith, O.V. Savinova, N.L. Hawes, B. Chang, D. Turnbull, M. Davisson, T.H. Roderick, and J.R. Heckenlively. 1998. Essential iris atrophy, pigment dispersion, and glaucoma in DBA/2J mice. *Invest. Ophthalmol. Vis. Sci.* 39:951–962.
- Chang, B., R.S. Smith, N.L. Hawes, M.G. Anderson, A. Zabaleta, O. Savinova, T.H. Roderick, J.R. Heckenlively, M.T. Davisson, and S.W.M. John. 1999. Interacting loci cause severe iris atrophy and glaucoma in DBA/2J mice. *Nat. Genet.* 21:405–409.
- Anderson, M.G., R.S. Smith, N.L. Hawes, A. Zabaleta, B. Chang, J.L. Wiggs, and S.W.M. John. 2002. Mutations in genes encoding melanosomal proteins cause pigmentary glaucoma in DBA/2J mice. *Nat. Genet.* 30:81–85.
- Sturm, R.A., R.D. Teasdale, and N.F. Box. 2001. Human pigmentation genes: identification, structure and consequences of polymorphic variation. *Gene.* 277:49–62.
- Turque, N., F. Denhez, P. Martin, N. Planque, M. Bailly, A. Begue, D. Stehelin, and S. Saule. 1996. Characterization of a new melanocyte-specific gene (QNR-71) expressed in v-myc-transformed quail neuroretina. *EMBO J.* 15:3338–3350.
- Le Borgne, R., N. Planque, P. Martin, F. Dewitte, S. Saule, and B. Hoflack. 2001. The AP-3-dependent targeting of the melanosomal glycoprotein QNR-71 requires a di-leucine-based sorting signal. *J. Cell Sci.* 114:2831–2841.
- John, S.W.M., M.G. Anderson, and R.S. Smith. 1999. Mouse genetics: a tool to help unlock the mechanisms of glaucoma. *J. Glaucoma.* 8:400–412.
- Ahn, J.H., Y. Lee, C. Jeon, S.J. Lee, B.H. Lee, K.D. Choi, and Y.S. Bae. 2002. Identification of the genes differentially expressed in human dendritic cell subsets by cDNA subtraction and microarray analysis. *Blood.* 100:1742–1754.
- Shikano, S., M. Bonkobara, P.K. Zukas, and K. Ariizumi. 2001. Molecular cloning of a dendritic cell-associated transmembrane protein, DC-HIL, that promotes RGD-dependent adhesion of endothelial cells through recognition of heparan sulfate proteoglycans. *J. Biol. Chem.* 276:8125–8134.
- Banchereau, J., and R.M. Steinman. 1998. Dendritic cells and the control of immunity. *Nature.* 392:245–252.
- McMenamin, P.G., J. Crewe, S. Morrison, and P.G. Holt. 1994. Immunomorphologic studies of macrophages and MHC class II-positive dendritic cells in the iris and ciliary body of the rat, mouse, and human eye. *Invest. Ophthalmol. Vis. Sci.* 35:3234–3250.
- Bora, N.S., M.D. Woon, M.T. Tandhasetti, T.P. Cirrito, and H.J. Kaplan. 1997. Induction of experimental autoimmune anterior uveitis by a self-antigen: melanin complex without adjuvant. *Invest. Ophthalmol. Vis. Sci.* 38:2171–2175.
- Yamaki, K., K. Gocho, K. Hayakawa, I. Kondo, and S. Sakuragi. 2000. Tyrosinase family proteins are antigens specific to Vogt-Koyanagi-Harada disease. *J. Immunol.* 165:7323–7329.
- Kaya, M., D.P. Edward, H. Tessler, and R.L. Hendricks. 1992. Augmentation of intraocular inflammation by melanin. *Invest. Ophthalmol. Vis. Sci.* 33:522–531.
- Mo, J.S., and J.W. Streilein. 2001. Immune privilege persists

in eyes with extreme inflammation induced by intravitreal LPS. *Eur. J. Immunol.* 31:3806–3815.

22. Hawes, N.L., R.S. Smith, B. Chang, M. Davisson, J.R. Heckenlively, and S.W.M. John. 1999. Mouse fundus photography and angiography: a catalogue of normal and mutant phenotypes. *Mol. Vis.* 5:22.
23. Kaiser, C.J., B.R. Ksander, and J.W. Streilein. 1989. Inhibition of lymphocyte proliferation by aqueous humor. *Reg. Immunol.* 2:42–49.
24. Streilein, J.W. 1996. Ocular immune privilege and the Faustian dilemma. The Proctor lecture. *Invest. Ophthalmol. Vis. Sci.* 37:1940–1950.
25. Chen, J.J., Y. Sun, and G.J. Nabel. 1998. Regulation of the proinflammatory effects of Fas ligand (CD95L). *Science.* 282:1714–1717.
26. Gregory, M.S., A.C. Repp, A.M. Hohlbaum, R.R. Saff, A. Marshak-Rothstein, and B.R. Ksander. 2002. Membrane Fas ligand activates innate immunity and terminates ocular immune privilege. *J. Immunol.* 169:2727–2735.
27. Niederkorn, J., J.W. Streilein, and J.A. Shaddock. 1981. Deviant immune responses to allogeneic tumors injected intracamerally and subcutaneously in mice. *Invest. Ophthalmol. Vis. Sci.* 20:355–363.
28. Overwijk, W.W., and N.P. Restifo. 2000. Autoimmunity and the immunotherapy of cancer: targeting the “self” to destroy the “other.” *Crit. Rev. Immunol.* 20:433–450.
29. Vijayasradhi, S., and A.N. Houghton. 1991. Purification of an autoantigenic 75-kDa human melanosomal glycoprotein. *Int. J. Cancer.* 47:298–303.
30. Wilbanks, G.A., and J.W. Streilein. 1991. Studies on the induction of anterior chamber-associated immune deviation (ACAID). 1. Evidence that an antigen-specific, ACAID-inducing, cell-associated signal exists in the peripheral blood. *J. Immunol.* 146:2610–2617.
31. Williamson, J.S., D. Bradley, and J.W. Streilein. 1989. Immunoregulatory properties of bone marrow-derived cells in the iris and ciliary body. *Immunology.* 67:96–102.
32. Austyn, J.M., D.F. Hankins, C.P. Larsen, P.J. Morris, A.S. Rao, and J.A. Roake. 1994. Isolation and characterization of dendritic cells from mouse heart and kidney. *J. Immunol.* 152:2401–2410.
33. Thomson, T.M., F.X. Real, S. Murakami, C. Cordon-Cardo, L.J. Old, and A.N. Houghton. 1988. Differentiation antigens of melanocytes and melanoma: analysis of melanosome and cell surface markers of human pigmented cells with monoclonal antibodies. *J. Invest. Dermatol.* 90:459–466.
34. Rodrigues, M.M., G.L. Spaeth, S. Weinreb, and E. Sivalingam. 1976. Spectrum of trabecular pigmentation in open-angle glaucoma: a clinicopathologic study. *Trans. Am. Acad. Ophthalmol. Otolaryngol.* 81:258–276.
35. Kampik, A., W.R. Green, H.A. Quigley, and L.H. Pierce. 1981. Scanning and transmission electron microscopic studies of two cases of pigment dispersion syndrome. *Am. J. Ophthalmol.* 91:573–587.
36. Rittenhouse, E. 1968. Genetic effect on fine structure and development of pigment granules in mouse hair bulb melanocytes. I. The b and d loci. *Dev. Biol.* 17:351–365.
37. Alvarado, J.A., and C.G. Murphy. 1992. Outflow obstruction in pigmentary and primary open angle glaucoma. *Arch. Ophthalmol.* 110:1769–1778.
38. Fine, B.S., M. Yanoff, and H.G. Scheie. 1974. Pigmentary “glaucoma.” A histologic study. *Trans. Am. Acad. Ophthalmol. Otolaryngol.* 78:OP314–OP325.