

Spontaneous resolution of ruptured dissecting anterior inferior cerebellar artery aneurysm: A rare case report

Sumeet Singh, R. S. Mittal, Devendra Purohit, Jetendra Shekhawat

Department of Neurosurgery, SMS Medical College, Jaipur, Rajasthan, India

ABSTRACT

Dissecting anterior inferior cerebellar artery (AICA) aneurysms are extremely rare, and only nine cases are reported till date. We are reporting a case of ruptured dissecting distal AICA aneurysm with spontaneous resolution; first of its kind in the indexed literature.

Key words: Conservative, dissecting anterior inferior cerebellar artery aneurysm, spontaneous resolution

Introduction

Dissecting aneurysm of the distal anterior inferior cerebellar artery (AICA) is extremely rare with an incidence of 0.03-0.5% of all intracranial aneurysms.^[1] Congenital fragility may be involved in aneurysm formation.^[2] The treatment modalities available are trapping or endovascular occlusion of AICA. We are reporting a case of 52-year-old woman with spontaneous resolution of distal dissecting AICA aneurysm after 8 weeks of conservative management.

Case Report

A 52-year-old woman presented with a history of sudden onset of severe headache and vomiting with a negative history of loss of consciousness and seizure. On examination, she had neck stiffness with blood pressure of 190/110 without any cranial nerve deficit. On computed tomography (CT) brain there was a blood in perimesencehalic cisterns [Figure 1]. CT angiography was normal, but digital subtraction angiography showed distal right AICA fusiform aneurysm involving the whole circumference of the vessel wall with late stagnation of contrast inside the aneurysm, suggestive of dissection

etiology [Figure 2]. She was offered the available modalities of treating dissecting AICA aneurysms, but she denied any intervention. Hence, patient was given the nimodipine - 60 mg 4 times a day, antihypertensives, antiepileptics and analgesics, patient was discharged after 12 days of conservative management with advice of complete bed rest and regular follow-up. Follow-up digital subtraction angiography (DSA) after 8 weeks, showed complete resolution of dissecting AICA aneurysm [Figure 3]. Patient is asymptomatic even 3 months after the ictus.

Discussion

Anterior inferior cerebellar artery aneurysms are an extremely rare pathology and have been reported in only 2 of 6368 aneurysms by Locksley^[3] and in only 34 AICA aneurysms (1.3%) of >3500 saccular aneurysms by Gonzalez *et al.*^[4] Most aneurysms arise from the proximal segment of the AICA and rarely from the distal one. The former can be treated by clip ligation at the neck, and the latter may be trapped or occluded surgically or endovascularly.^[4]

Dissecting aneurysms of the AICA can present as subarachnoid hemorrhage (SAH), when the plane of dissection is between media and adventitia and occlusion of the vessel, and occlusion of the vessel if plane of dissection is between elastic lamina and media.^[5] However, a SAH presentation is more common and was observed in 88% of patients with intracranial dissections in the posterior circulation.^[6] More intensive investigation, when facing SAH in posterior circulation, is required especially DSA in which features of dissection are well described.^[7,8] Surgical treatment of dissecting cerebellar arteries is considered to be difficult and associated with high morbidity and mortality. However, in some patients, adequate collateral circulation prevents infarction in the territory of the occluded vessel.^[9] The best way to test the safety of

Access this article online	
Quick Response Code:	Website: www.asianjns.org
	DOI: 10.4103/1793-5482.145561

Address for correspondence:

Dr. Sumeet Singh, Department of Neurosurgery, SMS Medical College, Jaipur - 302 004, Rajasthan, India.
E-mail: drsumeetneurosurgery@yahoo.in

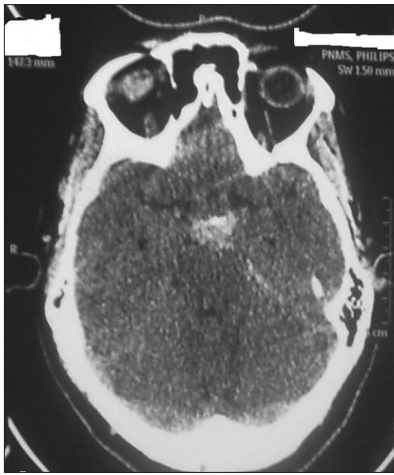


Figure 1: Computed tomography scan plane showing blood in mesencephalic cisterns

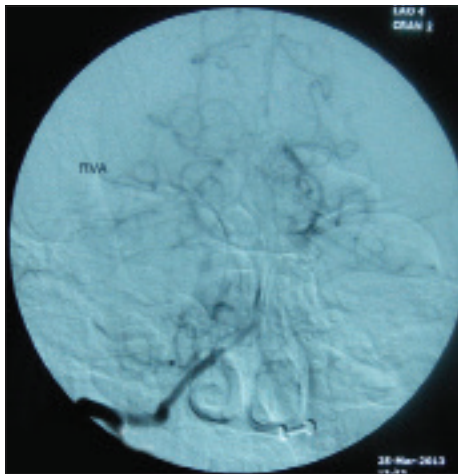


Figure 2: Digital subtraction angiography showing dissecting anterior inferior cerebellar artery aneurysm in the late phase of DSA

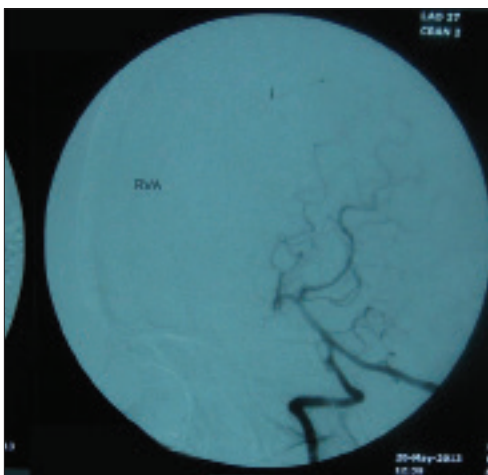


Figure 3: Digital subtraction angiography showing resolution of dissecting anterior inferior cerebellar artery aneurysm

parent vessel occlusion is to perform a temporary balloon test occlusion, but this is impossible to perform in the distal AICA

because the artery is too small. Therefore, the risk of parent vessel occlusion in this location is difficult to predict. If the posterior inferior cerebellar artery (PICA) is unusually small and the AICA is large, the collateral circulation is likely to be poor, creating an unfavorable and dangerous situation in the event of an AICA occlusion.^[10] Matsuyama *et al.*^[11] reported single case with good results of a ruptured dissecting AICA aneurysm treated with endovascular embolization. They stated that no ischemic complications occurred after the sacrifice of the distal AICA because of sufficient collateral circulation from the ipsilateral superior cerebellar artery (SCA) or PICA. Nishimoto *et al.*, Suzuki *et al.*, Yokoyama *et al.* recommend Occipital artery (OA) anastomosis followed by trapping or endovascular occlusion.^[12-14] Takeuchi *et al.* reported a case of dissecting AICA aneurysm in which they perform trapping.^[15] Eckard *et al.* described one case of AICA aneurysm in which the occlusion of the parent vessel was obtained with low complication rates.^[16] Andrade *et al.* treated 3 cases of dissecting AICA with endovascular occlusion.^[17] Kusaka *et al.* reported a single case of dissecting AICA aneurysm which was treated by endovascular occlusion.^[18]

Occipital artery-AICA bypass may be performed to prevent ischemic complications before the sacrifice of the AICA. This strategy represents an alternative if there is insufficient collateral circulation into the AICA. Fukushima *et al.* reported a case of the right distal AICA dissecting aneurysm with hypoplasia of the right PICA. The endovascular approach was selected for a parent artery occlusion.^[19]

In our case, patient had dissecting AICA aneurysm, and she was without any neurological deficit. She was explained about trapping as well as endovascular occlusion as a method of treatment and the associated risks. She was apprehensive and denied surgery as well as endovascular treatment modality and was discharged on conservative treatment. DSA was performed after 8 weeks of the ictus, and there was complete resolution of the dissecting AICA aneurysm.

Conclusion

Dissecting AICA aneurysm is very rare, and little information is available regarding its management. Surgery has high morbidity and mortality because of surrounding vital structures. Serious complications after AICA occlusion are rare as the cortical branch may receive collateral flow from SCA or PICA or leptomeningeal anastomosis. We feel even with conservative management, these aneurysm may heal themselves with time as in our case. Hence, we advise wait and watch policy before any intervention, if clinical status of the patient permits with close follow up and DSA.

References

1. Ikeda N, Tamura Y, Aoki A, Kuroiwa T, Sakaguchi I. Ruptures aneurysm of the anterior inferior cerebellar artery – Internal auditory

- junction: A case report. No Shinkei Geka J 2003 12:31-33, 003. [JPN, with Eng abstract].
2. Fujiwara K, Ito J, Kanayama S. Multiple aneurysms of the PICA communicating artery: A case report. No Shinkei Geka 1999;27:177-82.
 3. Locksley HB. Natural history of subarachnoid hemorrhage, intracranial aneurysms and arteriovenous malformations. Based on 6368 cases in the cooperative study. J Neurosurg 1966;25:219-39.
 4. Gonzalez LF, Alexander MJ, McDougall CG, Spetzler RF. Anteroinferior cerebellar artery aneurysms: Surgical approaches and outcomes – A review of 34 cases. Neurosurgery 2004;55:1025-35.
 5. Endo S, Nishijima M, Nomura H, Takaku A, Okada E. A pathological study of intracranial posterior circulation dissecting aneurysms with subarachnoid hemorrhage: Report of three autopsied cases and review of the literature. Neurosurgery 1993;33:732-8.
 6. Yamaura A, Watanabe Y, Saeki N. Dissecting aneurysms of the intracranial vertebral artery. J Neurosurg 1990;72:183-8.
 7. Hancock JH, Millar JS. Spontaneous dissection of the anterior inferior cerebellar artery. Neuroradiology 2000;42:535-8.
 8. Anxionnat R, de Melo Neto JF, Bracard S, Lacour JC, Pinelli C, Civit T, *et al.* Treatment of hemorrhagic intracranial dissections. Neurosurgery 2003;53:289-300.
 9. Peluso JP, van Rooij WJ, Sluzewski M, Beute GN. Distal aneurysms of cerebellar arteries: Incidence, clinical presentation, and outcome of endovascular parent vessel occlusion. AJNR Am J Neuroradiol 2007;28:1573-8.
 10. Rhoton AL Jr. The cerebellar arteries. Neurosurgery 2000;47:S29-68.
 11. Matsuyama T, Okuchi K, Norimoto K, Ueyama T. Ruptured dissecting anterior inferior cerebellar artery aneurysm – Case report. Neurol Med Chir (Tokyo) 2002;42:214-6.
 12. Suzuki K, Meguro K, Wada M, Fujita K, Nose T. Embolization of a ruptured aneurysm of the distal anterior inferior cerebellar artery: Case report and review of the literature. Surg Neurol 1999;51:509-12.
 13. Nishimoto A, Fujimoto S, Tsuchimoto S, Matsumoto Y, Tabuchi K, Higashi T. Anterior inferior cerebellar artery aneurysm. Report of three cases. J Neurosurg 1983;59:697-702.
 14. Yokoyama S, Kadota K, Asakura T, Kawazoe K. Aneurysm of the distal anterior inferior cerebellar artery – Case report. Neurol Med Chir (Tokyo) 1995;35:587-90.
 15. Takeuchi S, Takasato Y, Masaoka H, Hayakawa T, Otani N, Yoshino Y, *et al.* Trapping of ruptured dissecting aneurysm of distal anterior inferior cerebellar artery – Case report. Brain Nerve 2009;61:203-7.
 16. Eckard DA, O'Boynick PL, McPherson CM, Eckard VR, Han P, Arnold P, *et al.* Coil occlusion of the parent artery for treatment of symptomatic peripheral intracranial aneurysms. AJNR Am J Neuroradiol 2000;21:137-42.
 17. Andrade G, Faquini I, Azevedo-Filho H, Laércio J, Câmara D, Mendes JC, *et al.* Dissecting anterior inferior cerebellar artery aneurysm treated by endovascular route: Report of three cases and review. Arq Neuropsiquiatr 2010;68:645-7.
 18. Kusaka N, Maruo T, Nishiguchi M, Takayama K, Maeda Y, Ogihara K, *et al.* Embolization for aneurysmal dilatation associated with ruptured dissecting anterior inferior cerebellar artery aneurysm with preservation of the parent artery: Case report. No Shinkei Geka 2006;34:729-34.
 19. Fukushima S, Hirohata M, Okamoto Y, Yamashita S, Ishida S, Shigemori M. Anterior inferior cerebellar artery dissecting aneurysm in a juvenile: Case report. Neurol Med Chir (Tokyo) 2009;49:81-4.

How to cite this article: Singh S, Mittal RS, Purohit D, Shekhawat J. Spontaneous resolution of ruptured dissecting anterior inferior cerebellar artery aneurysm: A rare case report. Asian J Neurosurg 2017;12:570-2.

Source of Support: Nil, **Conflict of Interest:** None declared.