

# Orbital Exenteration and Brachytherapy for the Treatment of Pediatric, Fusion-positive, Recurrent Rhabdomyosarcoma

Joseph Lopez, MD, MBA\*  
 Nancy Qin, BA\*  
 Robbie Woods, MD\*  
 Marjorie Golden, MFA, CDT†  
 Harrison Spatz, DMD, MS†  
 Jatin Shah, MD\*  
 Leonard H. Wexler, MD‡  
 Joseph Randazzo, DDS†  
 Suzanne L. Wolden, MD§  
 David H. Abramson, MD¶

**Summary:** A 20-month-old boy presented with biopsy-proven recurrent alveolar rhabdomyosarcoma without metastasis. He was previously treated with multiagent chemotherapy and external beam irradiation showing a complete response. Upon relapse, he was treated with chemotherapy, orbital exenteration, and brachytherapy. Customized, intraoperative brachytherapy has potential to limit the sequelae associated with radiation adjuvant therapy. (*Plast Reconstr Surg Glob Open* 2022;10:e4581; doi: 10.1097/GOX.0000000000004581; Published online 7 October 2022.)

## INTRODUCTION

In children, rhabdomyosarcoma (RMS) accounts for approximately 50% of soft tissue malignancies.<sup>1</sup> This equates to approximately five cases per million children in the United States. The most common site of RMS is the head and neck regions (35%), with orbital RMS accounting for 10%.<sup>1,2</sup> Although surgery was the standard of care until 1979, improved survival with retention of the eye became possible with the introduction of multiagent systemic chemotherapy and localized, orbital radiation.<sup>3</sup> Today, the mainstay of treatment for primary orbital RMS remains systemic chemotherapy followed by external beam radiotherapy (EBRT).<sup>4</sup> With this approach, localized RMS is considered curable in children with overall survival exceeding 90%.<sup>4</sup> However, there are several studies highlighting pretreatment prognostic factors; infancy, unresectable disease, alveolar-subtype, fusion-positive status, and metastatic disease are associated with worse outcomes.<sup>5</sup>

Despite advancements made, approximately one-third of patients with localized RMS and two-thirds of patients

with metastatic RMS experience recurrence within 3 years.<sup>6</sup> Recurrences in the orbit are difficult to treat. Local excision is rarely possible, and orbital exenteration usually fails. Similarly, repeat radiation is problematic because of potential toxicity to the brain; chemotherapy is not curative. In cases where surgical resection is insufficient, studies have shown that brachytherapy can be effective and limits the sequelae of EBRT.<sup>1,2</sup> Brachytherapy is defined as the use of high radiation dosage within the tumor site, while sparing exposure to surrounding anatomy. We report a case of recurrent RMS of the orbit in a 20-month-old boy who underwent a combined surgical and brachytherapy treatment regimen.

## MATERIALS AND METHODS

### Clinical History

A 20-month-old boy with biopsy-proven recurrent, FOXO1-fusion positive RMS was referred for further treatment. He previously presented at 4 months of age with RMS and was immediately treated with 50.4 GyE proton radiotherapy (RT) while partaking in a 35-week phase III randomized controlled clinical trial, Children's Oncology Group (COG) D9803 Regimen A (vincristine, actinomycin D, and cyclophosphamide) chemotherapy. The patient showed a complete response, but surveillance imaging at 5 months posttreatment revealed infield local recurrence with no evidence of metastasis (Fig. 1).

### Management

Within a week after recurrence, treatment commenced off trial with COG AEWS0031 Regimen B (vincristine,

From the \*Department of Surgery, Head and Neck Service, Memorial Sloan Kettering Cancer Center, New York, N.Y.; †Department of Surgery, Dental Service, Memorial Sloan Kettering Cancer Center, New York, N.Y.; ‡Department of Pediatrics, Memorial Sloan Kettering Cancer Center, New York, N.Y.; §Department of Radiation Oncology, Memorial Sloan Kettering Cancer Center, New York, N.Y.; and ¶Department of Surgery, Ophthalmic Oncology Service, Memorial Sloan Kettering Cancer Center, New York, N.Y.

Received for publication June 6, 2022; accepted August 17, 2022.

Copyright © 2022 The Authors. Published by Wolters Kluwer Health, Inc. on behalf of The American Society of Plastic Surgeons. This is an open-access article distributed under the terms of the Creative Commons Attribution-Non Commercial-No Derivatives License 4.0 (CCBY-NC-ND), where it is permissible to download and share the work provided it is properly cited. The work cannot be changed in any way or used commercially without permission from the journal.

DOI: 10.1097/GOX.0000000000004581

**Disclosure:** The authors have no financial interest to declare in relation to the content of this article.

Related Digital Media are available in the full-text version of the article on [www.PRSGlobalOpen.com](http://www.PRSGlobalOpen.com).

doxorubicin, cytoxan, ifosfamide, and etoposide with topotecan) for six cycles followed by right orbital exenteration and custom orbital brachytherapy. A noneyelid-sparing orbital exenteration was performed after the first cycle of chemotherapy using a standard approach. Immediately after completion of the orbital exenteration, the medial orbital skeleton was covered with Steri-Strips to mark the tumor location and cover the created lamina propria defect (Fig. 2).

Next, polyvinylsiloxane material (Affinis, Coltène/Whaledent Inc., Cuyahoga Falls, Ohio) was injected into the orbital defect to create a customized impression. The impression was then fashioned to create a clear polymethylmethacrylate (PMMA) implant (Lucitone Clear, DENTSPLY Prosthetics, York, Pa.). (See figure, Supplemental Digital Content 1, which displays the processed clear PMMA mold, <http://links.lww.com/PRSGO/C188>.) The PMMA implant was loaded with 18 catheters within 2 mm of the surface containing 73 I-125 model 6711 seeds with 275 units total air kerma strength activity (Fig. 3). One week after, the implant was placed into the orbit, delivering 5000 cGy to the tumor site and high-risk region and 3600 cGy to the low risk-region to a depth of 3 mm (Fig. 4). This was repeated twice daily for a total of six sessions. The patient's postoperative and post-RT course was uncomplicated. Postoperatively, he completed off trial, 12 cycles of COG ARST0921 Regimen B (vinorelbine tartrate, cyclophosphamide, and temsirolimus). The patient has no evidence of local or systemic recurrence with his last follow-up being 6 months after treatment.

## DISCUSSION

For more than 40 years, combinations of multiagent systemic chemotherapy and radiation have led to a high (>90%) chance of cure in cases of orbital RMS.<sup>4</sup> Multiple studies have refined the best drugs and radiation dose/techniques.<sup>3,7</sup> Unfortunately, when the tumor recurs in the orbit, there are few alternatives. Most patients develop metastatic disease and eventually die.

In 1990, we introduced surgery combined with brachytherapy as a novel and improved alternative, since

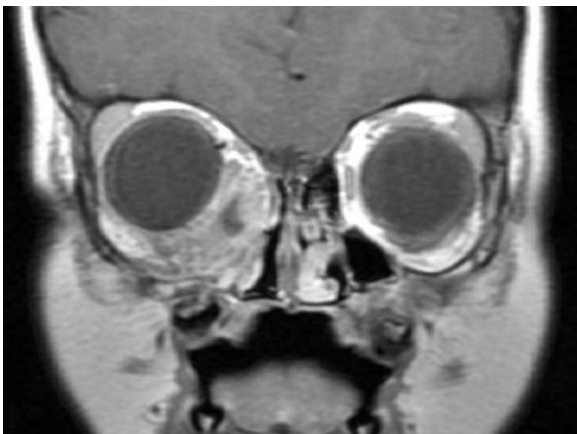


Fig. 1. Pretreatment magnetic resonance imaging; coronal scan.

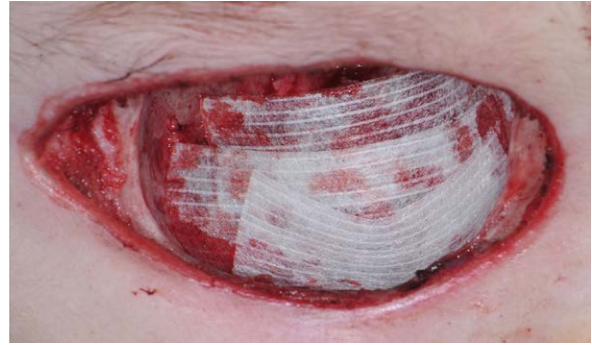

Fig. 2. Steri-Strips lined to cover the lamina propria defect.

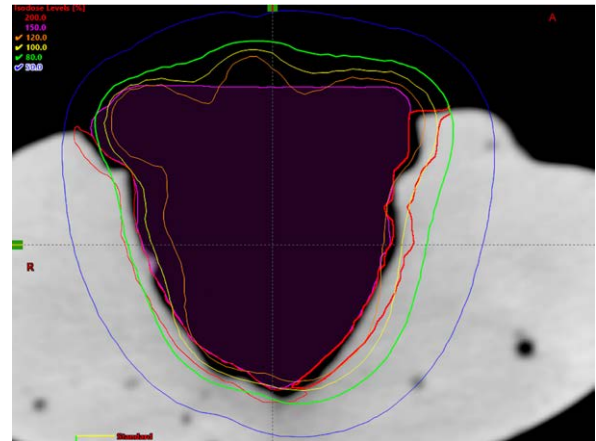
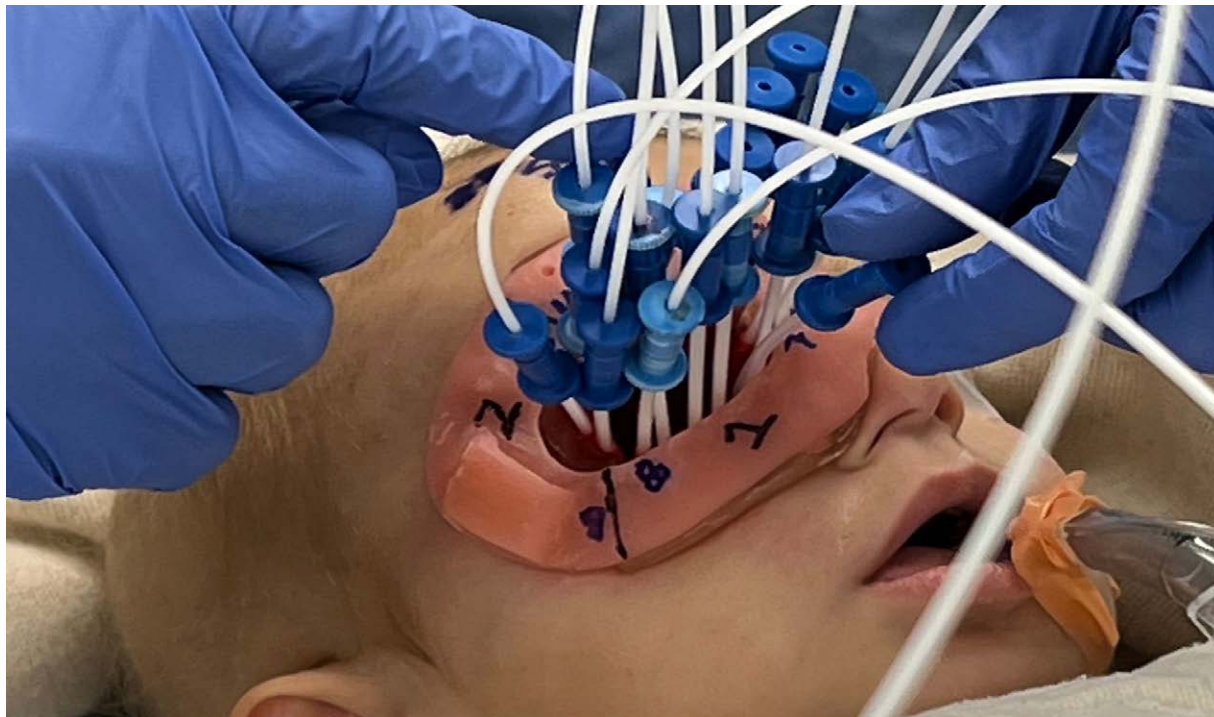


Fig. 3. Customized dosimetry plan.

surgery alone was repeatedly shown to be disappointing. Brachytherapy delivers a high dose of radiation to the remaining microscopic disease without radiating the nearby brain. In a 10-year study conducted by Schoot et al,<sup>8</sup> brachytherapy combined with ablative surgery was associated with both fewer and less severe adverse events compared to that from EBRT, while yielding comparable overall survival for head and neck RMS. We have previously reported on this approach in recurrent embryonal RMS and recurrent soft tissue Ewings sarcoma of the orbit, but the approach has not been done for recurrent FOXO1 fusion-positive RMSs.<sup>7</sup>

Steri-Strips lined with Mastisol were used in this case to “bridge” periorbital defects created during orbital exenteration. This technique has previously been described by Menick<sup>9</sup> for the creation of defect molds used in nasal subunit reconstruction. This technique not only prevents leakage of mold material into the sinuses but also allows for precise anatomic recreation of the periorbital skeleton by using a semirigid construct.

Brachytherapy has been used either with 125I (low-dose RT) seeds or iridium (high-dose RT). In this case, the overhanging edge of the orbit required us to design a multisectional implant brachytherapy device to allow for multiple paths of insertion while creating an index to reorient the separate pieces and prevent movement during treatment. By having separate sections, each section could sit flush against the defect area, facilitating precise



**Fig. 4.** Insertion of custom brachytherapy implant into orbit with 18 catheters in position.

implant placement and treatment execution. This design also helps mitigate the concern for slight movement during radiation treatment. Despite these benefits, intraoperative brachytherapy continues to be limited by cost, need for specialty training, and operating room time requirements. Furthermore, brachytherapy prolongs inpatient stays and requires long-term postoperative wound care, as the device is inserted into an open wound. Further refinements in technique are necessary to alleviate these concerns in the future.

### SUMMARY

A 20-month-old boy presented with recurrent alveolar RMS without metastasis. He relapsed 5 months after being treated with multiagent chemotherapy and EBRT. Subsequently, he was treated with chemotherapy, orbital exenteration, and brachytherapy. This is the first report on the use of multisectional customized orbital implant-based brachytherapy for recurrent fusion-positive RMS.

*Joseph Lopez, MD, MBA*

Department of Surgery, Head and Neck Service  
Memorial Sloan Kettering Cancer Center  
1275 York Ave  
New York, NY 10065  
E-mail: josephlopezmdmba@gmail.com

### REFERENCES

1. Drew A, Abramson DH, Wolden SL, et al. Fabrication of a custom brachytherapy appliance. *J Prosthet Dent.* 2019;121:535–537.
2. Schoot RA, Saeed P, Freling NJ, et al; Amsterdam Head and Neck Working Group on Childhood Tumors. Local resection and brachytherapy for primary orbital rhabdomyosarcoma: outcome and failure pattern analysis. *Ophthalmic Plast Reconstr Surg.* 2016;32:354–360.
3. Abramson DH, Ellsworth RM, Tretter P, et al. The treatment of orbital rhabdomyosarcoma with irradiation and chemotherapy. *Ophthalmology.* 1979;86:1330–1335.
4. Chen C, Dorado Garcia H, Scheer M, et al. Current and future treatment strategies for rhabdomyosarcoma. *Front Oncol.* 2019;9:1458.
5. Pappo AS, Anderson JR, Crist WM, et al. Survival after relapse in children and adolescents with rhabdomyosarcoma: a report from the Intergroup Rhabdomyosarcoma Study Group. *J Clin Oncol.* 1999;17:3487–3493.
6. Heske CM, Mascarenhas L. Relapsed rhabdomyosarcoma. *J Clin Med.* 2021;10:804.
7. Klufas MA, Wolden SL, Bohle GC III, et al. Exenteration and custom implant brachytherapy as a treatment for recurrent primary extraskelatal orbital ewing sarcoma. *Ophthalmic Plast Reconstr Surg.* 2015;31:e89–e91.
8. Schoot RA, Slater O, Ronckers CM, et al. Adverse events of local treatment in long-term head and neck rhabdomyosarcoma survivors after external beam radiotherapy or AMORE treatment. *Eur J Cancer.* 2015;51:1424–1434.
9. Menick FJ. Aesthetic and reconstructive rhinoplasty: a continuum. *J Plast Reconstr Aesthet Surg.* 2012;65:1169–1174.