

A Case Report of Homocystinuria With Dystonia and Stroke

Arezoo Rezazadeh, MD¹, Shahram Oveisgharan, MD²,
Gholamali Shahidi, MD³, and Reza Naghdi, MD⁴

Abstract

Inherited homocystinuria is a rare autosomal recessive aminoacidopathy which through early diagnosis can prevent its severe neurologic and vascular complications. Here we report a 9-year-old girl with homocystinuria, presenting with sequential symptoms of bilateral lens dislocation, skeletal complication, and eventually dystonia from the age of 4 years. Laboratory evaluation revealed severe high serum homocysteine level. Although pathophysiologically unexplained, evidence of deep white matter watershed infarct along with remarkable ipsilateral carotid stenosis was detected on the contralateral side of the dystonia in the neuroimaging. Treatment with high dose of pyridoxine relieved limb and gait dystonia significantly, while carotid stenosis remained unchanged. Therefore, homocysteine might have both structural and irreversible effect and functional and reversible impact that could be overcome even in late stages.

Keywords

homocysteine, movement disorder, cerebrovascular disease

Inherited homocystinuria is a rare autosomal recessive metabolic disorder affecting several organs including nervous system through toxic effect of homocysteine (Hcy). Here, we present a referred patient with dystonia who was found to have occult stroke on further evaluation.

Case summary

A 9-year-old girl presented with right-hand dystonia and gait difficulty. She developed the symptom around the age of 7. When she was 4 years old, she experienced blurred vision and was operated for lens dislocation 3 years later. Last year, she had a history of severe low back pain. Earlier she had experienced right femur fracture.

There was a family history of undiagnosed progressive motor disability in her older brother, which finally resulted in seizure and death. Her parents had consanguineous marriage.

On physical examination, she had fair and wooly hair and mild fixed oromandibular dystonia presenting as fixed smiling. On chest examination, pectus carinatum was evident. There was no eye deviation in primary position. All types of horizontal and vertical eye movements were preserved. At rest, she had dystonic posture in her limbs on both sides, with more severity on the right side. Attempted movements of the right hand worsened the abnormal postures. There was mild motor deficit on

the right side. Deep tendon reflexes were prominent on right side as well. She was unable to stand unsupported. While aiding in walking her dystonic gait was revealed.

Her blood cell count, liver function test, thyroid function test, calcium, serum ceruloplasmin, 24-hour urine copper, and serum B12 were within the normal range. Serum homocysteine was measured as 200 nmol/mL.

Her brain magnetic resonance imaging (MRI) revealed deep watershed infarct in left centrum semiovale (Figure 1). Basal ganglia were normal. Previous MRI of lumbosacral vertebrae was suggestive of severe degenerative changes (Figure 2).

Carotid Doppler sonography demonstrated left carotid narrowing without evidence of thrombosis. Carotid intima-media thickness (IMT) was within normal range on both sides. The patient was treated with high dose of oral pyridoxine (360 mg daily) and put on

¹ Department of Neurology, Valiasr Hospital, Khoramshahr, Iran

² Department of Neurology, Tehran University of Medical Sciences, Shariati Hospital, Tehran, Iran

³ Department of Neurology, Iran University of Medical Sciences, Rasool-Akram Hospital, Tehran, Iran

⁴ Department of Internal Medicine, Valiasr Hospital, Khoramshahr, Iran

Corresponding Author:

Arezoo Rezazadeh, Valiasr Hospital, Sazman-e-Ab St., Khoramshahr, Iran.
Email: a.rezazadeh0057@gmail.com

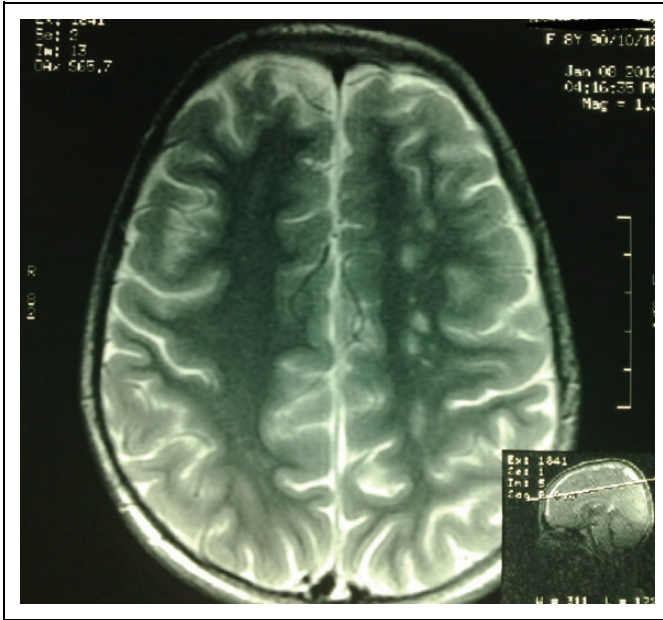


Figure 1. Deep watershed infarct in left central semiovale.

methionine-restricted diet. She was followed up monthly for clinical evaluation and response to treatment. She attained the ability of standing and walking without help. She showed a remarkable recovery from her limb dystonia, although nothing was completely normal. After 3 months and 9 months of treatment, serum Hcy decreased to 40 nmol/mL and 26.5 nmol/mL, respectively. The second carotid Doppler did not show any change.

Discussion

“Homocystinuria is the second most common treatable aminoacidopathy” after phenylketonuria.¹ Homocysteine, an intermediate metabolite of methionine catabolism, can be removed in 2 ways. Cystathionine β -synthase (CBS) is an enzyme that catalyzes Hcy irreversibly by the means of B6 as the cofactor. This is called transsulfuration.^{2,3}

In the second way, methionine is rebuilt through remethylation, by means of either methylenetetrahydrofolate reductase or methionine synthase. In the first pathway, Hcy is converted into methionine in the presence of coenzyme, methylcobalamine. Folic acid is the substrate in this reaction.^{2,3}

Mutation in the encoding gene of each of these enzymes can result in homocystinuria. The most common genetic disorder is CBS deficiency (homocystinuria type I).⁴ The reported worldwide incidence of this rare autosomal recessive disorder is between 1 in 50 000 and 1 in 200 000.⁵

The clinical manifestation of CBS deficiency is diversely heterogeneous; however, 4 organs are dominantly affected, namely “central nervous system, eye, skeletal, and vascular system.”⁶ These patients are often normal at birth. Homocystinuria, due to CBS deficiency, usually manifests itself as ocular lens subluxation, which results in severe myopia and iridodonesis. In a large number of patients, ectopic lentis occurs by the age of 8 years.^{4,7}

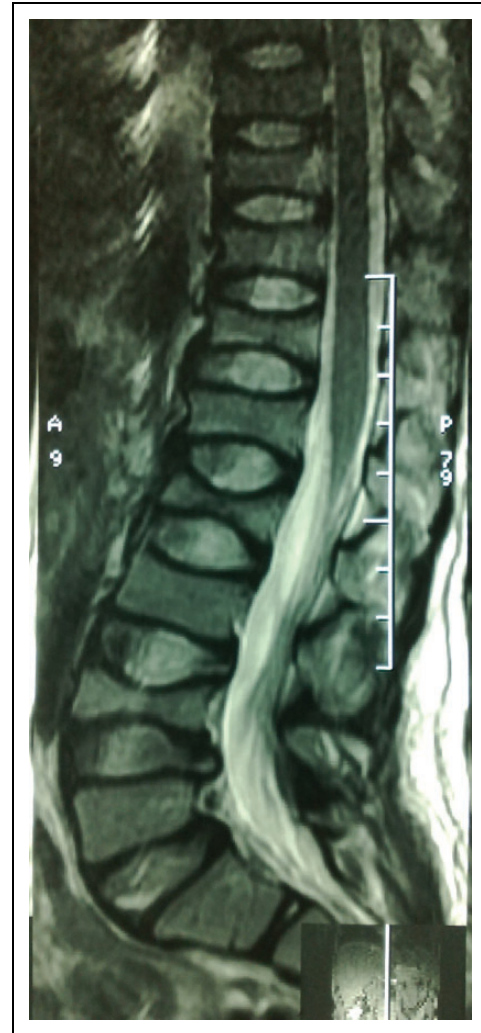

Figure 2. Degenerative changes in lumbosacral vertebrae.

Skeletal abnormalities in homocystinuria are a common manifestation similar to what is seen in Marfan syndrome. These abnormalities consist of fair woolly hairs, blue eyes, livedo reticularis, limitation of joint mobility, scoliosis, high-arched palate, pes cavus, pectus excavatum or pectus carinatum, and genu valgum and osteoporosis, especially of vertebrae and long bones.⁷

Central nervous system involvement includes progressive mental retardation, seizure, dystonia, behavioral and personality disorder, and stroke due to thromboembolic syndromes.^{4,8} Premature vascular events are the major causes of early death and morbidity.⁷

Vascular injury is proposed to be due to “endothelial dysfunction, smooth muscle proliferation, extracellular matrix modification, lipoprotein oxidation, and increased thrombin production.”⁹

Endothelial dysfunction is the result of nitric oxide release impairment, thereby disturbing vasodilation and facilitating platelet aggregation.¹⁰ Although it had been mentioned in earlier studies that hyperhomocysteinemia provokes intima hypertrophy and resultant increased intima-media thickness,¹¹ some of the recent observation have failed to show this correlation.¹²

Similarly, in this case, no evidence of increased intima-media thickness was detected on carotid Doppler; nevertheless, significant narrowing of internal carotid artery was observed unilaterally. This is in consistent with 2 studies that claimed the plasma level of Hcy was higher in carotid artery stenosis,^{13,14} although in the latter, the serum Hcy level was not correlated with pulsatility index in the stenoocclusive state of the proximal internal carotid.

Correlation between Hcy and dystonia has been shown in several studies; Muller et al demonstrated that the serum Hcy was significantly higher in primary dystonia than in control.¹⁵ While some believe that dystonia is due to microinfarct in the basal ganglia,¹⁶ others assume that neurotoxic effect of Hcy can be responsible for developing dystonia.¹⁷ In this case, the brain MRI did not reveal any abnormality in basal ganglia, however, having experienced deep white mater infarct would have predisposed this patient to manifest dystonia more vigorously. Furthermore, remarkable response of dystonia to high dose of pyridoxine might be suggestive of some reversible effect of Hcy, while lowering Hcy did not alter arterial stenosis.

Treatment

Early diagnosis and treatment of homocystinuria might prevent ectopic lentis and other serious complication including thrombotic events.¹⁸ Since in half of the patients with homocystinuria 1% to 5% of CBS activity is normal, high dose of pyridoxine (B6) with a dosage of 200 mg/d, can ameliorate clinical and laboratory signs significantly.¹⁹

Even in cases with certain CBS gene mutation and nonresponsive to B6, high dose of B6 administration (500-1000 mg daily) is recommended.^{7,8} In addition to methionine restriction, betaine is the second treatment that lowers plasma Hcy through Hcy remethylation.⁷ Finally, folate and cobalamine are other adjunctive treatments that help reducing serum Hcy concentration.⁸

Regarding the normal range of plasma Hcy concentration between 5 and 15 nmol/mL, it is recommended that maintaining the Hcy concentration to less than 11 nmol/mL will show the best result especially to those being treated “shortly after birth.”⁸

Author Contribution

Arezoo Rezazadeh contributed to patient diagnosis and follow-up, writing draft. Shahram Oveisgharan contributed to article review and draft edit. Gholamali Shahidi contributed to draft edit and treatment consultant. Reza Naghdi contributed to patient care.

Authors' Note

Informed consent was obtained from her parents.

Declaration of Conflicting Interests

The authors declared no potential conflicts of interest with respect to the research, authorship, and/or publication of this article.

Funding

The authors received no financial support for the research, authorship, and/or publication of this article.

References

1. Yap S. Classical homocystinuria: vascular risk and its prevention [Abstract]. *J Inherit Metab Dis*. 2003;26(2-3):259-265.
2. Fonseca N, Vidal N, Santos J, et al. Hyperhomocysteinemia-case report. *Rev Port Cardiol*. 2003;22(2):223-230.
3. Finkelstein JD, Martin JJ. Methionine metabolism in mammals. Adaptation to methionine excess. *J Biol Chem*. 1986;261(4):1582-1587.
4. Bhardwaj P, Sharma R, Sharma M. Homocystinuria: a rare condition presenting as stroke and megaloblastic anemia. *J Pediatr Neurosci*. 2010;5(2):129-131.
5. E-Medicine: Homocystinuria/Homocystinemia. Web site. <http://emedicine.medscape.com/article/1952251-overview#aw2aab6b4>. updated June 12, 2013. Accessed May 16, 2014.
6. Milosević-Tosić M, Borota J, Katanić D, Vlaski J. A case report of pyridoxine-responsive homocystinuria [Abstract]. *Med Pregl*. 1999;52(11-12):501-504.
7. Picker JD, Levy HL. *Homocystinuria Caused by Cystathionine Beta-Synthase Deficiency*. GeneReviews. Pagon RA, Adam MP, Ardinger HH, et al, eds. Seattle, WA: University of Washington; 1993-2014 (Last Update: 2011).
8. Rao TN, Radhakrishna K, Mohana Rao TS, Guruprasad P, Ahmed K. Homocystinuria due to cystathionine beta synthase deficiency. *Indian J Dermatol Venereol Leprol*. 2008;74(4):375-378.
9. Bellamy MF, McDowell IFW. Putative mechanisms for vascular damage by homocysteine. *J Inher Metab Dis*. 1996;20(2):307-331.
10. Doshi SN, Goodfellow J, Lewis MJ, McDowell IF. Homocysteine and endothelial function. *Cardiovasc Res*. 1999;42(3):578-582.
11. Megnien JL, Garipey J, Saudubray JM, et al. Evidence of carotid artery wall hypertrophy in homozygous homocystinuria. *Circulation*. 1998;98(21):2276-2281.
12. Ntaios G, Savopoulos C, Hatzitolios A, et al. Homocysteine and carotid intima-media thickness in ischemic stroke patients are not correlated. *Neuropsychiatr Dis Treat*. 2008;4(2):477-479.
13. Wang GH, Wang YJ, He Y, Jiang WJ, Du B, Jin M. Correlation between plasma level of homocysteine and cerebral large-artery atherosclerosis. [Abstract]. *Zhonghua Nei Ke Za Zhi*. 2006;45(9):744-747.
14. Lim MH, Cho YI, Jeong SK. Homocysteine and pulsatility index of cerebral arteries. *Stroke*. 2009;40(10):3216-3220.
15. Muller UJ, Frick B, Winkler C, et al. Homocysteine and serum markers of immune activation in primary dystonia. [Abstract]. *Mov Disord*. 2005;20(12):1663-1667.
16. Davous P, Rondot P. Homocystinuria and dystonia. *J Neurol Neurosurg Psychiatry*. 1983;46(3):283-286.
17. Müller T, Voitalla D, Hunsdiek A, Kuhn W. Elevated plasma levels of homocysteine in dystonia. [Abstract]. *Acta Neurol Scand*. 2000;101(6):388-390.
18. Yap S, Naughten E. Homocystinuria due to cystathionine R-synthase deficiency in Ireland: 25 years' experience of a newborn screened and treated population with reference to clinical outcome and biochemical control. *J Inherited Metab Dis*. 1998;21(7):738-747.
19. Mudd SH, Skovby F, Levey HL, et al. A revisit to the natural history of homocystinuria due to cystathionine B-synthase deficiency. *Am J Hum Genet*. 1985;37(1):1-31.