

Effect of intravenous administration of zoledronic acid on jaw bone density in cases having skeletal metastasis: A prospective clinical study

Veena Jain, Ashu Seith¹, Smita Manchanda¹, Rajath Pillai, DN Sharma², Vijay Prakash Mathur

Department of Prosthodontics, Center for Dental Education and Research, All India Institute of Medical Sciences,

¹Department of Radio-Diagnosis, All India Institute of Medical Sciences, ²Department of Radiation Oncology, B. R. Ambedkar Institute Rotary Cancer Hospital, All India Institute of Medical Sciences, New Delhi, India

Abstract

Aim: The objective is to evaluate the effect of intravenous (i.v.) administration of bisphosphonate (zoledronic acid) therapy on the jaw bone density and incidence of any other bony patholog.

Settings and Design: Observational – prospective study.

Materials and Methods: A total of 57 patients having a history of bony metastasis (excluding the jaw bone) were enrolled following the inclusion/exclusion criteria. Each patient received six doses of 4 mg i.v. bisphosphonate once a month. Multidetector computed tomography (MDCT) of jawbones for each patient was performed before the start of therapy (baseline) and subsequently at 6 and 12 months. Bone density was assessed at 24 predetermined sites (8 sites in maxilla and 16 sites in mandible) and any pathological change in either of the jaw bones was noted.

Statistical Analysis Used: Shapiro–Wilk test, Pearson's Chisquare test and repeated measures analysis of variance.

Results: The result showed no statistically significant increase in mean bone density over a period of 1 year in maxilla and mandible. However, a significant increase in bone density was observed from 6 months to 1 year in mandibular anterior cancellous bone. The detailed observation of each MDCT scan showed no pathological change in either of the jaw bones during the study period.

Conclusion: The administration (i.v.) of six doses of 4 mg bisphosphonate did not lead to a significant change in bone density over a period of 1 year.

Keywords: Bisphosphonates, bone density, jaw bone necrosis, metastasis

Address for correspondence: Dr. Veena Jain, Department of Prosthodontics, Center for Dental Education and Research, All India Institute of Medical Sciences, New Delhi - 110 029, India.

E-mail: jainveena1@gmail.com

Received: 19th November, 2018, **Accepted:** 28th June, 2019

INTRODUCTION


Bisphosphonates are commonly used to treat metabolic diseases such as osteoporosis, Paget's disease, hypercalcemia

of malignancy, and skeletal complications due to bone metastasis in malignancies.^[1] They are extensively used to attenuate the occurrence of skeletal complications

This is an open access journal, and articles are distributed under the terms of the Creative Commons Attribution-NonCommercial-ShareAlike 4.0 License, which allows others to remix, tweak, and build upon the work non-commercially, as long as appropriate credit is given and the new creations are licensed under the identical terms.

For reprints contact: reprints@medknow.com

How to cite this article: Jain V, Seith A, Manchanda S, Pillai R, Sharma DN, Mathur VP. Effect of intravenous administration of zoledronic acid on jaw bone density in cases having skeletal metastasis: A prospective clinical study. J Indian Prosthodont Soc 2019;19:203-9.

Access this article online	
Quick Response Code:	Website: www.j-ips.org
	DOI: 10.4103/jips.jips_368_18

(bone pain and pathologic fracture) in patients with bone metastases. Bisphosphonates work by inhibiting the bone resorption. Their nuclear structure has two phosphate group joined by a single carbon atom.^[2] Bisphosphonates are either nitrogen containing or nonnitrogen containing, cyclic or noncyclic^[3] and can be administered through two modes: intravenously (i.v.) or orally. Bioavailability is higher with i.v. administration more than 50% of the administered drug is bioactive reaches the target organ, and hence, potency of the drug is increased. While bioavailability with oral administration is less only 1% of the dose is absorbed by the gastrointestinal tract.^[4,5]

The mechanism of action of bisphosphonates occurs by two ways either by their affinity for bone mineral resulting in selective uptake to the target organ and achieving high local concentration in bone, or by inhibiting the osteoclast differentiation, reducing the osteoclast activity, and inducing osteoclast apoptosis,^[6-8] thereby resulting in concomitant increases in bone density. Nitrogen-containing bisphosphonates are more potent and accumulate in maximum concentration in the matrix and osteoclasts. They function by interrupting the mevalonic acid pathway, thereby inhibiting the synthesis of a key enzyme, i.e., farnesyl pyrophosphate synthase, which prevents the production of proteins essential for osteoclast survival and function.^[7] The concomitant increase in bone density may result in increased risk of the development of osteonecrosis of jaw (ONJ), as the constant microtrauma from jaw movement and lack of adequate remodeling in the presence of bisphosphonate may contribute to the genesis of ONJ. The risk of developing ONJ increases in a case who has been taking the drug for longer period, especially those on i.v. bisphosphonates.^[9]

Zoledronic acid is the most potent nitrogen-containing, third-generation, and cyclic bisphosphonate, that have an enormous significance in reducing skeletal-related complications in bone metastases from carcinoma of other parts of the body.^[10-13] Several studies have reported increase in bone density after i.v. zoledronic acid therapy,^[13-17] but many of these studies were on long bones and vertebrae. In addition to this, certain studies have reported that i.v. zoledronic acid therapy is commonly associated with ONJ, but several other factors were also responsible for ONJ other than zoledronic acid, i.e., dose, duration of treatment, oral health, and timing of surgical procedures in the patient under bisphosphonate therapy.^[18-26] Furthermore, most of these studies were of a retrospective design. Furthermore, there are limited prospective studies on the effect of i.v. zoledronic acid therapy on the quality of the jaw bones and incidence of ONJ.

Thus, this prospective study was planned and executed to evaluate the effect of i.v. zoledronic acid on quality of jaw bones and incidence of jaw bone necrosis at 6 months and 12 months after the start of therapy in patients with skeletal metastasis (excluding the jaw bones) using the multiple detector computed tomography (MDCT).

SUBJECTS AND METHODS

The study was conducted in accordance with the Declaration of Helsinki II and was approved by the Institutional Ethical Committee (No.IEC/NP-260/20127RP-33/2012). Patients with skeletal metastasis, who were registered in the medical and uro-oncology department for bisphosphonate therapy, were screened according to the inclusion/exclusion criteria. A total of 57 patients in the age range of 30–55 years, irrespective of the gender having bony metastasis (not involving the jawbone), secondary to carcinoma in other parts of the body were enrolled in the study after taking the informed consent. The exclusion criteria were: patients having progressive disease, metastasis in jaw bone, cancer in head and neck region, extraskelatal metastasis or having a history of radiotherapy in head and neck region, with deranged kidney function test, were excluded along with patients who developed progressive/terminal disease during the study.

After the routine consultation, all the enrolled individuals were requested to report to the research staff for a thorough clinical dental examination. Informed consent was obtained from all individuals included in the study. The individuals were informed about the project verbally, and they were handed over with the subject information sheet, and any queries they had regarding the project was answered. Once satisfied, their written informed consent was obtained. During interview and examination, if it was found that the individuals had a dental health-care need, they were offered treatment at the dental center. The required dental treatment was instituted accordingly, such as oral prophylaxis, extraction of root stumps, and any tooth with hopeless prognosis and restoration or root canal treatment of carious or carious exposed teeth.

Before administering the bisphosphonate to the participants, each participant underwent general blood, kidney function, and liver function tests. If the entire test showed values in permissible limits, participants were admitted to the daycare and 4 mg i.v. zoledronic acid was administered by a nurse in the medical oncology department under the supervision of a medical oncologist. Each patient received six doses of 4 mg i.v. zoledronic acid once a month at each recall visit. If any subject showed deranged values in any of the recall visits, administration of bisphosphonate was either

delayed or discontinued, and further decision was made by the medical oncologist. MDCT of jawbones for each patient was performed before the start of therapy (to get the baseline values), and subsequently 6 and 12 months after the start of therapy. All the MDCTs were taken on one computed tomography (CT) machine by a single operator. Bone density was measured at eight points (standardized locations based on anatomical landmarks) in the maxillary and at 16 points (eight points in cancellous bone and eight points in cortical bone) in mandibular bones [Figure 1]. Bone density values were filled in a predesigned form. These MDCT scans were also evaluated for any other change in bone, such as any signs of bone necrosis or any other morphological changes. All these MDCT scans were evaluated by a single experienced radiologist.

However, of these 57 patients, 30 patients were not able to complete the study as 26 patients either passed away due to their medical condition or were lost to follow-up. In four patients, the administration of zoledronic acid was extended to 12 months, hence excluded. Therefore, only 27 patients were able to complete the study.

Statistical Software for Social Sciences, Version 13.1 (IBM, Chicago, IL, USA) was used to analyze the data. Frequency distributions were produced, and the means, standard deviation, and confidence interval of the dependent variables were estimated and compared within the study population. Shapiro–Wilk test was used to assess the normality of data. Pearson’s Chi-square test and repeated measures analysis of variance were used to test for correlation and analyze the data over time, respectively. $P < 0.05$ was considered as statistically significant.

RESULTS

The present data represent only 26 patients who were able to complete the monthly scheduled dose of bisphosphonate for 6 months.

Before starting the analysis, the distribution or normality of the data was checked, for that Shapiro–Wilk test was applied along with the Q-Q plots show that the data are normally distributed for the baseline and at 1st time point as the significant value of the Shapiro–Wilk test was >0.05 . The data were slightly skewed in the final time point. Considering this and the sample size, it was decided to apply parametric tests (this applies to maxilla and mandible data).

In maxilla, the posterior area was studied at points, i.e., 18y-16y, 28y-26y, and anterior at points 14y-12y,

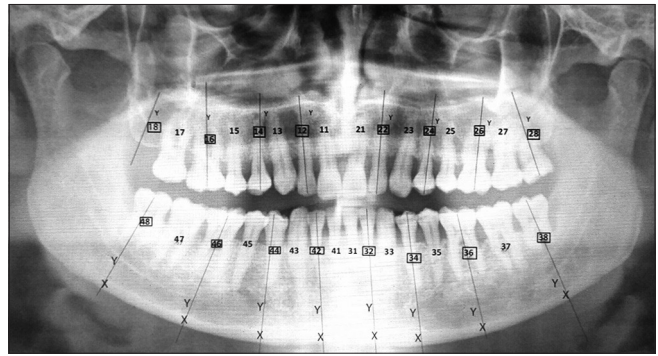


Figure 1: Anatomical location template to measure bone density for maxilla and mandible

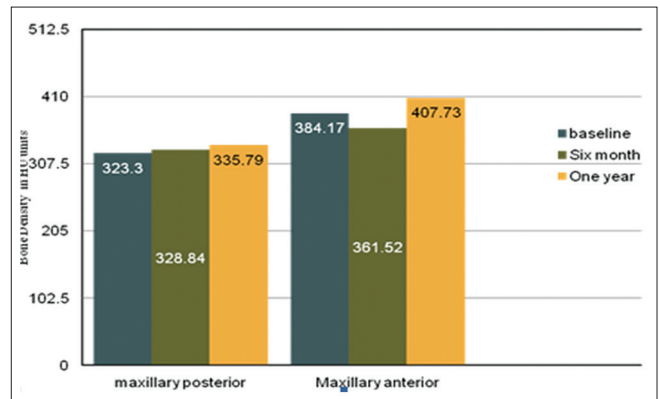


Figure 2: Bone density in Hounsfield units units at different time intervals in maxilla

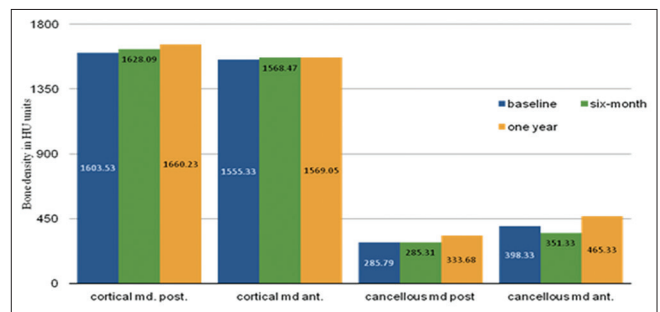


Figure 3: Bone density (Hounsfield units units) at different time intervals in cortical and cancellous mandible

22y-24y [Figure 1]. Pearson’s correlation for the baseline values did not show any significant difference, and the values were in coherence. Hence, it was decided to combine certain data points segmentally. Therefore, 18y-16y was combined (mean) to maxillary right posterior, 14y-12y was combined to maxillary right anterior, 22y-24y was combined as maxillary left anterior, and 26y-28y was combined as maxillary left posterior, to maintain homogeneity of the data.

Similar to maxillary data, mandibular data for cancellous (at points – 38y-36y, 48y-46y, 34y-32y,

42y-44y) and cortical bone (at points – 38x-36x, 48x-46x, 34x-32x, 42x-44x) were statistically evaluated on similar parameter and it was decided to combine the different points to represent that as single mandibular posterior value and mandibular anterior value for both cancellous and cortical bone.

Descriptive analysis showed mean bone density increases with time in both maxilla and mandible in anterior and posterior region. When assessing the changes in bone quality over the three-time points, repeated measures of ANOVA was applied. The Mauchly's test of sphericity assumption failed, and therefore, the Greenhouse-Geisser test shows that there was no significant difference in the bone quality over a period of 1 year (same results when comparing baseline to 6 months, etc.) for both the jaws, except cancellous bone in the mandibular anterior region, showed significant increase in bone density between 6 and 12 months [Tables 1-3 and Figures 2 and 3].

Furthermore, since the overall comparison showed a significant difference in bone density for cancellous bone in mandibular anterior region, pairwise comparisons were made using the Bonferroni adjustment. It was seen that the

mean difference for bone density was statistically significant between 6 months and 1 year, but the rest of the differences were statistically not significant [Table 4]. Further detailed observation of each cone beam CT (CBCT) scan by a radiologist did not show any pathological change in any of the patient.

DISCUSSION

In this study to measure the effect of zoledronic acid on jaw bone density was measured using MDCT. Different imaging techniques have been used to evaluate changes in quality of bone after systemic therapy in patients of skeletal metastases such as dual-energy X-ray absorptiometry (DXA), bone scans, and quantitative CT.^[27-29] Although the MDCT method used in our study lacks in providing an absolute measure of density values, these are feasible to use for assessing jaw bones as compared to DXA, bone scans, and quantitative CT. Furthermore, they are also widely available, but DEXA scan requires a separate probe to measure the jaw bone density. CBCT is commonly used to check the bone volume as well as bone density in cases require implants for rehabilitation, but previous studies show CBCT is not validated to measure the bone density alone.^[30-34]

The result of this study suggests that there was no statistically significant difference in the quality of bone over time in maxillary anterior and posterior bone and the mandibular cortical bone, although a mean bone density increase was seen in the respective jaw and region of bone after 1 year. Similarly, there was no statistically significant difference in quality of the mandibular posterior cancellous bone over time. However, there was a significant difference between the bone densities from 6 months to 1 year in mandibular anterior cancellous bone.

Table 1: Bone density in the anterior and posterior maxilla over 1 year

Region	Time point	Bone density (HU unit), mean±SD (95% CI)	Significance
Maxillary posterior	Baseline	323.30±186.23 (248.08-398.52)	0.899
	6 months	328.84±173.10 (258.92-398.76)	
	1 year	335.79±197.29 (256.11-415.48)	
Maxillary anterior	Baseline	384.17±172.42 (314.52-453.81)	0.269
	6 months	361.52±167.21 (293.98-429.06)	
	1 year	407.73±177.67 (335.96-479.49)	

SD: Standard deviation, CI: Confidence interval

Table 2: Bone density in the anterior and posterior mandibular cortical bone over 1 year

Region	Time point	Bone density in HU unit, mean±SD (95% CI)	Significance
Cortical mandibular posterior	Baseline	1603.53±92.18 (1566.30-1640.77)	0.126
	6 months	1628.09±81.98 (1594.98-1661.21)	
	1 year	1660.23±162.20 (1594.71-1725.74)	
Cortical mandibular anterior	Baseline	1555.33±73.96 (1525.46-1585.21)	0.676
	6 months	1568.47±81.52 (1535.54-1601.40)	
	1 year	1569.05±112.29 (1523.70-1614.41)	

SD: Standard deviation, CI: Confidence interval

Table 3: Bone density in the anterior and posterior mandibular cancellous bone over 1 year

Region	Time point	Bone density in HU unit, mean±SD (95% CI)	Significance
Cancellous mandibular posterior	Baseline	285.79±168.59 (217.70-353.89)	0.207
	6 months	285.31±165.54 (218.45-352.18)	
	1 year	333.68±156.31 (270.54-396.81)	
Cancellous mandibular anterior	Baseline	398.33±188.42 (322.22-474.44)	0.009
	6 months	351.33±144.16 (293.10-409.56)	
	1 year	465.33±188.44 (389.22-541.44)	

SD: Standard deviation, CI: Confidence interval

Table 4: Pairwise comparison of change in cancellous bone density in the anterior mandibular region at different time points

Time point	Versus time point	P
Baseline	6 months	0.290
	1 year	0.345
6 months	Baseline	0.290
	1 year	0.002
1 year	Baseline	0.345
	6 months	0.002

The conclusive finding of this study suggests that i.v. administration of zoledronic acid increases the mean bone density of both maxillary bone and mandibular cortical and posterior cancellous bone over time. These findings may be due to either the accumulation of zoledronic acid in the osseous matrix or in osteoclasts, which may have resulted in inhibition of osteoclastic activity through a cascade of the pathway.^[6,7,35-37] This decreased osteoclastic activity might have resulted in inhibition of normal bone resorption, consequently causing reduced bone turnover, increased mean bone density, and decreased incidence of skeletal-related events. However, the bisphosphonate significantly increased the bone density in mandibular anterior cancellous bone over time. This significant increase in bone density of mandibular anterior cancellous bone may be due to jawbone specific over suppression of bone turnover. Van den Wyngaert *et al.* have shown that the mandible exhibited a lower bone remodeling rate than the maxilla after bisphosphonate therapy.^[36] Despite this, certain other studies are inconsistent and opposite to the findings as observed in previous study.^[27,37] Considering these reports in mind, the alternative reason for significant increase in mandibular anterior cancellous bone density may be either due to antiangiogenic effect of zoledronic acid through the inhibition of vascular endothelial growth factor resulting in decreased blood flow ultimately affecting bone remodeling or due to more mineral per bone volume in anterior mandibular cancellous bone adsorbing more bisphosphonate in the region.^[38-40]

This study replicates the findings of a prospective analysis of the quality of bone using CT after i.v. 15 min infusion of 4 mg Zoledronic acid conducted by Quattrocchi *et al.*^[14] Although the treatment was given for a maximum of 12 months, their study evaluated the effect of zoledronic acid on bone density of iliac and sacral region over a period of 2 years as compared to 1 year in this study (with zoledronic acid administered for 6 months). In addition, they found a significant increase in bone density over time. Certain other studies have also reported bone density increase after i.v. zoledronic acid therapy, but they have reported it in long bones and vertebrae.^[13,15-17]

Nevertheless, as mentioned by Quattrocchi *et al.*,^[14] there are chances that the bone density increase may be due to therapy (e.g., hormonal or cytotoxic) that the patient is already taking during the treatment of carcinoma. The pharmacological interaction of the above-mentioned therapy with zoledronic acid may also have a role in increasing the bone density. However, within the range of our study, we cannot rule out with the assurance of this collateral direct effect. Furthermore, to the best of our knowledge, there are no present reported data on the effect of hormonal or cytotoxic drugs on bone density at metastatic sites in the literature. Therefore, the above-mentioned drug interaction and their relation to bone density increase are mere speculations. Thus, the mean bone density increase can be related to the absolute effect of zoledronic acid in our patients.^[14]

Regarding the incidence of bone necrosis or any other pathology, no relevant clinical symptom and radiological finding was seen in our study, although previous studies have reported the association of necrosis of jawbone and i.v. zoledronic acid treatment.^[18-26] Most of these studies were retrospective. The diagnosis of necrosis was only made after clinical sign, and symptoms were noted. A retrospective study by Ruggiero *et al.*^[20] even reported that most of the necrosis affected patient had dental disease that was missed by oncologist before starting the therapy. The contrary result in our study could be due to the reason that before starting bisphosphonate therapy, all patients needing any dental treatment underwent the required treatment accordingly, such as oral prophylaxis, extraction of root stumps and any tooth with hopeless prognosis and restoration or root canal treatment of carious or carious exposed teeth. However, literatures show that nonextraction cases may also report necrosis of jaw bone, which is again contradictory to our results.^[22] Another reason may be that the median duration of zoledronic exposure and necrosis risk is approximately 2 years or more, as mentioned in previous studies.^[18,19,23-25] Ryan *et al.* in their report, do not report necrosis of jaw bone in 1-year period after 4 mg i.v. infusion of zoledronic acid every 3 months for 1 year.^[17] Hence, as a whole, it can be concluded that the length of exposure, dose, poor oral health, and previous dental extraction plays a significant role in the development of ONJ.^[20,21,24,26]

The clinical significance of the finding is that the dentist should consider the above-mentioned effect of zoledronic acid on jaw bone while planning of dental implant placement and performing any surgical dental procedures.^[41,42] The medical community, especially medical oncologists, should be aware of the consequences of

bisphosphonate therapy on jawbones and should refer the patients to dentists before starting the bisphosphonate therapy. The dentist should perform a thorough dental evaluation to rule out any dental pathology, the presence of which should be managed beforehand.

The main limitation of this study was a shorter observation period because patients enrolled in this study had carcinoma with bony metastasis not involving the jaw bone; such patients do not have long-term survival.

CONCLUSION

The administration (i.v.) of six doses of 4 mg zoledronic acid did not lead to a significant change in bone density over a period of 1 year in the maxillary and mandibular bones. No adverse skeletal event was noted over the 1-year period.

Acknowledgment

We would like to acknowledge the Indian Council of Medical Research for providing financial support to conduct this study. We also acknowledge to Dr. Punit Kumar Singh, senior resident, Department of Prosthodontics, CDER, AIIMS for the timely help.

Financial support and sponsorship

This study was supported by the Indian Council of Medical Research for providing financial support to conduct this study.

Conflicts of interest

There are no conflicts of interest.

REFERENCES

- Montoya-Carralero JM, Parra-Mino P, Ramírez-Fernández P, Morata-Murcia IM, Mompeán-Gambín Mdel C, Calvo-Guirado JL, *et al.* Dental implants in patients treated with oral bisphosphonates: A bibliographic review. *Med Oral Patol Oral Cir Bucal* 2010;15:e65-9.
- Serra MP, Llorca CS, Donat FJ. Oral implants in patients receiving bisphosphonates: A review and update. *Med Oral Patol Oral Cir Bucal* 2008;13:E755-60.
- Shima K, Tsuchiya M, Oizumi T, Takano-Yamamoto T, Sugawara S, Endo Y. Inflammatory effects of nitrogen-containing bisphosphonates (N-BPs): Modulation by non-N-BPs. *Biol Pharm Bull* 2017;40:25-33.
- Ezra A, Golomb G. Administration routes and delivery systems of bisphosphonates for the treatment of bone resorption. *Adv Drug Deliv Rev* 2000;42:175-95.
- Berenson JR, Rosen L, Vescio R, Lau HS, Woo M, Sioufi A, *et al.* Pharmacokinetics of pamidronate disodium in patients with cancer with normal or impaired renal function. *J Clin Pharmacol* 1997;37:285-90.
- Russell RG, Watts NB, Ebtino FH, Rogers MJ. Mechanisms of action of bisphosphonates: Similarities and differences and their potential influence on clinical efficacy. *Osteoporos Int* 2008;19:733-59.
- Russell RG, Xia Z, Dunford JE, Oppermann U, Kwaasi A, Hulley PA, *et al.* Bisphosphonates: An update on mechanisms of action and how these relate to clinical efficacy. *Ann N Y Acad Sci* 2007;1117:209-57.
- Drake MT, Clarke BL, Khosla S. Bisphosphonates: Mechanism of action and role in clinical practice. *Mayo Clin Proc* 2008;83:1032-45.
- King AE, Umland EM. Osteonecrosis of the jaw in patients receiving intravenous or oral bisphosphonates. *Pharmacotherapy* 2008;28:667-77.
- Kohno N, Aogi K, Minami H, Nakamura S, Asaga T, Iino Y, *et al.* Zoledronic acid significantly reduces skeletal complications compared with placebo in Japanese women with bone metastases from breast cancer: A randomized, placebo-controlled trial. *J Clin Oncol* 2005;23:3314-21.
- Lipton A, Zheng M, Seaman J. Zoledronic acid delays the onset of skeletal-related events and progression of skeletal disease in patients with advanced renal cell carcinoma. *Cancer* 2003;98:962-9.
- Himelstein AL, Foster JC, Khatcheressian JL, Roberts JD, Seisler DK, Novotny PJ, *et al.* Effect of longer-interval vs. standard dosing of zoledronic acid on skeletal events in patients with bone metastases: A randomized clinical trial. *JAMA* 2017;317:48-58.
- Rosen LS, Gordon D, Tchekmedyan S, Yanagihara R, Hirsh V, Krzakowski M, *et al.* Zoledronic acid versus placebo in the treatment of skeletal metastases in patients with lung cancer and other solid tumors: A phase III, double-blind, randomized trial – The zoledronic acid lung cancer and other solid tumors study group. *J Clin Oncol* 2003;21:3150-7.
- Quattrocchi CC, Santini D, Dell'aia P, Piciucchi S, Leoncini E, Vincenzi B, *et al.* A prospective analysis of CT density measurements of bone metastases after treatment with zoledronic acid. *Skeletal Radiol* 2007;36:1121-7.
- Smith MR, Eastham J, Gleason DM, Shasha D, Tchekmedyan S, Zinner N. Randomized controlled trial of zoledronic acid to prevent bone loss in men receiving androgen deprivation therapy for nonmetastatic prostate cancer. *J Urol* 2003;169:2008-12.
- Kapoor A, Gupta A, Desai N, Ahn H. Effect of zoledronic acid on bone mineral density in men with prostate cancer receiving gonadotropin-releasing hormone analog. *Prostate Cancer* 2011;2011:176164.
- Ryan CW, Huo D, Demers LM, Beer TM, Lacerna LV. Zoledronic acid initiated during the first year of androgen deprivation therapy increases bone mineral density in patients with prostate cancer. *J Urol* 2006;176:972-8.
- Dodson TB. Intravenous bisphosphonate therapy and bisphosphonate-related osteonecrosis of the jaws. *J Oral Maxillofac Surg* 2009;67:44-52.
- Migliorati CA, Siegel MA, Elting LS. Bisphosphonate-associated osteonecrosis: A long-term complication of bisphosphonate treatment. *Lancet Oncol* 2006;7:508-14.
- Ruggiero SL, Mehrotra B, Rosenberg TJ, Engroff SL. Osteonecrosis of the jaws associated with the use of bisphosphonates: A review of 63 cases. *J Oral Maxillofac Surg* 2004;62:527-34.
- Bamias A, Kastiris E, Bamia C, Mouloupoulos LA, Melakopoulos I, Bozas G, *et al.* Osteonecrosis of the jaw in cancer after treatment with bisphosphonates: Incidence and risk factors. *J Clin Oncol* 2005;23:8580-7.
- Woo SB, Hellstein JW, Kalmar JR. Narrative [corrected] review: Bisphosphonates and osteonecrosis of the jaws. *Ann Intern Med* 2006;144:753-61.
- Cetiner S, Sucak GT, Kahraman SA, Aki SZ, Kocakahaoglu B, Gultekin SE, *et al.* Osteonecrosis of the jaw in cancer after treatment with multiple myeloma treated with zoledronic acid. *J Bone Miner Metab* 2009;27:435-43.
- Hoff AO, Toth BB, Altundag K, Johnson MM, Warneke CL, Hu M, *et al.* Frequency and risk factors associated with osteonecrosis of the jaw in cancer patients treated with intravenous bisphosphonates. *J Bone Miner Res* 2008;23:826-36.
- Tosi P, Zamagni E, Cangini D, Tacchetti P, Di Raimondo F, Catalano L,

- et al.* Osteonecrosis of the jaws in newly diagnosed multiple myeloma patients treated with zoledronic acid and thalidomide-dexamethasone. *Blood* 2006;108:3951-2.
26. Boonyapakorn T, Schirmer I, Reichart PA, Sturm I, Massenkeil G. Bisphosphonate-induced osteonecrosis of the jaws: Prospective study of 80 patients with multiple myeloma and other malignancies. *Oral Oncol* 2008;44:857-69.
 27. Morris PG, Hudis C, Carrasquillo J, Larson S, Grewal RK, Van Poznak C. Bone scans, bisphosphonates, and a lack of acute changes within the mandible. *J Oral Maxillofac Surg* 2011;69:114-9.
 28. Reinbold WD, Wannemacher M, Hodapp N, Adler CP. Osteodensitometry of vertebral metastases after radiotherapy using quantitative computed tomography. *Skeletal Radiol* 1989;18:517-21.
 29. Shapiro CL, Keating J, Angell JE, Janicek M, Gelman R, Hayes D, *et al.* Monitoring therapeutic response in skeletal metastases using dual-energy x-ray absorptiometry: A prospective feasibility study in breast cancer patients. *Cancer Invest* 1999;17:566-74.
 30. Pauwels R, Jacobs R, Singer SR, Mupparapu M. CBCT-based bone quality assessment: Are hounsfield units applicable? *Dentomaxillofac Radiol* 2015;44:20140238.
 31. Kim DG. Can dental cone beam computed tomography assess bone mineral density? *J Bone Metab* 2014;21:117-26.
 32. Shah DN, Chauhan CJ, Solanki JS. Effectiveness of hyperbaric oxygen therapy in irradiated maxillofacial dental implant patients: A systematic review with meta-analysis. *J Indian Prosthodont Soc* 2017;17:109-19.
 33. John GP, Joy TE, Mathew J, Kumar VR. Fundamentals of cone beam computed tomography for a prosthodontist. *J Indian Prosthodont Soc* 2015;15:8-13.
 34. John GP, Joy TE, Mathew J, Kumar VR. Applications of cone beam computed tomography for a prosthodontist. *J Indian Prosthodont Soc* 2016;16:3-7.
 35. Caraglia M, Santini D, Marra M, Vincenzi B, Tonini G, Budillon A. Emerging anti-cancer molecular mechanisms of aminobisphosphonates. *Endocr Relat Cancer* 2006;13:7-26.
 36. Van den Wyngaert T, Huizing MT, Fossion E, Vermorken JB. Scintigraphic evaluation of mandibular bone turnover in patients with solid tumors receiving zoledronic acid. *Oral Oncol* 2010;46:214-8.
 37. Ristow O, Gerngroß C, Schwaiger M, Hohlweg-Majert B, Kehl V, Jansen H, *et al.* Is bone turnover of jawbone and its possible over suppression by bisphosphonates of etiologic importance in pathogenesis of bisphosphonate-related osteonecrosis? *J Oral Maxillofac Surg* 2014;72:903-10.
 38. Wood J, Bonjean K, Ruetz S, Bellahcène A, Devy L, Foidart JM, *et al.* Novel antiangiogenic effects of the bisphosphonate compound zoledronic acid. *J Pharmacol Exp Ther* 2002;302:1055-61.
 39. Parfitt AM. The mechanism of coupling: A role for the vasculature. *Bone* 2000;26:319-23.
 40. Wen D, Qing L, Harrison G, Golub E, Akintoye SO. Anatomic site variability in rat skeletal uptake and desorption of fluorescently labeled bisphosphonate. *Oral Dis* 2011;17:427-32.
 41. Kim I, Ki H, Lee W, Kim H, Park JB. The effect of systemically administered bisphosphonates on bony healing after tooth extraction and osseointegration of dental implants in the rabbit maxilla. *Int J Oral Maxillofac Implants* 2013;28:1194-200.
 42. Abtahi J, Agholme F, Sandberg O, Aspenberg P. Effect of local vs. systemic bisphosphonate delivery on dental implant fixation in a model of osteonecrosis of the jaw. *J Dent Res* 2013;92:279-83.

New features on the journal's website

Optimized content for mobile and hand-held devices

HTML pages have been optimized of mobile and other hand-held devices (such as iPad, Kindle, iPod) for faster browsing speed.

Click on [**Mobile Full text**] from Table of Contents page.

This is simple HTML version for faster download on mobiles (if viewed on desktop, it will be automatically redirected to full HTML version)

E-Pub for hand-held devices

EPUB is an open e-book standard recommended by The International Digital Publishing Forum which is designed for reflowable content i.e. the text display can be optimized for a particular display device.

Click on [**EPub**] from Table of Contents page.

There are various e-Pub readers such as for Windows: Digital Editions, OS X: Calibre/Bookworm, iPhone/iPod Touch/iPad: Stanza, and Linux: Calibre/Bookworm.

E-Book for desktop

One can also see the entire issue as printed here in a 'flip book' version on desktops.

Links are available from Current Issue as well as Archives pages.

Click on  View as eBook