

This article is licensed under the Creative Commons Attribution-NonCommercial 4.0 International License (CC BY-NC) (<http://www.karger.com/Services/OpenAccessLicense>). Usage and distribution for commercial purposes requires written permission.

## Single Case

# Interval Squamous Cell Carcinoma of the Rectum

Daryl Ramai<sup>a</sup> Kinesh Changela<sup>b</sup> Jonathan Lai<sup>a</sup> Ghulamullah Shahzad<sup>b</sup>  
Madhavi Reddy<sup>b</sup>

<sup>a</sup>Department of Anatomical Sciences, St. George's University, True Blue, Grenada;

<sup>b</sup>Division of Gastroenterology, The Brooklyn Hospital Center – Clinical Affiliate of Mount Sinai Hospital, Brooklyn, NY, USA

## Keywords

Interval cancer · Rectal carcinoma · Screening colonoscopy · Endoscopic ultrasound

## Abstract

Squamous cell carcinoma (SCC) of the rectum is a rare clinical entity with an incidence rate of 0.1–0.25% per 1,000 cases. Though its etiology and pathogenesis remains unclear, it has been associated with chronic inflammation and infections. Herein, we report a case of an 82-year-old female who presented with a 2-month history of worsening abdominal pain, hematochezia, and bilateral inguinal lymphadenopathy with right-sided purulent discharge. Two years prior, she had had an unremarkable screening colonoscopy which met all quality indicators. Abdominal CT scan showed an irregular rectal mass with bulky pelvic and retroperitoneal adenopathy. Colonoscopy revealed one large circumferential nonobstructing lesion in the rectum. Endoscopic ultrasound confirmed its origin from the rectal wall with an enlarged perirectal lymph node. Cold biopsy followed by histopathology revealed SCC of the rectum.

© 2017 The Author(s)  
Published by S. Karger AG, Basel

## Introduction

Squamous cell carcinoma (SCC) usually affects the esophagus or anal canal, and organs with squamous linings. SCC of the gastrointestinal tract lined by nonsquamous epithelium is

a very rare malignancy which accounts for 0.1–0.25% per 1,000 cases of colorectal carcinoma [1, 2]. There are only few reported cases of SCC of the rectum, but interval development of SCC of the rectum without any prior precancerous lesion is a very rare clinical entity. SCC of the rectum mainly affects individuals between the age of 39 and 93 years, with a mean age of 57 years, and is more frequently found in women than in men [3]. The first case of SCC of the colon was described by Schmidtmann [4] in 1919, who reported a case of SCC of the cecum in a 65-year-old male. We present a unique case report of interval SCC of the rectum in a patient who had no prior precancerous lesion on index high-quality screening colonoscopy. This article highlights the current knowledge and appropriate management options for SCC of the rectum.

### Case

An 82-year-old female was admitted for worsening abdominal pain, hematochezia, and bilateral inguinal lymphadenopathy with right-sided purulent discharge. She reported that her symptoms had worsened over 2 months. The patient was a nonsmoker and nondrinker, and review of systems was negative for any weight loss. Physical examination revealed diffuse lower abdominal tenderness and a rectal mass. Vital signs were stable, and laboratory results were within normal limits, with hemoglobin of 13.1 g/dL. Two years prior, she had had an unremarkable screening colonoscopy which met all quality indicators. Abdominal CT scan revealed a suspicious rectal mass with bulky pelvic and retroperitoneal adenopathy. The patient underwent a colonoscopy, which revealed one large circumferential lesion in the rectum (Fig. 1). Endoscopic ultrasound showed a hypoechoic irregular mass extending into the muscularis propria measuring approximately 20.5 × 17.7 mm without pelvic organ involvement (Fig. 2, Fig. 3). The lesion occupied 75% of the lumen. Also, a perirectal lymph node was detected in the perirectal area measuring 13.1 × 16.5 mm. Histology revealed an invasive, moderately differentiated SCC (Fig. 4), and staging of the tumor revealed T3, N1, M0.

### Discussion

SCC is one of the rarest forms of rectal cancer. Ninety percent of rectal cancers are adenocarcinomas, with the remaining 10% being neuroendocrine tumors, lymphomas, and gastrointestinal stromal tumors [5, 6]. While SCC can occur throughout the gastrointestinal tract, it commonly affects the anal canal and esophagus. Though cases of mixed histology such as adenosquamous carcinoma have been described in the literature, pure SCC is a very rare histological diagnosis and clinical occurrence [7]. Even though SCC shares similar clinical presentations with adenocarcinoma, we believe it possesses a unique etiology, pathogenesis pathway, and clinical course.

Though the first case of SCC of the colon was reported in 1919, it was not until 1933 that the first case of rectal SCC was published by Raiford [8]. Due to its rarity, the natural history and progression of SCC is not well established. However, information on rectal SCC can be extrapolated from the large population-based National Cancer Institute, which estimated its incidence at 1.9 per million in the year 2000 [9]. In 2007, Kang et al. [3] reported that the incidence appears to be increasing and extrapolated the incidence as high as 3.5 per million population. While risk factors have not been clearly defined, SCC of the rectum has been

associated with inflammatory processes such as ulcerative colitis, *Entamoeba histolytica*, schistosomiasis, and human papilloma virus, which has a strong association with squamous cancer of the anal canal [2, 10].

The etiology and pathogenesis of rectal SCC remains unclear. One of the leading theories postulates that chronic inflammation leads to squamous metaplasia and subsequent carcinoma. It reasons that irritation from various stressors causes architectural distortion within the epithelial layer. If the inciting stressor is not removed, the area of metaplasia can subsequently undergo dysplasia and subsequent carcinoma. Another theory draws upon the idea that mucosal stem cells are pluripotent and capable of multidirectional differentiation. Nahas et al. [11] showed that the keratin profile for rectal SCC and adenocarcinoma were similar and unlike SCC of the anal canal. The theory suggests a common cellular ancestor for both cancer subtypes.

The clinical presentation of SCC is similar to adenocarcinoma, with rectal bleeding being most frequently reported. Furthermore, many supposed rectal SCC may be an extension of anal or gynecological carcinoma, requiring diagnostic vigilance. It is for this reason that Williams et al. [12] established guidelines before a definitive diagnosis of SCC can be made. These criteria include: (1) exclusion of primary SCC from distant sources; (2) exclusion of a squamous lined fistula from the bowel tumor; (3) the tumor must originate from the rectum and not be an extension of SCC of the anus; (4) confirmation of SCC by histology. To fulfil the above criteria, we decided to proceed with endoscopic ultrasound, which confirmed its origin from the rectal wall with enlarged perirectal lymph node and no local spread to adjacent pelvic organs.

Traditionally, rectal SCC has been treated with surgical resection. However, in the recent decade, there has been growing interest in the use of chemoradiotherapy. Following multiple randomized controlled trials, the Nigro protocol has become the standard of care in treating anal carcinoma. It encourages the use of chemoradiotherapy, followed by the use of surgery for rescue therapy. The protocol has been slowly adopted to treat rectal SCC. Guerra et al. [9] in their review showed that chemoradiotherapy had an overall survival of 85% compared with 45% for conventional treatment.

In conclusion, SCC of the rectum is a very rare and malignant disease. Current screening guidelines recommend repeat screening colonoscopy after 10 years in an average risk population if the index screening colonoscopy is unremarkable and meets all high-quality indicators. However, cases of interval cancer can occur. Thus, more research is needed to understand the etiology and pathogenesis of SCC of the rectum. We believe that more multicentric studies are needed to develop a screening tool for the prevention of SCC of the colon.

### Statement of Ethics

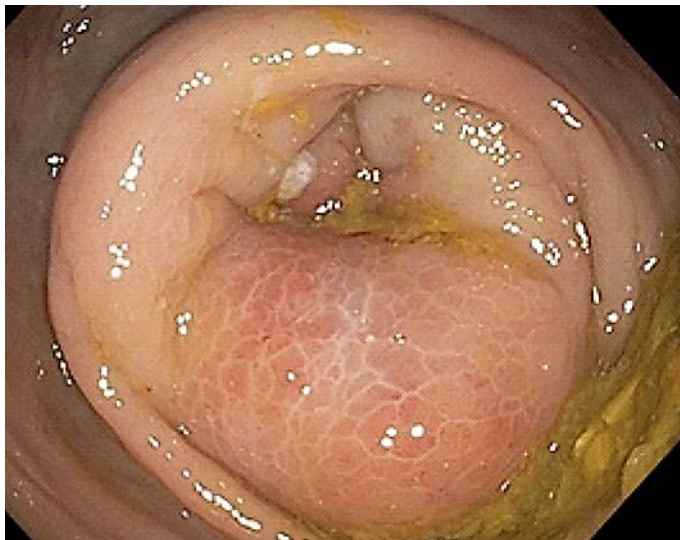The authors have no ethical disclosures.

### Disclosure Statement

There are no conflicts of interest.

## References

- 1 Giovannucci E, Wu K: Cancers of the colon and rectum; in Schottenfeld D, Fraumeni JF Jr (eds): *Cancer Epidemiology and Prevention*, 3rd ed. New York, Oxford University Press, 2006.
- 2 Dyson T, Draganov PV: Squamous cell cancer of the rectum. *World J Gastroenterol* 2009;15:4380–4386.
- 3 Kang H, O'Connell JB, Leonardi MJ, et al: Rare tumors of the colon and rectum: a national review. *Int J Colorectal Dis* 2007;22:183–189.
- 4 Schmidtman M: Zur Kenntnis seltener Krebsformen. *Virchows Arch Pathol Anat* 1919;226:100–118.
- 5 DiSario JA, Burt RW, Kendrick ML, et al: Colorectal cancers of rare histologic types compared with adenocarcinomas. *Dis Colon Rectum* 1994;37:1277–1280.
- 6 Miyamoto H, Nishioka M, Kuritaa N, et al: Squamous cell carcinoma of the descending colon: report of a case and literature review. *Case Rep Gastroenterol* 2007;1:77–83.
- 7 Frizelle FA, Hobday KS, Batts KP, et al: Adenosquamous and squamous carcinoma of the colon and upper rectum: a clinical and histopathologic study. *Dis Colon Rectum* 2001;44:341–346.
- 8 Raiford TS: Epitheliomata of the lower rectum and anus. *Surg Gynecol Obstet* 1933;57:21–35.
- 9 Guerra GR, Kong CH, Warriner SK, et al: Primary squamous cell carcinoma of the rectum: an update and implications for treatment. *World J Gastrointest Surg* 2016;8:252–265.
- 10 Kong CS, Welton ML, Longacre TA: Role of human papillomavirus in squamous cell metaplasia-dysplasia-carcinoma of the rectum. *Am J Surg Pathol* 2007;31:919–925.
- 11 Nahas CS, Shia J, Joseph R, et al: Squamous-cell carcinoma of the rectum: a rare but curable tumor. *Dis Colon Rectum* 2007;50:1393–1400.
- 12 Williams GT, Blackshaw AJ, Morson BC: Squamous carcinoma of the colorectum and its genesis. *J Pathol* 1979;129:139–147.



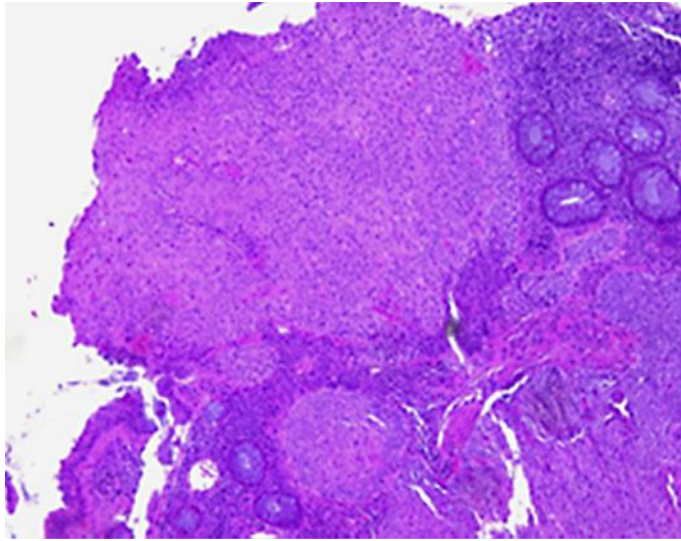
**Fig. 1.** Large circumferential lesion in the rectum.

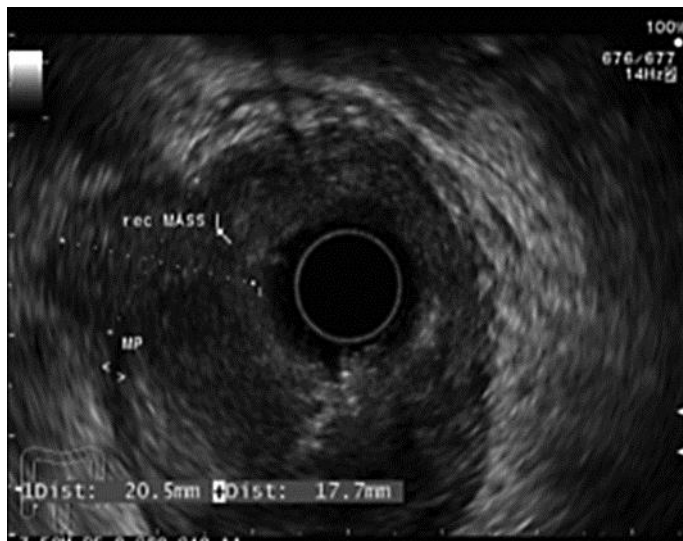

Fig. 2. Hypoechoic rectal mass extending into the muscularis propria.

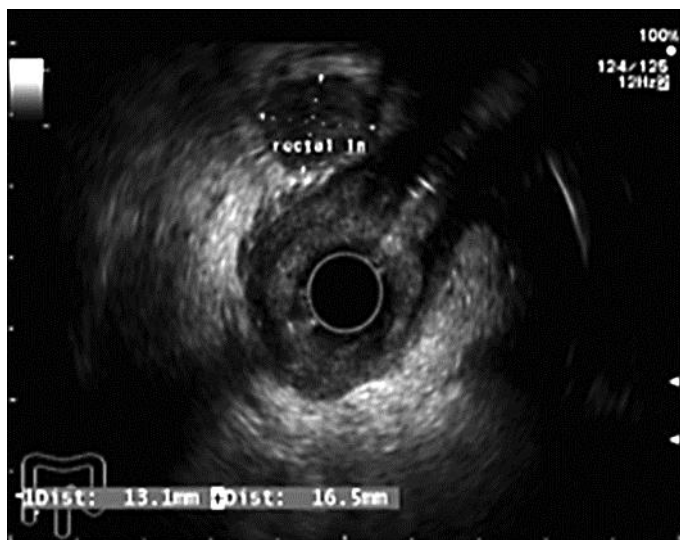

Fig. 3. Enlarged perirectal lymph node.



**Fig. 4.** H&E-stained squamous cell carcinoma arising from the rectal mucosa.