

# Weakness, Numbness and Urinary Incontinence in an 11-Year-Old Female

Global Pediatric Health  
Volume 9: 1–4  
© The Author(s) 2022  
Article reuse guidelines:  
sagepub.com/journals-permissions  
DOI: 10.1177/2333794X221106165  
journals.sagepub.com/home/gph



Larissa Maria Isaac Maximo, MD<sup>1</sup> , Amanda March, DO<sup>1</sup>,  
and Suet Kam Lam, MD, MPH, MS<sup>1,2,3</sup>

## Abstract

Acute disseminated encephalomyelitis (ADEM) affects the central nervous system (CNS) via a rapid and auto-immune process. It has been associated to viral and bacterial infections, as well as after immunization. Since the beginning of the SARS-CoV-2 (COVID-19) pandemic, reports of COVID 19 infection have been linked to ADEM. We present a case of an 11-year-old female with neurological symptoms during the acute phase of her COVID-19 illness, with MRI changes and positive Myelin Oligodendrocyte Glycoprotein (MOG) antibodies, with clinical presentation consistent of ADEM.

## Keywords

acute disseminated encephalomyelitis, SARS-CoV-2 infection, demyelinating disease

Received March 3, 2022. Accepted for publication May 23, 2022.

## Case Presentation

An 11-year-old previously healthy female, with no significant past medical history, presented to the emergency department with complaints of bilateral lower extremity weakness and numbness. Initial symptoms started 5 days prior to admission, with fatigue, chills, headache, abdominal discomfort, as well as a mild sore throat and muffled voice. On the fifth day, she began experiencing bilateral lower extremity weakness and numbness that progressed upwards to the knees, with associated urinary incontinence, and falls. She denied nausea, vomiting, diarrhea, rhinorrhea, cough, anosmia, or fevers.

On admission, a routine hospital admission SARS-CoV-2 infection (COVID-19) test resulted positive. Of note, there was a history significant for multiple family members who tested positive for COVID-19 a few days prior to the patient's ED visit during a visit to Florida. Her physical exam was notable for bilateral lower extremity weakness (right > left) ranging from 4 to 4+, ataxia, left upgoing plantar response, as well as reduced sensation to pinprick bilateral lower extremities to L3 dermatome, with normal sensation of bilateral upper extremities. Her gait was unsteady and wide-based, but she presented with intact deep-tendon reflexes, proprioception, mental status, cranial nerves II-XII, and coordination. Admission laboratory findings were remarkable for an elevated creatine kinase of 252 U/L (normal

42-196 U/L) and D-dimer 700 ng/mL FEU—Fibrinogen Equivalent Units (normal < 500 ng/mL FEU). MRI neuroaxis revealed restricted diffusion in splenium of corpus callosum, with multifocal T2/FLAIR hyperintensities in supra- and infra-tentorial white matter, edema in the cervical and thoracic intramedullary cord with thoracic level syrinx, with patchy intramedullary enhancement edema (Figures 1 and 2).

Infectious disease and neurology sub-specialty services were consulted. A lumbar puncture was done, with extensive cerebrospinal fluid (CSF) analysis, that was significant for an elevated total nucleated cells 34/uL (normal 0-5/uL), glucose 53 mg/dL (normal 60-80 mg/dL), protein 39 mg/dL (normal 15-45 mg/dL). Immunoglobulin G (IgG) was 3.1 (normal 1.0-3.0 mg/dL), with IgG index 0.65 (normal 0-0.61). The Myelin Oligodendrocyte Glycoprotein Fluorescence-Activated Cell Sorting (MOG-IgG1 FACS) assay was positive,

<sup>1</sup>Cleveland Clinic Children's Hospital, Cleveland, OH, USA

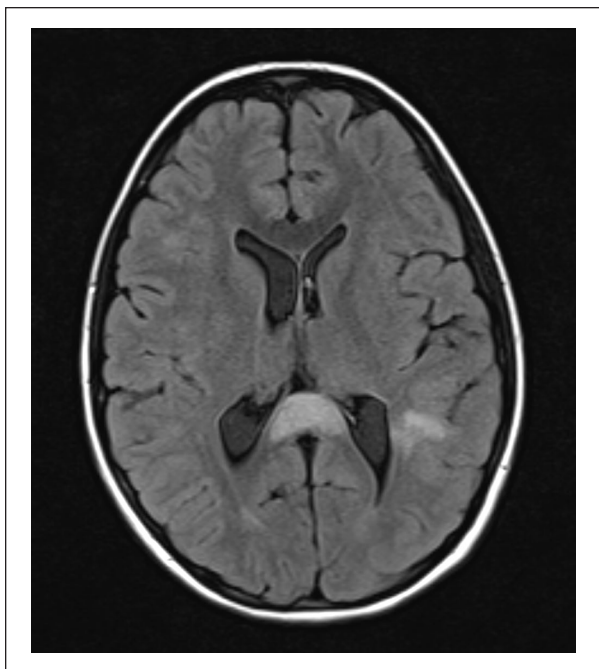
<sup>2</sup>Case Western Reserve University School of Medicine, Cleveland, OH, USA

<sup>3</sup>Cleveland Clinic Lerner College of Medicine, Cleveland, OH, USA

## Corresponding Author:

Larissa Maria Isaac Maximo, Department of Pediatrics, Cleveland Clinic Children's Hospital, 8950 Euclid Avenue, R Building, Cleveland, OH 44106, USA.  
Email: isaacml@ccf.org





**Figure 1.** T2/FLAIR axial image of the brain, showing high T2/FLAIR signal scattered in the subcortical white matter, particularly in the splenium of the corpus callosum.

with titers 1:1000 (normal < 1:20). Aquaporin-4 Receptor Antibody IgG (NMO Aq4 IgG) was negative. Myelin Basic Protein was elevated at 85 ng/mL (normal 0-5.5 ng/mL). Oligoclonal bands were not seen in the CSF. A complete blood count showed mild leukocytosis 12.74k/uL (normal 4.27-11.40k/uL), with a normal C-reactive protein. Blood and CSF cultures did not result in any bacterial growth.

### Hospital Course

Our patient was started on IV methylprednisolone 1000mg/day for 5 days, followed by a gradual steroid taper with oral prednisolone, with a total of 30 days on steroids. Her diagnosis was most consistent with ADEM, based on the clinical history, MRI, and CSF findings.

She was discharged on day 6 of admission, and she was seen for outpatient neurology follow-up 28 days later. At that visit, she was back to her baseline with a normal physical exam and was able to play sports, with no further need for physical and occupational therapy that was started during hospital admission. Her only active issue was nocturnal enuresis, presumed to resolve as she continues to recover. She denied other neurological symptoms, such as urinary incontinence while awake, bowel incontinence, polydipsia, or sleep disturbances. The plan was to recheck MOG titers approximately 6 months after, to ensure decreasing levels, but the patient lost follow up.

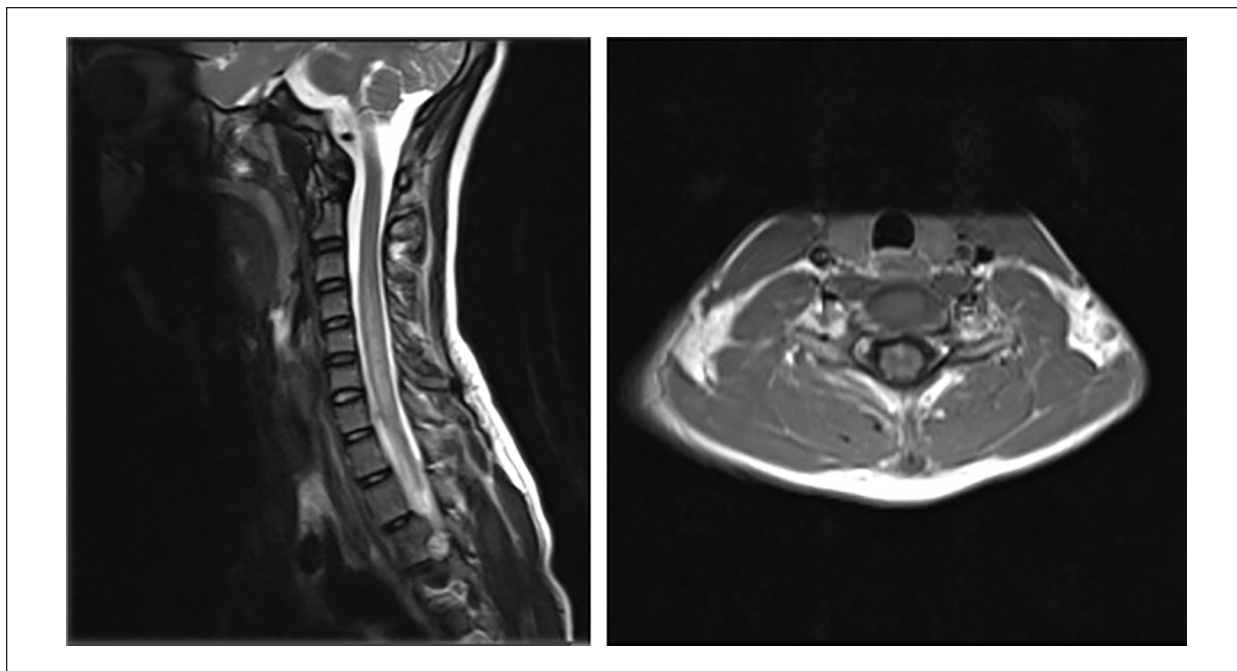
### Discussion:

Since the beginning of the COVID-19 pandemic, 84,762,952 cases of COVID-19 have been reported as of June 6, 2022 in the United States.<sup>1</sup> Neurological symptoms have been reported as complications of the COVID-19 infection, especially in adults, such as anosmia, headache, encephalopathy, meningitis, Guillain-Barre syndrome, stroke, myopathy, and ADEM.<sup>2</sup> Although the majority of the pediatric patients are asymptomatic, there are a few reports of neurological manifestations.<sup>3</sup>

Acute disseminated encephalomyelitis (ADEM) (or post-infectious encephalomyelitis) affects the central nervous system (CNS) via a rapid and auto-immune process. Vaccines and viral infections have been linked to the condition, though bacteria have also played a role.<sup>4,5</sup> Most recently, reports of SARS-CoV-2 (COVID-19) infection have been linked to ADEM.<sup>2,3</sup> The estimated incidence of ADEM in the pediatric population is 0.2 to 0.4/100,000, with a male predominance of 1.3:1 females.<sup>6</sup>

While the pathophysiology of the disease has not been fully elucidated, it is believed that a trigger (infection, vaccination) may lead to an autoimmune response, leading to demyelination and a rapid onset of multifocal neurological deficits.<sup>6,7</sup> Another proposed mechanism is increased vascular permeability, leading to increased immune complexes and inflammation in the CNS.<sup>6,7</sup> According to the criteria established in 2013 by the International Pediatric Multiple Sclerosis group, the diagnosis of ADEM require meeting the following criteria<sup>8</sup>: “(1) a first polyfocal, clinical CNS event with presumed inflammatory demyelinating cause; (2) encephalopathy that cannot be explained by fever; (3) no new clinical and MRI findings emerge 3 months or more after the onset; (4) brain MRI is abnormal during the acute (3 month) phase; (5) typically on brain MRI: (a) diffuse, poorly demarcated, large (>1-2 cm) lesions involving predominantly the cerebral white matter; (b) T1 hypointense lesions in the white matter are rare; (c) deep gray matter lesions (eg, thalamus or basal ganglia) can be present”.

There is no confirmatory diagnostic test for ADEM and diagnosis relies on a thorough history and physical exam, supplemented by imaging.<sup>6</sup> Clinical presentation consists of a non-specific sudden onset of encephalopathy, with or without fever. Neurological deficits are classically polyfocal and may include visual field deficits and hemiparesis. Also, a preceding history of viral illness supports the diagnosis. Brain MRI imaging is also consistent with bilateral and asymmetrical brain lesions in the supra- or infra-tentorial white matter, which are hyperintense on T2-weighted and FLAIR sequences.<sup>7</sup>



**Figure 2.** T2 sagittal image of the cervical spine, showing T2 hyperintense longitudinally extensive lesion from C3 down to T2.

Initial lesions may persist and new lesions may appear during the immediate recovery period.<sup>9</sup>

The presence of elevated Myelin Oligodendrocyte Glycoprotein (MOG) antibodies is not specific for ADEM and have also been described in multiple sclerosis, neuromyelitis optica, transverse myelitis and optic neuritis. However, it can be useful for long-term monitoring, as monophasic and multiphasic presentations have been reported in ADEM.<sup>6</sup>

### Treatment/Management

The mainstay of treatment for ADEM is steroids (intravenous methylprednisolone 30 mg/kg/day [maximum 1000 mg/day] for 3 to 5 days, followed by an optional oral steroid taper for 4-6 weeks). In refractory cases, IV immunoglobulin and plasma exchange demonstrated improved outcomes. Steroid response is seen in patients with high MOG antibodies; however, these patients may be more vulnerable to relapse during steroid reduction or cessation.<sup>6</sup> The majority of patients recover fully neurologically by 3 months.<sup>6</sup>

The patient described in this case report had neurological symptoms during the acute phase of her COVID-19 infection. She also presented with MRI changes, with multifocal T2/FLAIR hyperintensities in supra- and infra-tentorial white matter, cervical and thoracic intramedullary cord lesions. She was positive for MOG

antibodies and had a good response to steroid therapy, but still needs monitoring of MOG antibody levels due to the chance of recurrence. This presentation is one of the neurological manifestations of COVID-19 infection that needs to be considered in a pediatric patient with central nervous system presentation.

### Acknowledgments

Thank you to Dr Doksu Moon, MD for assistance with imaging for the article.

### Author Contributions

Drs Isaac Maximo, March and Lam contributed to the writing of the manuscript, literature review and imaging selection.

### Declaration of Conflicting Interest

The author(s) declared the following potential conflicts of interest with respect to the research, authorship, and/or publication of this article: Drs Isaac Maximo, March, and Lam have disclosed no financial relationships relevant to this article. Dr. Lam is a planning faculty for the AAP global health education course. This commentary does not contain a discussion of an unapproved/investigative use of a commercial product/device.

### Funding

The author(s) received no financial support for the research, authorship, and/or publication of this article.

### Ethical Approval/Patient consent

Patient and legal guardian consented verbally and in a written paper regarding the case report and the images for publication

### ORCID iD

Larissa Maria Isaac Maximo  <https://orcid.org/0000-0001-7731-2211>

### References

1. Centers for Disease Control and Prevention. COVID data tracker. 2021. Accessed August 27, 2021. [https://covid.cdc.gov/covid-data-tracker/#trends\\_dailytrendscases](https://covid.cdc.gov/covid-data-tracker/#trends_dailytrendscases)
2. Parsons T, Banks S, Bae C, Gelber J, Alahmadi H, Tichauer M. COVID-19-associated acute disseminated encephalomyelitis (ADEM). *J Neurol*. 2020;267(10):2799-2802. doi:10.1007/s00415-020-09951-9
3. de Miranda Henriques-Souza AM, de Melo AC, de Aguiar Coelho Silva Madeiro B, Freitas LF, Sampaio Rocha-Filho PA, Gonçalves FG. Acute disseminated encephalomyelitis in a COVID-19 pediatric patient. *Neuroradiol*. 2021;63(1):141-145. doi:10.1007/s00234-020-02571-0
4. Anilkumar AC, Foris LA, Tadi P. *Acute Disseminated Encephalomyelitis*. StatPearls Publishing; 2021.
5. Malagón Valdez J. Enfermedades desmielinizantes en niños. Encefalomyelitis diseminada aguda y esclerosis múltiple [Demyelinating diseases in children. Acute disseminated encephalomyelitis and multiple sclerosis]. *Medicina*. 2019;79(Suppl 3):66-70.
6. Santoro JD, Chitnis T. Diagnostic considerations in acute disseminated encephalomyelitis and the interface with MOG Antibody. *Neuropediatrics*. 2019;50(5):273-279. doi:10.1055/s-0039-1693152
7. Langley L, Zeicu C, Whitton L, Pauls M. Acute disseminated encephalomyelitis (ADEM) associated with COVID-19. *BMJ Case Rep*. 2020;13(12):e239597. doi:10.1136/bcr-2020-239597
8. Krupp LB, Tardieu M, Amato MP, et al. International Pediatric Multiple Sclerosis Study Group criteria for pediatric multiple sclerosis and immune-mediated central nervous system demyelinating disorders: revisions to the 2007 definitions. *Multiple Scler J*. 2013;19(10):1261-1267. doi:10.1177/1352458513484547
9. Murthy SN, Faden HS, Cohen ME, Bakshi R. Acute disseminated encephalomyelitis in children. *Pediatrics*. 2002;110(2 Pt 1):e21. doi:10.1542/peds.110.2.e21