

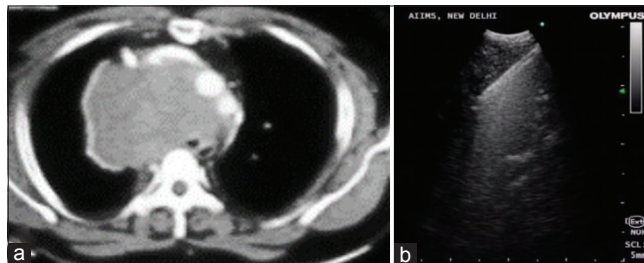
## Rigid transbronchial needle aspiration: “A sledgehammer to crack a nut”!!

Sir,

We read with keen interest the case report by Khan *et al.* published in a recent issue of Lung India.<sup>[1]</sup> In this article, authors have reported the use of rigid transbronchial needle aspiration (TBNA) using 18G rigid needle through a rigid bronchoscope for obtaining diagnosis in a large mediastinal mass causing significant airway compromise. We congratulate the authors for considering the use of this modality but have a few concerns that question the applicability of rigid TBNA (TBNA using a rigid needle inserted through a rigid bronchoscope) in the modern-day interventional pulmonology practice.

The major issue of concern in establishing tissue diagnosis in a patient with lung/mediastinal mass causing critical airway narrowing is the maintenance of a patent airway to provide safety during the bronchoscopy procedure. The authors used rigid bronchoscopy (RB) for securing the airway. However, one of the simplest, accurate, and convenient ways to perform tissue sampling in an airway secured by RB would have been the use of endobronchial ultrasound (EBUS) guided-TBNA or conventional TBNA through the barrel of the rigid bronchoscope. EBUS-TBNA provides real-time visualization and avoidance of puncture of vascular structures, which is a definite possible risk during rigid TBNA owing to lack of real-time visual guidance.

An alternative approach in this setting would have been a transesophageal bronchoscopic ultrasound-guided fine needle aspiration (EUS-B-FNA), in which an EBUS bronchoscope is inserted trans-oesophageally to perform needle aspiration or alternatively EUS-FNA.<sup>[2]</sup> We recently encountered a similar scenario. A 40-year-old non smoker male presented with shortness of breath for 15 days and orthopnea for 2 days. Computed tomography thorax revealed a large anterior mediastinal mass causing marked tracheal compromise extending up to the carina [Figure 1a]. As the patient was unable to lie supine, we decided to perform EUS-B-FNA from the lesion in a semi-recumbent position without the use of sedation. The patient was given topical oropharyngeal anesthesia with five sprays of 10% lignocaine. EBUS bronchoscope (Olympus BF-UC-180 F, Olympus Corporation Japan) was inserted through oral route through a bite-block. EBUS scope was gently negotiated posterior to the larynx and into the esophagus. Soft-tissue mass was sonographically localized in the left paratracheal location, and three passes were performed using 21G EBUS-TBNA needle (Olympus Vizishot) [Figure 1b]. The aspirate was obtained for cytopathological analysis, and clot core was



**Figure 1:** (a) Computed tomography thorax demonstrating large mediastinal mass causing marked tracheal compression, (b) Ultrasonographic image demonstrating needle sampling being performed through 21-G needle

also obtained for histopathology. There were no procedural complications. Diagnosis of B-cell Non-Hodgkin's lymphoma was established. This highlights the utility of EUS-B-FNA in patients with mediastinal lesions presenting with airway compromise. EUS-B-FNA by obviating airway entry averts the risks of airway compromise in a narrowed airway and is an excellent alternative to RB that can be performed by pulmonologists under mild/no sedation.

A major advantage over rigid TBNA in this situation is real-time visualization. A possible advantage that one may argue is larger bore of the rigid needle, but it is unlikely to be of major advantage over the 21G EBUS-TBNA needle.<sup>[3]</sup> Another technical disadvantage of using an 18G rigid needle is difficulty in distal tip control and puncture site which is possibly considerably easier with the use of a flexible bronchoscope or EBUS scope. These limitations were most likely the factors that prevented widespread adoption of rigid TBNA since its inception. Another point of discussion is the use of rapid on-site evaluation in a high-risk procedure done under general anesthesia.<sup>[4]</sup> Performance of ROSE is ideally preferable in a high-risk case. Therefore, in our opinion, rigid-TBNA does not have a major role in current clinical practice with the availability of safer sampling instruments like flexible bronchoscope and EBUS bronchoscope that can be used through RB in case the same is performed for airway stabilization.

### Declaration of patient consent

The authors certify that they have obtained all appropriate patient consent forms. In the form the patient(s) has/have given his/her/their consent for his/her/their images and other clinical information to be reported in the journal. The patients understand that their names and initials will not be published and due efforts will be made to conceal their identity, but anonymity cannot be guaranteed.

**Financial support and sponsorship**

Nil.

**Conflicts of interest**

There are no conflicts of interest.

**Saurabh Mittal, Anant Mohan, Karan Madan**

*Department of Pulmonary Medicine and Sleep Disorders,  
All India Institute of Medical Sciences, New Delhi, India  
E-mail: drkaranmadan@gmail.com*

**REFERENCES**

1. Khan A, Nath A, Lal H, Krishnani N, Agarwal A. Vintage meets contemporary: Use of rigid TBNA in the era of real-time imaging – First report from India. *Lung India* 2018;35:241-4.
2. Madan K, Garg P, Kabra SK, Mohan A, Guleria R. Transesophageal bronchoscopic ultrasound-guided fine-needle aspiration (EUS-B-FNA) in a 3-year-old child. *J Bronchology Interv Pulmonol* 2015;22:347-50.
3. Vaidya PJ, Saha A, Kate AH, Pandey K, Chavhan VB, Leuppi JD, et al. Diagnostic value of core biopsy histology and cytology sampling of mediastinal lymph nodes using 21-gauge EBUS-TBNA needle. *J Cancer Res Ther* 2016;12:1172-7.
4. Madan NK, Madan K, Jain D, Walia R, Mohan A, Hadda V, et al. Utility

of conventional transbronchial needle aspiration with rapid on-site evaluation (c-TBNA-ROSE) at a tertiary care center with endobronchial ultrasound (EBUS) facility. *J Cytol* 2016;33:22-6.

This is an open access journal, and articles are distributed under the terms of the Creative Commons Attribution-NonCommercial-ShareAlike 4.0 License, which allows others to remix, tweak, and build upon the work non-commercially, as long as appropriate credit is given and the new creations are licensed under the identical terms.

**Access this article online****Quick Response Code:****Website:**

[www.lungindia.com](http://www.lungindia.com)

**DOI:**

10.4103/lungindia.lungindia\_164\_18

**How to cite this article:** Mittal S, Mohan A, Madan K. Rigid transbronchial needle aspiration: "A sledgehammer to crack a nut"!!. *Lung India* 2018;35:447-8.

© 2018 Indian Chest Society | Published by Wolters Kluwer - Medknow