

# A case report of nodal CD4-positive T-cell lymphoproliferative disorder with an indolent course

Xiaowen Ge, MD, PhD, Na Zhu, MD, Jiamei Yao, MD, Haiying Zeng, BS, Jieakesu Su, BS, Zhengzeng Jiang, MS, Yuan Ji, MD, PhD, Yunshan Tan, MD, PhD, Yingyong Hou, MD, PhD\*

## Abstract

**Rationale:** Primary nodal CD4-positive T-cell lymphoproliferative disorder with a relatively indolent process is a rare kind of lymphoproliferative disease. Here we report the first case of a 49 year-old man developed indolent nodal CD4-positive T-cell lymphoproliferative disorder. To our knowledge, based on a careful search of PubMed, it is the first case of primary nodal CD4-positive T-cell lymphoproliferative disorder.

**Patient concerns:** A 49-year-old Chinese man presented to our hospital with fever, enlargement of multiple superficial lymphonodes more than 14 years and splenomegaly. Clinical and pathological data were collected under treatment. This case was diagnosed based on histologically characteristic, immunohistochemical staining, and lymphoid clonality testing. On immunohistochemical staining, the abnormal T-cells were CD4 positive and CD8 negative. The lymphoid clonality testing showed positive results. The patient also has enlarged spleen.

**Diagnoses:** The patient was diagnosed with nodal CD4-positive T-cell lymphoproliferative disorder.

**Interventions:** A watch-and-wait stratagem was performed without any chemotherapy or radiation therapy.

**Outcomes:** During 17 years of follow-up, this case presented an indolent course without evidence of systemic dissemination.

**Lessons:** This report presents the first case of indolent nodal CD4-positive T-cell lymphoproliferative disorder. In this case, the proliferated T-cell in the paracortex of lymph node showed T-cell receptor gene rearrangement, which indicated a clonal proliferation. There are several kinds of nodal CD4-positive T-cell lymphoma, which have a relatively aggressive course; however, this case has a relatively indolent course.

**Abbreviations:** ATL = adult T-Cell leukemia/lymphoma, CT = computed tomography, EBER = Epstein-Barr virus-encoded RNA, EBV = Epstein-Barr virus, HTLV1 = human T-lymphotropic virus type I, LDH = lactate dehydrogenase, LPDs = lymphoproliferative disorders, PET/CT = positron emission tomography/computed tomography, PTCL = peripheral T-cell lymphoma, PTCL, NOS = peripheral T-cell lymphoma, not otherwise specified, PTLDs = post-transplantation lymphoproliferative diseases, TCR = T-cell receptor, WBC = white blood cell, WHO = World Health Organization.

**Keywords:** CD4-positive, indolent, lymphoproliferative disorders, nodal, T cell

Editor: ZhiJun Duan.

This work was supported by the National Natural Science Foundation of China (grant no. 81402570), the Zhongshan Hospital for Excellent Young Scientists (grant no. 2015ZSYXQN01), and the Shanghai Municipal Commission of Health and Family Planning for Young Scientists (grant no. 20134y102) to Xiaowen Ge.

The authors declare no conflicts of interest.

Department of Pathology, Zhongshan Hospital, Fudan University, Shanghai, People's Republic of China.

\* Correspondence: Yingyong Hou, Department of Pathology, Zhongshan Hospital, Fudan University, 180 Fenglin Road, Shanghai 200032, People's Republic of China  
(e-mails: hou.yingyong@zs-hospital.sh.cn, hou.yingyong@hotmail.com).

Copyright © 2018 the Author(s). Published by Wolters Kluwer Health, Inc. This is an open access article distributed under the Creative Commons Attribution-NoDerivatives License 4.0, which allows for redistribution, commercial and non-commercial, as long as it is passed along unchanged and in whole, with credit to the author.

Medicine (2018) 97:10(e0099)

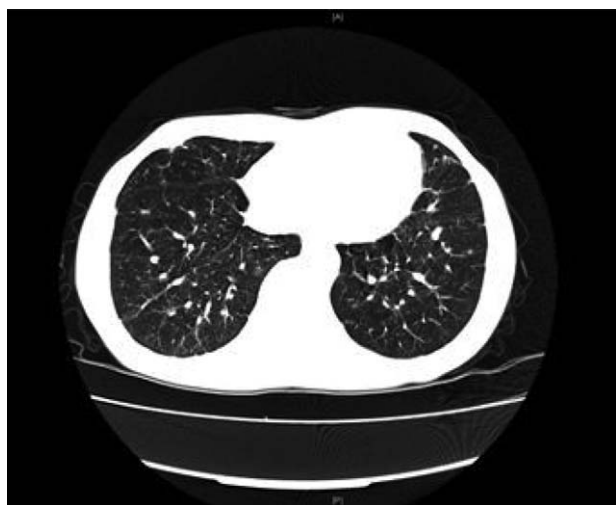Received: 6 December 2017 / Received in final form: 8 February 2018 /

Accepted: 12 February 2018

<http://dx.doi.org/10.1097/MD.00000000000010099>

## 1. Introduction

Lymphoproliferative disorders (LPDs) are part of a spectrum that includes polyclonal, oligoclonal/partial monoclonal, and monoclonal diseases. For example, immunodeficiency-related LPDs include reactive proliferation (multiple/oligomeric cloning), pleomorphic lesions (partial monoclonal), and monomorphic lesions (monoclonal).<sup>[1]</sup> These disorders are rare but can be quite serious, often occurring in immunosuppressed patients. There are several kinds of nodal CD4-positive T-cell lymphomas; they are all monoclonal diseases, like peripheral T-cell lymphomas not otherwise specified (PTCL, NOS), angioimmunoblastic T-cell lymphomas, and others, which have a relatively aggressive course. Another CD4-positive T-cell lymphoma that has a relatively indolent course is primary cutaneous CD4-positive small/medium T-cell lymphoma. These tumors usually have a CD3+CD4+ mature helper T-cell phenotype and express functional T-cell receptors (TCRs). However, a monoclonal indolent primary nodal CD4-positive T-cell lymphoma has never been reported. Because it has a relatively indolent course, we



**Figure 1.** Computed tomography scan detected scattered small nodules in both lungs.

prefer to call this case an LPD. Here, we report the first such case, that of a 49-year-old man who developed indolent nodal CD4-positive T-cell LPD. To our knowledge, based on a careful search of PubMed, it is the first reported case of primary nodal CD4-positive T-cell LPD with an indolent course. The use of this sample has been reviewed and approved by our institutional ethics board (B2015-043, 02/11/2015, Ethics Board of Zhongshan Hospital Affiliated with Fudan University).

## 2. Case report

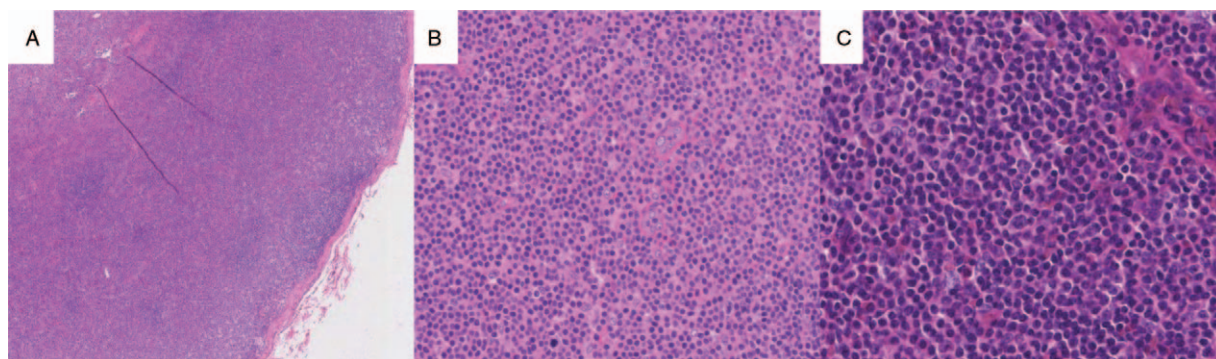
In December 2014, a 49-year-old Chinese man was admitted to the Zhongshan Hospital for multiple superficial enlarged lymph nodes of more than 14 years' duration as well as fever and chills that had lasted for more than a week. The patient had been admitted to another hospital on April 27, 2001, where multiple palpable superficial lymph nodes were discovered; at that time he had no fever or pain. He underwent right inguinal lymph node biopsy, showing that the diameter of the typical lymph node was about 1.5 cm. The pathology report pointed to chronic inflammation of the hyperplastic lymph nodes, and the patient received no further treatment. On June 7, 2001, the patient visited another hospital and underwent left submandibular

lymph nodes biopsy, indicating a typical lymph node size of about 1 by 0.5 cm. The pathology report indicated lymph node inflammation and positron emission tomography/computed tomography (PET/CT) showed enlargement and fusion of multiple superficial lymph nodes. However, the patient received no further treatment. In March 2004, because he was having chest pain, the patient was admitted to another hospital, where radiography showed multiple small nodules in both lungs. At that point the patient underwent a thoracoscopic lung biopsy. The resulting pathology report pointed to Wegener's granulomatosis. Finally, the patient came to our hospital for further treatment, which consisted of prednisone 40 mg daily over several years. As a result, the pulmonary nodules shrank without disappearing completely, while the multiple superficial lymph nodes remained.

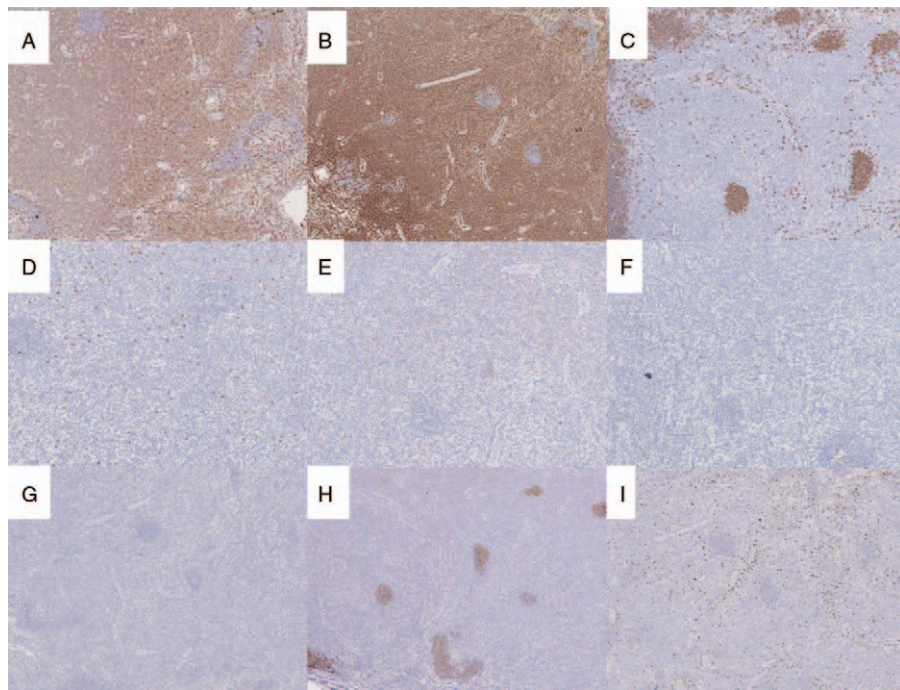
Laboratory analysis revealed a mildly elevated white blood cell (WBC) and platelet counts and mild anemia; and blood chemistries and liver profile tests were normal. Blood levels of lactate dehydrogenase (LDH) were found to be normal. The test for human T-lymphotropic virus type I (HTLV-I) was negative. Computed tomography (CT) showed scattered small nodules in both lungs (Fig. 1). The patient had an enlarged spleen and multiple palpable superficial lymph nodes the size of peanuts; these were hard and not tender. Finally the patient underwent a right axillary lymph node biopsy, which pointed to T-cell LPD.

The 3 resected lymph nodes, 3.0 by 1.5 by 1.0 cm in size, had a gray-white cut surface. Pathologic examination showed lymphoid hyperplasia. The lymph node architecture had partly disappeared and was effaced by intense, diffuse, mildly atypical small to medium lymphocytes in the paracortex (Fig. 2). Mitotic figures were not abundant. The atypical lymphocytes were positive for CD3 (Fig. 3A) and CD4 (Fig. 3B). Some 5% were positive for TIA-1 (T-cell intracytoplasmic antigen-1). The cells were negative for CD20 (Fig. 3C), CD79a, CD8 (Fig. 3D), CD56 (Fig. 3E), PD-1 (Fig. 3F), granzyme B (Fig. 3G), and perforin. CD21 (Fig. 3H) staining showed shrunken germinal centers. The Ki-67 proliferation index was approximately 40% (Fig. 3I). All antibodies were from Maixin (Shanghai, China). On in situ hybridization, the cells were also found to be negative for Epstein-Barr virus (EBV)-encoded RNA (EBER). T-cell receptor gene rearrangement studies indicated a clonal rearrangement (Fig. 4). Bone marrow aspiration and biopsy revealed no abnormalities. The final diagnosis was considered to be a nodal CD4-positive T-cell LPD with an indolent course.

The specimens obtained in April 2001 and March 2004 were also referred to our hospital for consultation. The lymph node of April 2001 also showed a diffuse proliferation of CD3- and CD4-



**Figure 2.** The lymph node architecture had partly disappeared and was effaced by intense, diffuse, mildly atypical small to medium lymphocytes in the paracortex (A  $\times 2.5$  magnification; B  $\times 10$  magnification; C  $\times 20$  magnification).



**Figure 3.** Immunohistochemical stains of the atypical lymphocytes showed the cells were positive for (A) CD3, (B) CD4. The cells were negative for (C) CD20, (D) CD8, (E) CD56, (F) PD-1, and (G) granzyme B. H, CD21 staining showed a shrunk germinal centers. I, Ki-67 proliferation index was approximately 40%. ( $\times 5$  magnification).

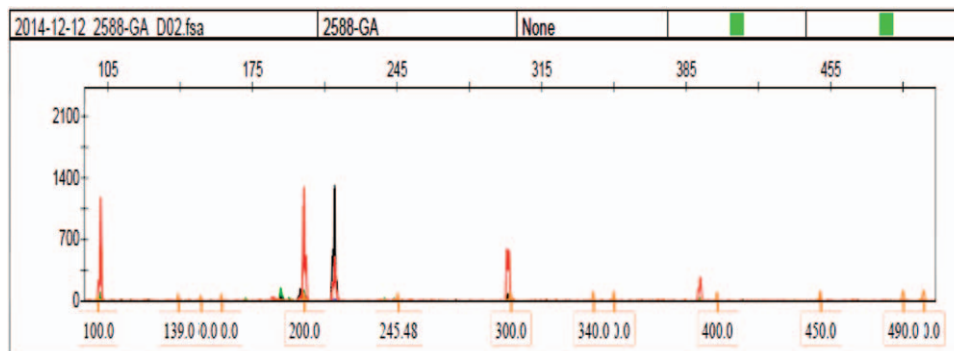
positive T-cells in the paracortex (Figs. 5 A and B). However, T-cell receptor gene rearrangement studies showed no clonal rearrangement. The lung biopsy obtained in March 2004 showed that CD3- and CD4-positive T cells had infiltrated the alveolar septum (Figs. 5 C and D). T-cell receptor gene rearrangement studies showed clonal rearrangement.

After the diagnosis, the patient was treated with anti-inflammatory drugs and the prednisone was discontinued. We determined that a watch-and-wait strategy with no chemotherapy or radiation would thereafter be the best course. Thirty months later, blood levels of LDH were found to be normal at all the follow-up evaluations. The follow-up CT scan showed that the pulmonary nodules had slowly enlarged, while already existing palpable superficial lymph nodes had not increased in size. Unexpectedly, over 17 years of follow-up, this case

presented an indolent course without evidence of systemic dissemination.

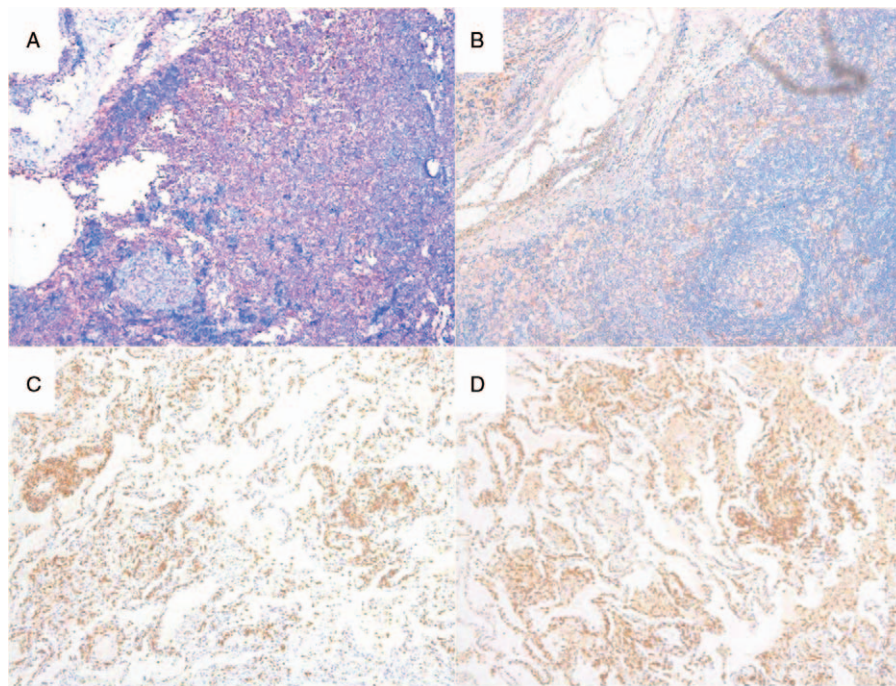
### 3. Discussion

We had a patient with primary nodal CD4-positive T-cell LPD that had a uniquely indolent clinical course; it was unlike a common malignant T-cell lymphoma. T-cell LPDs comprise a spectrum including polyclonal, oligoclonal/partial monoclonal, and monoclonal disease.<sup>[1]</sup> In this case, the proliferating T-cells in the lymph node paracortex showed gene rearrangement of the T-cell receptor, yet the disease took a relatively indolent course. To our knowledge, based on a careful search of PubMed, this is first reported case of primary nodal CD4-positive T-cell LPD with an indolent course.



**Figure 4.** T-cell receptor (TCR) gene rearrangement studies indicated a clonal rearrangement. TCR- $\gamma$ : Tube A shows atypical peaks at 219 bps.





**Figure 5.** Immunohistochemical stains of the lymph node biopsied in April 2001 showed a diffuse CD3 (A) and CD4 (B) positive T-cell proliferation in the paracortex. The lung biopsy of March 2004 showed CD3 (C) and CD4 (D) positive T-cell infiltrated in the alveolar septum.

Based on the immunophenotype, this case may have an etiopathogenesis similar to that of peripheral T-cell lymphoma (PTCL). PTCLs are histologically and clinically diverse; they have an aggressive clinical course and show systemic dissemination. In this case, the abnormal T cells invaded the lungs, but without further dissemination; moreover, enlargement of the pulmonary nodules was very slow. There is a smoldering subtype of adult T-cell leukemia/lymphoma (ATL) wherein the survival is quite variable, with some patients living for many years and others developing dissemination in less than a year.<sup>[2]</sup> The malignant cells in ATL usually have a CD4+/CD8- phenotype and are associated with human HTLV-I.<sup>[1]</sup> However, this patient was seronegative for HTLV-I. Cases of rare indolent clonal T-cell proliferations in the gastrointestinal (GI) tract have been reported<sup>[3]</sup>. The infiltrates of cells were dense, but nondestructive, and composed of small, mature appearing lymphoid cells. The immunophenotype of most of these cases were CD4-/CD8+, however, in this case, the T-cells were positive for CD3 and CD4 and do not invade GI.

LPDs occur at an increased rate in immunosuppressed patients and are often associated with EBV infection, which can induce many T/NK-cell LPDs.<sup>[4]</sup> EBV is known to infect approximately 90% of the world population and to persist in the host for life.<sup>[5]</sup> The EBV-related posttransplantation lymphoproliferative diseases (PTLDs) have been described primarily in association with liver transplantation but also with kidney, lung, heart, and bone marrow transplantation.<sup>[6,7]</sup> However, in this case, in situ hybridization for EBV was negative. The patient also had no history of immunosuppression before he began taking prednisone for the treatment of Wegener's granulomatosis. The specimen of the pulmonary nodules was referred to our hospital for consultation. The lung biopsy showed that CD3- and CD4-positive T cells had infiltrated the alveolar septum and the T-cell receptor gene

rearrangement studies showed clonal rearrangement. There was not enough evidence to support a diagnosis of Wegener's granulomatosis for the pulmonary nodules.

CD4+ primary cutaneous small/medium-sized pleomorphic T-cell lymphoma (CD4+ PCSM-TCL) is a provisional entity in the World Health Organization (WHO) classification of cutaneous lymphomas. A dense dermal infiltrate of CD4+ small/medium-sized pleomorphic T cells can sometimes be seen histopathologically. In the case of CD4+ PCSM-TCL patient, immunophenotyping showed CD3+ and CD4+ cells, with the follicular T-helper phenotype expressing PD-1 and CXCL13; a variable component of B cells could also be found.<sup>[8,9]</sup> However, in this case, the patient did not have any cutaneous lesions and the cells were negative for PD-1.

Over the 17 years of follow-up, this case took an indolent clinical course without evidence of systemic dissemination. As for treatment, we considered that high-dose chemotherapy [eg, cyclophosphamide, doxorubicin, vincristine, and prednisone (CHOP)], radiation, and autologous hematopoietic stem-cell transplant were not suitable for this case. Instead, we adopted a watch-and-wait strategy with no additional intervention until evidence of further dissemination should emerge.

## References

- [1] Swerdlow S, Campo E, Harris N, et al. WHO Classification of Tumours of Haematopoietic and Lymphoid Tissues. 4th ed. IARC Press, Lyon:2008.
- [2] Shimoyama M. Diagnostic criteria and classification of clinical subtypes of adult T-cell leukaemia-lymphoma. A report from the Lymphoma Study Group (1984-87). *Br J Haematol* 1991;79:428-37.
- [3] Perry AM, Warnke RA, Hu Q, et al. Indolent T-cell lymphoproliferative disease of the gastrointestinal tract. *Blood* 2013;122:3599-606.
- [4] Pope JH, Horne MK, Scott W. Transformation of foetal human leukocytes in vitro by filtrates of a human leukaemic cell line containing herpes-like virus. *Int J Cancer* 1968;3:857-66.

- [5] Allen U, Alfieri C, Preiksaitis J, et al. Epstein-Barr virus infection in transplant recipients: summary of a workshop on surveillance, prevention, and treatment. *Can J Infect Dis* 2002;13:89–99.
- [6] Preiksaitis JK, Keay S. Diagnosis and management of posttransplant lymphoproliferative disorder in solid-organ transplant recipients. *Clin Infect Dis* 2001;33(suppl 1):S38–46.
- [7] Zompi S, Tulliez M, Conti F, et al. Rituximab (anti-CD20 monoclonal antibody) for the treatment of patients with clonal lymphoproliferative disorders after orthotopic liver transplantation: a report of three cases. *J Hepatol* 2000;32:521–7.
- [8] Willemze R, Jaffe ES, Burg G, et al. WHO-EORTC classification for cutaneous lymphomas. *Blood* 2005;105:3768–85.
- [9] Rodriguez Pinilla SM, Roncador G, Rodriguez-Peralto JL, et al. Primary cutaneous CD4+ small/medium-sized pleomorphic T-cell lymphoma expresses follicular T-cell markers. *Am J Surg Pathol* 2009;33:81–90.