

# Syncope and Twitching at the Emergency Department

Authors' Contribution:  
Study Design A  
Data Collection B  
Statistical Analysis C  
Data Interpretation D  
Manuscript Preparation E  
Literature Search F  
Funds Collection G

ADEF **Adrian Scutelnic**  
ADE **Ulrike Prange**  
DE **Simon Jung**  
ADEFG **Mirjam R. Heldner**

Department of Neurology, Inselspital, University Hospital and University of Bern, Bern, Switzerland

**Corresponding Author:** Adrian Scutelnic, e-mail: [adrian.scutelnic@insel.ch](mailto:adrian.scutelnic@insel.ch)  
**Conflict of interest:** None declared

**Patient:** Female, 49  
**Final Diagnosis:** Anti-LGI1 limbic encephalitis  
**Symptoms:** Seizure • sinus arrest  
**Medication:** —  
**Clinical Procedure:** Immunosuppression  
**Specialty:** Neurology





**Objective:** Rare co-existence of disease or pathology  
**Background:** Anti-LGI1 encephalitis is a type of autoimmune limbic encephalitis. This case report elucidates features of anti-LGI1 limbic encephalitis, focusing on clinical findings and outcome as well as on rarely reported sinus arrest and its pathophysiology.

**Case Report:** A 49-year-old female patient presented at the Emergency Department (ED) because of twitching and an acute confusional state. Initial neurological examination revealed cognitive disturbance with disorientation, inattention, and amnesic deficits. While in the ED, twitching of the right arm was observed and shortly thereafter she experienced a sinus arrest. A temporary cardiac pacemaker was implanted. Laboratory investigations demonstrated mild hyponatremia and positive LGI1-IgG antibodies in serum. An initial head MRI was unremarkable and electroencephalography showed epileptic seizure activity starting focally in the left hemisphere synchronous with the intermittent twitching of the right arm. A seizure-suppressant therapy with levetiracetam, valproate, and gabapentin was initiated, as well as an immunosuppressive pulse therapy with methylprednisolone followed by a tapering oral regimen of prednisolone. Within a few days, the seizures ceased. One month later, neurocognitive test results were back to normal. At 2 years, mild depressive symptoms and anxiety disorder were the main clinical problems, as well as episodic migraine-like headaches.

**Conclusions:** Repetitive focal dystonic seizures, confusion, amnesic deficits, sinus arrest, and mild-to-moderate hyponatremia are pathognomonic features of anti-LGI1 limbic encephalitis. Sinus arrest may occur because of a direct pathophysiological dysfunction of the structures involved in autonomic cardiac rhythm control or as an ictal or postictal phenomenon. Early diagnosis and initiation of immunosuppressive therapy are both of utmost importance for favorable clinical outcome.

**MeSH Keywords:** Epilepsy, Partial, Motor • Limbic Encephalitis • Syncope

**Full-text PDF:** <https://www.amjcaserep.com/abstract/index/idArt/916945>

 1597   4  19



## Background

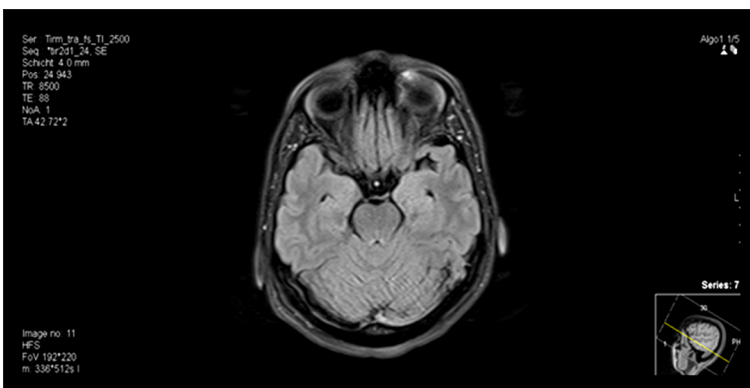
Anti-LGI1 encephalitis is a type of autoimmune limbic encephalitis. This case report elucidates features of anti-LGI1 limbic encephalitis, focusing on clinical findings and outcome as well as on rarely reported sinus arrest and its pathophysiology.

## Case Report

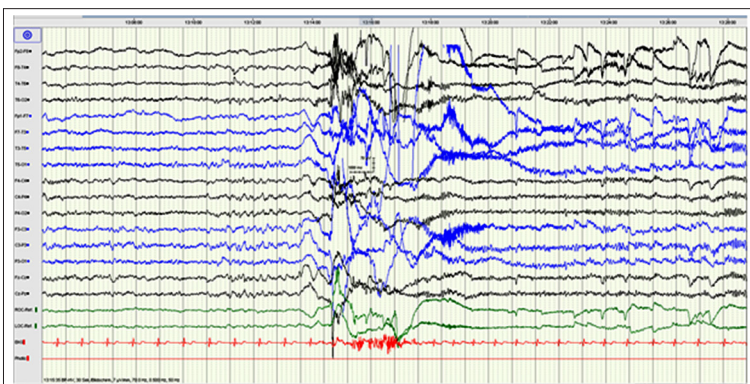
A 49-year-old female patient was taken to our Emergency Department (ED) because of twitching and an acute confusional state. On the day before admission, her daughter had found her staring at her without reaction for 5–6 s, then she started twitching with her arm(s) for several seconds and afterwards began to ask the same questions repeatedly, such as ‘Where am I?’.

The patient had last been seen the day before, appearing well. The week before, she had complained about an episode of vertigo. A subsequent outpatient continuous monitoring of the blood pressure had failed to show any arterial hypotonia, as initially suspected by the treating general practitioner. He then had proposed probatory betahistine, which the patient refused to take. The past medical and family history were unremarkable.

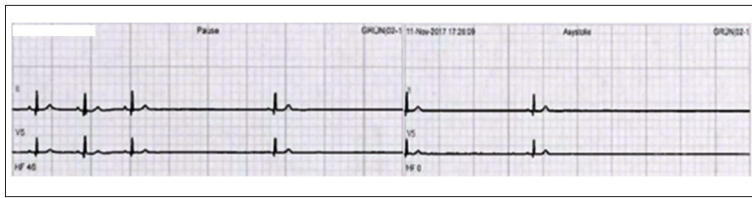
On initial neurological examination at our ED, the patient was disoriented to time, place, and situation, and was inattentive (e.g., calculating and spelling of single words backwards was not possible, and the forward digit-span was 3 out of 5 digits). Further pathological somatic neurological findings were absent. On admission, laboratory investigations displayed moderate hyponatremia (130 mmol/l, normal range 136–145 mmol) and a slight elevation of NT-proBNP (261pg/ml, normal <169 pg/ml). Creatinine, CRP, ASAT, GGT, LDH, creatinine-kinase, troponin-T, TSH, blood glucose, hemogram, and coagulation parameters were normal. A basic cerebrospinal examination revealed no abnormalities (protein 0.24 g/l, glucose 3.68 mmol/l, lactate 1.5 mmol/l, erythrocyte count  $<1 \times 10^6/l$ , cell-count  $1 \times 10^6/l$ , albumin 144 g/l, no intrathecal production of antibodies). Also, an MRI of the head (Figure 1) did not show any relevant pathology. However, while at our ED, intermittent involuntary dystonic twitches of the right arm were observed. They turned out to be focal seizures, as they correlated with electroencephalographic seizure activity starting focally in the contralateral left hemisphere (Figure 2). Also, while lying in our ED bed being monitored, a syncope due to a 17-s sinus arrest without ventricular escape beat emerged, preceded by a short period of sinus bradycardia without AV block (Figure 3). Therefore, the patient was transferred to the intensive care unit and a temporary cardiac pacemaker was implanted.



**Figure 1.** MRI of the head. FLAIR-sequence showing normal brain parenchyma including hippocampi.



**Figure 2.** Electroencephalography during a dystonic brachial seizure. Electroencephalography showing ictal event starting focally in the left hemisphere with underlying theta and delta waves in frontal and central location and left-dominant frontotemporal propagation including changes of frequency and amplitude and with steep alpha waves resulting in a dystonic brachial seizure clinically.



**Figure 3.** Electrocardiography. Sinus bradycardia without AV block followed by sinus arrest.

Antikörperanalytik	Methode	Einheit	Referenzbereich	Wert
<b>Erkrankungen des Nervensystems</b>				
NMDA (Glutamat)-Rezeptor	indir. Immunfl.	Titer	<1:10 negativ	<1:10 negativ
NMDA (Glutamat)-Rezeptor Liq.	indir. Immunfl.	Titer	negativ	<1:1
AMPA-1 (Glutamat)-Rezeptor	indir. Immunfl.	Titer	<1:10 negativ	<1:10 (1)
AMPA-2 (Glutamat)-Rezeptor	indir. Immunfl.	Titer	<1:10 negativ	<1:10 (1)
Lgi-1 (VGKC-assoziiert)	indir. Immunfl.	Titer	<1:10 negativ	1:80 (2)
CASPR-2 (VGKC-assoziiert)	indir. Immunfl.	Titer	<1:10 negativ	<1:10 (1)
GABA-Rezeptor B1/2	indir. Immunfl.	Titer	<1:10 negativ	<1:10 (1)
AMPA-1 (Glutamat)-Rezeptor Liq.	indir. Immunfl.	Titer	negativ	<1:1 (3)
AMPA-2 (Glutamat)-Rezeptor Liq.	indir. Immunfl.	Titer	negativ	<1:1 (3)
Lgi-1 (VGKC-assoziiert) Liq.	indir. Immunfl.	Titer	negativ	1:1 (3)
CASPR-2 (VGKC-assoziiert) Liq.	indir. Immunfl.	Titer	negativ	<1:1 (3)
GABA-Rezeptor B1/2 Liq.	indir. Immunfl.	Titer	negativ	<1:1 (3)

**Figure 4.** Panel with the most common antibodies causing limbic encephalitis. Positive LGI-1 antibodies in serum (1: 80). The technique used was indirect immunofluorescence using a commercial kit (Euroimmun Switzerland AG).

Further immune-serological investigations (Figure 4) revealed positive leucine-rich glioma inactivated (LGI)-1 antibodies in serum (1: 80, normal <1: 10). In the cerebrospinal fluid, the LGI-1 antibodies were negative, as were other investigations of infectious diseases, autoimmune, and paraneoplastic antibodies. Although anti-LGI-1 limbic encephalitis rarely is the result of a paraneoplastic process, a chest and abdomen CT and a gynecological evaluation were performed, which showed no evidence of cancer.

Intravenous pulse therapy with 1 g methylprednisolone over 5 days followed by an oral regimen of prednisolone (1 mg/kg with tapering over 3 months) was initiated. At first, the seizure-suppressant therapy consisted of levetiracetam 1 g twice daily. Because of focal seizure persistence, gabapentin and valproate extended release (1200 mg/day each) were added. Under this treatment regimen, the seizures ceased within a few days. As no other episodes with sinus arrest occurred, the temporary cardiac pacemaker was removed after 9 days and the patient was transferred to our inpatient rehabilitation clinic. We observed inattention and impairment of short-term memory, as well as visuoconstruction and executive function impairment. Because of depressive symptoms, venlafaxine therapy was started.

One month later, neurocognitive testing was back to normal. One year later, the depressive symptoms, for which an outpatient psychiatric treatment was initiated and newly-occurred migraine-like headaches prevailed. For 2 years, the patient remained clinically seizure-free and there was no epileptic activity in routine electroencephalography. Therefore, gabapentin and levetiracetam were stopped but valproate extended release 1200 mg/day was continued because of persistent episodic migraine-like headaches. At 2 years, mild depressive symptoms and newly-occurred anxiety disorder were the main clinical problems, so the outpatient psychiatric treatment was continued.

## Discussion

The prerequisite for the correct diagnosis of an autoimmune anti-LGI-1 limbic encephalitis in this patient was a high clinical suspicion due to the combination of repetitive focal dystonic seizures, confusion, amnesic deficits, sinus arrest, and mild- to-moderate hyponatremia at presentation. However, the unremarkable MRI of the head and the normal basic cerebrospinal fluid results were challenging.

In a case series of anti-LGI1 encephalitis including 38 patients, hippocampal lesions were seen in 74% of patients, an unremarkable basic cerebrospinal fluid examination result was seen in 75%, and hyponatremia was seen in 65% [1].

In the early stage of the disease, the diagnosis is best recognized on clinical grounds [1,2–7]. Faciobrachial dystonic seizures (abr. FBDS) are considered as pathognomonic for anti-LGI1 limbic encephalitis [5]. The isolated involvement of one arm, as in our patient, has been reported before [4]. There may also be other epileptic seizures with temporal focus and possibly secondary generalization and impaired consciousness, cognitive impairment (e.g., of short-term memory, attention, and orientation), psychiatric symptoms (e.g., paranoia, depression, dysphoria, anxiety, and visual hallucinations), sleep disorders, and autonomic dysfunction (e.g., cardiac arrhythmia, sexual dysfunction, and sweating).

Syncope has been previously described in association with limbic encephalitis, mostly of the anti-NMDA, but also GABA-B-receptor type [8–12]. We have found 4 published cases with syncope [13,14] and 2 with bradycardia [3] caused by anti-LGI1 limbic encephalitis. The predominant mechanism has been identified as sinus arrest preceded by sinus dysrhythmia/bradycardia [10,12].

Different pathophysiological mechanisms for sinus arrest in limbic encephalitis have been discussed.

On the one hand, a direct pathophysiological dysfunction of the structures that play a role in autonomic cardiac rhythm control seems plausible, since attacked receptors are expressed in them as follows [6,15]: NMDA-receptors are scattered along the intra-cardiac conduction system, the vagal nuclei and the nucleus of the solitary tract (NTS) [12]. The GABA-B-receptors also have been found in the NTS and vagal nuclei [10]. LGI1 protein is known to be present throughout the neocortex, such as in the temporal lobe, the insular region, the hippocampus, and the hypothalamus [7,13,14,16]. These structures play an important role in central regulation of autonomic function [15]. On the other hand, sinus arrest in limbic encephalitis might also be an ictal or postictal phenomenon since it affects the temporal lobe. This has been thoroughly elucidated before [15].

In our patient, the episode of vertigo 1 week before admission possibly was a first manifestation of cardiac arrhythmia (but not retrospectively verifiable) related to the autoimmune anti-LGI-1 limbic encephalitis. The etiology of the proven sinus arrest remains uncertain. The sinus arrest happened after onset of focal seizures and confusional state and not as a prodromal phenomenon or after a vagal stimulus, as also has been depicted in the literature [13,14].

Seizures ceased in our patient within a few days of treatment, but this happens in only around 10% of patients with anti-LGI1 limbic encephalitis, despite seizure-suppressant therapy, and in 51% and 88% after 30 and 90 days, respectively, in patients receiving additional immunosuppressive therapy [6]. Also, our patient fully recovered cognition, although only about 35% of patients do so [17].

In described disease progression, unilateral tonic-dystonic seizures first occur, then they become bilateral, there may be frontal or temporal lobe epilepsy, and persistent cognitive impairment and status epilepticus finally develop [4]. An association between faciobrachial dystonic seizures duration and cognitive impairment has also been described. Cognitive impairment is reported in 38% of patients after 30 days, and in 56% of patients after 90 days [6].

The good recovery in our patient was likely due to the disease being at its initial stage upon admission and due to early initiation of immunosuppressive therapy, which are both of utmost importance for favorable clinical outcome [4–6,18].

There are currently no randomized trials of long-term immunosuppression in patients with anti-LGI1 limbic encephalitis [19]. Observational studies have shown a benefit. However, in our patient, we decided on the therapy regime described above because we wished to lower the risk of potential relevant adverse effects of long-term immunosuppression. Because there was good clinical recovery and no relapses, we did not have to reinstate immunosuppression.

LGI-1 antibodies in CSF were negative in our patient, highlighting the higher sensitivity of detection of anti-LGI1 antibodies in serum compared to CSF [3,8]. Recently, it also has been discovered that involvement of anti-LGI1 IgG1 antibodies, which fixate complement, is associated with worse cognitive impairment and long-term disability than with involvement of non-fixating complement anti-LGI1 IgG4 antibodies [6]. In our patient, we investigated total anti-LGI1 IgG antibodies only.

To date, 2 years after disease onset, there was no evidence of any relapse in our patient in the outpatient follow-up visits. Because of considerable relapse rates (27% [17] according to Ariño et al. and 35% [1] according to van Sonderen et al.) and the relatively long time-span in which relapses may occur (up to 8 years [1] after disease onset), a long-term outpatient follow-up is also of importance.

To the best of our knowledge, psychiatric symptoms as an outcome parameter and onset of migraine-like headaches after anti-LGI1 limbic encephalitis have not yet been explored in literature. However, the latter likely is a secondary headache phenomenon.

## Conclusions

At an early stage, the diagnosis of anti-LGI1 limbic encephalitis is easy to miss. However, repetitive focal dystonic seizures, confusion, amnesic deficits, sinus arrest, and hyponatremia combined are highly pathognomonic of anti-LGI1 limbic encephalitis. Sinus arrest may occur because of a direct pathophysiological dysfunction of the structures involved in autonomic cardiac rhythm control or as an ictal or postictal phenomenon. Early recognition of the disease and timely treatment initiation are of utmost importance for favorable clinical outcome.

## Conflicts of interest

None.

## References:

1. Van Sonderen A, Thijs RD, Coenders EC et al: Anti-LGI1 encephalitis, clinical syndrome and long-term follow-up. *Neurology*, 2016; 87: 1449–56
2. Wang M, Cao X, Liu Q et al: Clinical features of limbic encephalitis with LGI1 antibody. *Neuropsychiatr Dis Treat*, 2017; 13: 1589–96
3. Li W, Wu S, Meng Q et al: Clinical characteristics and short-term prognosis of LGI1 antibody encephalitis: A retrospective case study. *BMC Neurol*, 2018; 18: 96
4. Navarro V, Kas A, Apartis E et al: Motor cortex and hippocampus are the two main cortical targets in LGI1-antibody encephalitis. *Brain*, 2016; 139: 1079–93
5. Irani SR, Buckley C, Vincent A et al: Immunotherapy-responsive seizure-like episodes with potassium channel antibodies. *Neurology*, 2008; 71: 1647–48
6. Thompson J, Bi M, Murchison AG et al: The importance of early immunotherapy in patients with faciobrachial dystonic seizures. *Brain*, 2018; 141: 348–56
7. Irani SR, Alexander S, Waters P et al: Antibodies to Kv1 potassium channel-complex proteins leucine-rich, glioma inactivated 1 protein and contactin-associated protein-2 in limbic encephalitis, Morvan's syndrome and acquired neuromyotonia. *Brain*, 2010; 133: 2734–48
8. Lee M, Lawn N, Prentice D, Chan J: Anti-NMDA receptor encephalitis associated with ictal asystole. *J Clinical Neurosci*, 2011; 18: 1716–18
9. Mehr S, Neeley RC, Wiley M, Kumar AB: Profound autonomic instability complicated by multiple episodes of cardiac asystole and refractory bradycardia in a patient with Anti-NMDA encephalitis. *Case Rep Neurol Med*, 2016; 2016: 7967526
10. Ovens C, Jayamanne A, Duggins A: Gamma-aminobutyric acid-B limbic encephalitis and asystolic cardiac arrest: A case report. *J Med Case Rep*, 2017; 11: 361
11. Millichap JJ, Goldstein JL, Laux LC et al: Ictal Asystole and anti-N-Methyl-D-aspartate receptor antibody encephalitis. *Pediatrics*, 2011; 127: e781–86
12. Nazif TM, Vázquez J, Honig LS, Dizon JM: Anti-N-methyl-D-aspartate receptor encephalitis: An emerging cause of centrally mediated sinus node dysfunction. *Europace*, 2012; 14: 1188–94
13. Nilsson AC, Blaabjerg M: More evidence of a neurocardiac prodrome in anti-LGI1 encephalitis. *J Neurol Sci*, 2015; 357: 310–11
14. Naasan G, Irani SR, Bettcher BM et al: Episodic bradycardia as neurocardiac prodrome to voltage-gated potassium channel complex/leucine-rich, glioma inactivated 1 antibody encephalitis. *JAMA Neurol*, 2014; 71: 1300–4
15. Britton JW, Benarroch E: Seizures and syncope: Anatomic basis and diagnostic considerations. *Clin Auton Res*, 2006; 16: 18–28
16. Schulte U, Thumfart JO, Klöcker N et al: The Epilepsy-Linked Lgi1 protein assembles into presynaptic Kv1 channels and inhibits inactivation by Kvb1. *Neuron*, 2006; 49: 697–706
17. Ariño H, Armangué T, Petit-Pedrol M et al: Anti-LGI1 – associated cognitive impairment. Presentation and long-term outcome. *Neurology*, 2016; 87: 759–65
18. Finke C, Prüss H, Heine J et al: Evaluation of cognitive deficits and structural hippocampal damage in encephalitis with leucine-rich, glioma-inactivated 1 antibodies. *JAMA Neurology*, 2017; 74: 50–59
19. Hermetter C, Fazekas F, Hochmeister S: Systematic review: Syndromes, early diagnosis, and treatment in autoimmune encephalitis. *Front Neurol*, 2018; 9: 706