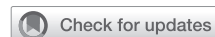

How I do it: Multiport video-assisted thoracoscopic surgery of the right middle lobe for non-small cell lung cancer: Right middle lobectomy in 12 steps



Emily L. Polhemus, BS, Daniel P. Dolan, MD, Daniel N. Lee, BS, Hassan A. Khalil, MD, Abby A. White, DO, and Scott J. Swanson, MD, Boston, Mass

From the Division of Thoracic and Cardiac Surgery, Department of Surgery, Brigham & Women's Hospital, Boston, Mass.

Disclosures: Dr Swanson discloses relationships as a consultant for Ethicon and Medtronic. All other authors reported no conflicts of interest.

The *Journal* policy requires editors and reviewers to disclose conflicts of interest and to decline handling or reviewing manuscripts for which they may have a conflict of interest. The editors and reviewers of this article have no conflicts of interest.

Received for publication April 27, 2021; revisions received Dec 7, 2021; accepted for publication Feb 17, 2022; available ahead of print April 2, 2022.

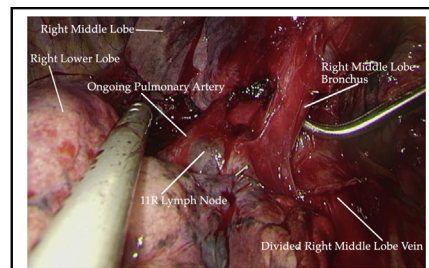
Address for reprints: Scott J. Swanson, MD, Division of Thoracic and Cardiac Surgery, Department of Surgery, Brigham & Women's Hospital, 75 Francis St, Boston, MA 02115 (E-mail: sjswanson@bwh.harvard.edu).

JTCVS Techniques 2022;14:130-5

2666-2507

Copyright © 2022 The Authors. Published by Elsevier Inc. on behalf of The American Association for Thoracic Surgery. This is an open access article under the CC BY-NC-ND license (<http://creativecommons.org/licenses/by-nc-nd/4.0/>).

<https://doi.org/10.1016/j.jtc.2022.02.035>



Intraoperative image of preparation of right middle lobe pulmonary bronchus for division.

CENTRAL MESSAGE

Multiport video-assisted thoracoscopic surgery: lobectomy of the right middle lobe for non-small cell lung cancer as demonstrated by Dr Scott J. Swanson.

See Commentary on page 136.

Video clip is available online.

Right middle lobe (RML) lobectomy for non-small cell lung cancer (NSCLC) is the least commonly performed lobectomy at 5% to 10%.^{1,2} RML lobectomy is not infrequently performed as a bilobectomy if tumors are located close to the RML anatomy and right upper or lower lobectomy alone is not feasible. Sublobar resection of the RML for small NSCLC is feasible but has worse outcomes as tumor size increases.³ Current randomized trials are ongoing to prospectively evaluate these retrospective findings.⁴

Video-assisted thoracoscopic surgery (VATS) for RML lobectomy can be difficult due to the infrequency with which the operation is performed. However, using the techniques shown here, the operation can be made relatively straightforward, requiring few additional tools outside of the normal VATS operation. We have previously described the technique elsewhere.^{5,6} Here, the VATS RML lobectomy operative technique is explained with videos of the 12 key steps. This procedure can be performed safely using modifications and variations of these steps.

METHODS

The VATS approach to RML lobectomy is described in 12 steps with accompanying video taken from one operation of a patient who presented with a 2 × 2.5-cm right middle lobe opacity (Figure 1). The specific steps

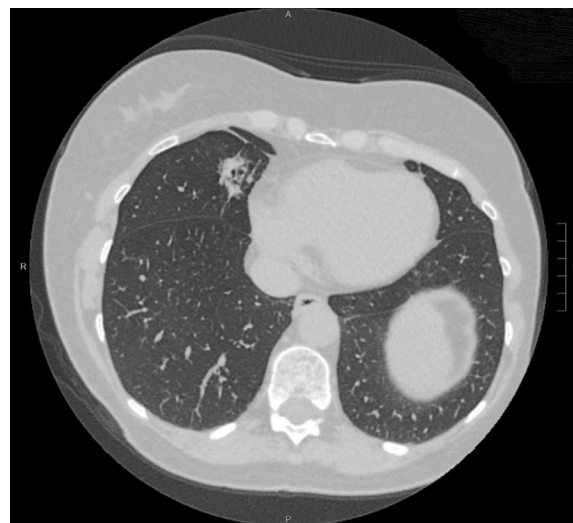

FIGURE 1. Preoperative coronal computed tomography of right middle lobe adenocarcinoma




FIGURE 2. A, Echelon 45-mm endoscopic stapler, regular/thick tissue stapler loads (Gold). B, Endoleader (8 Fr catheter with 0 silk). C, Harmonic Ultrasonic scalpel. D, CONMED laparoscopic suction-irrigator. E,

were chosen based on the authors' experience and the way the operation is taught in the authors' institution. The instruments used in this procedure are listed in [Figure 2](#).

RESULTS

The RML lobectomy presented here was performed in a 60-year-old female patient with chronic obstructive pulmonary disease who, as previously stated, presented with a 2 × 2.5-cm right middle lobe opacity ([Figure 1](#)). Biopsy confirmed adenocarcinoma. She underwent uneventful surgical resection. A case instrument card for the procedure with key tools is included in [Table 1](#). The final pathology for the lesion noted overall size of 2.6 × 1.8 × 1.6 cm with an invasive component size of 1.7 cm, staged as pT1bN0. This study, including patient information, was approved by our institutional review board under IRB2006P002482 and informed consent was waived. In addition, the patient consented to deidentified pictures and videos collected during this procedure; Brigham and Women's is a teaching hospital, and this practice is standard and included in procedure consent, which was obtained prior to surgery.

STEP 1: PORT PLACEMENT, EXPLORATION, AND PALPATION OF NODULE

Video 1: The patient is placed in left lateral decubitus position and prepped and draped in a sterile fashion. The first incision is made in the eighth intercostal space posterior to the anterior axillary line and is approximately 2 cm long. The second incision is made in the fifth or sixth intercostal space just anterior to the anterior axillary line, directly over the right middle lobe vein and right major fissure. This incision is approximately 4 cm long, and this port is used for the wound protector and later the endo-stapler. The third incision is made in the sixth or seventh intercostal space, posterior to the tip of the scapula just anterior to the anterior border of latissimus dorsi muscle, and is approximately 2 cm long. Notably, the second incision is typically 1 or 2 interspaces lower than that made for an upper lobectomy, as it facilitates dissection of the middle lobe bronchus and vein. The lesion is then palpated through the anterior incision.

STEP 2: RML VEIN DISSECTION

Video 2: The lung is retracted from the posterior port site and dissection of the RML vein is begun by identifying it, which is typically a small branch of the superior pulmonary vein. Alternatively, although rarely, the vein can be found as a branch of the inferior pulmonary vein or have its own trunk directly off the left atrium. In this video, the phrenic

← CONMED laparoscopic Kittner dissector. F, Echelon 35-mm endoscopic stapler, vascular/thin tissue stapler load (White).

TABLE 1. Case card with key tools for video-assisted thoroscopic surgery of the right middle lobe

Tool	Company	Location
Bovie electrocautery	Bovie Medical Corporation	Clearwater, Fla
Set of 3 metal thoroscopic trocars	Snowden-Pencer, Inc	Tucker, Ga
Ring forceps	Symmetry Surgical, Inc	Antioch, Tenn
Army-Navy retractors	Symmetry Surgical, Inc	Antioch, Tenn
Medium sized wound protector	Applied Medical	Rancho Santa Margarita, Calif
Laparoscopic Kittner dissectors	CONMED	Utica, NY
Laparoscopic suction-irrigator	CONMED	Utica, NY
Long right-angle clamp	Symmetry Surgical, Inc	Antioch, Tenn
Harmonic ultrasonic scalpel	Ethicon, Inc	Raritan, NJ
Endoleader (8 Fr catheter with 0 silk)	Medtronic	Fridley, Minn
Echelon 45 mm endoscopic stapler, regular/ thick tissue stapler loads (Gold)	Ethicon, Inc	Raritan, NJ
Echelon 35-mm endoscopic stapler, vascular/ thin tissue stapler load (White)	Ethicon, Inc	Raritan, NJ
Right angle clamp	Symmetry Surgical, Inc	Antioch, Tenn
Laparoscopic surgical tissue pouch	Cook Medical, Inc	Bloomington, Ind
24-Fr straight chest tube	Medtronic	Fridley, Minn

nerve is swept medially away from the anterior hilar pleura. This manipulation is not always necessary.

After dissecting the inferior and superior boundaries of the vein using blunt dissection with a laparoscopic Kittner (Figure 2), the right-angle clamp is used to dissect posteriorly around the RML vein.

STEP 3: RIGHT MAJOR FISSURE DISSECTION

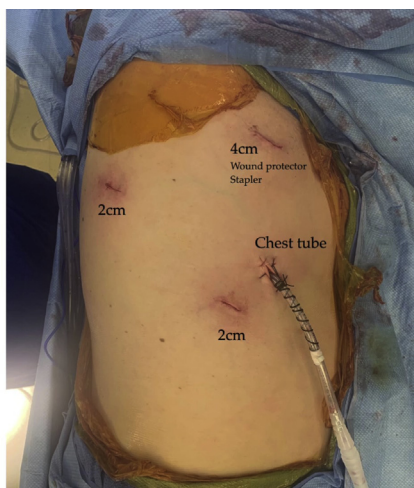
Video 3: The lung is retracted via the anterior port and careful dissection with a laparoscopic Kittner is used to develop the right major fissure. The ongoing pulmonary artery is uncovered. Identification of the RML bronchus is key

to avoid injury during subsequent division of the anterior fissure. The basilar trunk of the pulmonary artery and underlying bronchus denote the lateral extent of the fissure and the major fissure parenchyma is encircled and divided with the endoscopic stapler.

Note: The major fissure may not be complete and, to avoid potential alveolar leaks, a fissure-less technique may be used where the lung parenchyma is lifted off the ongoing pulmonary artery and then divided after identification, dissection, and division of the RML vein and bronchus.

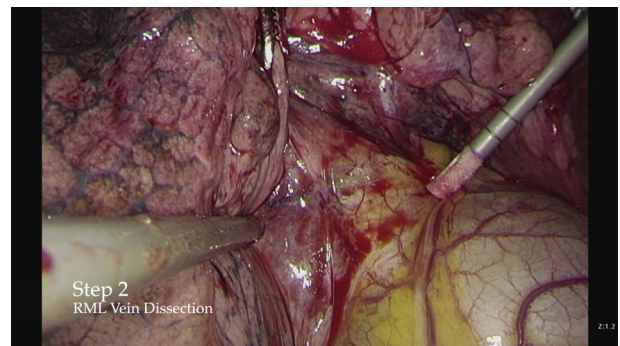
STEP 4: RML VEIN DIVISION

Video 4: The RML vein can now be seen anterior to the RML bronchus. Through the 4-cm port, the endoscopic

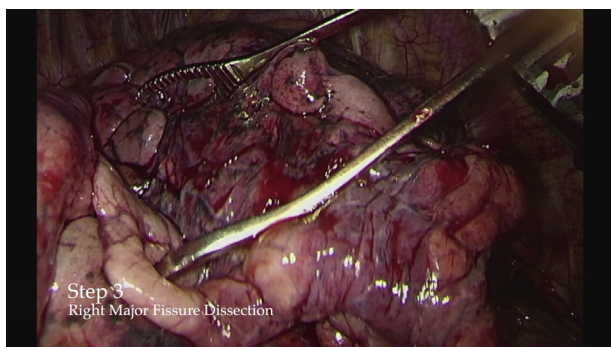


Left Lateral Decubitus

VIDEO 1. Video available at: [https://www.jtcvs.org/article/S2666-2507\(22\)00179-1/fulltext](https://www.jtcvs.org/article/S2666-2507(22)00179-1/fulltext).



VIDEO 2. Video available at: [https://www.jtcvs.org/article/S2666-2507\(22\)00179-1/fulltext](https://www.jtcvs.org/article/S2666-2507(22)00179-1/fulltext).



VIDEO 3. Video available at: [https://www.jtcvs.org/article/S2666-2507\(22\)00179-1/fulltext](https://www.jtcvs.org/article/S2666-2507(22)00179-1/fulltext).

stapler is carefully passed around the RML vein, which is then stapled and divided using a vascular/thin staple load.

STEP 5: RML BRONCHUS DISSECTION

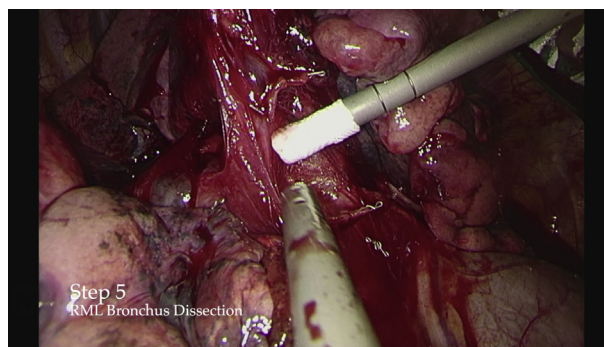
Video 5: The RML bronchus is visualized with the RML artery now clearly seen superior and posterior to the divided RML vein. Careful blunt dissection is carried out between the RML bronchus and artery. The ongoing pulmonary artery is seen traveling down the minor fissure, passing around the bronchus, and progressing anteriorly along the major fissure.

STEP 6: RML BRONCHUS DIVISION

Video 6: The right-angle clamp is used to pass the endoleader to facilitate the approach of the endoscopic stapler, again through the 4-cm port. The stapler is guided into position and the RML retracted to allow clean division of the RML bronchus using a regular/thick stapler load. The endoleader allows passage of the stapler safely when the space between the RML artery and bronchus is challenging or if there is difficult angulation of the stapler.

STEP 7: RML ARTERY DISSECTION

Video 7: Blunt dissection is used to encircle the RML artery. The right-angle clamp is used to ensure adequate space



VIDEO 5. Video available at: [https://www.jtcvs.org/article/S2666-2507\(22\)00179-1/fulltext](https://www.jtcvs.org/article/S2666-2507(22)00179-1/fulltext).

to pass the stapler around the artery. Note: Anatomic variation of 2 or more RML arteries can occur, and potential presence of these variants must be assessed before proceeding to arterial division. Care should be taken to isolate the RML artery (or arterial branches) to make sure no upper lobe branches of the right superior pulmonary vein will be divided when the RML artery is divided in the next step.

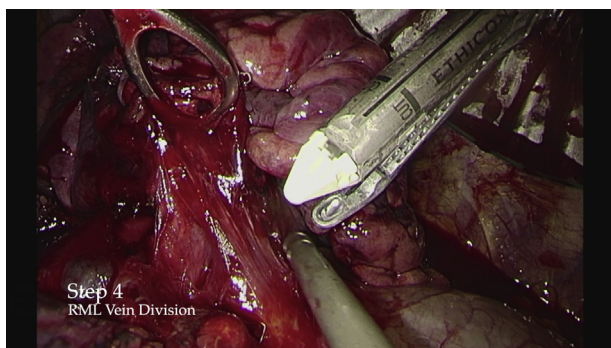
STEP 8: RML ARTERY DIVISION

Individual Branch Division

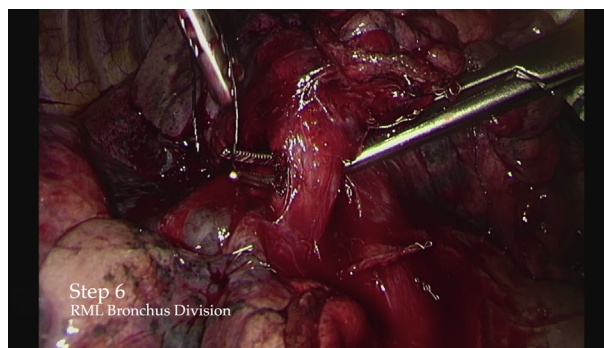
Video 8: The stapler is passed around the RML artery, which is then stapled and divided using a vascular/thin staple load.

Alternative Division of RML Artery: En Bloc Division With Incomplete Minor Fissure

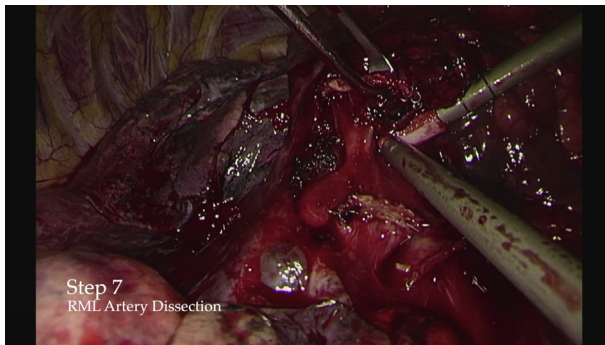
Video 9: In some rare cases in which the preferred method of individual RML artery dissection and division is not possible, for example, due to an incomplete minor fissure or due to concerns that further dissection would cause damage to surrounding structures, an en bloc division can be done. In this alternate approach, an incomplete minor fissure is noted along with at least 2 small arterial branches. If the tumor is well away from the minor fissure, it may be appropriate to divide the smaller arteries en bloc with the



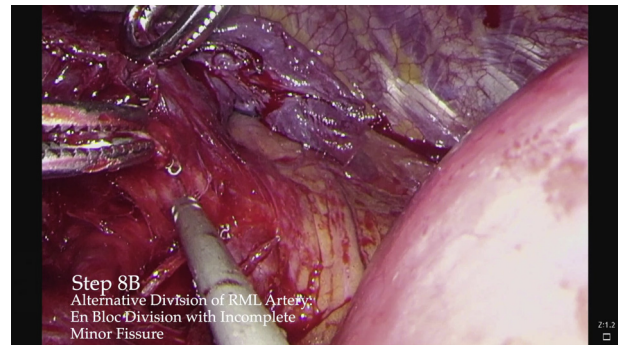
VIDEO 4. Video available at: [https://www.jtcvs.org/article/S2666-2507\(22\)00179-1/fulltext](https://www.jtcvs.org/article/S2666-2507(22)00179-1/fulltext).



VIDEO 6. Video available at: [https://www.jtcvs.org/article/S2666-2507\(22\)00179-1/fulltext](https://www.jtcvs.org/article/S2666-2507(22)00179-1/fulltext).



VIDEO 7. Video available at: [https://www.jtcvs.org/article/S2666-2507\(22\)00179-1/fulltext](https://www.jtcvs.org/article/S2666-2507(22)00179-1/fulltext).



VIDEO 9. Video available at: [https://www.jtcvs.org/article/S2666-2507\(22\)00179-1/fulltext](https://www.jtcvs.org/article/S2666-2507(22)00179-1/fulltext).

minor fissure, and avoid injury related to the dissection and passage of the large stapler behind smaller vessels. The RML vein and bronchus have previously been divided.

STEP 9: MINOR FISSURE

Video 10: The RML is reflected inferiorly and the stapler used to complete the division of the minor fissure between the right upper and middle lobes, taking care to ensure that the middle lobe bronchial stump is included in the specimen. Depending on the completeness of the fissure, multiple regular/thick tissue staple loads may be required to divide the remaining parenchyma. The Harmonic scalpel is used to divide the remaining soft tissue connecting the RML specimen to the right upper lobe.

STEP 10: REMOVAL OF RML FROM CHEST

Video 11: The LapSac (Cook Medical) is inserted through the anterior port and placed in the right apex with the opening toward the base of the lung. The RML specimen is then guided into the sack and the sack closed. The specimen and sack are then extracted.

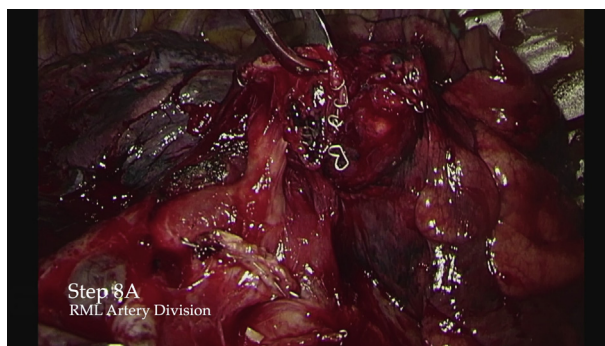STEP 11: LYMPH NODE DISSECTION

Video 12: Mediastinal lymph node dissection can be performed at various points of the operation. In the first portion

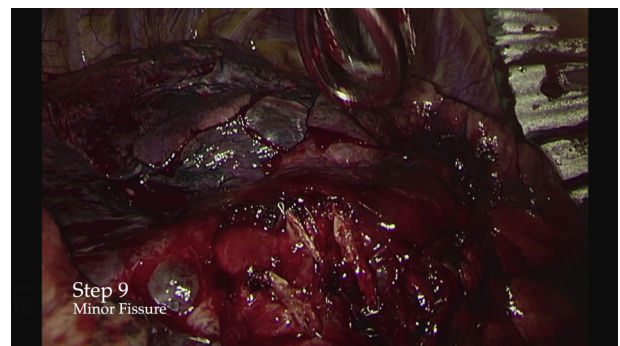
of **Video 12**, the right lung is reflected anteriorly to facilitate dissection of level 7 lymph nodes. In the next portion of the video, 11R lymph nodes are being removed from the area adjacent to the RML bronchus after the RML specimen has been removed. Finally, a right paratracheal lymph node dissection was performed, 4R. At this point, stations 8R and 9R can be sampled as well, but are not shown in this video.

STEP 12: STUMP CHECK AND LUNG REINFLATION

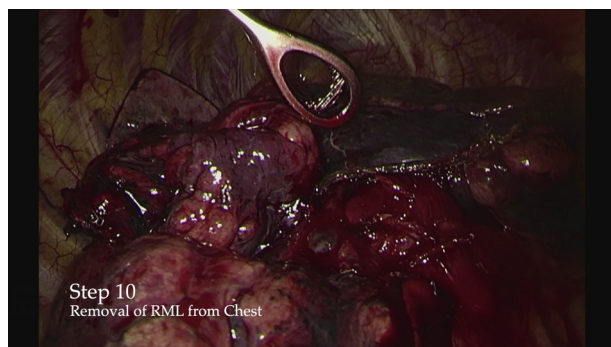
Video 13: The suction-irrigator (CONMED) is used to submerge the RML bronchial stump. The lung is then re-inflated to a pressure of 30 cmH₂O to perform a stump air-leak check. No bubbling is seen and the air-leak check is negative. The fluid is then removed. A 24-Fr chest tube can be placed through the inferior incision to the right thoracic apex running anterior to the hilum or a new chest tube insertion site can be made as seen in the video for Step 1. Although the air-leak check is negative in this procedure, if it were positive, sutures could be placed to reinforce closure and a second stump check would be performed.



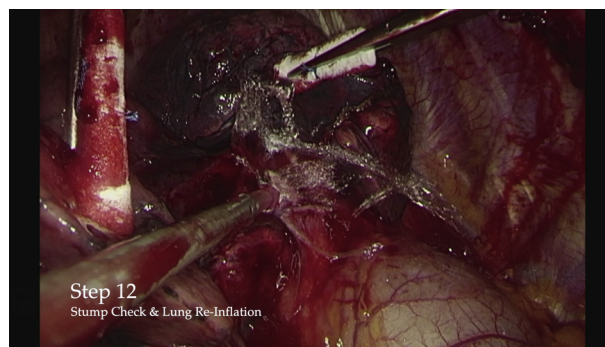
VIDEO 8. Video available at: [https://www.jtcvs.org/article/S2666-2507\(22\)00179-1/fulltext](https://www.jtcvs.org/article/S2666-2507(22)00179-1/fulltext).



VIDEO 10. Video available at: [https://www.jtcvs.org/article/S2666-2507\(22\)00179-1/fulltext](https://www.jtcvs.org/article/S2666-2507(22)00179-1/fulltext).



VIDEO 11. Video available at: [https://www.jtcvs.org/article/S2666-2507\(22\)00179-1/fulltext](https://www.jtcvs.org/article/S2666-2507(22)00179-1/fulltext).



VIDEO 13. Video available at: [https://www.jtcvs.org/article/S2666-2507\(22\)00179-1/fulltext](https://www.jtcvs.org/article/S2666-2507(22)00179-1/fulltext).

DISCUSSION

VATS lobectomy is the standard of care for early-stage lung cancer, and numerous studies have demonstrated its oncologic efficacy and superiority over thoracotomy with respect to complications and return to function.²⁻⁷ The National Comprehensive Cancer Network guidelines recommend a minimally invasive approach whenever possible and robotic approaches appear to offer similar advantages.¹

A key hazard to note for VATS RML lobectomy regards damage to the ongoing pulmonary artery and lower lobe bronchus, potentially during division of an incomplete major fissure. This complication is thankfully rare due to thoughtful diligence of surgeons, but attention is drawn to this potential issue to continue the rarity of this complication. Another concern is distorting or obstructing the lower-lobe bronchus while dividing the middle lobe bronchus. This can be avoided by inflating the right lower lobe while clamping the middle lobe bronchus or using bronchoscopic guidance. Also, unlike the typical conduct of other lobectomies, the bronchus is divided after the vein, which

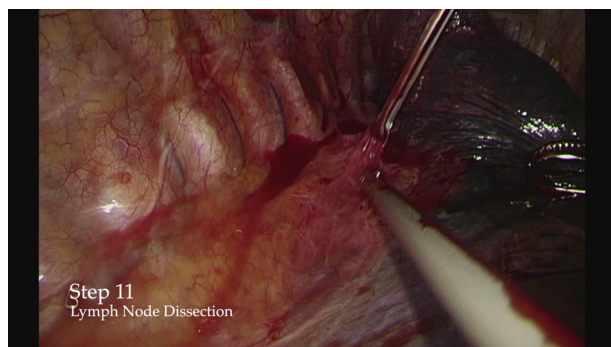
inherently means the artery or arteries to the middle lobe have not yet been secured while dissecting the middle lobe bronchus immediately in front of them. Care must be taken to identify and avoid direct or avulsion injuries to the artery while dividing the bronchus. We find the placement of the posterior port to be especially useful for this particular dissection and division.

CONCLUSIONS

VATS right middle lobectomy can be performed safely and reliably with the steps outlined in this manuscript.

References

1. Yang CF, Sun Z, Speicher PJ, Saud SM, Gulack BC, Hartwig MG, et al. Use and outcomes of minimally invasive lobectomy for stage I non-small cell lung cancer in the national cancer data base. *Ann Thorac Surg.* 2016;101:1037-42. <https://doi.org/10.1016/j.athoracsur.2015.11.018>
2. Falcoz P-E, Puyraveau M, Thomas P-A, Decaluwe H, Hürtgen M, Petersen RH, et al. Video-assisted thoracoscopic surgery versus open lobectomy for primary non-small-cell lung cancer: a propensity-matched analysis of outcome from the European Society of Thoracic Surgeon database. *Eur J Cardiothorac Surg.* 2016;49:602-9.
3. Lv X, Cao J, Dai X, Rusidanmu A. Survival rates after lobectomy versus sublobar resection for early-stage right middle lobe non-small cell lung cancer. *Thorac Cancer.* 2018;9:1026-31. <https://doi.org/10.1111/1759-7714.12782>
4. Comparison of Different Types of Surgery in Treating Patients With Stage IA Non-Small Cell Lung Cancer (Alliance for Clinical Trials in Oncology). Accessed April 13, 2021. <https://clinicaltrials.gov/ct2/show/NCT00499330>
5. Hirji SA, Nicastrì DG, Swanson SJ. VATS lobectomy and segmentectomy. In: Sugarbaker DJ, Bueno R, Burt BM, Groth SS, Loor G, Wolf AS, eds. *Sugarbaker's Adult Chest Surgery*. 3rd ed. McGraw-Hill; 2020. Accessed April 14, 2021. <https://accesssurgery.mhmedical.com/content.aspx?bookid=2781§ionid=239711113>
6. McKenna R, Mahtabifard A, Swanson S. *Atlas of Minimally Invasive Thoracic Surgery (VATS)*. 1st ed. Elsevier/Saunders; 2011.
7. Swanson SJ, Herndon JE II, D'Amico TA, Demmy TL, McKenna RJ Jr, Green MR, et al. Video-assisted thoracic surgery lobectomy: report of CALGB 39802—a prospective, multi-institution feasibility study. *J Clin Oncol.* 2007;25:4993-7. <https://doi.org/10.1200/JCO.2007.12.6649>



VIDEO 12. Video available at: [https://www.jtcvs.org/article/S2666-2507\(22\)00179-1/fulltext](https://www.jtcvs.org/article/S2666-2507(22)00179-1/fulltext).