

Using a pedicle pectoralis major musculocutaneous flap in head and neck reconstruction after modified radical mastectomy

A case report

Jen-Wu Huang, MD^{a,b}, Nai-Yuan Wu, MD^c, Yi-Ying Lin, MD^{b,d,*}

Abstract

Rationale: A pedicle pectoralis major musculocutaneous (PMMC) flap is one of the strategies for head and neck reconstruction. Seldom studies reported the case in which the skin area of previous modified radical mastectomy (MRM) had been used as a PMMC flap in head and neck reconstruction.

Patient concerns: An 84-year-old female who had suffered from left breast cancer and undergone a left modified radical mastectomy (MRM) more than 20 years earlier.

Diagnoses: She had squamous cell carcinoma of the tongue and had undergone partial glossectomy and left modified radial neck dissection. Four months later, a left submandibular mass was noted with progressive enlargement and the biopsy revealed recurrent carcinoma.

Interventions: Left marginal mandibulectomy with radical neck dissection was performed and the neck area was reconstructed by a left pedicle PMMC flap harvested from the left chest wall which had the previous MRM scar.

Outcomes: The post-operative course was uneventful with complete survival of the flap. The patient received post-operative adjuvant radiotherapy at the left neck and no delayed wound disruption or flap necrosis was noted six months after surgery.

Lessons: A pedicle PMMC flap may be harvested to achieve a functionally as well as an aesthetically pleasing outcome without compromising its viability despite the previous MRM.

Abbreviations: MRM = modified radical mastectomy, PMMC = pectoralis major musculocutaneous, TRAM = transverse rectus abdominis musculocutaneous.

Keywords: breast cancer, head and neck reconstruction, modified radical mastectomy, pectoralis major musculocutaneous flap, perforator flap, tongue cancer

Editor: Bernhard Resch.

Ethical approval is not required for the case report, but this patient signed informed consent for publication. The patient provided written informed consent for publication of this report and all accompanying images.

The data supporting the conclusions of this article is included within the article.

J-WH performed the surgery and followed the patient; N-YW collected data and drafted the manuscript; Y-YL supervised the study and the entire clinical care. All authors read and approved the final manuscript.

The authors have no conflicts of interest to disclose.

^a Department of Surgery, National Yang-Ming University Hospital, National Yang-Ming University, Yi-Lan, ^b Institute of Emergency and Critical Care Medicine, School of Medicine, ^c Institute of Biomedical Informatics, National Yang-Ming University, ^d Department of Pediatrics, Heping Fuyou Branch, Taipei City Hospital, Taipei, Taiwan.

* Correspondence: Yi-Ying Lin, Department of Pediatrics, Heping Fuyou Branch, Taipei City Hospital, No. 33, Section 2, Zhonghua Road, Zhongzheng District, Taipei 10065, Taiwan (e-mail: ped125@gmail.com).

Copyright © 2017 the Author(s). Published by Wolters Kluwer Health, Inc. This is an open access article distributed under the terms of the Creative Commons Attribution-Non Commercial-No Derivatives License 4.0 (CCBY-NC-ND), where it is permissible to download and share the work provided it is properly cited. The work cannot be changed in any way or used commercially without permission from the journal.

Medicine (2017) 96:15(e6313)

Received: 16 November 2016 / Received in final form: 9 February 2017 /

Accepted: 10 February 2017

<http://dx.doi.org/10.1097/MD.0000000000006313>

1. Background

It is not uncommon to use a pedicle pectoralis major musculocutaneous (PMMC) flap for head and neck reconstruction. A pedicle PMMC flap is based on the pectoral branch of the thoracoacromial vessels. A literature search of published work over recent decades revealed no case report in which the skin area of previous modified radical mastectomy (MRM) had been used as a PMMC flap in head and neck reconstruction. The case we presented here is interesting not only because of its management but also its past history.

2. Case presentation

The patient was an 84-year-old female who had suffered from left breast cancer and undergone a left MRM more than 20 years earlier. She also had a history of diabetes mellitus that was under medical control. This time she had sustained squamous cell carcinoma of the tongue and had undergone partial glossectomy and left modified radial neck dissection. Four months later, a left submandibular mass was noted with progressive enlargement, and the biopsy revealed recurrent carcinoma. Thus, she was transferred to our tertiary care hospital and received left marginal mandibulectomy and radical neck dissection 6 months after primary operation. The ablation surgery resulted in major skin defect and great vessel exposure (Fig. 1). Because of the patient's

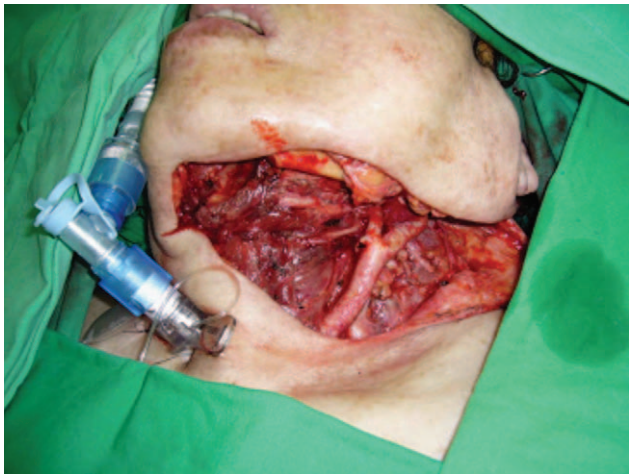


Figure 1. Neck skin defect with great vessels exposure after wide excision and radical neck dissection.

age and history of diabetes mellitus, we decided to reconstruct neck area by the use of a left pedicle PMMC flap, 10 cm × 6 cm, laid out on the left chest wall that had the MRM scar (Fig. 2A). After harvesting, blood circulation of the flap was confirmed and it was passed through a subcutaneous tunnel to cover the neck skin defect (Fig. 2B). The postoperative course was uneventful with complete survival of the flap. The patient received

postoperative adjuvant radiotherapy at the left neck and no delayed wound disruption or flap necrosis was noted 6 months after surgery (Fig. 3).

3. Discussion

The PMMC flap procedure was originally developed by Dr Ariyan in 1979 and has been widely used in the reconstruction of head and neck defects.^[1,2] Advantages of the PMMC flap include the adequate size, ease of harvesting, low donor-site morbidity, and proximity to the head and neck region. A cutaneous paddle can be used to reconstruct oral mucosa, skin, or both. Despite the recent advances in free flap surgery, the pedicle PMMC flap maintains a role in head and neck reconstruction, especially in conditions where free flaps fail or are contraindicated. In this case, we chose a pedicle PMMC flap for reconstruction because of the age of the patient and the diabetes mellitus comorbidity. The advantages of this procedure compared with a free flap are the shorter operation time, less donor site morbidity, and less need for postoperative intensive care and monitoring.

One disadvantage of the pedicle PMMC flap is the possible inconsistent blood circulation that could result in total or partial necrosis of the flap. Necrosis of a skin island is the most frequently encountered complication. Some authors have reported the rate of skin island necrosis to be between 7% and 27%.^[3,4] Before harvesting, we considered the possibility of partial or total skin paddle necrosis of the PMMC flap. But we decided a skin graft could be used to cover the left neck skin

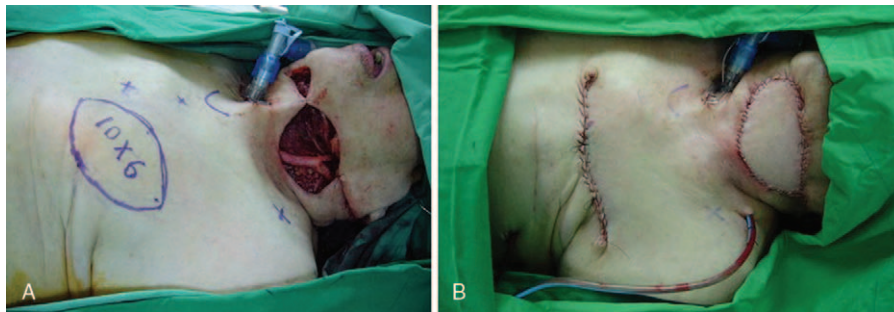


Figure 2. A 10 × 6 cm pedicle pectoralis major musculocutaneous flap was laid out over the left chest wall where modified radical mastectomy had been performed more than 20 years earlier (A). After harvesting, blood circulation of the flap was confirmed and it was passed through a subcutaneous tunnel to cover the neck skin defect (B).

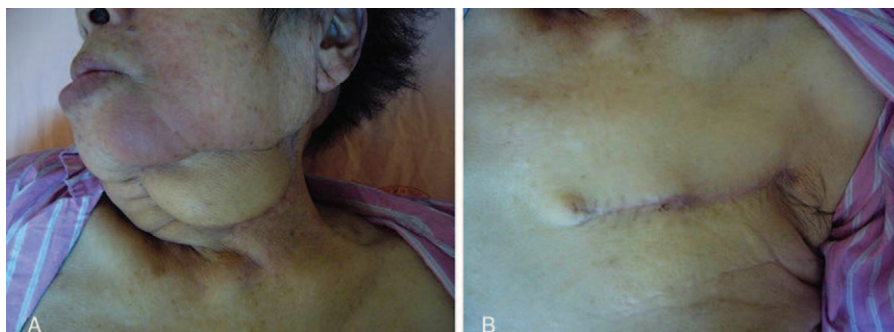


Figure 3. Six months after surgery, the pedicle pectoralis major musculocutaneous flap survived well despite adjuvant radiotherapy (A) and the donor site was stable (B).

defect, in the event that skin island necrosis did occur, because the great vessels would still be covered by the pectoralis muscle.

In our case, the pedicle PMMC flap was harvested from the surgical region of the previous MRM. This is similar to the concept of flap prefabrication. The overlying skin paddle is prefabricated by pedicle muscle as a vessel carrier. Angiogenesis, a major component of wound healing, begins in the first 24 hours after an injury.^[5] In 1995, Sozer et al^[6] reported 2 successful double-pedicle transverse rectus abdominis musculocutaneous (TRAM) flaps for breast reconstruction after a conventional abdominoplasty. Edington and Erol and Spira^[7,8] both reported that new perforator vessels develop within 30 days after the anterior abdominal wall is undermined. The exact time required to fully develop a perforator system is still unknown. Ribuffo et al^[9] reported that the perforator system was fully developed 1 month after surgery and the diameter of the arteries continued to grow for 6 months postoperatively. However, their diameter is always under 40% of a normal artery. In our case, the skin paddle had been prefabricated by the underlying pectoralis major muscle flap for more than 20 years. Clearly, the time it takes for a perforator system to develop fully after MRM remains to be determined. Underlying biomolecular mechanism of perforator growth deserves further investigation to promote the development of reconstructive medicine.

4. Conclusions

Even though similar clinical situation, a TRAM flap after previous abdominoplasty, has been reported in several studies,^[6,9-11] it has not been noted of a PMMC flap after previous MRM in head and neck reconstruction. In conclusion, a

pedicle PMMC flap may be harvested to achieve a functionally as well as an aesthetically pleasing outcome without compromising its viability despite the previous MRM.

References

- [1] Ariyan S. The pectoralis major myocutaneous flap. A versatile flap for reconstruction in the head and neck. *Plast Reconstr Surg* 1979;63:73–81.
- [2] Ariyan S. Further experiences with the pectoralis major myocutaneous flap for the immediate repair of defects from excisions of head and neck cancers. *Plast Reconstr Surg* 1979;64:605–12.
- [3] Mehta S, Sarkar S, Kavarana N, et al. Complications of the pectoralis major myocutaneous flap in the oral cavity: a prospective evaluation of 220 cases. *Plast Reconstr Surg* 1996;98:31–7.
- [4] Castelli ML, Pecorari G, Succo G, et al. Pectoralis major myocutaneous flap: analysis of complications in difficult patients. *Eur Arch Otorhinolaryngol* 2001;258:542–5.
- [5] Erol OO, Spira M. Development and utilization of a composite island flap employing omentum: experimental investigation. *Plast Reconstr Surg* 1980;65:405–18.
- [6] Sozer SO, Cronin ED, Biggs TM, et al. The use of the transverse rectus abdominis musculocutaneous flap after abdominoplasty. *Ann Plast Surg* 1995;35:401–11.
- [7] Edington HE. Wound Healing, in *Basic Science Review for Surgeons* (Simmons RL Steed DL, eds). 1992;WB Saunders, Philadelphia, PA:41–55.
- [8] Erol OO, Spira M. Reconstructing the breast mound employing a secondary island omental skin flap. *Plast Reconstr Surg* 1990;86:510–8.
- [9] Ribuffo D, Marcellino M, Barnett GR, et al. Breast reconstruction with abdominal flaps after abdominoplasties. *Plast Reconstr Surg* 2001;108:1604–8.
- [10] May JW Jr, Silverman RP, Kaufman JA. Flap perfusion mapping: TRAM flap after abdominal suction-assisted lipectomy. *Plast Reconstr Surg* 1999;104:2278–81.
- [11] Hess CL, Gartside RL, Ganz JC. TRAM flap breast reconstruction after abdominal liposuction. *Ann Plast Surg* 2004;53:166–9.