

# Application of Microautologous Fat Transplantation in the Correction of Sunken Upper Eyelid

Tsai-Ming Lin, MD, PhD\*†

Tsung-Ying Lin, MD†

Chih-Kang Chou, MD†‡

Chung-Sheng Lai, MD, PhD†

Sin-Daw Lin, MD†

**Background:** Although fat grafting has been clinically applied by surgeons in esthetic and reconstructive surgery, it has widely evolved in processes such as harvesting, processing, and placement of fat, using the fat-grafting procedure, which dates back over 100 years. Surgeons frequently use fat grafting to recontour, augment, or fill soft-tissue defects, facial wrinkles, or skin problems such as depressions or scars. However, fat grafting has not been thoroughly understood and has not been conclusively standardized to ensure superior clinical results.

**Methods:** This study was intended to determine the role of microautologous fat transplantation (MAFT) under evidence-based medicine, particularly in accurate delivery of small fat parcels. The research method involved the conceptualization of MAFT and the development of an innovative surgical instrument for fat placement. Clinically, 168 patients with sunken upper eyelids with multiple folds underwent this procedure.

**Results:** The major findings suggested that MAFT exhibits promising clinical results and offers a superior guideline for fat placement. Details of the technique and theoretical implications are also discussed.

**Conclusions:** The therapeutic effects of MAFT and the long-term clinical results of patients with sunken upper eyelids with multiple folds indicated satisfactory outcomes. Based on the results, MAFT offers an alternative option to surgeons for performing fat grafting and provides a more favorable option for the benefit and welfare of patients by reducing the potential complications. (*Plast Reconstr Surg Glob Open* 2014;2:e259; doi: 10.1097/GOX.0000000000000141; Published online 24 October 2014.)

In Asian people, the superior sulcus in the upper eyelid frequently becomes visible because of aging or overzealous removal of the orbital fat through blepharoplasty or other unknown etiologies. The hollow or sunken appearance is often accompanied by multiple eyelid folds, which result from variable insertion levels of levator palpebrae superioris, with consequent thinning of the skin and orbicularis oculi muscle and/or preaponeurotic fat atrophy. The coalescence of both phenomena results in a tired, weary, and even exhausted appearance.

From the \*Charming Institute of Aesthetic and Regenerative Surgery, Kaohsiung, Taiwan; †Department of Plastic Surgery, Kaohsiung Medical University, Kaohsiung, Taiwan; and ‡Department of Surgery, Yuan's General Hospital, Kaohsiung, Taiwan.

Received for publication November 30, 2013; accepted May 20, 2014.

Presented at 20th ISAPS, August 14–18, 2010, San Francisco; IPRAS, May 22–27, 2011, Vancouver, Canada; 1st ISPRES, March 9–11, 2012, Rome, Italy; and 3rd WAPSCD, October 12–14, 2013, Xi'an, China.

Certain strategies, such as autologous fat grafting, dermal fat grafting, or allogeneous dermal grafting, have been described and detailed in the literature for correcting the aforementioned problems.<sup>1–5</sup> Currently, numerous soft-tissue fillers are widely used despite their short duration of efficacy.<sup>6</sup> A reliable strategy with favorable long-term effects that leads to higher patient satisfaction and higher confidence of surgeons has not yet been developed.

Fat grafting was initially addressed over a century ago by Neuber.<sup>7</sup> Thereafter, fat-grafting techniques, methods, and protocols have been enhanced numerous times to improve the fat survival or fat retention

Copyright © 2014 The Authors. Published by Lippincott Williams & Wilkins on behalf of The American Society of Plastic Surgeons. *PRSGlobalOpen* is a publication of the American Society of Plastic Surgeons. This is an open-access article distributed under the terms of the Creative Commons Attribution-NonCommercial-NoDerivatives 3.0 License, where it is permissible to download and share the work provided it is properly cited. The work cannot be changed in any way or used commercially.

DOI: 10.1097/GOX.0000000000000141

rate.<sup>8-12</sup> Numerous surgical mentors in this field have investigated innovative methods for potentially improving fat grafting.<sup>13-17</sup>

In this article, we advocate a new concept of microautologous fat transplantation (MAFT) and its application in correcting sunken upper eyelids with multiple folds. The results indicated that MAFT facilitates reduced morbidity, higher patient satisfaction, and favorable long-term follow-up results.

## MATERIALS AND METHODS

### Patient Demography

A total of 168 patients (2 men and 166 women) received fat grafting for correction of sunken upper eyelids with multiple folds from September 2007 to September 2010 at the Charming Institute of Aesthetic and Regenerative Surgery, Kaohsiung, Taiwan. These patients were regularly followed up at the outpatient clinic. Preoperative and postoperative photographs taken at each visit were compared. In addition, complications such as calcification, fibrosis, nodulation, uneven skin (irregular surface), and cyst formation were meticulously recorded.

### Anesthetization

Unless accompanied with other major adjunct procedures, all patients were anesthetized using total intravenous anesthesia for the entire MAFT procedure. Concurrently, local anesthesia was administered at the incision sites (donor and recipient sites) by infiltrating 2% Xylocaine (Lidocaine Hydrochloride 20mg/ml, Oriental Co., Taiwan) with epinephrine (1:1000). The fat-harvesting area, primarily the lower abdomen, was preinfiltrated with a tumescent solution prepared at a ratio of 2% Xylocaine:Lactate Ringer solution:epinephrine (1:1000) = 10 mL:30 mL:0.2 mL.

### MAFT Procedure

#### Fat Harvesting

The donor area was preinfiltrated with a tumescent solution after the incisional site was anesthetized. Approximately 10 to 15 min after the tumescent solution was administered, a blunt-tip

cannula (diameter, 3 mm) was used to harvest the fat, and the lipoaspirated volume was the same as that of the infiltrated tumescent solution to achieve a high proportion of purified fat after centrifugation. To ensure minimal damage to the lipoaspirate, the plunger of a 10-mL Luer-Lok syringe was pulled back for 2 to 3 mL and maintained so that, while it was connected to the liposuction cannula, the reactive aspirating negative pressure was maintained between 270 and 330 mm Hg.<sup>18</sup>

#### Fat Processing and Refinement

For fat processing, various methods, such as the sieve method, multiple-layer gauze filtration, and centrifugation, have been proposed in the literature.<sup>19,20</sup> The internationally accepted Coleman's technique was used for processing the lipoaspirate through centrifugation because of its advantages of less environmental exposure and lower manual manipulation in the aseptic procedure.<sup>17</sup> A standard centrifugation of 3000 rpm, which was approximately 1200g for 3 minutes, was applied to process (purify) the fat.

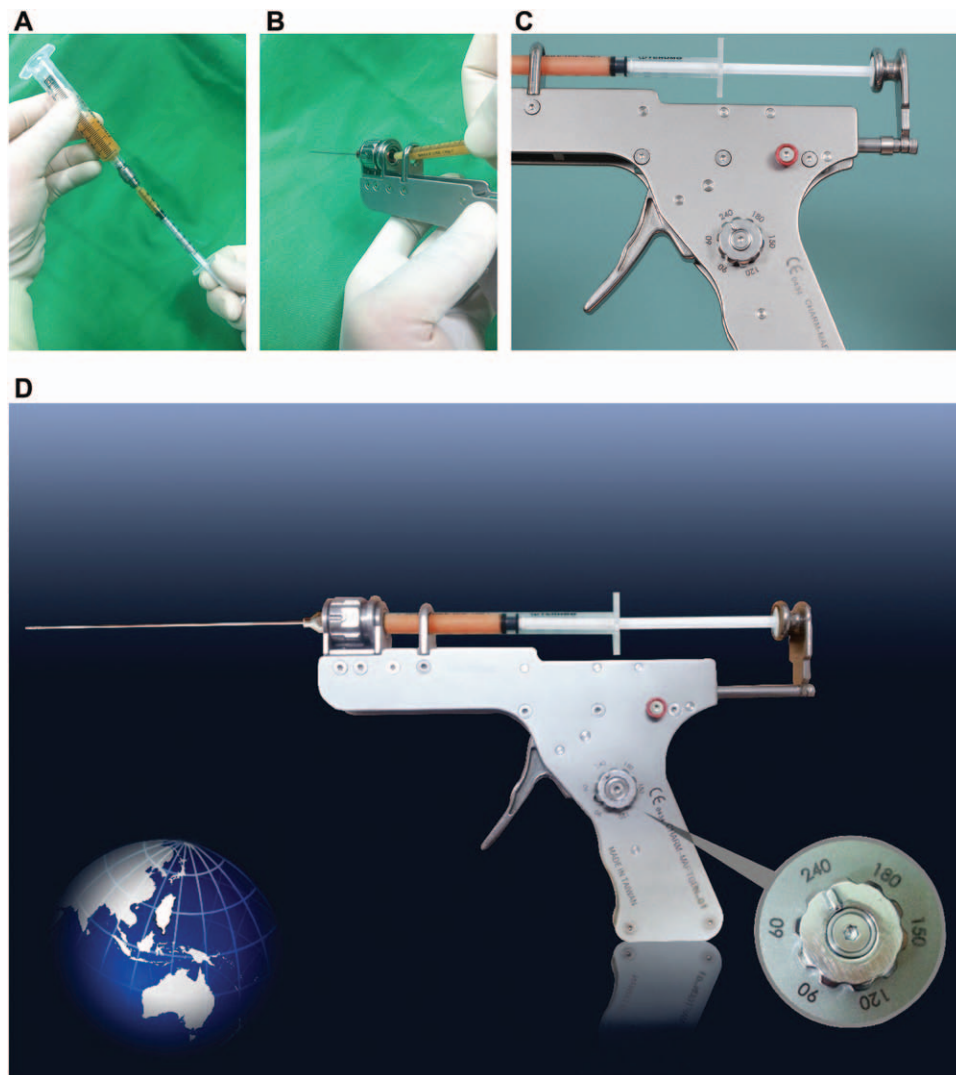
#### Fat Transfer

The purified fat was carefully transferred into a 1-mL Luer Slip syringe by using a transducer and was prepared for transplantation (Fig. 1A). (See **Video 1, Supplemental Digital Content 1**, which displays the microautologous fat transplantation for sunken upper eyelids. This video is available in the "Related Videos" section of the full-text article at <http://www.PRSGo.com> and at <http://links.lww.com/PRSGO/A55>.)

After the purified fat was transferred, the fat-filled syringe was loaded into the MAFT-Gun instrument (Fig. 1B). The predetermined volume of the fat parcel to be injected during each triggering was adjusted by rotating the dial (Fig. 1C) with labeled numbers depicting the total injection frequencies per 1 mL of fat graft. An 18-G blunt cannula was used to inject fat while withdrawing the MAFT-Gun. Each delivered fat volume was set at 1/240 mL and meticulously transplanted in 3 to 4 layers: a deep layer above the inferior orbital rim; a middle layer, the sub-orbicularis oculi muscle (deep in the muscle); and superficial layer, the supraorbicularis oculi muscle (just beneath the dermis of the eyelid) (Figs. 2A–D). Postoperative care was provided regularly and without any special dressings or massage. Oral antibiotic and non-steroid anti-inflammatory drugs were administered for 3 days, as required. All patients were regularly photographed at each follow-up visit, and the preoperative and postoperative photographs of each patient were compared.

**Disclosure:** Dr. Tsai-Ming Lin owns the patent rights of MAFT-Gun, is the scientific advisor of DPB, and received partial financial support from DPB, which is the manufacturer of the MAFT-Gun device. None of the other authors has any financial disclosures. The Article Processing Charge was paid for by the authors.

Supplemental digital content is available for this article. Clickable URL citations appear in the text.



**Fig. 1.** A, The processed fat after centrifugation was transferred from a 10-mL syringe to a 1-mL Luer Slip syringe through a transducer. B, The fat-filled syringe was loaded into the MAFT-Gun, and the fat was ready for transplantation. C, The predetermined fat volume of each delivery by triggering could be adjusted by switching the dial (“240” stands for each delivered fat parcel by triggering, which equals 1/240 mL). D, Panoramic view of the MAFT-Gun.

## RESULTS

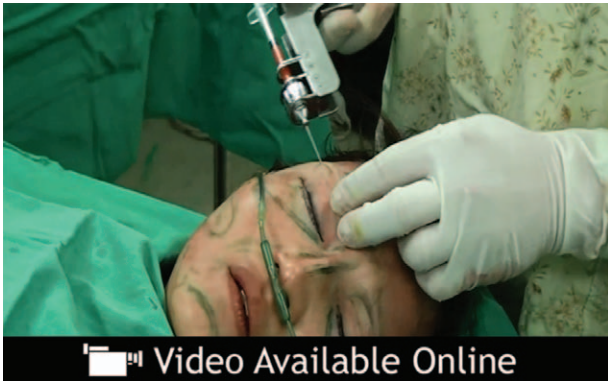The average age of the patients was 35.5 years (range, 26–52 years), and the total injection volume of fat was 1.8 mL for the right side (range, 1.2–2.3 mL) and 1.7 mL for the left side (range, 0.8–2.4 mL). The average operation time was 34 min unless combined with other adjunctive procedures such as upper or lower blepharoplasty or fat grafting of other areas. No major complications were encountered except 2 cases of prolonged swelling for > 2 weeks. All patients were satisfied with the results except one who requested secondary fat grafting [Cases 1 (Figs. 3A, B), case 2 (Figs. 4A–C), case 3 (Fig. 5), and case 4 (Fig. 6)].

## DISCUSSION

### Literature Review

For over a century, surgeons have struggled to apply autologous fat grafting in plastic, reconstructive, and esthetic surgery with variable results. In 1893, the grand surgeon, Neuber,<sup>7</sup> became the first to reconstruct a facial defect. Thereafter, several reports have described fat grafting: Kanavel<sup>21</sup> stated that “fat cells are the best friend of the surgeon,” Peer<sup>8</sup> described an approximately 55% fat-graft retention rate, and Bames<sup>9</sup> reported convincing results regarding fat grafting for breast augmentation. In 1977, Ilouz<sup>10</sup> reported on “liposuction” and developed the related medical instruments. Subsequently, fat graft-





**Video 1.** See video, Supplemental Digital Content 1, which displays the microautologous fat transplantation for sunken upper eyelids. This video is available in the “Related Videos” section of the full-text article at <http://www.PRSGo.com> and is available at <http://links.lww.com/PRSGO/A55>.

ing was fine-tuned and applied in plastic surgery; for example, Fournier<sup>11</sup> used fat grafting to fill involuted facial tissues, and Chajchir and Benzaquen<sup>12</sup> used fat grafting for rejuvenation of facial wrinkles and treatment of hemifacial atrophy. In addition, various endeavors have been attempted for recipient site preparation; for example, Asken<sup>13</sup> performed subcision to prepare a pocket for fat grafting, and Nguyen et al<sup>14</sup> reported muscle as the optimal recipient site for fat grafting. In the past 2 decades, prominent surgeons have illustrated numerous principal theories. Carpaneda and Ribeiro<sup>15,16</sup> postulated higher fat graft survival, and in 1993 and 1994, they experimentally proved that the graft survival is higher when the grafting is within 1 to 2 mm from the margin. In 1994, Coleman<sup>17</sup> presented the structure fat graft method and emphasized that in special locations, such as periorbital areas, each fat parcel must be between 1/30 and 1/50 mL. Based on the review of the aforementioned literature, experts and scientists in the field have demonstrated various fat-grafting techniques; however, no conclusive strategy has yet been developed.<sup>22</sup>

#### **Evidence-based Medicine in Fat Grafting**

Evidence-based medicine applies the most reliable evidence gained from scientific methods to clinical decision making.<sup>23</sup> In autologous fat grafting, 2 theories were proposed by Carpaneda and Coleman, which demonstrate the importance of evidence-based medicine.

#### **Theory by Carpaneda**

Carpaneda and Ribeiro<sup>15</sup> demonstrated only 40% graft survival at  $1.5 \pm 0.5$  mm peripheral to the graft margin. Furthermore, they reported that thickness and geometrical shape are the keys to successful fat transplantation and concluded that the

diameter of the fat graft (either spherical or cylindrical shaped) should be  $< 3$  mm to achieve higher graft survival rates.<sup>16</sup>

#### **Coleman’s Theory**

Coleman<sup>17</sup> proposed the concept of structure fat grafting and emphasized that the fat parcels should be manually arranged in layers with a volume of  $< 1/10$  mL per injection for each parcel; in special sites such as periorbital areas, each fat parcel should be 1/30–1/50 mL. Moreover, the complications and morbidities can be minimized by avoiding the central necrosis of a fat graft that can be induced through overinjection when each parcel is placed.

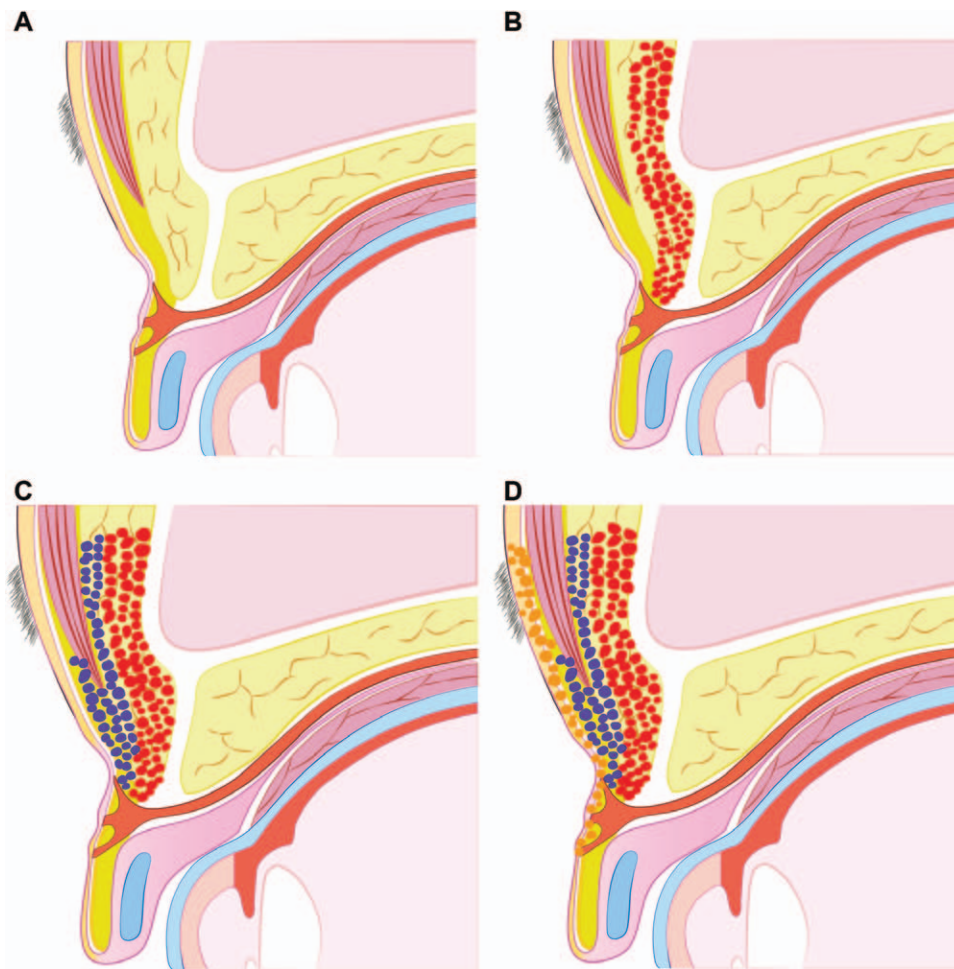
#### **Disadvantages of Commercialized Medical Devices: Ratchet Guns**

For several years, commercially available ratchet guns have been clinically applied in fat grafting with variable results. The advantages of ratchet guns include the accurate control of fat parcels by pulling of the trigger, and the ergonomic design. However, the disadvantages are the relatively large volume injected per triggering (1/10 mL, 1/2 mL, and up to 1 mL) and the potential exposure of the fat graft inside the syringe to ambient air because of repeated manipulation of the plunger. Although some surgeons have reported favorable results, most surgeons are hesitant in using these instruments. Accordingly, in addition to accuracy, fat grafting also necessitates delicate, precise, and consistent control of the placement of each fat parcel.

The aforementioned evidence-based medicine indicates the necessity for precise, accurate, and consistent delivery of each parcel, as insisted by Coleman and Carpaneda. However, commercial devices have not yet satisfied all the requirements for precise delivery. Moreover, manual operation is not only physically difficult; it is also scientifically impossible to deliver each fat parcel at minute volumes between 1/30 and 1/50 mL when using this method.

#### **Myths Regarding Overinjection with Massage**

Previous studies have emphasized the requirements for optimal fat grafting at recipient sites, such as the periorbital area, wherein a fat droplet should be as minute as 1/30 to 1/50 mL.<sup>17</sup> The delicate placement of fat graft relies on the surgeon’s manual skills; however, even an experienced surgeon cannot expect to inject each minute fat parcel with accuracy and consistency, particularly in the case of tissue resistance inside the donor area. Therefore, instances of overinjection or abrupt placement of fat are frequently observed and unavoidable.



**Fig. 2.** A, Sagittal view of the upper eyelid. B, The lower (deep) layers were transplanted with 3 to 4 layers of fat parcels (preferable volume of each parcel, 1/240 mL); the fat parcel was red in color. C, The intermediate (middle) layers were transplanted with 2 to 3 layers of fat parcels, each with a volume of 1/240 mL; the fat parcel was blue in color. D, The upper (superficial) layers were transplanted with a layer of the fat parcel (recommended volume of each parcel, 1/240 mL); the fat parcel was brown in color.

Based on a study conducted by Peer that indicated approximately 55% graft survival after fat grafting, some surgeons prefer to perform fat grafting through overinjection at the recipient site, followed by vigorous manual massage exerted by the operator to even out and flatten the skin surface. However, as illustrated in Figure 7, overinjection can eventually induce several complications as described previously.<sup>24</sup>

#### Concept of MAFT

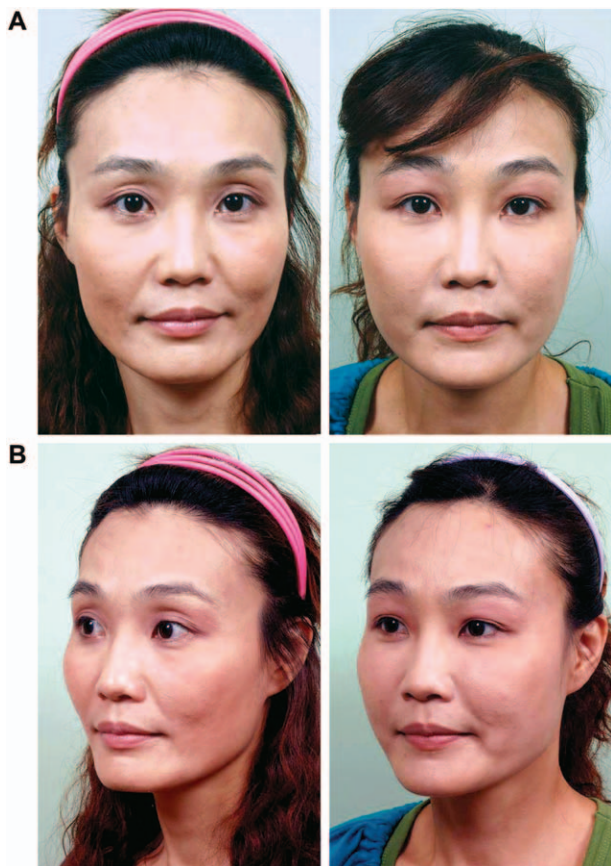Similar to the acceptance of skin grafts, a fat graft regains its blood circulation 48 h after implantation (neovascularization formation).<sup>25</sup> However, the inflow of nutrients and outflow of metabolites (adipocytes) depend on the initial diffusion and plasmatic imbibition after grafting. Carpaneda and Ribeiro<sup>15</sup> demonstrated that the central area eventually necrotizes and only the

marginal zone survives at a rate of approximately 40% at  $1.5 \pm 0.5$  mm from the grafted margin, regardless of the shape of the fat graft (spherical or cylindrical).

Previous studies have reported several postoperative complications associated with the large size of an implanted fat parcel, including absorption, cyst formation, fibrosis, calcification, ossification, and asymmetry.<sup>24</sup> This phenomenon of “central necrosis” induces a cascade of aggressive chain reactions, leading to numerous unavoidable complications including unpredictable graft survival and fat retention. Therefore, it is highly recommended that the size of the implanted fat droplets be as small as possible.<sup>11</sup>

Based on the theory postulated by Carpaneda, the mathematical formula for determining the optimal volume of fat parcels (here, the fat graft is presumed to be spherical in shape) is calculated as follows: the volume



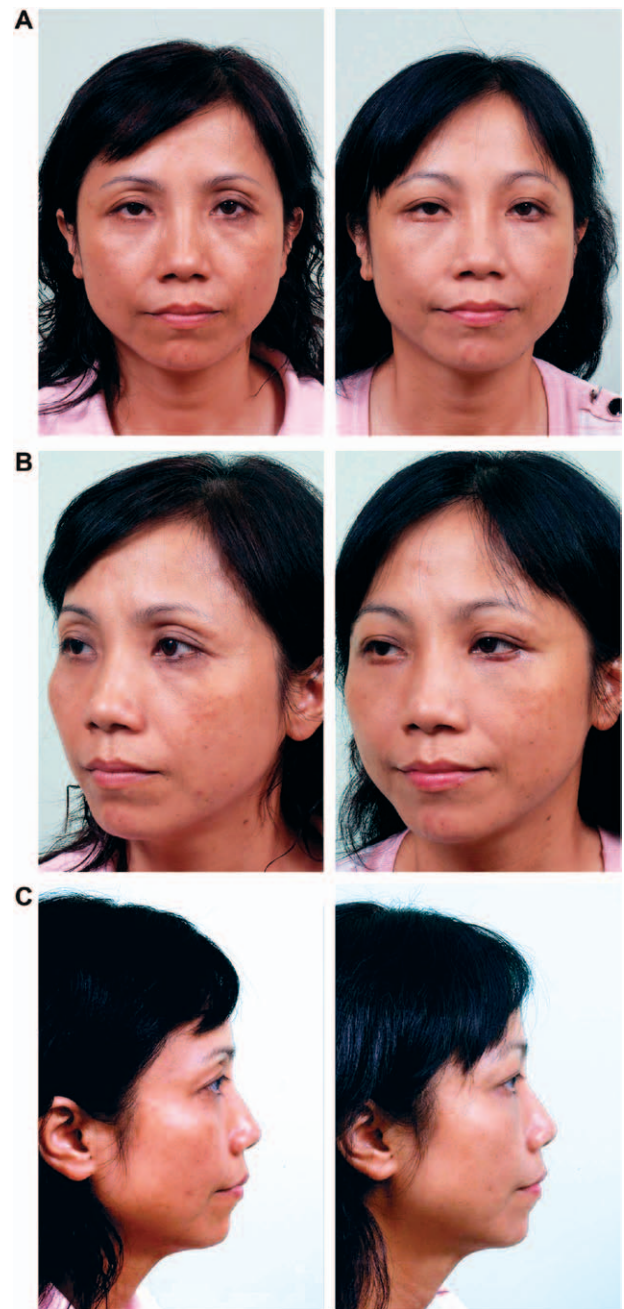


**Fig. 3.** A 42-year-old woman suffered from bilateral sunken upper eyelids with multiple folds. One-time MAFT was performed at 2.2 mL/2.4 mL (right/left side). A, Preoperative frontal view (left) and left profile view 12 months after grafting (right). B, Preoperative left profile view (left) and 12 months after grafting (right).

of a globe is  $(4/3)\pi r^3$ , where  $r$  is the global radius and  $\pi$  is the ratio of any circle's circumference to its diameter in Euclidean space. Table 1 presents the information regarding the volume of each fat parcel at the radii of 1, 1.5, and 2 mm. We concluded that the injection frequency of 1-mL fat parcels for a spherical graft with a 2-mm radius can be calculated by dividing  $1000\text{mm}^3$  (1 mL) by  $(4/3)\pi(2\text{mm})^3$ . Therefore, a minimal injection frequency of 30 was set for each 1 mL fat-graft parcel to achieve superior graft survival rates.

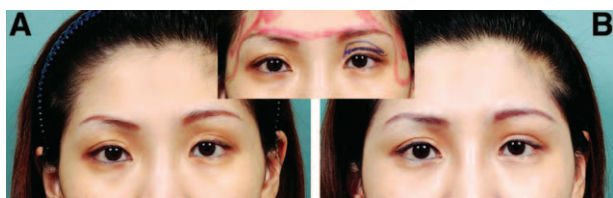**What MAFT Emphasizes and How It Works**  
*Precise, Accurate, and Consistent Placement*

The subcutaneous tissue overlying the skin where fat grafts are primarily placed possesses a strong longitudinal adherence to the fibrous septa, with strong fascia or ligaments. For placement of minute parcels, a tunneling maneuver of the injection needle is required by moving it back and forth to loosen the tough subcutaneous tissues and place as small a par-

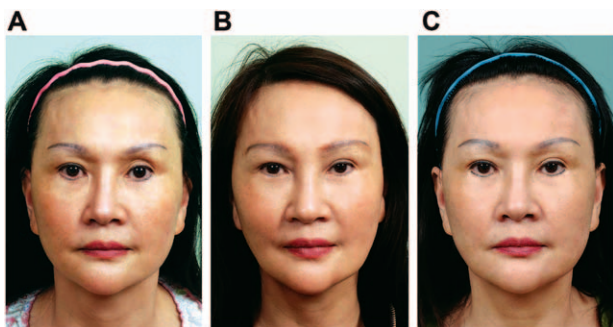

**Fig. 4.** A 47-year-old woman underwent MAFT for the hollowness of her upper eyelids with multiple folds. One-time MAFT was performed at 1.8 mL/2.0 mL (right/left). A, Preoperative frontal view (left) and at 6 months follow-up (right). B, Preoperative left profile view (left) and at the 6-month postoperative follow-up (right). C, Preoperative right lateral view (left) and at 6-month postoperative follow-up (right).

cel as possible. Such a maneuver in fat placement results in more tissue injury and necessitates a longer healing time. Moreover, severe ecchymosis and swelling in the first 2 weeks after grafting embarrassed and frustrated the patients with an unattractive or



**Fig. 5.** Unilateral sunken eyelid of a 28-year-old woman who received MAFT at 1.5 mL on her left upper eyelid. A, Preoperative frontal view. B, Frontal view at the 6-month follow-up. Inset, Blue marking on left upper eyelid was the grafted area.



**Fig. 6.** A 58-year-old woman requested recontouring of her bilateral sunken upper eyelids with left-side entropion (A) because of 2 previous blepharoplasties. Fat grafting was performed using MAFT at 1.2 mL/2.5 mL (right/left). B, The results observed 3 months after MAFT were satisfactory. C, Long-term results indicated that the recontouring was well maintained 15 months after grafting.

bruised appearance.<sup>26</sup> Some swelling persisted even 16 weeks after grafting.

#### *Alternative to Overinjection with Manual Massage*

As observed in Figure 7, an irregular depression (Fig. 7A) was observed as a soft-tissue defect (mimicking soft-tissue depression or grooves). Surgeons often overinjected the sunken areas (Fig. 7B), followed by vigorous massage to remold and flatten them evenly (Fig. 7C). However, after vigorous massage, the fat parcels formed a confluent mass. Although the skin surface appeared smooth and full after operation for days to weeks, the remodeling processes including absorption and fibrosis continued and evolved because of central necrosis (Fig. 7D). Eventually, as shown in Figure 7E, irregular skin and uneven surface over the graft area appeared as unavoidable morbidities.

#### *An Instrument to Reflect the Concept of MAFT*

The innovative transmission system of the MAFT-Gun was designed to minimize the injecting volume to 1/240 mL per parcel (Fig. 1D). This microdelivery mechanism ensured that the radius of each injected droplet was approximately 1 mm, which has been documented in the literature as essential to

decreasing the severity of the inevitable central necrosis of the fat parcel.<sup>15</sup> Therefore, the graft survival rate improved when the fat droplet resided in the tissue with no potential central necrosis, which was the primary reason for impairing the transmission of nutrients inside and the metabolites outside the adipocyte (or preadipocyte).

#### *No Excess Swelling and Long Healing Time Compared with Other Traditional Modalities*

Even when performed by the most experienced surgeons, postoperative swelling and edema are unavoidable, which often frustrates patients.<sup>26</sup> Severe bruising and swelling develop in the recipient areas in the first week after fat grafting, and this is primarily attributed to the to-and-fro movements of the injection cannula during the injection procedure.<sup>26</sup> However, the strong and tough adherent subcutaneous tissue in some recipient areas needs to be loosened by using such a maneuver to place the fine fat parcel and avoid the dislodgement of huge droplets by abrupt overinjection. The patented microcontrolling system of MAFT-Gun ensured that the injection volume of each parcel was predetermined and thus controlled in the procedure. A steady and accurate volume was transmitted at each trigger pull, regardless of the strength exerted by surgeons or the tempo of the injection. Therefore, by reducing the frequency of the back-and-forth tunneling movements used to loosen the recipient area, postoperative healing time was reduced, and the swelling and edematous appearance was minimal when compared with traditional techniques.

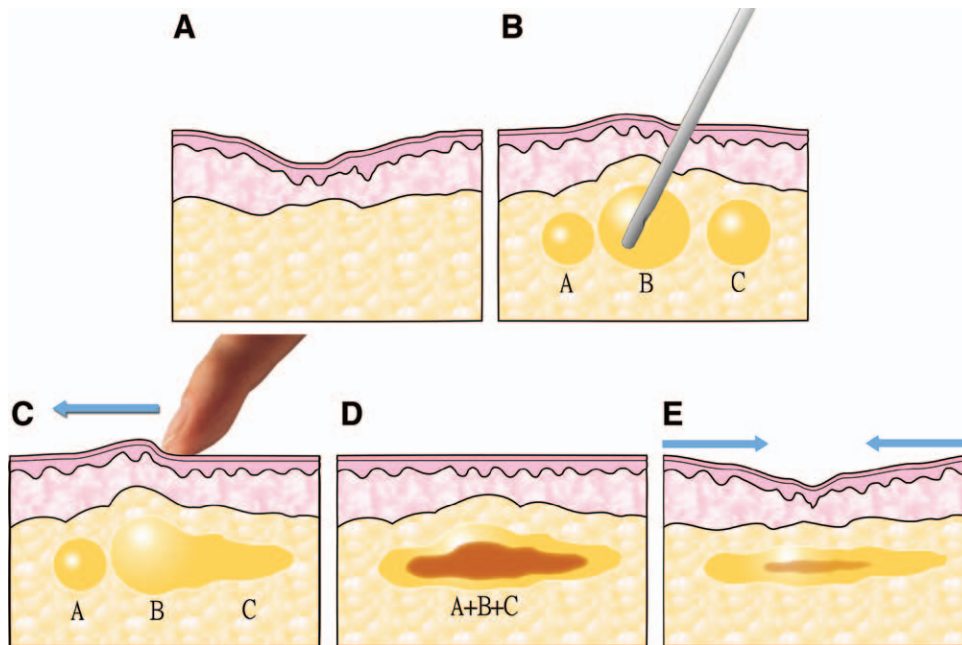
#### *Enhanced Performance of Surgeons*

Surgeons have to turn their hands often because the fixed pinhole of commercial injection needles requires changing for various grafting sites. The inconstant and labor-intensive turning of the surgeons' hands impedes efficacious performance during the grafting procedure. A clear marking with 360° multi-range adjustability of the MAFT instrument provided precise control of the direction of injection. With this innovation, surgeons were able to change the pinhole of the injection needle freely, comfortably, and accurately. The user-friendly trigger system based on the pulling maneuver enabled a predetermined volume of each parcel to be precisely delivered. Right- or left-handed use of the handpiece was set in advance, which is therefore adaptable for use by all surgeons.

#### *Innovation of MAFT-Gun*

The MAFT-Gun provided an innovative operating system to deliver fat grafts with a flexible volume of 1/60, 1/90, 1/120, 1/150, 1/180, or 1/240 mL per injection (by rotating the adjustable dial to 60, 90, 120,





**Fig. 7.** A, Sagittal view indicated an irregular, depressed area. B, Traditional fat-grafting was performed through injection and overcorrection. Three large fat parcels, A, B, and C, appeared. At this time, the overcorrection resulted in bulging of the surface of the depressed areas. C, After vigorous manual massage, the 3 parcels, A, B, and C, came into contact with each other and fused as a larger fat entity. D, Although the skin surface of the bulged areas smoothed and flattened after massage, the central area of this conjoined parcel, A + B + C, was presumed to have necrotized. E, Several weeks after the event of central necrosis, some absorption areas resulted in irregular skin surfaces, as presented between the 2 arrows in this figure. The newly formed depression or irregularity was visible after grafting.

**Table 1. Total Injection Frequency of a 1-mL Fat Parcel at Radii of 1.0, 1.5, and 2.0 mm**

Radius (mm)	Volume of Spherical (mm <sup>3</sup> )	Total Injection Frequency of 1-mL (1000 mm <sup>3</sup> ) Fat Graft
1.0	4.2	240 (1000/4.2)
1.5	14.1	70 (1000/14.1)
2.0	33.5	30 (1000/33.5)

150, 180, or 240, respectively), which was suitable for the needs of the surgeons performing the grafting procedure at various areas. Ease of use and ergonomics in application defined the characteristics of this state-of-the-art device as a preferential assisting device.

**Problems with Sunken Upper Eyelids**

Sunken upper eyelids, particularly in Oriental people, are a common occurrence and often present a weak and tired appearance. Based on racial and physiognomic considerations, Asian people might wish to enhance the facial appearance caused by sunken upper eyelids, not only for beautification but also for luck. Several operative strategies, including fascia, dermal grafts, and derma-fat-fascia grafts, have been documented in the

literature.<sup>1-5</sup> However, no satisfactory long-term results have been reported. Commercial soft-tissue fillers such as hyaluronic acid, collagen, or other synthetic biocompatible/degradable materials are popular in the cosmetic market. However, because of the high cost, short duration, and risk of allergies and other complications, an ideal filler is yet to be defined regarding persistency, no allergy reactions, and lower morbidity.<sup>22</sup> In this study, the sunken upper eyelids were recontoured using the MAFT concept and by employing the MAFT-Gun, which enabled an accurate and precise transplantation of each fat droplet. In addition to the recontouring of the hollow-looking eyes, most patients observed that after MAFT, their skin texture and appearance was more youthful and rejuvenated, which implied the existence of stem cells or stromal vascular fractions in the transplanted fat.<sup>27, 28</sup> Because fat grafts play an essential role as “more than a permanent filler,” as advocated by Coleman,<sup>29</sup> they occupy the future stage in regenerative medicine. Therefore, the success of completion of a fat grafting procedure has promising applications not only in cosmetic surgery but also in reconstructive surgery.



## CONCLUSIONS

The evolutionary era of fat grafting is the result of the continuous endeavors of various plastic surgeons. All the strategies of fat grafting, including harvesting, processing, refinement, and transplantation, exhibit promising progress. MAFT is introduced as a novel approach in fat grafting, and its execution can be accomplished using the innovative MAFT-Gun instrument. Using this technique, sunken upper eyelids with multiple folds, which present as hollow eyes, can be reconstructed with favorable long-term follow-up results.

**Tsai-Ming Lin, MD, PhD**

Charming Institute of Aesthetic and  
Regenerative Surgery  
2F-1, No. 172, Ziqiang 2nd Road  
Qianjin District  
Kaohsiung City 801  
Taiwan  
E-mail: k79157@gmail.com

## REFERENCES

- Lee Y, Kwon S, Hwang K. Correction of sunken and/or multiply folded upper eyelid by fascia-fat graft. *Plast Reconstr Surg*. 2001;107:15–19.
- Lew DH, Kang JH, Cho IC. Surgical correction of multiple upper eyelid folds in East Asians. *Plast Reconstr Surg*. 2011;127:1323–1331.
- Kim DW, Bhatki AM. Upper blepharoplasty in the Asian eyelid. *Facial Plast Surg Clin North Am*. 2007;15:327–335, vi.
- Park S, Kim B, Shin Y. Correction of superior sulcus deformity with orbital fat anatomic repositioning and fat graft applied to retro-orbicularis oculi fat for Asian eyelids. *Aesthetic Plast Surg*. 2011;35:162–170.
- Maniglia JJ, Maniglia RF, Jorge dos Santos MC, et al. Surgical treatment of the sunken upper eyelid. *Arch Facial Plast Surg*. 2006;8:269–272.
- Liew S, Nguyen DQ. Nonsurgical volumetric upper peri-orbital rejuvenation: a plastic surgeon's perspective. *Aesthetic Plast Surg*. 2011;35:319–325.
- Neuber F: Fettransplantation. *Bericht über die Verhandlungen der Deutschen Gesellschaft für Chirurgie Zbl Chir*. 1893;22:66.
- Peer LA. Loss of weight and volume in human fat grafts: with postulation of a "cell survival theory". *Plast Reconstr Surg*. 1950;5:217–230.
- Bames HO. Augmentation mammoplasty by lipo-transplant. *Plast Reconstr Surg (1946)*. 1953;11:404–412.
- Illouz YG. Communication à la Société Française de Chirurgie Esthétique, Juin 1978, 1979.
- Fournier PF. Microlipoextraction et microlipoinjection. *Rev Chir Esthet Lang Fr*. 1985;10:36–40.
- Chajchir A, Benzaquen I. Liposuction fat grafts in face wrinkles and hemifacial atrophy. *Aesthetic Plast Surg*. 1986;10:115–117.
- Asken S. Facial liposuction and microlipoinjection. *J Dermatol Surg Oncol*. 1988;14:297–305.
- Nguyen A, Pasyk KA, Bouvier TN, et al. Comparative study of survival of autologous adipose tissue taken and transplanted by different techniques. *Plast Reconstr Surg*. 1990;85:378–386; discussion 387–389.
- Carpaneda CA, Ribeiro MT. Study of the histologic alterations and viability of the adipose graft in humans. *Aesthetic Plast Surg*. 1993;17:43–47.
- Carpaneda CA, Ribeiro MT. Percentage of graft viability versus injected volume in adipose autotransplants. *Aesthetic Plast Surg*. 1994;18:17–19.
- Coleman SR. The technique of periorbital lipofiltration. *Oper Tech Plast Reconstr Surg*. 1994;1:120.
- Chou CK, Lin TM, Chiou JH, et al. Influential factors in autologous fat transplantation—focusing on the lumen size of injection needle and the injecting volume. *IPRAS J*. 2012;8:25–27.
- Fulton JE. Breast contouring with "gelled" autologous fat: a 10-year update. *Int J Cosmet Surg Aesthetic Dermatol*. 2003;5:155–163.
- Shu T, Lam SM. Liposuction and lipotransplants for facial rejuvenation in the Asian patient. *Int J Cosmet Surg Aesthetic Dermatol*. 2003;5:165–173.
- Kanavel AG. The transplantation of free flaps of fat. *Surg Gynecol Obstet*. 1916;23:163.
- Pu LL. Towards more rationalized approach to autologous fat grafting. *J Plast Reconstr Aesthet Surg*. 2012;65:413–419.
- Sackett DL, Rosenberg WM, Gray JA, et al. Evidence based medicine: what it is and what it isn't. 1996. *Clin Orthop Relat Res*. 2007;455:3–5.
- Khawaja HA, Hernandez-Perez E. Fat transfer review: controversies, complications, their prevention and treatment. *Int J Cosmet Surg Aesthetic Dermatol*. 2002;4:131–138.
- Eto H, Kato H, Suga H, et al. The fate of adipocytes after nonvascularized fat grafting: evidence of early death and replacement of adipocytes. *Plast Reconstr Surg*. 2012;129:1081–1092.
- Coleman SR. *Structural Fat Grafting*. St. Louis: Quality Medical; 2004.
- Lu F, Li J, Gao J, et al. Improvement of the survival of human autologous fat transplantation by using VEGF-transfected adipose-derived stem cells. *Plast Reconstr Surg*. 2009;124:1437–1446.
- Yoshimura K, Sato K, Aoi N, et al. Cell-assisted lipotransfer for cosmetic breast augmentation: supportive use of adipose-derived stem/stromal cells. *Aesthetic Plast Surg*. 2008;32:48–55; discussion 56–57.
- Coleman SR. Structural fat grafting: more than a permanent filler. *Plast Reconstr Surg*. 2006;118(3 Suppl): 108S–120S.