



Effect of cisplatin on pancreas and testis in Wistar rats: biochemical parameters and histology

Yogesh Chand Yadav*

Department of Pharmacology, Faculty of Pharmacy, Uttar Pradesh University of Medical Sciences, Saifai, Etawah, 206130, UP, India



ARTICLE INFO

Keywords:

Toxicology
Biochemical parameters and histology
Rats
Testis
Cisplatin
Pancreas

ABSTRACT

Objective: To investigate effect of cisplatin on biochemical parameter and histology of pancreas and testis in Wistar rats.

Material and methods: Single dose cisplatin (10 mg/kg) was injected by intraperitoneal route in Wistar rats. Blood was withdrawn on 7th day from cisplatin treated rats by retro-orbital sinus for biochemical estimation. Further rats were sacrificed and dissected out their pancreases and testes for estimation of antioxidant enzymes and histopathological study.

Results: The cisplatin-treated group showed a significantly ($P < 0.01$) increased blood glucose level, Glycosylated hemoglobin in blood on the 7th day as compared to the control group. Whereas cisplatin-treated group showed significantly ($p < 0.001$) increased lipid peroxidation and decreased reduced glutathione, superoxide dismutase, catalase in pancreatic and testicular tissue as compared to the control group. Histopathological sections of the pancreatic tissue showed marked vasoconstriction and micro infiltration were observed however testicular tissue showed degeneration in some seminiferous tubules and also greatly depleted of germ cells in cisplatin treated group.

Conclusion: These findings demonstrated that the cisplatin could be induced diabetes and testicular toxicity due to their free radical mediated oxidative stress.

1. Introduction

Cisplatin is a prominent and most potent anticancer drugs and it used to treat metastatic testicular and ovarian cancer [1]. It is also used for treatment on various type cancer like lung, urine bladder, head, neck, esophageal, stomach, skin prostate, lymphoma and neuroblastoma, sarcoma, cervical, myeloma, mesothelima and osteosarcoma. In spite of its significant anticancer activity, cisplatin is often dose limited undesirable side effects such as nephrotoxicity [2]. Recent studies has been reported that nephrotoxicity and hepatotoxicity are cisplatin induced is reported that cisplatin and others around the world suggested hepatotoxicity is also a major dose-limiting side effect in cisplatin-based chemotherapy [3, 4, 5, 6]. Cisplatin can induce hepatotoxicity after administered at high doses [7, 8]. Metallothionein protects against liver injury induced by high doses of cisplatin in mice [9]. Selenium and high dose of vitamin E administration protect against cisplatin-induced oxidative damage to liver [10]. Komdeur et al (2007) has been reported that Cisplatin-induced hyperglycemic hyperosmolar coma [11]. Amin et al (2007) has well documented that effect of Roselle and Ginger on cisplatin-induced

reproductive toxicity in rats [12].

With this background, the present study has designed to investigate whether have any effect of cisplatin on pancreas and testes in Wistar rats.

2. Materials and methods

2.1. Drug and reagents

5,5-dithiobis 2-nitrobenzoic acid (Merck pvt. Ltd., India). Thio-barbuturic acid (Loba chemicals pvt.ltd. India). Superoxide Dismutase (sigma Aldrich chemicals pvt. Ltd. India).

2.2. Animals

The Wistar rats were allowed to have an access to water and food ad libitum, and maintained under constant (25 ± 1 °C), humidity (65 ± 10 %) and a 12 h light/dark cycle. The experiment was carried out in accordance to the guidelines mentioned in the CPCSEA, and institution animal ethical committee of Sumandeep Vidyapeeth University was

* Corresponding author.

E-mail address: drycy31@gmail.com.

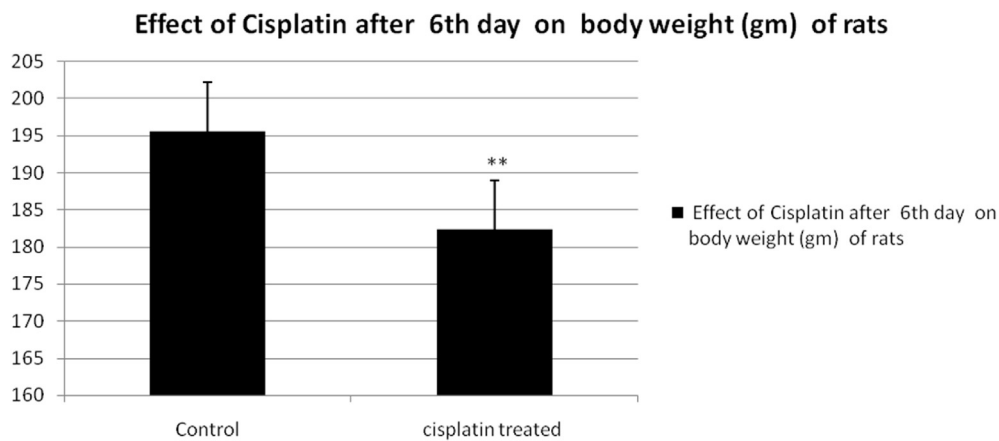


Fig. 1. Effect of Cisplatin after 6th day on body weight (gm) of rats. Each group represents mean \pm SD of six animals as compared to control treated group. $**p < 0.01$ as compared to the control control.

approved the experiment protocols. The experiment was conducted in accordance with accepted standard guidelines for the care and use of animals in scientific research.

2.3. Cisplatin-induced toxicity

Two groups of rats ($n = 6$) used, in which 1st group administered 5 ml/kg normal saline throughout the experiment for 7 days; 2nd group (cisplatin treated) with single dose of cisplatin (10 mg/kg i.p.) on 1st day and keep animals up to 7 days. On the 7th day all animals were anaesthetized with diethyl ether. Blood sample (1–1.5 ml) were collected at once from the retro orbital plexus of rats under light diethyl ether anaesthesia, for biochemical parameter estimation. Pancreas and testes were subjected to histopathological study.

2.4. Biochemical analysis

2.4.1. Determination blood glucose level

The Blood glucose was determined by the method of O-toluidine using the modified reagent [13] and Glycosylated hemoglobin (gly Hb) was determined by the method of Sudhakar and Pattabiraman [14].

2.4.2. Determination reduced glutathione (GSH)

GSH Levels in pancreas and testis were estimated by the method (Beutler et al. 1963). 10% (w/v) homogenate prepared by added 5% trichloroacetic acid solution. It was centrifuged at 3500 rpm for 10 min, 50 μ L supernatant was mixed with 0.32 mol/L disodium hydrogen phosphate and 0.04% 5,5-dithiobis 2-nitrobenzoic acid (DTNB) solution. The yellow-colored substance formed by the reaction of GSH and DTNB was measured at 412 nm. The results were expressed as GSH mg/g tissue weight [15].

2.4.3. Determination of malondialdehyde (MDA)

MDA levels were estimated by the method of (Satoh 1978). 10% (weight/volume) homogenate of pancreas and testis was prepared by added 0.1 mol/L phosphate buffer. It was centrifuged at 4 $^{\circ}$ C, 3500 rpm for 10 min. 0.2 mL supernatant was mixed with 0.67% 2-thiobarbuturic acid (TBA) and 20% trichloroacetic acid solution, and heated in a boiling water bath for 30 min. The pink-coloured chromogen formed by the reaction of TBA with MDA was measured at 532 nm. The results were expressed as MDA nmol/mg protein [16].

2.4.4. Determination of superoxide dismutase (SOD)

Superoxide dismutase (SOD) activity in pancreas and testis homogenate was determined according to the method (Minami and Yoshikawa 1979). The homogenate was centrifuged at 2500 rpm for 15 minutes at 4

Table 1

Effect of cisplatin on biochemical parameters in serum.

Parameters	Control groups	Cisplatin treated group
Glucose	83.83 \pm 3.71	194.64 \pm 2.36 ***
Gly Hb	5.96 \pm 0.5	8.65 \pm 0.60 *
Total protein	8.56 \pm 1.35	5.24 \pm 0.86**

***P < 0.01, **P < 0.01 and *P < 0.05 as compared to the Control.

$^{\circ}$ C. The 0.25 ml of supernatant was mixed with 0.5 ml of tris cacodylic buffer, and 0.1 ml of 16% triton x- 100 and 0.25 ml NBT. The reaction was started by the addition of 0.01 ml diluted pyrogallol. It was kept on Incubation for 5 minutes at 37 $^{\circ}$ C. The reaction was stopped by the addition of 0.3 ml of 2 M formic acid. The formazan colour developed was determined spectrophotometrically (Spectronic 501, Shimadzu). Enzymatic activity (SOD) was expressed as U/g of tissue [17].

2.5. Histopathological examination

The Wistar rats were sacrificed on the day of blood withdrawal. Pancreas and testis were isolated, processed, and embedded in paraffin wax. The sections were stained in haematoxylin and eosin and permanently mount for viewing and reporting [18].

2.6. Statistical analysis

Result were expressed as mean \pm SEM, Statistical Analysis were performed with unpaired t test. P value less than <0.05 was considered.

3. Results

3.1. Changes of body weight of rats

Cisplatin treated group showed significantly ($p < 0.001$) decreased body wt of rats as compared control group (Fig. 1).

Table 2

Levels of GSH, SOD, CAT and MDH in pancreatic tissues of control and cisplatin treated group of rats.

Parameters	Control group	Cisplatin treated group
GSH(μ mol/g)	11.45 \pm 1.35	7.57 \pm 1.35**
MDH(nmol/g)	24. \pm .85	74.84 \pm 1.42**
SOD(U/g)	15.46 \pm 1.66	7.63 \pm 1.33**
CAT(μ mol H2O2/g)	298 \pm 1.84	185 \pm 3.45**

**P < 0.01 as compared to the Control.

Table 3

Levels of GSH, SOD, CAT and MDH in testicle tissue of control and cisplatin treated group of rats.

Parameters	Control group	Cisplatin treated group
GSH($\mu\text{mol/g}$)	55 \pm 2.45	42.48 \pm 2.68**
MDH(nmol/g)	44. \pm 1 .64	65.38 \pm 2.24**
SOD(U/g)	28.46 \pm 2.25	15.25 \pm 2.24**
CAT($\mu\text{mol H}_2\text{O}_2/\text{g}$)	225 \pm 2.54	105 \pm 2.34**

**P < 0.01 as compared to the Control.

3.2. Alteration of biochemical parameters

The cisplatin-treated group showed significantly ($p < 0.001$) increased glucoses, gly Hb in blood on the 7th day as compared to the control group (Table 1).

In term of tissue homogenate biochemical estimation, it was found that the cisplatin-treated group showed significantly ($p < 0.001$) increased lipid peroxidation (Table 2), whereas significantly ($p < 0.001$) decreased GSH, SOD, CAT in pancreatic and testicular tissue (Tables 2 and 3) as compared to the control group.

3.3. Histopathological examination

Histopathological sections of the pancreatic tissue showed marked vasoconstriction and micro infiltration were observed cisplatin treated group II [Fig. 2 Plates 1(B)] as compared to control group [Fig. 2 Plates 1(A)].

Histopathological sections of testicular tissue showed degeneration in some somniferous tubules and were also greatly depleted of germ cells in cisplatin treated group II [Fig. 2 Plates 1(D)] as compared to control group [Fig. 2 Plates 1(C)].

4. Discussion

The present study to investigate the effect of cisplatin on body wt of rats, biochemical parameters and histology of pancreas and testes.

After single dose of 10 mg/kg the cisplatin-treated showed a significant decreased body wt of rats as compared control group. The loss body wt of rats due to cisplatin induced gastrointestinal toxicity. Shahid et al (2018) has been reported that cisplatin induced gastrointestinal dysfunction due to concurrently utilized cisplatin with plant-derived agents [19].

After single dose of 10 mg/kg the cisplatin-treated showed a significant increase glucoses and gly Hb in serum me be due their emetogenic, glucocorticoids effect. The glucocorticod induces diabetes via impaired glucose metabolism.

In the present study, Cisplatin treated groups showed significantly increased lipid peroxidation and GSH, SOD, CAT were significantly decreased in pancreatic and testicular tissue as compared control group. The instantaneously significant decrease of antioxidants enzyme in cisplatin-induced tissues could potentiate elucidates the upregulation of lipid peroxidation [20]. It has been also well documented about a relationship between cisplatin-induced complications and lipid peroxidation [21]. Actually, cisplatin reacts with water and generated free radical. It's free radical oxidative stress induced toxicity pancreatic and testicular tissue (Fig. 3).

There are many previous studies have been well documented that cisplatin induces toxicity in liver [22] kidney [23, 24], due their free radical oxidative stress by interacting with DNA [25].

In vitro and in vivo Previous studies reported that cisplatin induces apoptotic cell death at low dose and it produces both necrosis and apoptosis at higher dose [26, 27]. There are numerous apoptotic pathways which are mediated by TNF receptors as an extrinsic pathway and the mitochondrial and endothelium stress as an intrinsic pathway [28].

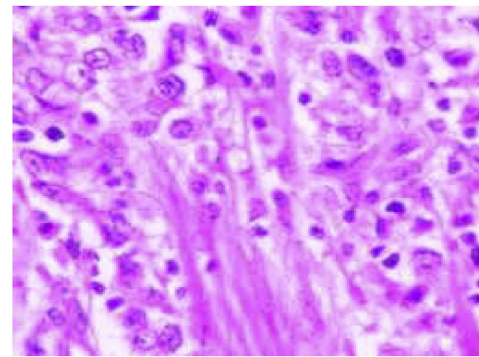


Plate 1 (A)

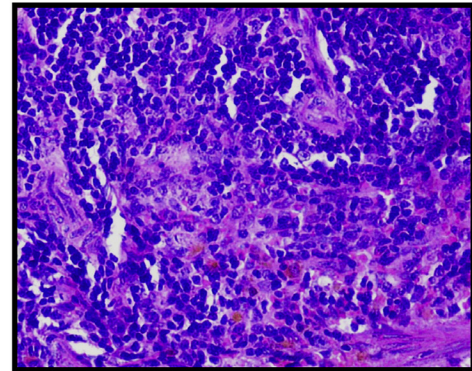


Plate 1 (B)

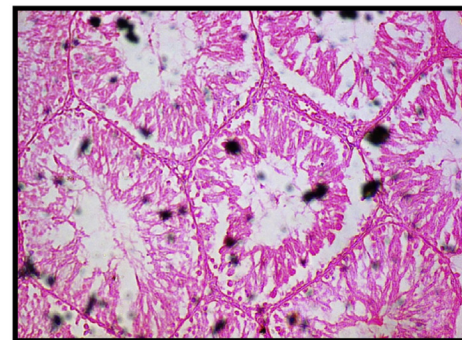


Plate 1 (C)

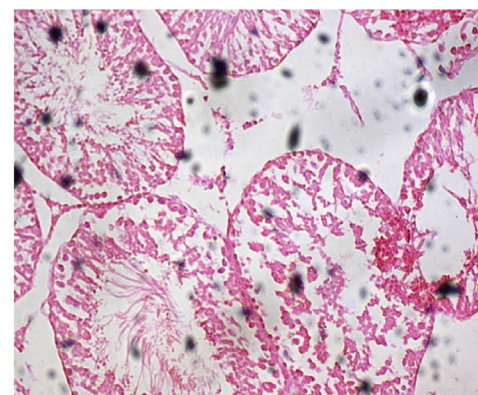


Plate 1 (D)

Fig. 2. Plate 1(A) Photograph of Pancreas in control group rat, Plate 1(B) Photograph of pancreas Cisplatin treated rat. Plate 1(C) Photograph of testis in control group rat. Plate 1 (D) Photograph of testes in cisplatin treated rat.

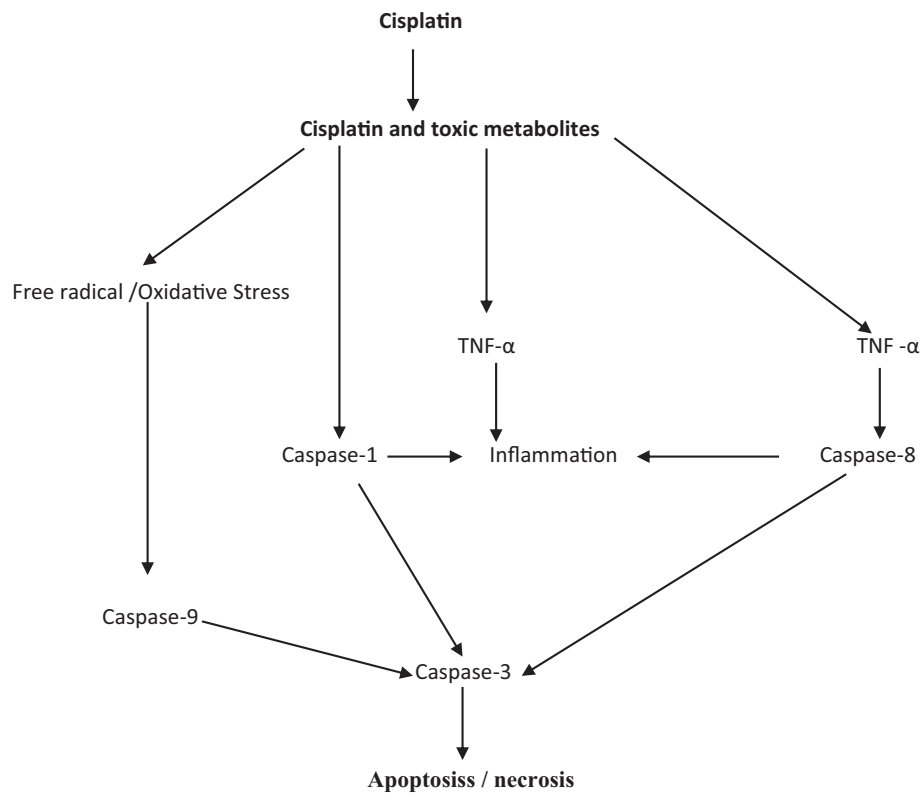


Fig. 3. Mechanism of cisplatin induces pancreatic and testicle toxicity.

Histopathological sections of the pancreatic tissue showed marked vasoconstriction and micro infiltration which was indicates cisplatin could be indicated diabetes. It was also suggested by Goldstein et al [29], Nan et al (2003) and Komdeur et al [30].

Histopathological sections of testicular tissue showed degeneration in some somniferous tubules and were also greatly depleted of germ cells in cisplatin treated could be showed testicular toxicity. The present study is supported by Amr et al (2006) which are reported as effects of Roselle and Ginger on cisplatin-induced reproductive toxicity in rats [31].

Hence, cisplatin-induced pancreas and testicular damage due to their free radical mediated oxidative necrosis of tissue.

5. Conclusion

Finally on the basis of these investigations, it is concluded that cisplatin could be induced diabetes and testicular toxicity due to their cytotoxic and sever free radical oxidative stress effect. Actually, Cisplatin induces toxicity due their free radical oxidative stress by interacting with DNA. Further more studies needed for next generation.

Declarations

Author contribution statement

Yogesh Chand Yadav: Conceived and designed the experiments; Performed the experiments; Analyzed and interpreted the data; Contributed reagents, materials, analysis tools or data; Wrote the paper.

Funding statement

This research did not receive any specific grant from funding agencies in the public, commercial, or not-for-profit sectors.

Competing interest statement

The authors declare no conflict of interest.

Additional information

No additional information is available for this paper.

References

- [1] T. Thigpen, R. Vance, L. Punecky, T. Khansurt, Chemotherapy in advanced ovarian carcinoma: current standards of care based on randomized trials, *Gynecol. Oncol.* 55 (1994) 597–607.
- [2] N.E. Madias, J.T. Harrington, Platinum nephrotoxicity, *Am. J. Med.* 65 (1978) 307–314.
- [3] Y.J. Liao, H. Tang, Y.P. Jin, Study of toxic effects on hearing, kidney and liver of mice induced by anticancer agent of cisplatin and their mechanisms, *Chin. Pharmacol. Bull.* 20 (1) (2004) 82–87.
- [4] K.O. Hong, J.K. Hwang, K.K. Park, S.H. Kim, Phosphorylation of c-Jun N-terminal Kinases (JNKs) is involved in the preventive effect of xanthorrhizol on cisplatin-induced hepatotoxicity, *Arch. Toxicol.* 79 (4) (2005) 231 2–23136.
- [5] J. Liu, LiuY, S.S. Habeebu, C.D. Klaassen, Metallothionein (MT)-null mice are sensitive to cisplatin-induced hepatotoxicity, *Toxicol. Appl. Pharmacol.* 149 (1998) 24–31.
- [6] R. Pratibha, R. Sameer, P.V. Rataboli, D.A. Bhiwgade, C.Y. Dhume, Enzymatic studies of cisplatin induced oxidative stress in hepatic tissue of rats, *Eur. J. Pharmacol.* 532 (2006) 290–293.
- [7] R.J. Cersosimo, Hepatotoxicity associated with cisplatin chemotherapy, *Ann. Pharmacother.* 27 (1993) 438–441.
- [8] C.F. Pollera, F. Meglio, M. Nardi, G. Vitelli, P. Marolla, Cisplatin-induced hepatic toxicity, *J. Clin. Oncol.* 5 (1987) 318–319.
- [9] J. Liu, LiuY, S.S. Habeebu, C.D. Klaassen, Metallothionein (MT)-null mice are sensitive to cisplatin-induced hepatotoxicity, *Toxicol. Appl. Pharmacol.* 149 (1998) 24–31.
- [10] M. Naziroglu, A. Karaoglu, A.O. Aksoy, Selenium and high dose vitamin E administration protects cisplatin-induced oxidative damage to renal, liver and lens tissues, *Toxicology* 195 (2004) 221–230.
- [11] R. Komdeur, J. Derksen, M.C. Legdeur, B.S. Hylkema, Cisplatin induces hyperglycaemic and hyperosmolar coma, *J. Med.* 65 (1) (2007) 36–37.

- [12] Amr Amin, Alaa Eldin, A. Hamza, Effects of Roselle and Ginger on cisplatin-induced reproductive toxicity in rats, *Asian J. Androl.* 8 (5) (2006) 607–612.
- [13] T. Sasaki, S. Mastys, A. Sonae, Effect of acetic acid concentration on the colour reaction in the O-toluidine boric acid method for blood glucose estimation, *Rinsho Kagaku* 1 (1972) 346–353.
- [14] Pattabiraman Sudhakar, A new colorimetric method for the estimation of glycosylated haemoglobin, *Clin. Chem. Acta* 109 (1981) 267–274.
- [15] E. Beutler, O. Duron, B.M. Kelly, Improved method for the determination of blood glutathione, *J. Lab. Clin. Med.* 61 (1963) 882–890.
- [16] K. Satoh, Serum lipid peroxide in cerebrovascular disorders determined by new colorimetric method, *Clin. Chim. Acta* 90 (1978) 37–43.
- [17] M. Minami, H. Yoshikawa, A simplified assay method of superoxide dismutase activity for clinical use, *Clin. Chim. Acta* 92 (1979) 337–342.
- [18] S.K. Chandrasekaran, H. Benson, J. Urquhart, Methods to achieve controlled drug delivery: the biochemical engineering approach, in: J.R. Robinson (Ed.), *Sustained and Controlled Drug Delivery Systems*, Marcel Dekker, New, 1978, pp. 557–593.
- [19] F. Shahid, Z. Farooqui, F. Khan, Cisplatin-induced gastrointestinal toxicity: an update on possible mechanisms and on available gastroprotective strategies, *Eur. J. Pharmacol.* 827 (2018) 49–57, 15.
- [20] P. Kaur, M.P. Bansal, Influence of selenium induced oxidative stress on spermatogenesis and lactate dehydrogenase-X in mice testis, *Asian J. Androl.* 6 (2004) 227–232.
- [21] L.M. Antunes, J.D. Darin, L. Bianchi Nde, Effects of the antioxidants curcumin or selenium on cisplatin-induced nephrotoxicity and lipid peroxidation in rats, *Pharmacol. Res.* 43 (2001) 145–150.
- [22] Yogesh Chand Yadav, Effect of *Ficus religiosa* latex on cisplatin induced liver injury in Wistar rats, *Revista Brasileira de Farmacognosia* 25 (2015) 278–283.
- [23] Yogesh Chand Yadav, D.N. Srivastava, Nephroprotective and curative effects of *Ficus religiosa* latex extract against cisplatin induced acute renal failure, *Pharm. Biol.* 51 (11) (2013) 1480–1485.
- [24] Yogesh Chand Yadav, Effect of *Ficus benghalensis* L. Latex extract (FBLE) on cisplatin induced hypotension and renal impairment in Wistar rats, *Biochem. Pharmacol.* 5 (2016) 216.
- [25] H. Masuda, T. Tanaka, U. Takahama, Cisplatin generates superoxide anion by interaction with DNA in a cell-free system, *Biochem. Biophys. Res. Commun.* 203 (1994) 1175–1180.
- [26] W. Lieberthal, V. Triaca, J. Levine, Mechanisms of death induced by cisplatin in proximal tubular epithelial cells: apoptosis vs. necrosis, *Am. J. Physiol. Renal. Physiol.* 270 (1996) F700–F708.
- [27] R.H. Lee, J.M. Song, M.Y. Park, S.K. Kang, Y.K. Kim, J.S. Jung, Cisplatin-induced apoptosis by translocation of endogenous Bax in mouse collecting duct cells, *Biochem. Pharmacol.* 62 (2001) 1013–1023.
- [28] F. Shiraishi, L. Curtis, L. Truong, K. Poss, G. Visner, K. Madsen, H. Nick, A. Agarwal, Heme oxygenase-1 gene ablation or expression modulates cisplatin-induced renal tubular apoptosis, *Am. J. Physiol. Renal. Physiol.* 278 (2000) F726–F736.
- [29] R.S. Goldstein, G.H. Mayor, R.L. Gingerich, J.B. Hook, R.W. Rosenbaum, J.T. Bond, The effects of cisplatin and other divalent platinum compounds on glucose metabolism and pancreatic endocrine function, *Toxicol. Appl. Pharmacol.* 69 (1983) 432–441.
- [30] D.N. Nan, M. Fernandez-Ayala, M.E. Vega Villegas, et al., Diabetes mellitus following cisplatin treatment, *Acta Oncol.* 42 (2003) 75–78.
- [31] A. Amr, Alaa Eldin A. Hamza, Effects of Roselle and Ginger on cisplatin-induced reproductive toxicity in rats, *Asian J. Androl.* 8 (5) (2006) 607–612.