



Excision of Rudimentary Preaxial Polydactyly of the Hand with Use of Electrocautery

Young Ho Shin, MD, Jun O Yoon, MD, Hyung Seo Jung, MD, Hyun Seok Joo, MD, Jae Kwang Kim, MD

Department of Orthopedic Surgery, Asan Medical Center, University of Ulsan College of Medicine, Seoul, Korea

Background: Suture ligation has been used widely for the treatment of rudimentary type extra digits, but several complications related to this treatment have been reported. The purpose of this study was to describe a new technique for excision of rudimentary preaxial polydactyly of the hand using electrocautery and assess its clinical outcomes.

Methods: The authors performed a retrospective study of 34 thumbs (32 patients) that had undergone excision of rudimentary preaxial polydactyly using electrocautery under local anesthesia. The mean follow-up period was 16.5 months.

Results: All children had full range of thumb motion without angular deformity at the most recent follow-up. There were no postoperative complications such as bleeding or infection. In 33 thumbs (97.1% of 34 thumbs), there were no signs of residual digit prominence. One thumb had a residual digit prominence at the extra digit removal site. In two thumbs, scar hypertrophy was evident at the operation site. All parents of the patients except two were very satisfied with this technique and the mean visual analog scale score for satisfaction was 9.5 ± 2.0 (range, 0–10).

Conclusions: Excision of rudimentary preaxial polydactyly of the hand with the use of electrocautery could remove an extra digit completely in 97.1% of the cases. This technique would be a useful alternative to suture ligation, surgical clip application, or surgical excision for the treatment of rudimentary preaxial polydactyly of the hand.

Keywords: *Electrocautery, Excision, Polydactyly*

Polydactyly is one of the most common congenital anomalies of the hand and it includes a spectrum of abnormalities ranging from a rudimentary extra digit to a fully formed and functional duplicate digit. The rudimentary type of extra digit could be observed both in pre- and postaxial polydactyly. Preaxial polydactyly is usually classified based on the Wassel-Flatt classification system, but there are still some rudimentary digit cases that could not be described properly.^{1,2)} Postaxial polydactyly is commonly divided into two types and the type B is defined as a rudimentary

extra digit attached only by a soft-tissue stalk.³⁾

The treatment of a rudimentary extra digit has mostly focused on the type B postaxial polydactyly. The treatment options are simple observation, suture ligation at early postnatal period, excision under local anesthesia at the outpatient clinic, and formal excision in the operating room with skin sutures.^{4,5)} Among them, the suture ligation in the early postnatal period has been accepted as a standard treatment due to its low cost and simplicity.⁴⁾ However, several complications including necrotized extra digit-related infection, parental distress, and a residual digit prominence at the operation site have been reported.^{4,6-8)} In addition, physicians other than orthopedic surgeons perform this procedure, but there is no consensus on the optimum time for intervention; and its effectiveness for the treatment of preaxial rudimentary polydactyly has yet to be proved. We have treated rudimentary preaxial polydactyly of the hand with excision using electrocautery. The purpose of this study was to describe our new technique

Received November 13, 2020; Revised May 10, 2021;

Accepted September 8, 2021

Correspondence to: Jae Kwang Kim, MD

Department of Orthopedic Surgery, Asan Medical Center, University of Ulsan College of Medicine, 88 Olympic-ro 43-gil, Songpa-gu, Seoul 05505, Korea

Tel: +82-2-3010-3536, Fax: +82-2-488-7877

E-mail: orth4535@gmail.com

using electrocautery and to assess its clinical outcomes.

METHODS

This study was approved by the Institutional Review Board of Asan Medical Center (IRB No. 2018-1082) and informed consent was waived.

Patient Enrollment and Characteristics

We performed this technique in some of the hypoplastic type preaxial polydactyly cases,²⁾ which satisfied the following conditions. First, regardless of the location of the extra digit, independent movement of the ulnar side main digit should be intact, and independent movement of the radial side extra digit should not be present. Second, there should be no evidence of a bony or cartilaginous connection between the main and the extra digit on physical examination and X-ray. Third, the proximal end of the extra digit should be pedunculated (pedunculated type) or at least the thickness of the proximal end should be thinner than that of the extra digit pulp (broad-based type). We defined the pedunculated type as an extra digit that is connected to the main digit with a narrow-elongated stalk and could freely rotate in 360° without resistance. We did not apply this technique when the base of the extra digit was wider than that of the extra digit pulp due to the risk of remnant tissue.

From June 2016 to March 2019, a total of 252 digits (237 patients) with preaxial polydactyly were surgically treated and had preoperative radiographs taken. According to the modified Wassel classification,²⁾ the number and type of the initial deformity were as follows: 1 type I, 29 type II, 9 type III, 65 type IV, 14 type V, 7 type VI, 11 type VIIA, 5 type VIIB, 27 HD type, and 84 HP type. A total of 37 digits (35 patients) with hypoplastic type preaxial polydactyly were treated by excision with use of electrocautery, among which 34 digits (32 patients) were followed up for more than 1 year. The mean follow-up period was 16.5 ± 4.5 months (range, 12–28 months). Twenty-one patients were boys and 11 were girls. The mean age was 2.4 ± 1.4 months (range, 1–7 months) and mean weight was 5.6 ± 1.4 kg (range, 3.2–8.3 kg) at the time of surgery. Twenty patients had polydactyly in the right hand, 10 patients in the left hand, and 2 patients in both hands. Twenty-four patients did not have any other congenital anomaly, 4 patients had a contralateral preaxial polydactyly of a different variety, 3 patients had polydactyly on the foot, and 1 had a sacral dimple.

Surgical Technique

All operations were performed under local anaesthesia by three orthopedic surgeons (YHS, JOY, and JKK). The patients were accompanied by either of their parents to the operation room. Instructions were provided to the parents about the surgical procedure with emphasis on holding their children properly during the procedure. The operation was performed with the parent in a sitting position, hugging the child in front of the chest. After an assistant held the patient's forearm and the extra digit, the base of the extra digit was swabbed with alcohol and approximately 1.0 mL 1% lidocaine was injected around its base. Next, an assistant held the tip of the extra digit and slight traction was applied to prevent any tissue remnant and neuroma formation near the skin. A bipolar electrocautery was applied from the peripheral to the central area. We adjusted the gaps between the bipolar tips according to the thickness of the tissue to cut in a single attempt. After removing the extra digit, the wound was examined for any bleeding or remaining tissue. When the cutting nerve ending was visible at the excision site, the nerve was pulled with forceps and cut at the most proximal level again. After the bleeding control, betadine was applied to sterilize the wound and a sterile bandage was applied.

Postoperative Management and Outcome Evaluation

Postoperatively, the dressing was changed every 2 to 3 days for 2 weeks. Two weeks after the surgery, the wound dried and a scar was formed in most cases. In some cases with incomplete scar formation, sterile dressing was continued for an additional 1 or 2 weeks. After scar formation, the patients were allowed to perform all activities including washing. A follow-up was done after 3, 6, and 12 months and standard posteroanterior and lateral radiographs were taken. The patients were then followed up annually. We also surveyed the parents' satisfaction level for this technique using the visual analog score (VAS) at the annual follow-up.⁹⁾ The VAS for satisfaction consists of a 100-mm-long horizontal line with two descriptors representing the extremes of satisfaction at the beginning and end of the line. Parents rated their satisfaction by making a vertical mark on the 100-mm line. The measurement in millimeters was converted into points, ranging from 0 (no satisfaction) to 10 (strong satisfaction). We retrospectively reviewed the medical records, including the parents' satisfaction level, radiographs, and gross medical photos of all patients to evaluate the clinical outcomes and occurrence of complications, including surgical site scar hypertrophy and residual digit prominence.

Statistical Analysis

The descriptive statistical analyses were performed using the IBM SPSS ver. 22.0 (IBM Corp., Armonk, NY, USA).

RESULTS

All operations were done in the same manner without reoperation. All the children had full range of motion without any deformity of the remaining thumb at the most recent follow-up. The location of the extra digit was around the interphalangeal joint level in 10 thumbs and around the metacarpophalangeal joint level in 24 thumbs. Twenty extra digits were pedunculated type and 14 were broad-based type.

There were no postoperative complications such as bleeding or infection. In 33 thumbs (97.1% of 34 thumbs), there were no signs of residual digit prominence (Figs. 1-3). One thumb had a residual digit prominence at the extra digit removal site, but the child's parents did not want a reoperation because it was small and painless (Fig. 4). In 2 thumbs of broad-based type, scar hypertrophy was evident at the operation site. Thirty of the 32 parents were very satisfied with this technique (VAS, 10) and the mean VAS score was 9.5 ± 2.0 (range, 0–10). One patient with scar hypertrophy at the excision site was moderately satisfied (VAS, 5) and another patient was not satisfied (VAS, 0) although there were no complications and no operation site abnormalities, and the parent had doubts regarding

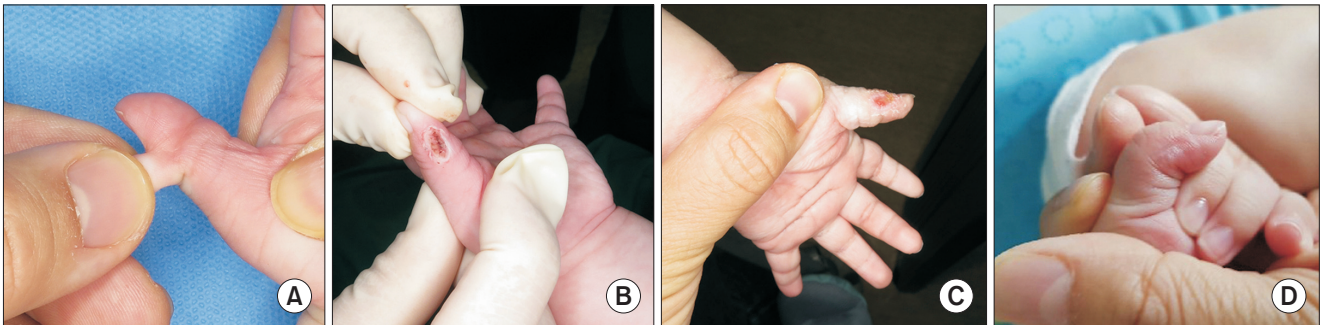


Fig. 1. (A) A 1-month-old girl had a broad-based extra digit at the thumb interphalangeal joint level. (B) Excision was performed with electrocautery. (C) At 2 postoperative weeks, scar tissue was not established yet at the operation site. (D) At postoperative 20 months, skin color and height were similar to the surrounding tissues. No recurrence or remnant of the extra digit was seen.

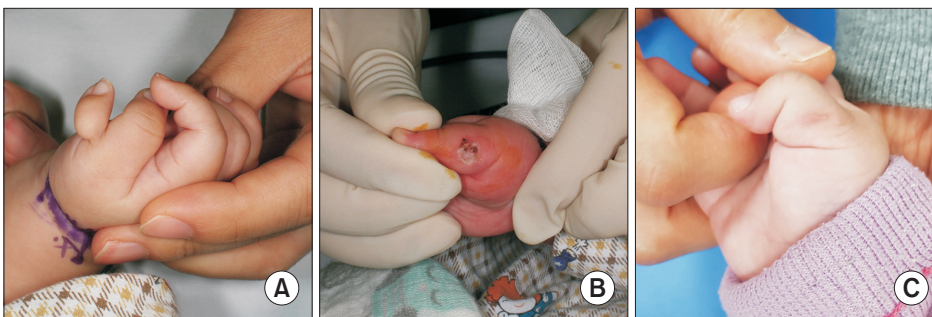


Fig. 2. (A) A 1-month-old boy had a pedunculated extra digit at the thumb metacarpophalangeal joint level. (B) Excision was performed with electrocautery. (C) At postoperative 19 months, no evidence of recurrence or residual digit prominence was found.

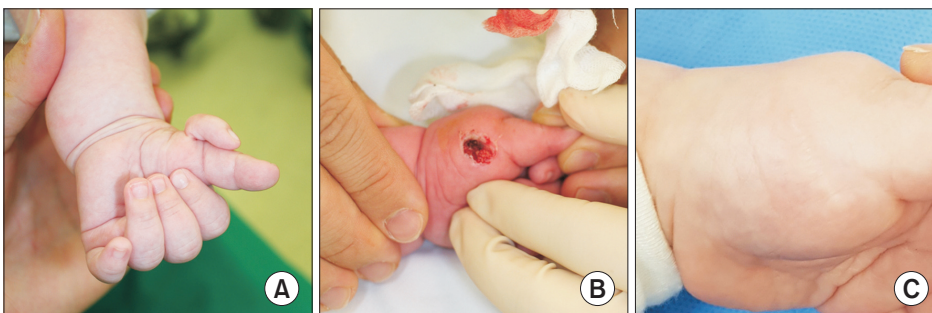


Fig. 3. (A) A 3-month-old boy had a broad-based extra digit at the thumb metacarpophalangeal joint level. (B) Excision was performed with electrocautery. (C) At postoperative 24 months, skin color and height were similar to the surrounding tissues. No recurrence or residual digit prominence was seen.

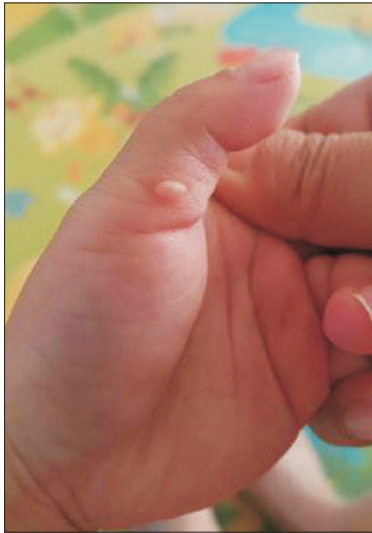


Fig. 4. A 2-month-old boy had a pedunculated extra digit at the thumb metacarpal level and excision was performed with electrocautery. At postoperative 14 months, a residual digit prominence remained at the previous extra digit site.

the rationale and reliability of this technique.

DISCUSSION

Suture ligation of rudimentary polydactyly has been typically performed in a nursery or a clinic by pediatricians, obstetricians, and orthopedic surgeons with or without local anesthesia.³⁾ By placing a suture around the base of the stalk of the rudimentary digit, blood flow is stopped, which induces ischemic necrosis. Therefore, this technique can be performed in extra digits with a pedunculated base, but not in those with a broad stalk as insufficient stalk compression could delay the necrosis. In addition, the necrotized extra digit could be a source of infection for the remaining digits and its appearance could cause parental distress.^{4,10)} Furthermore, this technique results in a residual digit prominence at the operation site in many patients. Watson and Hennrikus¹¹⁾ performed the suture ligation technique in 37 digits in 21 newborns with type B postaxial polydactyly and a bump was present in 43% of the digits. Along with traumatic neuroma formation, a bump increases the possibility of a child having discomfort when placing the ulnar border of the hand against a hard surface.³⁾

Vascular clip application at the outpatient clinic was to be a suitable substitute for suture ligation. It is cost-effective compared to surgical excision, with no acute complications and a low scar revision rate.¹²⁾ However, the application of multiple surgical clips to the base of the

stalk is technically demanding especially in broad stalk extra digits and maintaining the clips over 1 to 2 weeks is an additional problem. In addition, in case of an incomplete detachment, additional trauma can be induced with a needle after 2 weeks. Instead of inducing ischemic necrosis, excision of rudimentary polydactyly with a single swipe of a scalpel without cautery has been suggested.¹⁰⁾ To prevent neuroma formation on the skin, traction was applied on the extra digit during removal. The cosmetic results at the operation site were good. However, it was recommended observing all infants for 24 hours in the neonatal nursery to check for bleeding at the operation site. In addition, bleeding at the excision site could hinder a complete excision of the extra digit during the procedure.

Compared to previous techniques, our excision technique, which uses electrocautery, has several advantages. First, prompt removal of an extra digit did not cause problems related to ischemic changes of the digit. As parents could observe all the procedures and check the progress of the operation site daily, they were emotionally assured and satisfied with the outcomes. Second, bleeding at the operation site is not a problem in this technique. Third, this technique can be applied in cases with a broad-based stalk as the gap between the tips of the bipolar electrocautery could be adjusted. Finally, the cosmetic outcome was satisfactory. Although scar hypertrophy was seen at the operation site in 2 patients and a bump remained in 1 digit, 30 of the 32 parents were very satisfied with this technique.

The treatment of rudimentary preaxial polydactyly has not been described well previously.¹⁾ Several patients had this type of polydactyly, but could not be categorized according to the Wassel-Flatt classification system. The rudimentary extra digit of our patients existed in various locations from the interphalangeal joint to the metacarpal shaft with various configurations (broad stalk and pedunculated). A modified classification system that includes these thumbs should be designed.²⁾ In addition, the proper timing of suture ligation for rudimentary polydactyly is considered to be before the age of 1 month.⁷⁾ However, several patients underwent excision after 1 month and reported good clinical results in the current study. Therefore, the time limit for rudimentary polydactyly excision needs to be reconsidered.

Our study has several limitations. First, this retrospective study did not compare the results with those of other treatments including suture ligation, surgical clip application, and surgical excision. Second, the minimum 1-year follow-up is not long enough to evaluate the long-term outcomes of this technique. Further comparative

studies between treatment options with long-term follow-up are needed.

In conclusion, the excision of rudimentary preaxial polydactyly of the hand with the use of electrocautery could remove the extra digit completely in 97.1% of the cases. Excision using electrocautery may be a useful alternative to suture ligation, surgical clip application, and surgical excision for the treatment of rudimentary preaxial polydactyly of the hand.

CONFLICT OF INTEREST

No potential conflict of interest relevant to this article was reported.

ORCID

Young Ho Shin <https://orcid.org/0000-0002-9388-9720>
 Hyung Seo Jung <https://orcid.org/0000-0002-5770-9307>
 Hyun Seok Joo <https://orcid.org/0000-0001-8669-3984>
 Jae Kwang Kim <https://orcid.org/0000-0001-5104-4634>

REFERENCES

- Ochi K, Horiuchi Y, Takayama S, Saito H. Duplicated thumb with enormous soft-tissue oedema: pacifier type of thumb duplication. *Hand Surg*. 2011;16(1):91-3.
- Kim JK, Al-Dhafer BA, Shin YH, Joo HS. Polydactyly of the thumb: a modification of the Wassel-Flatt classification. *J Hand Surg Eur Vol*. 2021;46(4):346-51.
- Abzug JM, Kozin SH. Treatment of postaxial polydactyly type B. *J Hand Surg Am*. 2013;38(6):1223-5.
- Patillo D, Rayan GM. Complications of suture ligation ablation for ulnar polydactyly: a report of two cases. *Hand (N Y)*. 2011;6(1):102-5.
- Leber GE, Gosain AK. Surgical excision of pedunculated supernumerary digits prevents traumatic amputation neuromas. *Pediatr Dermatol*. 2003;20(2):108-12.
- Heras L, Barco J, Cohen A. Unusual complication of ligation of rudimentary ulnar digit. *J Hand Surg Br*. 1999;24(6):750-1.
- Dodd JK, Jones PM, Chinn DJ, Potokar T, Laing H. Neonatal accessory digits: a survey of practice amongst paediatricians and hand surgeons in the United Kingdom. *Acta Paediatr*. 2004;93(2):200-4.
- Mullick S, Borschel GH. A selective approach to treatment of ulnar polydactyly: preventing painful neuroma and incomplete excision. *Pediatr Dermatol*. 2010;27(1):39-42.
- Brokelman RB, Haverkamp D, van Loon C, Hol A, van Kampen A, Veth R. The validation of the visual analogue scale for patient satisfaction after total hip arthroplasty. *Eur Orthop Traumatol*. 2012;3(2):101-5.
- Katz K, Linder N. Postaxial type B polydactyly treated by excision in the neonatal nursery. *J Pediatr Orthop*. 2011;31(4):448-9.
- Watson BT, Hennrikus WL. Postaxial type-B polydactyly: prevalence and treatment. *J Bone Joint Surg Am*. 1997;79(1):65-8.
- Mills JK, Ezaki M, Oishi SN. Ulnar polydactyly: long-term outcomes and cost-effectiveness of surgical clip application in the newborn. *Clin Pediatr (Phila)*. 2014;53(5):470-3.