

Available online at www.sciencedirect.com

ScienceDirect

journal homepage: www.elsevier.com/locate/radcr

Case Report

Percutaneous transhepatic holmium laser lithotripsy for cholelithiasis and balloon dilation for common bile duct stone removal [☆]

Nguyen Thai Binh, MD, PhD^{a,b,#}, Tran Quoc Hoa, MD^{c,#}, Thieu-Thi Tra My, MD^a,
Nguyen Minh Duc, MD^{d,*}

^a Diagnostic Imaging and Interventional Radiology Center, Hanoi Medical University Hospital, Ha Noi, Viet Nam

^b Department of Radiology, Hanoi Medical University, Ha Noi, Viet Nam

^c Department of Human Anatomy, Hanoi Medical University, Ha Noi, Viet Nam

^d Department of Radiology, Pham Ngoc Thach University of Medicine, Ho Chi Minh City, Viet Nam

ARTICLE INFO

Article history:

Received 5 April 2022

Accepted 15 April 2022

Keywords:

Percutaneous transhepatic

Cholecystolithiasis

Common bile duct stone expulsion

Laser lithotripsy

ABSTRACT

Biliary lithiasis is common in clinical practice. We present the case of a 53-year-old man referred to our hospital with a history of biliary lithiasis. Abdominal magnetic resonance imaging revealed gallbladder stones and common bile duct stones. To avoid surgery, we opted to apply percutaneous transhepatic techniques to clear gallbladder and bile duct stones. This study reports our experience using these techniques, including percutaneous transhepatic holmium laser lithotripsy for cholelithiasis combined with balloon dilation to remove common bile duct stones and avoid open surgery.

© 2022 The Authors. Published by Elsevier Inc. on behalf of University of Washington.

This is an open access article under the CC BY-NC-ND license (<http://creativecommons.org/licenses/by-nc-nd/4.0/>)

Introduction

Gallstones are diagnosed in 20% of the population, and approximately 15% of patients present with stones in both the gallbladder and common bile duct (CBD) [1]. Until recently, surgery and endoscopic retrograde cholangiopancreatography (ERCP) were the most common methods used to treat gallstones, and ERCP remains the first-line treatment for CBD stones; however, this technique is not available to patients with gastrointestinal abnormalities, such as duodenal diver-

ticulum [2]. Surgery is an effective method, but disadvantages include the need for general anesthesia and the potential for intra- and postoperative complications. Percutaneous transhepatic (PT) stone removal represents an important management approach for gallstones that can be used for the clearance of gallbladder stones in patients with concomitant CBD stones [3]. Due to a general lack of awareness and limited safety evaluations, the efficacy of PT balloon dilation (PTBD) remains unclear, and this procedure is not widely employed [4].

[☆] Competing Interest: The authors declare that they have no competing interests.

* Corresponding author.

These authors contributed equally to this article as co-first authors.

<https://doi.org/10.1016/j.radcr.2022.04.029>

1930-0433/© 2022 The Authors. Published by Elsevier Inc. on behalf of University of Washington. This is an open access article under the CC BY-NC-ND license (<http://creativecommons.org/licenses/by-nc-nd/4.0/>)

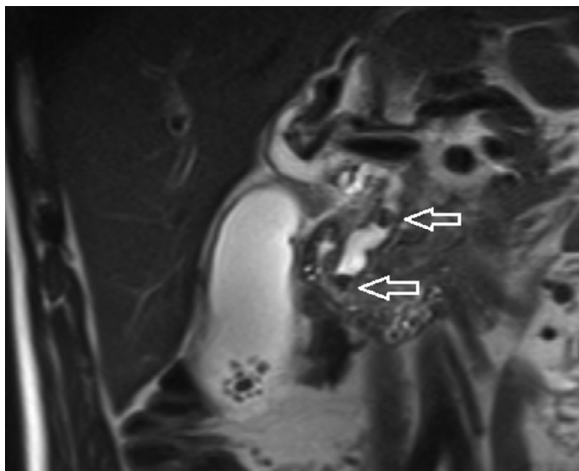


Fig. 1 – A 53-year-old man patient suffering from acute right upper quadrant abdominal pain underwent abdominal magnetic resonance imaging. Coronal T2-weighted image revealed 2 stones in the common bile duct (arrows) and multiple gallbladder stones

Case report

A 53-year-old man patient was referred to our hospital due to acute right upper quadrant abdominal pain for 1 day. He had a history of cholelithiasis over several years. Physical exami-

nation revealed mild jaundice, no fever, and other vital signs were normal. A blood test revealed an elevated total bilirubin level. Abdominal magnetic resonance imaging revealed multiple stones in the inferior portion of the gallbladder and 2 CBD stones (measuring 7 and 8 mm, Fig. 1). The gallbladder was increased in volume and presented with a thickened wall. The patient refused any operative approaches for the management of gallbladder and CBD stones Fig. 2.

Transhepatic access to the gallbladder was achieved using a 21-gauge needle guided by a combination of ultrasound and fluoroscopy. Lithotripsy for cholelithiasis was performed under direct endoscopic guidance using a holmium laser. The gallbladder stones were then grasped and extracted through the sheath using a stone basket. A guidewire was inserted into the CBD through the cystic duct and passed through the ampulla into the duodenum.

The papilla was dilated by inflating a balloon catheter to 12 mm. A cholangiogram was obtained to determine the occurrence of bile duct perforation. The CBD stones were pushed into the duodenum through the dilated papilla, and cholangiography was performed to ensure the absence of any residual stones. Four days after PTBD, a cholangiography was performed, and the drainage catheter in the CBD was removed.

Discussion

Current therapeutic approaches to cholelithiasis and choledocholithiasis can be performed in either 2 sessions or com-

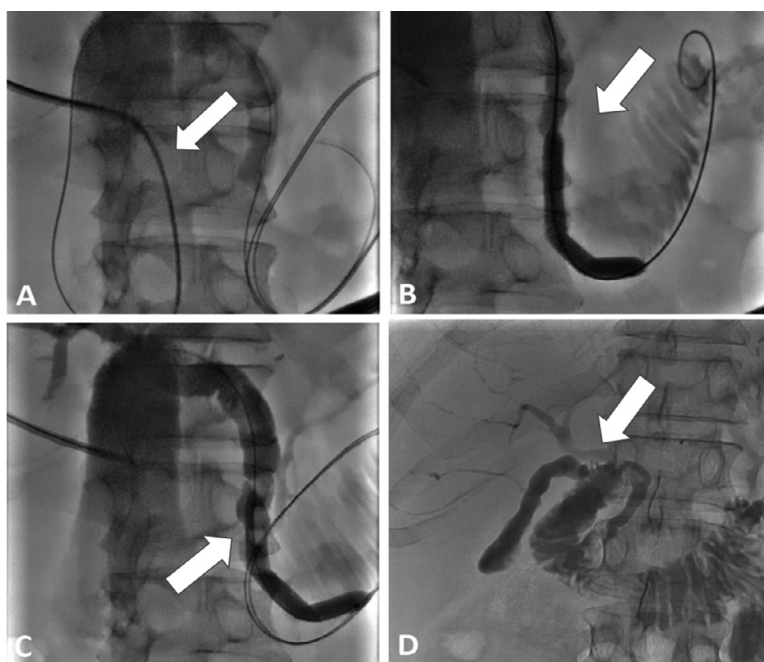


Fig. 2 – A 53-year-old man patient suffering from acute right upper quadrant abdominal pain underwent digital subtraction angiography. Cholangiograms of common bile duct (CBD) stone removal by percutaneous transhepatic papillary balloon dilation. (A) Two stones were visualized in the CBD (arrows). (B) The papilla was percutaneously dilated by inflating a large-bored balloon catheter. (C) An image obtained after dilation showed a spontaneously discharged stone through the dilated papilla. (D) Postprocedural cholangiography showed no residual stones, with contrast flowing directly into the duodenum

bined into 1 session [5]. PT stone removal into the duodenum without the use of balloon dilation was first reported in 1979 [6]. Since then, balloon dilatation of the sphincter of Oddi has been widely applied during this procedure to allow biliary stone passage with a high success rate [7]. For large stones, basket forceps, electrohydraulic lithotripsy, and laser lithotripsy are often applied to fragment the stones for easier passage [8]. For the management of gallbladder stones in patients with both gallbladder and CBD stones, some approaches have included surgery, extraction, and expulsion [1,5,9].

A meta-analysis examining the safety and efficacy of PTBD for removing CBD stones revealed that PTBD might be unsuitable for endoscopic procedures due to poor conditions, other comorbid diseases (eg, coronary artery disease, emphysema, pulmonary insufficiency, cardiac insufficiency, multiple sclerosis), or unsuccessful ERCP [4]. Patients with both CBD stones and gallbladder stones often require an additional procedure, such as laparoscopic choledochotomy and or a percutaneous transcystic procedure, for the removal of gallbladder stones. The study also demonstrated that PTBD had a high success rate of 98.1% for removing concurrent CBD and gallbladder stones, with a low rate of complications,

A study by Liu et al. [3] reported 17 patients who underwent PTBD for the management of gallbladder and CBD stones. PTBD was performed by puncturing the intrahepatic bile duct to remove CBD stones. The gallbladder stones were extracted to the CBD and pushed into the duodenum 1 week after PTBD. The successful removal rate using this technique was 94.1%.

Another study by MacCormick et al. [9] examining the percutaneous transcystic removal of gallbladder and CBD stones showed overall success rates of 84.9% for CBD stone extraction, 85.0% for gallbladder stone extraction, and 93.1% for CBD stone expulsion. This procedure allows for the removal of CBD and gallbladder stones via percutaneous cholecystostomy.

Some reported reasons for failure included severe CBD dilation, large stones, multiple stones, and bile duct stricture [4]. The incidence rate for complications was low (1.4%), and major complications can include cholangitis, bile duct hemorrhage, subcapsular biloma, subcapsular hematoma, bile peritonitis, pancreatitis, duodenal perforation, CBD perforation, and gastroduodenal artery pseudoaneurysm [3,4]. Minor complications include nausea, vomiting, and fever [4].

Although many non-operative approaches exist for the management of gallbladder and CBD stones, we attempted to remove all stones in a single session. A needle was used to achieve PT access to the gallbladder, and holmium laser lithotripsy was applied for cholelithiasis. A guidewire was placed into the CBD via the cystic duct to expel the stones into the duodenum. Transhepatic access to the gallbladder allows for the transhepatic tract to stabilize the catheter, reducing bile leakage into the peritoneum compared with transperitoneal access.

Conclusion

PT holmium laser lithotripsy for cholecystolithiasis combined with papilla balloon dilatation is an effective approach for removing stones in the CBD and gallbladder.

Patient Consent

Informed consent for patient information to be published in this article was obtained.

Author's contributions

Nguyen TB and Tran QH contributed equally to this article as co-first authors. Nguyen TB and Tran QH: Case file retrieval and case summary preparation. Nguyen TB and Nguyen MD: Case summary preparation and preparation of manuscript and editing. All authors read and approved the final manuscript.

Availability of data and materials

Data and materials used and/or analyzed during the current study are available from the corresponding author on reasonable request.

Ethics approval and consent to participate

Our institution does not require ethical approval for reporting individual cases or case series. Written informed consent was obtained from the patient(s) for their anonymized information to be published in this article.

REFERENCES

- [1] Li D, Li YL, Wang WJ, Liu B, Chang HY, Wang W, et al. Percutaneous transhepatic papilla balloon dilatation combined with a percutaneous transcystic approach for removing concurrent gallbladder stone and common bile duct stone in a patient with billroth II gastrectomy and acute cholecystitis: a case report. *Medicine (Baltimore)* 2017;96(35):e7964. doi:10.1097/MD.0000000000007964.
- [2] Ierardi AM, Fontana F, Petrillo M, Floridi C, Coccozza E, Segato S, et al. Percutaneous transhepatic endoscopic holmium laser lithotripsy for intrahepatic and choledochal biliary stones. *Int J Surg* 2013;11:S36–9. doi:10.1016/S1743-9191(13)60011-4.
- [3] Liu B, Wu DS, Cao PK, Wang YZ, Wang WJ, Wang W, et al. Percutaneous transhepatic extraction and balloon dilation for simultaneous gallbladder stones and common bile duct stones: a novel technique. *World J Gastroenterol* 2018;24(33):3799–805. doi:10.3748/wjg.v24.i33.3799.
- [4] Li YL, Li D, Liu B, Wang WJ, Wang W, Wang YZ. Safety and efficacy of percutaneous transhepatic balloon dilation in removing common bile duct stones: a systematic review. *World J Meta-Anal* 2019;7(4):162–9. doi:10.13105/wjma.v7.i4.162.
- [5] Cianci P, Restini E. Management of cholelithiasis with choledocholithiasis: endoscopic and surgical approaches.

- World J Gastroenterol 2021;27(28):4536–54.
doi:[10.3748/wjg.v27.i28.4536](https://doi.org/10.3748/wjg.v27.i28.4536).
- [6] Dotter CT, Bilbao MK, Katon RM. Percutaneous transhepatic gallstone removal by needle tract. *Radiology* 1979;133(1):242–3. doi:[10.1148/133.1.242](https://doi.org/10.1148/133.1.242).
- [7] Han JY, Jeong S, Lee DH. Percutaneous papillary large balloon dilation during percutaneous cholangioscopic lithotripsy for the treatment of large bile-duct stones: a feasibility study. *J Korean Med Sci* 2015;30(3):278. doi:[10.3346/jkms.2015.30.3.278](https://doi.org/10.3346/jkms.2015.30.3.278).
- [8] Ryu JK. Percutaneous approach for removal of difficult common bile duct stones. *Clin Endosc* 2013;46(1):3. doi:[10.5946/ce.2013.46.1.3](https://doi.org/10.5946/ce.2013.46.1.3).
- [9] MacCormick A, Jenkins P, Gafoor N, Chan D. Percutaneous transcystic removal of gallbladder and common bile duct stones: a narrative review. *Acta Radiol* 2022;63(5):571–6. doi:[10.1177/02841851211006915](https://doi.org/10.1177/02841851211006915).