

# Abnormal rate of human chorionic gonadotropin rise: a case series of patients with viable intrauterine pregnancies after embryo transfer

Lauren Kendall Rauchfuss, M.D., Alessandra J. Ainsworth, M.D., and Chandra C. Shenoy, M.D.

Department of Obstetrics and Gynecology, Mayo Clinic, Rochester, Minnesota

**Objective:** To report three cases of viable intrauterine pregnancies after embryo transfer with lower quantitative human chorionic gonadotropin (hCG) rates of rise than that expected in 99% of normal intrauterine pregnancies, based on current guidelines.

**Design:** Case series.

**Setting:** Tertiary care center.

**Patient(s):** Three patients underwent in vitro fertilization for ovulatory dysfunction or male factor infertility and had successful live births after an unusually low rate of hCG rise following embryo transfer.

**Intervention(s):** In vitro fertilization was utilized for all three patients.

**Main Outcome Measure(s):** Serial hCG levels.

**Result(s):** Three cases of abnormally rising hCG levels were described. All cases presented achieved pregnancy through assisted reproductive technologies. The lowest documented rate of rise for each case, over 48 hours, was 22.1%, 23.3%, and 26.9%. All three cases resulted in live births. Literature on this topic was reviewed.

**Conclusion(s):** Based on the cases presented, we recommend conservative management for patients found to have abnormally low rise hCG levels after embryo transfer; a high clinical suspicion for ectopic pregnancy should be maintained. (*Fertil Steril Rep*® 2021;2:129–32. ©2021 by American Society for Reproductive Medicine.)

**Key Words:** Early pregnancy, hCG rate of rise, embryo transfer

**Discuss:** You can discuss this article with its authors and other readers at <https://www.fertsterdialog.com/posts/xfre-d-20-00177>

Accurate diagnosis of an early intrauterine pregnancy, with or without viability, or an ectopic pregnancy is essential for appropriate management to maximize positive outcomes and minimize harm. Misdiagnosis can lead to either interruption of a desired viable pregnancy or an untreated ectopic pregnancy at risk of rupture. To aid in diagnosis, clinicians use clinical signs and symptoms, serial human chorionic gonadotropin (hCG) levels, and ultrasound criteria. In March 2018, es pre-

sented, we recommend conservative management for patients found to have abnormally low rise ACOG Practice Bulletin 191 cited a multicenter retrospective study of 285 women that published revised and lower thresholds for the rate at which hCG increase could be considered consistent with possible viability (1, 2). These values depended on the initial hCG level; 49% for hCG <1,500 mIU/mL, 40% for hCG 1,500–3,000 mIU/mL, and 33% for hCG >3,000 mIU/mL (2). We described three cases

of viable intrauterine pregnancy after embryo transfer with a lower hCG rate of rise than that seen in 99% of viable intrauterine pregnancies (3).

Currently, the same hCG thresholds are often used to establish pregnancy viability regardless of the method of achieving pregnancy (4). One previous study reported rates of rise as low as 30% measured 48 hours apart in 391 women who underwent in vitro fertilization (IVF) and were later found to have a viable intrauterine pregnancy (5). Our case series reports even lower rates of rise than has been previously described in patients following embryo transfer.

## CASE REPORT

All patients consented to the publication of their case. All reported hCG changes are over a 48-hour period.

Received August 31, 2020; revised November 22, 2020; accepted November 29, 2020.

L.K.R. has nothing to disclose. A.J.A. has nothing to disclose. C.C.S. has nothing to disclose.

Reprint requests: Lauren Kendall Rauchfuss, M.D., Mayo Clinic Minnesota, 200 First Street, Rochester, Mn 55905 (E-mail: [kendall.lauren@mayo.edu](mailto:kendall.lauren@mayo.edu)).

*Fertil Steril Rep*® Vol. 2, No. 1, March 2021 2666–3341

© 2021 The Author(s). Published by Elsevier Inc. on behalf of American Society for Reproductive Medicine. This is an open access article under the CC BY-NC-ND license (<http://creativecommons.org/licenses/by-nc-nd/4.0/>).

<https://doi.org/10.1016/j.xfre.2020.11.006>

### Case 1

This patient, 30 years old and G1P0 with a history significant for polycystic ovary syndrome with chronic anovulation, underwent four cycles of ovulation induction with intrauterine insemination and ultimately IVF with intracytoplasmic sperm injection (ICSI). On the day of transfer, a thawed single 5AA blastocyst, as defined by the Gardner blastocyst grading system, was transferred. Nine days after the embryo transfer, her hCG level was 131 mIU/mL. Forty-eight hours later, her hCG level was 160 mIU/mL, a 22.1% increase. Measurement of her hCG level was repeated 48 hours later, at which time it had risen to 225 mIU/mL, a 40.6% increase. A repeat hCG measurement and ultrasound were completed 1 week later, at approximately 5 weeks and 4 days gestation. At that time, the patient's hCG level was 2,778 mIU/mL, and an intrauterine gestational sac with yolk sac was visualized. The patient continued hormonal supplementation throughout this time, and a repeat ultrasound at 7 weeks and 6 days gestation confirmed a viable intrauterine pregnancy. She reported vaginal spotting at 11 weeks and 0 days, which resolved without consequence. Her antenatal course was notable for gestational hypertension for which she underwent induction of labor and ultimately had an emergency cesarean delivery for fetal indications, delivering a male neonate with a birth weight of 3850 g at 40 weeks and 5 days.

### Case 2

This patient was 36 years old and G3P0020 with a history of class I obesity (body mass index 35.6), male factor infertility, and one previous spontaneous pregnancy that resulted in early pregnancy loss. She previously completed two oocyte retrievals and one embryo transfer that resulted in a biochemical pregnancy. She then underwent transfer of a cryopreserved 4AA euploid blastocyst. Nine days after embryo transfer, her hCG level was 30 mIU/mL. Forty-eight hours later, her hCG level had risen to 37 mIU/mL, a 23.3% increase. Several hCG measurements repeated every 48 hours after the result of 37 mIU/mL was obtained showed an appropriate rise to 74 mIU/mL and then to 190 mIU/mL, a 100% and 156.8% increase, respectively. Expectant management was pursued. At 5 weeks and 6 days gestation by embryo transfer dating, ultrasound scan confirmed a viable intrauterine pregnancy. An ultrasound scan was repeated at 7 weeks and 5 days gestation and revealed appropriate growth and positive cardiac activity. She reported intermittent vaginal bleeding until 21 weeks gestation that resolved without consequence. Ultimately, she underwent induction of labor at 37 weeks and 5 days for gestational hypertension and had an uncomplicated vaginal delivery of a male neonate weighing 3,883 g.

### Case 3

This patient was 34 years old, G3P1011, with a history of male factor infertility and two previous pregnancies with a prior partner; she underwent IVF with testicular epididymal sperm extraction and ICSI. On the day of transfer, a single fresh 4AA blastocyst was transferred. Her hCG level was 73 mIU/mL 9 days after embryo transfer and rose to 108 mIU/mL 48 hours

later, a 47.9% increase. Given this borderline rise, measurement of her hCG level was repeated 48 hours later, showing a rise to 137 mIU/mL, a 26.9% increase, and again 48 hours later, showing a 35.8% rise to an hCG level of 186 mIU/mL. At this point, hormonal supplementation was discontinued and hCG measurement was repeated 48 hours later, this time rising from 186 mIU/mL to 371 mIU/mL, a 99.5% increase. Hormonal supplementation was restarted and an ultrasound scan was performed at approximately 5 weeks and 2 days gestation that showed no evidence of intrauterine or ectopic pregnancy. Her next ultrasound, performed at the patient's request at 5 weeks and 6 days gestation, showed a very small intrauterine gestational sac versus pseudosac with a size consistent with 4 weeks and 3 days gestation; at this time her hCG level was 1,614 mIU/mL. At 8 weeks and 1 day gestation, a repeat ultrasound scan revealed a viable intrauterine pregnancy. She reported vaginal bleeding at 12 and 13 weeks gestation. Ultimately, she had a cesarean delivery at 39 weeks and 3 days for fetal indications. She delivered a viable 3,100 g female neonate who was ultimately diagnosed with Apert syndrome.

## DISCUSSION

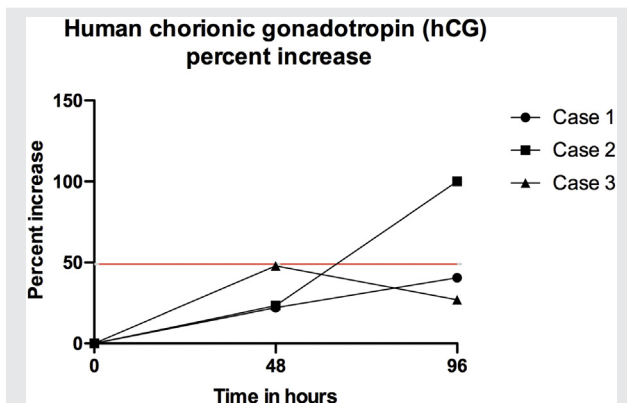
Women who pursue IVF have highly desired pregnancies but are also at higher risk for ectopic pregnancy, making abnormally rising hCG levels challenging to navigate for patients and providers alike. The cases presented highlight the need for caution in responding to abnormally rising hCG levels in patients after embryo transfer as conclusions of abnormal pregnancy may not be valid.

The caution required for interpretation of hCG levels in early pregnancy has been highlighted in recent publications; one case report noted a healthy live birth with a very low hCG level after embryo transfer and most notably, an ACOG practice bulletin recommended lower cutoffs for the rate of hCG rise and differing recommendations based on hCG level (1, 6). Relevant to the early pregnancies presented here, almost all viable intrauterine pregnancies will have a minimal 48-hour rate of increase of 49% for hCG levels <1,500 (1). Other investigators suggest even lower thresholds for a rate of hCG rise, citing increases of 30% or 35% associated with viable pregnancies (5, 7). Abnormal rates of rise have also been observed and reported in multiple embryo transfers but were less likely in single embryo transfers (8).

Similarly, ultrasound guidelines have become more conservative with the goal of preserving a desired viable intrauterine pregnancy. Recent data suggested broadening the discriminatory zone for hCG level from 1,500 to 3,500 mIU/mL, crown-rump length from 6 mm to 5.3 mm, gestational sac size from >20 mm to 25 mm, and days between scans from 7 to 14 to decrease the number of false positives leading to disruption of a normal pregnancy (9, 10).

A recently published study found that 99% of normal gestations will have a rise of at least 49% over 48 hours. The investigators clarify that this is not the threshold for viability (3). Our series highlights patients within this 1% of viable gestations who do not have the anticipated rate of rise of >49% over 2 days. These cases were identified from a 3-year period

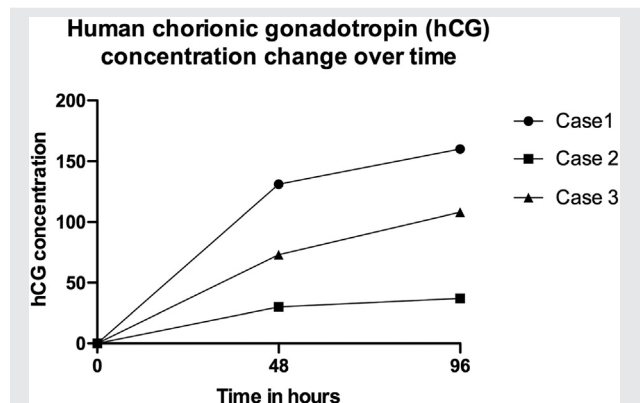
FIGURE 1



The human chorionic gonadotropin (hCG) level percent increases in the three patients. <sup>a</sup>Minimal rate of rise (49%) for 99% of viable intrauterine pregnancies with starting hCG level <1,500 mIU/mL.

Rauchfuss. Abnormal rate of hCG rise. Fertil Steril Rep 2021.

FIGURE 2



The human chorionic gonadotropin (hCG) level concentration change over time in the three patients.

Rauchfuss. Abnormal rate of hCG rise. Fertil Steril Rep 2021.

of time in a moderately sized assisted reproductive technology (ART) program that completes approximately 400 transfers per year with an ongoing pregnancy rate of 40%. Therefore, these patients represent approximately 0.6% of this clinic's total population. The lowest documented rate of increase for each case, collected 48 hours apart, was 22.1%, 23.3%, and 26.9%, respectively. Importantly, the initial levels were all <500 mIU/mL (131, 30, and 108 mIU/mL in cases 1, 2, and 3, respectively) (Fig. 1). A study by Morse et al. (7) in 2012 found that hCG levels <500 mIU/mL were exceptions to the defined increase pattern.

Embryo biopsy previously showed an association with lower initial hCG levels, although an abnormal trend in the rate of hCG rise has not been reported. Although one of the cases presented involved transfer of a euploid embryo, we do not think that this embryo biopsy explains the low rate of hCG rise after successful implantation (11). Each patient underwent elective single embryo transfer, so the likelihood of a vanishing twin to explain the abnormal rates of hCG rise was low.

There is a chance that the hCG assay reported erroneous measurements that could account for the low rates of rise in these cases. The hCG levels reported were obtained from the Cobas e immunoassay analyzer (Roche Diagnostics, Indianapolis, IN) using the sandwich principle. The intra-assay coefficient of variability ranged from 1.9% to 3.1%. The inter-assay coefficient of variability ranged from 1.7% to 5.5%. Because of this level of precision, there is a low probability that the observed rates of rise were due to hCG measurement error.

Compounding the uncertainty in the expected hCG rise in early pregnancy is the possible missed diagnosis of ectopic pregnancy or misdiagnosis of a nonviable pregnancy. hCG levels are used to reassure patients and providers of a viable intrauterine pregnancy; however, there are no established hCG levels or trends that differentiate an ectopic pregnancy from a failing intrauterine pregnancy. To aid in diagnosis, clinical correlation is recommended, taking into account

vaginal bleeding, uterine cramping, or acute abdominal pain. However, these symptoms may occur in both ectopic and intrauterine pregnancies that result in loss or live birth. A missed ectopic pregnancy can rupture, leading to the need for surgery and possible death. Rupture of an ectopic pregnancy can occur with very low hCG levels (12, 13). However, treating an unidentified intrauterine pregnancy as an ectopic pregnancy can lead to pregnancy loss, complications, and birth defects (10).

Accurate diagnosis is especially important in patients who have undergone ART, as these pregnancies are highly desired but the patients are at a higher risk of ectopic pregnancy (14). For patients who have undergone ART, there is an added clinical decision point of continuing or discontinuing luteal phase support. If hCG levels are thought to be abnormally rising, some practitioners could withdraw luteal phase support, which would then confound results or lead to miscarriage of otherwise viable and desired pregnancies. With so much at stake in the event of a misdiagnosis of an early viable pregnancy or ectopic pregnancy, more studies are needed to aid in determination of an appropriate hCG rise for patients who undergo IVF. Based on the cases presented, we recommend conservative management and continuation of luteal phase support for patients who are found to have abnormally rising hCG levels, particularly if the initial value is <500 mIU/mL, after embryo transfer while maintaining high clinical suspicion for ectopic pregnancy.

In conclusion, based on the cases presented, we recommend conservative management when following patients with abnormally rising hCG levels after embryo transfer while maintaining a high clinical suspicion for ectopic pregnancy.

## REFERENCES

1. ACOG practice bulletin no. 191: tubal ectopic pregnancy. *Obstet Gynecol* 2018;131:e65–77.
2. Barnhart KT, Guo W, Cary MS, Morse CB, Chung K, Takacs P, et al. Differences in serum human chorionic gonadotropin rise in early pregnancy

- by race and value at presentation. *Obstet Gynecol* 2016;128:504–11.
3. Barnhart KT, Senapati S, Sammel MD. Declaring a gestation nonviable: when 99% certainty is not enough. *Am J Obstet Gynecol* 2021;224:232–3.
  4. Zegers-Hochschild F, Altieri E, Fabres C, Fernandez E, Mackenna A, Orihuela P. Predictive value of human chorionic gonadotrophin in the outcome of early pregnancy after in-vitro fertilization and spontaneous conception. *Hum Reprod* 1994;9:1550–5.
  5. Chung K, Sammel MD, Coutifaris C, Chalian R, Lin K, Castelbaum AJ, et al. Defining the rise of serum HCG in viable pregnancies achieved through use of IVF. *Hum Reprod* 2006;21:823–8.
  6. Zheng Q, Xu S, Mo M, You J, Zeng Y. A live birth with unexpectedly low serum human chorionic gonadotropin level on day 11 after blastocyst embryo transfer: a case report. *F S Rep* 2020;1:48–50.
  7. Morse CB, Sammel MD, Shaunik A, Allen-Taylor L, Oberfoell NL, Takacs P, et al. Performance of human chorionic gonadotropin curves in women at risk for ectopic pregnancy: exceptions to the rules. *Fertil Steril* 2012;97:101–6.e2.
  8. Brady PC, Farland LV, Missmer SA, Racowsky C, Fox JH. Abnormal human chorionic gonadotropin (hCG) trends after transfer of multiple embryos resulting in viable singleton pregnancies. *J Assist Reprod Genet* 2018;35:483–9.
  9. Abdallah Y, Daemen A, Kirk E, Pexsters A, Naji O, Stalder C, et al. Limitations of current definitions of miscarriage using mean gestational sac diameter and crown-rump length measurements: a multicenter observational study. *Ultrasound Obstet Gynecol* 2011;38:497–502.
  10. Barnhart KT. Early pregnancy failure: beware of the pitfalls of modern management. *Fertil Steril* 2012;98:1061–5.
  11. Lu MM, Wen YX, Liu YL, Ding CH, Zhou CQ, Xu YW. Trophoctoderm biopsy reduces the level of serum  $\beta$ -human chorionic gonadotropin in early pregnancy. *Fertil Steril* 2020;114:801–8.
  12. Galstyan K, Kurzel RB. Serum beta-hCG titers do not predict ruptured ectopic pregnancy. *Int J Fertil Womens Med* 2006;51:14–6.
  13. Saxon D, Falcone T, Mascha EJ, Marino T, Yao M, Tulandi T. A study of ruptured tubal ectopic pregnancy. *Obstet Gynecol* 1997;90:46–9.
  14. Perkins KM, Boulet SL, Kissin DM, Jamieson DJ. Risk of ectopic pregnancy associated with assisted reproductive technology in the United States, 2001–2011. *Obstet Gynecol* 2015;125:70–8.