OPEN

PRS GLOBAL OPEN

ORIGINAL ARTICLE

Peripheral Nerve

Management of Superficial and Deep Peroneal Nerve Neuromas with Targeted Muscle Reinnervation in Nonamputees: Operative Technique and Early Outcomes

Simon Moradian, MD
Iulianna C. Taritsa, BA
Sripadh Sharma, MD, PhD
Lauren Mioton, MD
Gregory A. Dumanian, MD
Jason H. Ko, MD, MBA

Background: Targeted muscle reinnervation (TMR), a surgical technique developed by the senior authors that coapts proximal ends of nerves to distal motor nerves of adjacent muscles, has demonstrated efficacy in the treatment and prevention of neuroma pain. The objective of this study is to describe the surgical technique for TMR of the superficial peroneal nerve (SPN) and deep peroneal nerve (DPN) in nonamputee patients and provide data on postoperative functional outcomes.

Methods: A single-institution retrospective chart review was performed between March 2018 and April 2021. Patients were de-identified and included if they were nonamputees receiving TMR for pain in the peroneal nerve distribution. Data extracted included demographic information, symptoms before operation, relevant nerve coaptation, peri-, and postoperative complications, and long-term functional outcomes.

Results: Of the 19 patients reviewed, 11 patients underwent TMR of the SPN alone: eight had complete resolution of their symptoms; two indicated partial improvement in pain; and one patient had no improvement. Four patients underwent TMR of the DPN alone: two patients had complete resolution of their pain, and two patients had partial improvement with pain. Four patients underwent TMR of both the SPN/DPN: two patients had complete resolution of their symptoms, and two patients were noted to have significant improvement but had persistent pain from prior foot operations. Average follow-up time was 260 days.

Conclusions: TMR is a successful technique in the management of SPN and DPN neuroma pain. Our technique revealed excellent clinical outcomes, no procedure-specific complications, and improved subjective pain reports. *(Plast Reconstr Surg Glob Open 2024; 12:e5742; doi: 10.1097/GOX.0000000000005742; Published online 15 April 2024.)*

INTRODUCTION

More than 12 million Americans experience pain from peripheral nerve injuries (PNIs). PNIs resulting in symptomatic neuromas can significantly impact a patient's quality of life, as neuroma-related pain is associated with chronic opioid dependence and depression.[1,2] With no gold standard treatment, patients may visit a number of medical professionals for various interventions, creating a significant burden on the healthcare system.[1,2] Targeted muscle reinnervation (TMR) is an effective treatment for neuroma-related pain that involves coaptation of transected nerves to redundant nearby motor nerves.[3] Initially developed for amputees to intuitively control prostheses from intact native motor nerves whose targeted muscles

From the Division of Plastic and Reconstructive Surgery, Northwestern University Feinberg School of Medicine, Chicago, Ill.

Received for publication October 13, 2023; accepted February 20, 2024.

Presented at the American Society for Peripheral Nerve Scientific Program Committee Annual Meeting 2022 and Midwestern Association of Plastic Surgeons MAPS 60th Annual Scientific Meeting 2022.

Copyright © 2024 The Authors. Published by Wolters Kluwer Health, Inc. on behalf of The American Society of Plastic Surgeons. This is an open-access article distributed under the terms of the Creative Commons Attribution-Non Commercial-No Derivatives License 4.0 (CCBY-NC-ND), where it is permissible to download and share the work provided it is properly cited. The work cannot be changed in any way or used commercially without permission from the journal.

DOI: 10.1097/GOX.0000000000005742

Disclosure statements are at the end of this article, following the correspondence information.

Related Digital Media are available in the full-text version of the article on www.PRSGlobalOpen.com.

are no longer functional, TMR has since been successfully utilized in treating pain from PNIs—specifically, localized neuroma pain.[4,5] Histological and clinical studies have shown that excising the painful posttraumatic neuroma from the culprit sensory nerve and coapting the new terminus to the distal divided end of a motor nerve decreases the chances of recurrent painful neuroma formation, thus potentially improving the patient's quality of life.[6]

Typically, on examination, patients with neuropathies of the superficial (SPN) or deep peroneal nerve (DPN) have dysesthesias in the skin distribution supplied by the nerve, localized tenderness, and sometimes muscle weakness. Candidates for TMR have neuromas or severe nerve injuries—not compressive neuropathies—and typically have a history of a severe ankle sprain, ankle arthroscopy, or other prior ankle surgery that led to nerve injury and a neuroma-in-continuity or an end-neuroma formation in the distal SPN and/or DPN.

To date, there is a paucity of literature detailing successful treatment of SPN and DPN neuroma-related pain in the nonamputee patient population. Because of the long course of SPN and DPN before their targets, these nerves are particularly susceptible to injury. The nature of the damage to these nerves is such that reconstruction has not been a reliable option for treatment of pain. Specifically, neuroma excision in these patients may create large defects and sacrifice sensory nerves which may result in further nerve pain. Other options of sacrificing motor nerves (ie, to the vastus lateralis) greatly diminish muscle strength and are not preferable to the patient. Alternatively, the use of allografts or autografts is ineffective with larger-gap peripheral nerve defects.[7] Here, we describe a novel technique of treating SPN and DPN neuroma pain using TMR, along with a retrospective review of pain outcomes in patients who underwent SPN ± DPN TMR at our institution.

Takeaways

Question: What is the best surgical option for nonamputee patients with neuroma-related pain in the superficial peroneal nerve (SPN) and deep peroneal nerve (DPN) distribution? Can targeted muscle reinnervation (TMR), previously established as effective for treating neuroma pain in the amputee population, be an effective solution?

Findings: Our retrospective review showed that SPN/DPN TMR in our patients resulted in excellent clinical outcomes, no procedure-specific complications, and improved subjective pain reports.

Meaning: This study gives evidence supporting TMR as a promising route to treating SPN and DPN neuromas for nonamputees.

METHODS

Retrospective Review

institutional review board approval was obtained from Northwestern University to perform a retrospective chart review of qualifying patients. After review board approval, a retrospective chart review was performed of patient records captured between March 2018 and April 2021. Inclusion criteria were (1) older than 18 years of age, (2) past surgery of the leg to treat neuroma pain, and (3) underwent TMR of the peroneal nerve. Medical records were reviewed to collect demographic variables such as age, race, ethnicity, body mass index, smoking status, comorbidities, and any other prior operations. Operative notes were studied to obtain surgical technique and relevant anatomy for each case. Preoperative and postoperative notes were reviewed to capture patient-reported pain. Finally, notes were reviewed before and postoperatively to assess postoperative functional outcomes.

Anatomy of the Peroneal Nerves

Prior cadaver studies have described the anatomy of motor entry points in the upper and lower leg, but there are few clinical examples regarding the treatment of specific nerves used in TMR for neuroma pain.[8,9] In the case of SPN and DPN as they relate to TMR reconstruction, the common peroneal nerve branches from the lateral side of the sciatic nerve posterior to the distal end of the biceps femoris. It then enters the fibular tunnel (formed by the peroneus longus insertion and the fibula) posteriorly, where it bifurcates into the SPN and DPN. In approximately 10%–15% of individuals, this bifurcation may happen more proximally either at or proximal to the knee joint.[10] The SPN gives motor innervation to the lateral compartment of the leg (peroneus longus and brevis) as it descends inferiorly before piercing the investing crural fascia approximately two-thirds down the leg. Here, the SPN gives variable branches that form the purely sensory medial and intermediate dorsal cutaneous nerves that run superficial to the extensor retinacula to innervate much of the dorsum of the foot (except for the first webspace). The DPN travels through, and supplies motor innervation to, the anterior compartment of the leg, with the sensory component supplying the first webspace. There is segmental, redundant innervation of the SPN and DPN, as demonstrated by previous lower extremity cadaver studies.[8]

Operative Technique

Because of the long course of both SPN and DPN, deciphering which nerve(s) to be addressed and the planned surgical access incision should be based on the patient's physical examination. The patient's pain distribution and location of a Tinel sign, if present, should be documented, as well as the locations of prior surgical incisions. If neuroma-related pain is suspected, a local anesthetic block can be performed in clinic, and resolution of reported symptoms would serve as confirmation as to the nerves that are causing pain. In certain scenarios, imaging with an ultrasound or magnetic resonance imaging may be beneficial in confirming neuroma location.

In general for the nonamputee, the incision should be placed directly over the peroneus longus, measuring approximately 5 cm in length, centered at 30% leg length.[8] The SPN should be able to be found in this area

Fig. 1. A 10-cm longitudinally oriented incision 10 cm distal to the fibular head with a mark over the site of neuroma. The SPN exits the crural fascia 8–10 cm proximally to the marked neuroma. The longitudinal incision is made to find the motor target for the SPN. Further dissection will reveal the DPN.

first (Fig. 1). A neuroma of the SPN may be located as the nerve exits the fascia approximately 10 cm proximal to the lateral malleolus. It should be noted that the location of the incision may vary, as the most crucial aspect is operating proximally to the site of the neuroma. This is elicited on physical exam via a positive Tinel sign. If the neuroma is located more distally, a distal incision may be appropriate. Caution should be taken during the dissection distally, as the SPN can make a stark transition arising from the lateral crural septum into the subcutaneous space. A neuroma-in-continuity may appear as a bulbous contour in the nerve and can be hard on palpation.

The SPN should then be carefully released from the superficial septal layer overlying the nerve. Using careful blunt and sharp dissection, the SPN can be followed proximally. At this point, using an intraoperative nerve stimulator, a motor branch to an adjacent muscle should be identified. Prior cadaveric studies outlining the anatomy of the motor nerves of the lateral component of the lower leg highlight the number and location of major branch points and motor entry points in this compartment.[8] Interestingly, the peroneus longus was found to have the greatest number of motor entry points which were also more consistently located in the proximal lateral compartment as compared with the peroneus brevis. This quality, which was discovered through segmental innervation mapping of the lower leg, makes the peroneus longus the ideal target for TMR of neuromas of the SPN, DPN, and sural nerve.[8] Intraoperatively, the nerve stimulator should be judicially used in the proximal muscles to ensure there are enough motor end points to the muscle before motor nerve transection distally. Because of their proximity, motor nerves to peroneus longus, extensor digitorum longus (EDL), or extensor hallucis longus (EHL) are easiest to identify and use for the SPN TMR coaptation target (Fig. 2). [**See Video 1 (online),** which shows intraoperative nerve stimulation of the SPN with peroneus longus muscle contraction.] Motor nerve redundancy is important, conceptually so that the TMR nerve coaptation does not cause the patient to lose foot and ankle motor function. The motor target is often much smaller than the newly divided SPN and DPN terminals.

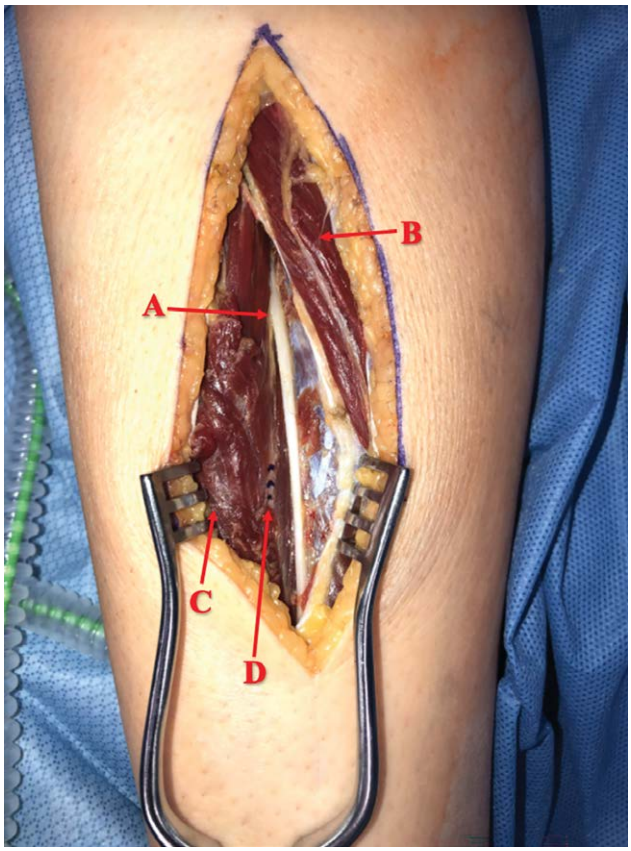

Fig. 2. SPN TMR anatomy and nearby motor targets. A represents the SPN, B is the peroneus longus muscle, C is the EDL muscle, and D is the motor nerve target of the EDL.

Fig. 3. Alternate distal incision choice for DPN/SPN exposure for TMR. The incision is more distally located, approximately 3 cm posterior and lateral to the tibia, 8–10 cm proximal to the lateral malleolus over the area of maximal tenderness and positive Tinel marked in the preoperative area.

After the SPN and its motor nerve target are identified, they are marked with a vessel loop, and further dissection into the anterior leg will identify the DPN (Fig. 3). The interval between the tibialis anterior and EHL is then identified, and the DPN can be located and released from

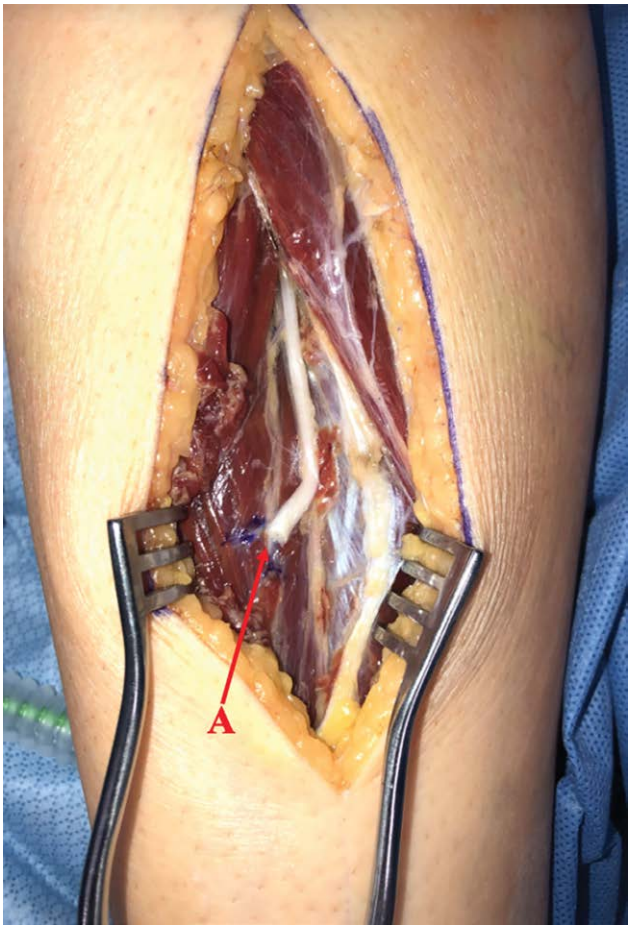

Fig. 4. DPN TMR anatomy. A represents the DPN. The DPN innervates the tibialis anterior, EDL, EHL, and peroneus tertius. The visualization of these motor targets may depend on the location of incision.

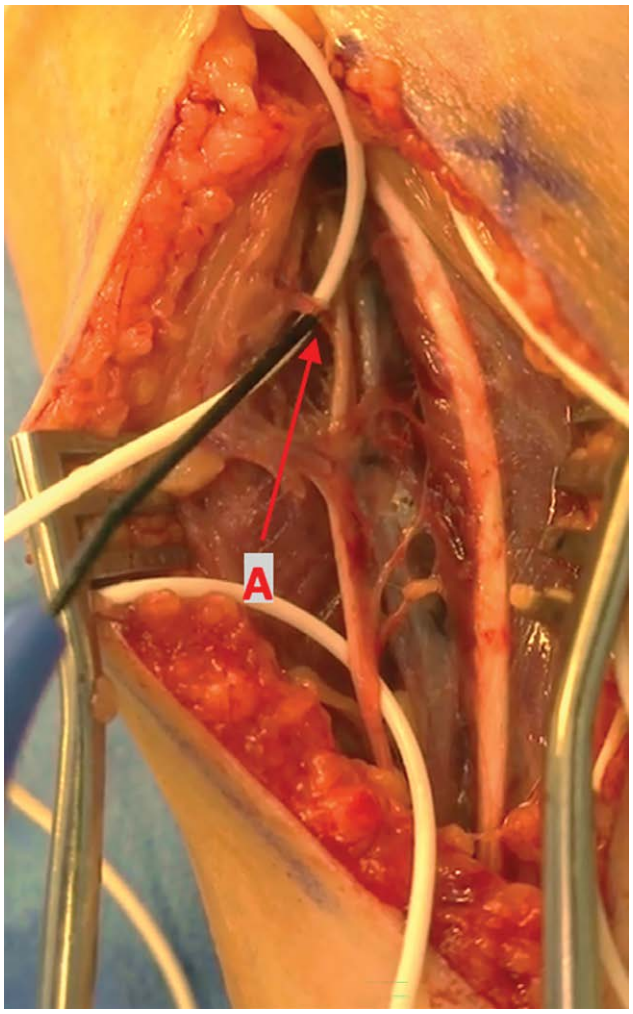

Fig. 5. SPN TMR anatomy with nerve coaptation. A represents the SPN to motor nerve of the (EDL) TMR nerve coaptation.

surrounding tissues. A redundant motor nerve can be identified in an adjacent muscle such as the tibialis anterior. This is then marked with a vessel loop and confirmed with the nerve stimulator, again ensuring proximal motor end points to the muscle to preserve its function before transection of the motor target distally (Fig. 4). [**See Video 2 (online),** which shows intraoperative nerve stimulation of the DPN with EDL contraction.]

It is controversial and unclear whether the affected SPN and DPN neuromas should be excised or if the nerve can simply be divided upstream of the neuroma. Leaving the neuroma in place limits the length of the incision and the surgical dissection, although there are infrequent cases when a disconnected neuroma remains painful and requires a second surgical intervention.

The free end of the affected sensory nerve can be brought over to the selected donor motor nerve to ascertain an ideal transection point along the motor nerve that would allow for a low-tension but not overly redundant coaptation. The property of being tension-free is crucial to a successful coaptation as it allows for faster axonal sprouting and final growth into motor nerve endplates.[11] In cases of doubt, alternating dorsiflexion and plantar flexion of the foot can help with visualization of muscle displacement and whether coaptation is adequate to ensure tension-free coaptation.

The motor nerve is then transected sharply, and end-to-end epineural coaptation ensues between the proximal end of the sensory nerve and distal end of the motor nerve using a 7-0 polypropylene monofilament suture (Fig. 5). Suture thickness is chosen based on ease of visualization using either 2.5× surgical magnification loupes or without magnification if that is the surgeon's preference.

RESULTS

Our search identified 19 nonamputee patients who underwent TMR of either the SPN or DPN based on their clinical presentation. Median age was 48 years old (range: 23–72), with 14 patients being women (73.68%) and five men. Median body mass index was 30.20 kg/m^2 (range: 20.45–51.83 kg/m^2). Two patients (10.52%) were recent smokers. Three patients (15.78%) had hypertension. All other medical comorbidities were noncontributory. All patients were nonamputees who had moderate-to-severe

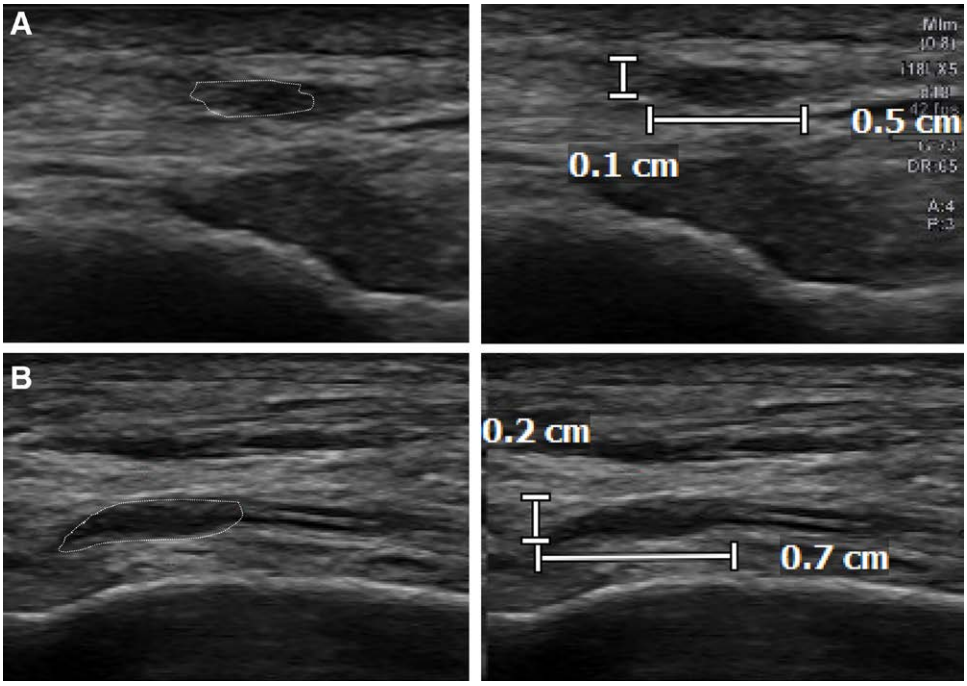

Fig. 6. A 39-year-old woman who previously had multiple orthopedic operations on the right ankle with neuromas/neuritis of the SPN and DPN. A, Focal neuroma-in-continuity of the SPN measuring 0.5 × 0.1 cm adjacent to the anterior inferior tibial fibular ligament. B, Focal neuroma-in-continuity of the DPN measuring 0.7 × 0.2 cm.

pain in the peroneal nerve distribution or described neuroma-like pain at the site of a prior surgical incision or traumatic injury site.

Preoperative imaging using ultrasound was obtained in nine of 19 of our patients before surgery, with four patients showing neuromas-in-continuity and one patient with an end-neuroma secondary to a transection of the SPN from a prior orthopedic surgery (Figs. 6 and 7). The remainder of the patients underwent preoperative diagnostic lidocaine injections at the maximal sites of pain/tenderness with pain relief in the SPN and/or DPN distribution, and in these cases, ultrasound imaging could be forgone.

The most common target muscle was the peroneus longus, but alternatives included motor nerves innervating the EDL, EHL, extensor digitorum brevis, and tibialis anterior (Table 1). The patients were seen between 1 month and 2 years after surgery with the average long-term follow-up being 260 days postoperation (range: 35–725 days). One patient was lost to long-term follow-up after their first postoperative visit but did report significant improvement in symptoms even at that singular visit.

Of these 19 patients, 11 patients underwent TMR of the SPN alone: eight had complete resolution of their symptoms, two patients indicated a reduction in pain but persistent tenderness over the dorsum of the foot, and one patient had no improvement upon follow-up at 6 months. Four patients underwent TMR of the DPN alone: all four patients had complete resolution of their pain. Four patients underwent TMR of both the SPN/DPN: two patients had complete resolution of their pain and symptoms in the SPN/DPN distribution, and two patients were noted to have complete resolution in their pain in the SPN/DPN distributions

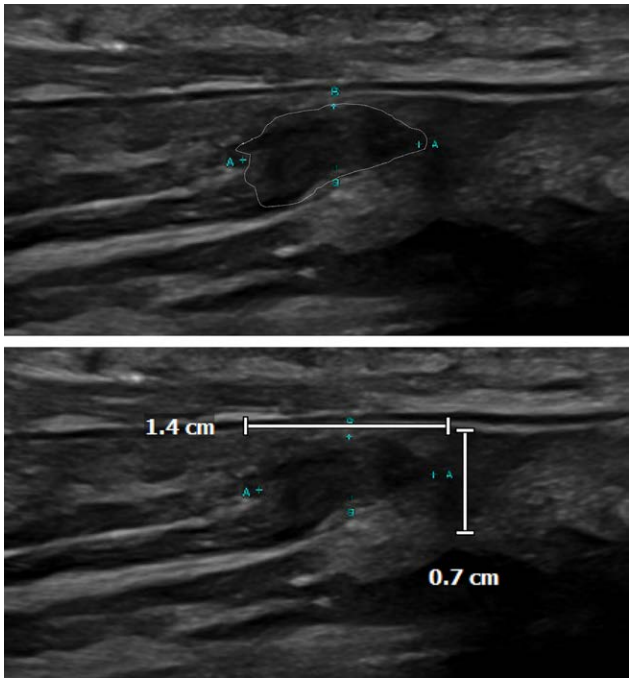

Fig. 7. A 22-year-old man who sustained a tibia/fibula fracture secondary to a motor vehicle accident with resultant complete laceration of the SPN at the level of the distal calf with focal traumatic end-neuroma formation measuring 1.4 × 0.7 cm.

but continued to have persistent dorsal foot pain and positive Tinel sign in areas of incisions from prior foot operations. They were later shown to have a sural nerve neuroma

Table 1. Target Muscles for TMR of the SPN or DPN

SPN TMR	14
Peroneus longus	7
EDL	4
EHL	3
DPN TMR	8
Tibialis anterior	5
Extensor digitorum brevis	1
Extensor pollicis brevis	1
EHL	1

and Morton neuromas. No functional motor deficits were observed postoperatively. Ultimately, 16 of 19 patients had complete resolution of their pain/symptoms at the most recent follow-up. [**See Video 3 (online)**, which shows a 40-year-old woman 6 months status post-SPN TMR.]

Case Example

One of these reported patients is a 35-year-old female patient who had previously undergone several orthopedic operations on her left foot and developed neuromas of the left DPN and SPN. The senior author performed regenerative peripheral nerve interface (RPNI) surgery to treat these neuromas. Like TMR, RPNI is done in amputees and nonamputees to treat severe nerve pain by wrapping the distant end of a severed peripheral nerve with a free muscle graft.[12] In this patient, neurolysis of the left SPN and DPN was performed, and then both nerves were wrapped with free muscle grafts harvested from the thigh. This patient continued to have significant persistent pain 20 months after her initial RPNI, so the senior author performed TMR to the SPN and DPN proximal to her RPNI sites. In this revision surgery, the left DPN was transferred to a motor point in the left tibialis anterior muscle. The left SPN was transferred to a motor point in the left EHL muscle. The procedure was done through a single incision. This specific example illustrates that the use of TMR in patients with recurrent nerve pain can be effective and, in this case, can be used to salvage a more distal neuroma treatment.

DISCUSSION

TMR has been established as a viable surgical option in the prevention and management of neuroma pain in both amputee and nonamputee patients.[6,13] By rerouting the sensory nerve endings to motor nerves in a nearby muscle, TMR directs nerve regeneration into the target muscle, which results in decreased neuroma formation and effectively alleviates residual limb pain and phantom pain in amputees.[5,6] This decreased pain corresponds with concomitant decreased rates of narcotic use.[14] The impressive potential of TMR to resolve neuroma pain can be explained by the clinical observation that cut motor nerves do not create symptomatic neuromas. There are little to no clinical reports in the literature of a painful motor nerve, largely due to the fact that motor nerves consist of approximately 50% sensory axons, which are predominantly proprioceptive, vibration-sensing, and pressure-sensing but not nociceptive.[15] Thus, performing TMR of a sensory nerve is believed to induce regeneration of the sensory nerves into the target muscle and reduce sensations of neuroma pain.

One potential downside of TMR in a nonamputee is the loss of motor nerve function caused by denervation. The likelihood of clinical motor downgrading is minimal because the major motor nerves of the ankle and toe dorsiflexors are located proximally in the leg relative to the distal neurotization and coaptation.[8] Furthermore, only small and redundant motor nerves are used as the recipient for TMR coaptation, which further ensures preservation of gross motor function.

We recommend TMR for patients who have pain from neuromas or severe nerve injuries that are not related to compressive neuropathy. These patients will often have a neuroma-in-continuity or an end-neuroma formation in the distal SPN and/or DPN as a result of a prior traumatic injury or surgery. In our experience, simple neurolysis for a neuroma-in-continuity has not been effective. In the case of a neuroma being too far proximal in relation to motor nerve branch points, we suggest reverting back to an allograft or autograft procedure. The authors only perform TMR surgery for neuromas or nerve injuries that are deemed "unreconstructable." Symptom onset before the procedure is not considered a barrier to effectiveness of the procedure. Rather, any patient with neuroma pain in the SPN/DPN distribution with the neuroma characteristics described is a potential candidate for this technique, regardless of time to presentation.

Limitations of this study include the retrospective nature of the study and that it is a single-institution study where all procedures were performed by two attending surgeons at Northwestern Memorial Hospital. The geographic location and training of the performing surgeons introduces bias to these results. This study also had a relatively small cohort for analysis. As TMR becomes more widely used, we expect future multi-institutional studies will be able to report on larger patient cohorts. Larger cohorts may be able to provide more racially diverse data. We recognize the need for objective, validated outcome metrics on pre- and postoperative patient-reported pain measures (Patient-Reported Outcomes Measurement Information System, visual analog scale). Capturing pre- and postoperative pain medication use may also be a way for future studies to analyze pain after the procedure in a more objective way. These represent avenues for future investigation.

CONCLUSIONS

TMR has emerged as a successful technique for the management of traumatic neuroma pain in both amputees and nonamputees. In this study, we have described the surgical technique for TMR of the SPN and DPN in nonamputee patients. This TMR technique has been used with good clinical outcomes and no procedure-specific complications in 19 patients with 84% of patients having complete resolution of their pain/symptoms.

Jason H. Ko, MD, MBA
Division of Plastic & Reconstructive Surgery
Department of Surgery
Northwestern University Feinberg School of Medicine
675 North Saint Clair Street, Suite 19-250
Chicago, IL 60611
E-mail: Jason.ko@nm.org

DISCLOSURES

G.D. is the inventor and founder of Mesh Suture, Inc, and is a consultant for Checkpoint Surgical, Inc. J.H.K. is a consultant for Checkpoint Surgical, Inc, Integra LifeSciences, Inc, KLISBio, and EDGe Surgical, Inc. He is on the Scientific Advisory Board of Mesh Suture, Inc. The other authors have no financial interest to declare.

REFERENCES

1. Grinsell D, Keating CP. Peripheral nerve reconstruction after injury: a review of clinical and experimental therapies. *Biomed Res Int.* 2014;2014:698256.
2. Taylor CA, Braza D, Rice JB, et al. The incidence of peripheral nerve injury in extremity trauma. *Am J Phys Med Rehabil.* 2008;87:381–385.
3. Kuiken TA, Dumanian GA, Lipschutz RD, et al. The use of targeted muscle reinnervation for improved myoelectric prosthesis control in a bilateral shoulder disarticulation amputee. *Prosthet Orthot Int.* 2004;28:245–253.
4. Cheesborough JE, Souza JM, Dumanian GA, et al. Targeted muscle reinnervation in the initial management of traumatic upper extremity amputation injury. *Hand (N Y).* 2014;9:253–257.
5. Souza JM, Cheesborough JE, Ko JH, et al. Targeted muscle reinnervation: a novel approach to postamputation neuroma pain. *Clin Orthop Relat Res.* 2014;472:2984–2990.
6. Dumanian GA, Potter BK, Mioton LM, et al. Targeted muscle reinnervation treats neuroma and phantom pain in major limb amputees: a randomized clinical trial. *Ann Surg.* 2019;270:238–246.
7. Kornfeld T, Vogt PM, Radtke C. Nerve grafting for peripheral nerve injuries with extended defect sizes. *Wien Med Wochenschr.* 2019;169:240–251.
8. Fracol ME, Janes LE, Ko JH, et al. Targeted muscle reinnervation in the lower leg: an anatomical study. *Plast Reconstr Surg.* 2018;142:541e–550e.
9. Agnew SP, Schultz AE, Dumanian GA, et al. Targeted reinnervation in the transfemoral amputee: a preliminary study of surgical technique. *Plast Reconstr Surg.* 2012;129:187–194.
10. Van den Bergh FR, Vanhoenacker FM, De Smet E, et al. Peroneal nerve: Normal anatomy and pathologic findings on routine MRI of the knee. *Insights Imaging.* 2013;4:287–299.
11. Pereira CT, Hill EE, Stasyuk A, et al. Molecular basis of surgical coaptation techniques in peripheral nerve injuries. *J Clini Med.* 2023;12:1555.
12. Woo SL, Kung TA, Brown DL, et al. Regenerative peripheral nerve interfaces for the treatment of postamputation neuroma pain: a pilot study. *Plast Reconstr Surg Glob Open.* 2016;4:e1038.
13. Thatte MR, Hiremath A, Goklani MS, et al. Peripheral nerve injury to the lower limb: repair and secondary reconstruction. *Indian J Plast Surg.* 2019;52:93–99.
14. Nigam M, Kim KG, Harbour P, et al. 6: Nerve blocks with targeted muscle reinnervation reduce acute postoperative opioid use in major lower extremity amputation. *Plast Reconstr Surg Global Open.* 2021;9:16–17.
15. Mioton LM, Dumanian GA, De la Garza M, et al. Histologic analysis of sensory and motor axons in branches of the human brachial plexus. *Plast Reconstr Surg.* 2019;144:1359–1368.