

Received: 2021.03.22

Accepted: 2021.05.08

Available online: 2021.05.20

Published: 2021.06.25

Extensive Facial Trichoblastoma – A Rare and Disfiguring Condition

Authors' Contribution:

Study Design A
Data Collection B
Statistical Analysis C
Data Interpretation D
Manuscript Preparation E
Literature Search F
Funds Collection G

ABCDEF 1 **Siti Nur Hidayah Abd Rahim**
BCDE 2 **Nur Ashikin Ahmad**
ACDEF 1 **Mohamed-Syarif Mohamed-Yassin**

1 Department of Primary Care Medicine, Faculty of Medicine, Universiti Teknologi MARA, Batu Caves, Selangor, Malaysia

2 Dermatology Unit, Department of Medicine, Faculty of Medicine, Universiti Teknologi MARA, Sungai Buloh, Selangor, Malaysia

Corresponding Author: Mohamed-Syarif Mohamed-Yassin, e-mail: syarif8258@uitm.edu.my

Conflict of interest: None declared

Patient: Female, 62-year-old
Final Diagnosis: Trichoblastoma
Symptoms: Nodular skin lesion • papular skin lesion
Medication: —
Clinical Procedure: —
Specialty: Dermatology • Family Medicine • Plastic Surgery

Objective: Rare disease

Background: Trichoblastoma is a rare, benign, cutaneous adnexal neoplasm arising from rudimentary hair follicles. The incidence and prevalence in the general population is unknown. However, most cases occur in adults aged 40 years and older.

Case Report: A 62-year-old woman presented to our primary care clinic for a hypertension and diabetes followup visit. The doctor, who had never seen the patient before, noticed several small lumps over the patient's eyebrows. After she removed her headscarf and face mask for a thorough examination, numerous skin-colored papules and nodules were seen on her nose, nasal bridge, forehead, and around her eyebrows. She was referred to a dermatologist, and a skin biopsy showed well-circumscribed dermal nests of basaloid cells, with peripheral palisading, and keratin horn cysts surrounded by dense fibrous stroma. These features were consistent with trichoblastoma. She was then referred to a plastic surgeon to discuss further management options. The patient finally chose laser ablation as she was fearful of the other more invasive surgical options.

Conclusions: This is a very rare case of extensive facial trichoblastoma. It highlights the need for clinicians to ensure optimal exposure when examining patients. It also highlights the role of biopsies for skin lesions of uncertain etiology. In this case, it helped to rule out basal cell carcinoma, which can be a more locally destructive condition than trichoblastoma. This case also serves as a reminder about the need for ongoing review and referral for further management for conditions for which previous treatment was unsuccessful.

Keywords: Basal Cell Carcinoma, Multiple • Neoplasms, Adnexal and Skin Appendage • Trichoepitheliomas, Multiple Desmoplastic

Full-text PDF: <https://www.amjcaserep.com/abstract/index/idArt/932320>




1086



—



5



12



Background

Trichoblastoma is a rare skin disease which is benign in nature. It usually presents as a papulonodular skin lesion on the head or neck. It may be confused with more common conditions such as rosacea or basal cell carcinoma. Identification of this condition is important as it may progress and become extensive, as in the present case. We present a case of an unfortunate woman who had extensive and disfiguring facial trichoblastoma for the past 30 years. This case underlines the need for referral to the appropriate specialist when a treatment is unsuccessful. It also serves as a reminder of the need for optimal exposure when examining patients, while considering the constraints of personal protective equipment use, especially during this Coronavirus Disease 2019 (COVID-19) pandemic period.

Case Report

A 62-year-old Malay woman presented to our primary care clinic for her regular hypertension and diabetes mellitus care visit. She had been diagnosed with these conditions several months earlier. Her medications were perindopril (8 mg daily), amlodipine (10 mg daily), metformin extended-release (500 mg nightly), gliclazide modified-release (30 mg daily), and atorvastatin (10 mg nightly). She did not smoke, drink alcohol, or use recreational drugs. Her family history was unremarkable except for a sister with nasal cancer diagnosed at the age of 57. This was the first time this doctor had seen her.

On examination, she wore a headscarf as a religious requirement, and a face mask, in view of the COVID-19 pandemic. Her blood pressure was 161/93 mmHg and pulse rate was 98 beats per minute, while her body mass index was 20 kg/m². Examination of her cardiovascular system and feet were unremarkable. During the consultation, the doctor noticed several small lumps over the patient's eyebrows. As she removed her headscarf and mask for a thorough examination, numerous skin-colored papules and nodules were seen on her nose, nasal bridge, forehead, and around her eyebrows (**Figures 1-4**). No ulcers or telangiectasias were seen. These lesions were soft, non-tender, and had no hypoesthesia.

On further questioning, she said that these lesions had initially developed 30 years earlier and had gradually become more widespread. They did not affect her breathing or sense of smell. Her relatives and friends kept commenting about them, and wherever she went, everyone would stare at her. She admitted to having low self-esteem because of these disfiguring lesions. She subsequently underwent laser therapy at a private medical clinic. Unfortunately, the lesions did not improve so she decided to discontinue the treatment as it was quite costly.

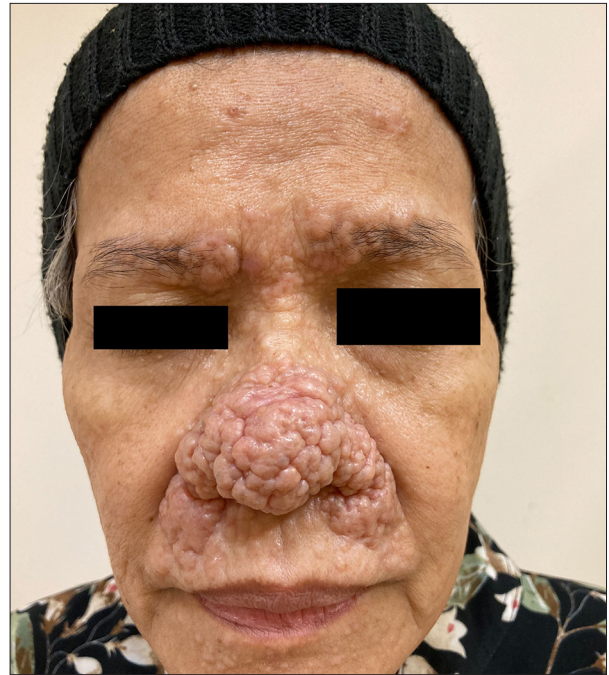

Figure 1. Multiple rounded whitish and skin-colored papules and nodules symmetrically distributed on the nasal and perinasal areas, eyebrows, and forehead.

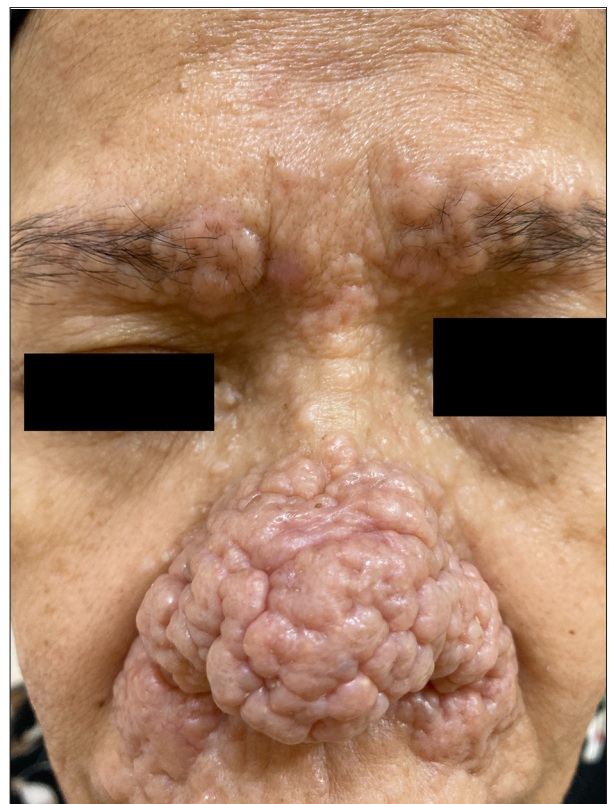

Figure 2. Closer view of multiple rounded whitish and skin-colored papules and nodules on the nasal and perinasal areas, eyebrows, and forehead.

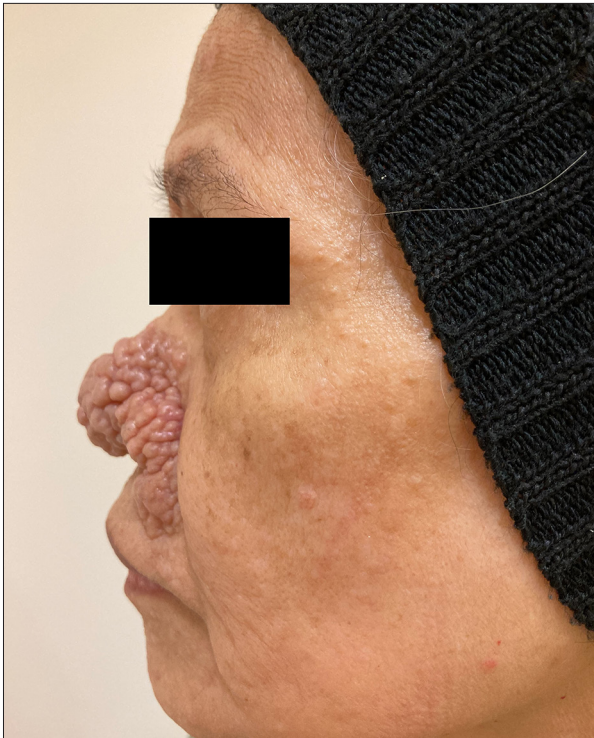

Figure 3. Numerous skin-colored papules on the left side of the patient's face, most prominent on the nose.

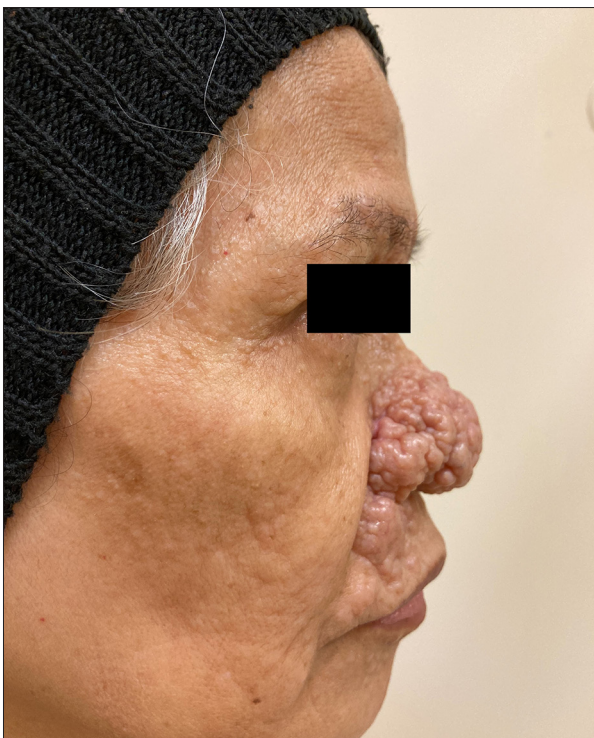

Figure 4. Numerous skin-colored papules on the right side of the patient's face, most prominent on the nose.

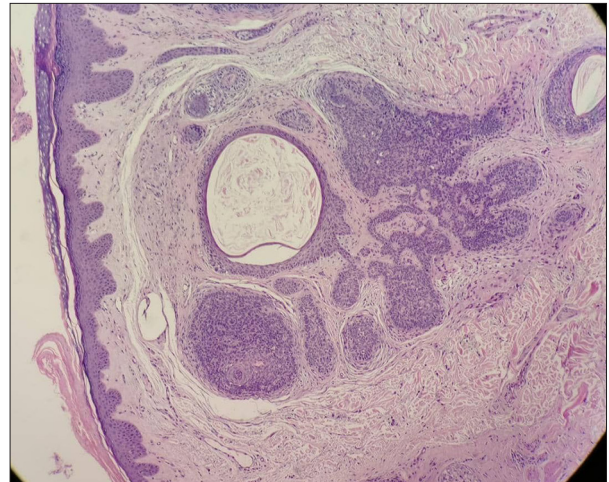


Figure 5. Photomicrograph of H&E-stained section showing well-circumscribed dermal nests of basaloid cells, with peripheral palisading, and keratin horn cysts surrounded by a dense fibrous stroma (4 \times).

A depression screen performed during this consultation did not show that she was depressed. Her latest blood laboratory results showed good glycemic and blood lipid control. She was advised to continue her current medications. She was also referred to a dermatologist for further assessment and management of her extensive facial skin lesions. A skin biopsy performed by the dermatologist showed well-circumscribed dermal nests of basaloid cells, with peripheral palisading, and keratin horn cysts surrounded by a dense fibrous stroma (Figure 5). These features were consistent with trichoblastoma. There was no evidence of malignancy. She was then referred to a plastic surgeon to discuss further management options. These options include serial carbon dioxide laser ablation, full thickness excision, full thickness skin graft, or reconstructive surgery. Laser treatment was chosen after detailed discussion with the patient.

Discussion

Trichoblastoma is a rare, benign cutaneous adnexal neoplasm arising from rudimentary hair follicles. There is a lack of data on its incidence and prevalence in the general population. However, most cases present in adults aged 40 years and older [1]. Trichoepithelioma is a subset of trichoblastoma, in which the neoplasm is composed of smaller islands of basaloid cells, occasionally just 1 or 2 cells thick, with significant fibrosis [1]. Trichoepithelioma may be associated with genetic conditions or syndromes such as Brooke-Spiegler disease and Brooke-Fordyce syndrome [2-4]. However, most cases are isolated and sporadic, and present with solitary lesions [5].

The main differential diagnosis for trichoblastoma is basal cell carcinoma (BCC), as both conditions may resemble each other clinically and dermatoscopically [6]. BCC of the skin is the most common type of cancer in humans [7]. It rarely metastasizes, but local invasion may lead to destruction of skin and other deeper tissues [8]. In contrast, trichoblastomas generally have a very low rate of malignant transformation [1]. Hence, both conditions require a histopathological diagnosis from a skin biopsy, to prevent undertreatment or overtreatment. Based on histological appearance, trichoblastoma can be further categorized as large nodular, small nodular, retiform, cribriform, racemiform, or columnar [4]. The presence of papillary-mesenchymal bodies, which are cuplike proliferations of basaloid cells engulfing fibroblasts, is a characteristic finding [2]. In comparison with BCC, the stroma of trichoblastoma is tightly associated with the basaloid epithelial cells, and there is a distinct demarcation between the periepithelial stroma and the surrounding dermal collagen [2].

Given the excellent prognosis, simple trichoblastoma may be managed with just ongoing clinical followup. As extensive trichoblastoma is very rare, there is a dearth of published evidence on the best management strategies and their success rates. Several treatment modalities have been proposed [1]. Mohs micrographic surgery is an option [9,10]. Nonsurgical destructive therapies, including curettage, cryosurgery, electric cauterization, and laser resurfacing have also been used for multiple small tumours, depending on the lesion sizes, location, and depth [4,10-12]. For this patient, laser treatment was chosen as she was fearful of the other, more invasive options. From the available literature on laser ablation for trichoblastoma,

it has shown good cosmetic results, good recovery, and minimal adverse effects [10]. Given the risk of recurrence [4,10], this patient will continue to be followed up at our primary care clinic for this condition, as well as for hypertension and diabetes management.

Conclusions

We present a very rare case of extensive facial trichoblastoma that highlights the need for clinicians to ensure optimal exposure when examining patients. This is especially relevant during this COVID-19 pandemic, when the usage of personal protective equipment may affect our ability to perform a thorough examination. This case also highlights the role of biopsies for skin lesions of uncertain etiology. It also serves as a reminder about the need for ongoing review and referral for further management for conditions when treatment is unsuccessful.

Acknowledgements

The authors would like to express our thanks to the patient for allowing us to publish her case and pictures. We would also like to acknowledge Dr. Awla Mohd Azraai from the Department of Pathology, Universiti Teknologi MARA for her assistance with the histopathology figure.

Conflict of Interest

None.

References:

1. North JP, McCalmont TH, Ruben BS. Cutaneous adnexal tumors. In: Post TW, editor. UpToDate. Waltham: Wolters Kluwer; 2021. <https://www.uptodate.com/contents/cutaneous-adnexal-tumors>
2. Prieto VG, Shea CR, Celebi JT, Busam KJ. Adnexal tumors. In: Busam KJ, editor. *Dermatopathology*. Philadelphia: W.B. Saunders; Elsevier Inc., 2010;381-436
3. Mandekou-Lefaki I, Theodosiou G, Delli FS, et al. Multiple nonfamilial unilateral trichoepitheliomas: Report of a case-mini review of the literature. *Case Rep Dermatol Med*. 2019;2019:6821854
4. Thomas LW, Pham CT, Coakley B, Lee P. Treatment of Brooke-Spiegler syndrome trichoepitheliomas with Erbium: Yttrium-Aluminum-Garnet laser: A case report and review of the literature. *J Clin Aesthet Dermatol*. 2020;13(7):41-44
5. Patel P, Nawrocki S, Hinthner K, Khachemoune A. Trichoblastomas mimicking basal cell carcinoma: The importance of identification and differentiation. *Cureus*. 2020;12(5):e8272
6. Ghigliotti G, De Col E, Parodi A, et al. Trichoblastoma: Is a clinical or dermoscopic diagnosis possible? *J Eur Acad Dermatol Venereol*. 2016;30(11):1978-80
7. Lacour JP. Carcinogenesis of basal cell carcinomas: Genetics and molecular mechanisms. *Br J Dermatol*. 2002;146(Suppl. 61):17-19
8. Crowson AN. Basal cell carcinoma: Biology, morphology and clinical implications. *Mod Pathol*. 2006;19(Suppl. 2):S127-47
9. Dohse L, Mowad C, Petrick M, Tyler M III. Trichoblastoma requiring four stages of Mohs surgery. *J Am Acad Dermatol*. 2009;60(3):AB193
10. Penev J, Bakardzhiev I, Chokoeva AA, et al. Disseminated trichoblastomas – successful treatment with CO2 laser. *J Eur Acad Dermatol Venereol*. 2016;30(12):e219-20
11. Zeller KA, Billmire DF. Trichoblastoma: Management of a rare skin lesion. *J Pediatr Surg*. 2012;47(1):250-52
12. Klein A, Bäuml W, Landthaler M, Babilas P. Laser thermal therapy of benign skin tumours: review and update. *Int J Hyperthermia*. 2011;27(8):762-70