

Anatomic investigation of lumbar transforaminal fenestration approach and its clinical application in far lateral disc herniation

Baoshan Xu, MD, PHD^{a,*}, Haiwei Xu, MD^a, Jean Destandau, MD^b, Xinlong Ma, MD^a, Jian He, MD^a, Qun Xia, MD^a, Ning Ji, MD^a, Qiang Yang, MD, PHD^a, Yue Liu, MD, PHD^a, Hongfeng Jiang, MD, PHD^a

Abstract

Treating lumbar disease at the intervertebral foramina is controversial because we lack an approach providing sufficient exposure and preserving spinal stability. The primary objective of this study was to investigate the feasibility of the transforaminal fenestration (TFF) approach for treating lumbar disease involving the intervertebral foramina.

In the anatomic study of 30 adult cadaveric lumbar spine specimens, the TFF approach was used from L1 to S1. The scope of resection was measured manually and on 3D CT images. 3D CT images of the lumbar spine of 31 adult patients were collected, and the scope of resection needed during the TFF approach was defined and measured from L1 to S1. In total, 30 patients (14 men) with lumbar FLDH underwent microendoscopic discectomy (MED) via the TFF approach. The results were evaluated with visual analog scale (VAS), Oswestry Disability Index (ODI), Short Form-36 survey (SF-36), and the MacNab scale.

In cadavers, the TFF approach provided sufficient exposure to the posterolateral aspect of the disc and the exiting nerve root at all segments. At L1 to L4, a relatively small part of the isthmus and facet joint was resected; at L4 to S1, a relatively large part of the isthmus and facet joint was resected, so uniform fenestration was needed to preserve a more inferior articular process and continuity of the isthmus. Treatment with MED via the TFF approach was successful in the 30 patients with significantly relieved of symptom after operation. In total, 24 patients were followed for a mean of 24 months. The VAS, ODI, SF-36 physical component, and mental component summary scores at the final follow-up improved significantly compared with preoperative data ($P < .05$), and excellent results were obtained in 19 patients and good results in 6 according to the Macnab scale.

The TFF approach can provide sufficient exposure to the lumbar intervertebral foramina with preservation of stability and can be used effectively with MED to treat lumbar FLDH.

Abbreviations: FLDH = far lateral disk herniation, MED = microendoscopic discectomy, mMED = mobile microendoscopic discectomy, ODI = Oswestry Disability Index, PELD = percutaneous endoscopic lumbar discectomy, TFF = transforaminal fenestration, VAS = visual analog scale.

Keywords: anatomy, far lateral disc herniation, lumbar spine, minimally invasive, transforaminal fenestration approach

1. Introduction

Far lateral disk herniation (FLDH) is a troublesome disease involving the intervertebral foramina.^[1] It accounts for 7% to 12% of all cases of lumbar disk herniation.^[2,3] The herniations

are localized within or lateral to the intervertebral foramina, with the exiting nerve root compressed and displaced.^[4,5] The herniated or sequestered disc materials are usually displaced cephalad, with only 20% at the level of the affected intervertebral space. Hence, extensive or through exploration is indispensable to achieve complete extraction of sequestered and fragmented disc materials. However, we lack a suitable approach for sufficient exposure and one that preserves the stability of the spine.^[6–10]

Surgical techniques used to treat lumbar FLDH have ranged from a conventional interlamina fenestration approach to the intertransverse approach and a post-lateral approach. For the conventional interlamina fenestration approach, the isthmus or inferior articular process needs to be resected to expose the intervertebral foramina, which causes instability of the spine.^[11–14] For the intertransverse approach, the soft tissue, such as ligamenta intertransversaria, needs to be separated. However, due to the complicated anatomy of intertransverse muscles, ligaments and blood vessels passing through them, it is not easy to make a clear exposure of intervertebral foramen and intervertebral disc, and usually a little bone needs to be resected.^[15] Exposure of the exiting nerve root through the intertransverse approach is difficult and dangerous since it is compressed between the soft tissues. In addition, full exposure of intervertebral foramen is difficult through the intertransverse approach, so the FLDH in the foramina cannot be exposed adequately. The post-lateral approach involves partial resection of the lateral part

Editor: Somchai Amorniyotin.

Funding: This study was supported by the National Natural Science Foundation of China (Nos. 81272046, 31500781), Natural Science Foundation of Tianjin (15JCYBJC25300), and Key Science Project of Tianjin Health and Family Planning Commission (14KG121).

The authors have no conflicts of interest to disclose.

^a Department of Minimally Invasive Spine Surgery, Tianjin Hospital, Hexi District, Tianjin, People's Republic of China, ^b Service de Neurochirurgie, Hôpital Bagatelle, Talence, France.

* Correspondence: Baoshan Xu, Department of Minimally Invasive Spine Surgery, Tianjin Hospital, Hexi District, Tianjin, People's Republic of China (e-mail: xubaoshan99@126.com).

Copyright © 2017 the Author(s). Published by Wolters Kluwer Health, Inc. This is an open access article distributed under the terms of the Creative Commons Attribution-Non Commercial License 4.0 (CCBY-NC), where it is permissible to download, share, remix, transform, and build up the work provided it is properly cited. The work cannot be used commercially without permission from the journal.

Medicine (2017) 96:29(e7542)

Received: 4 April 2017 / Received in final form: 24 June 2017 / Accepted: 26 June 2017

<http://dx.doi.org/10.1097/MD.0000000000007542>

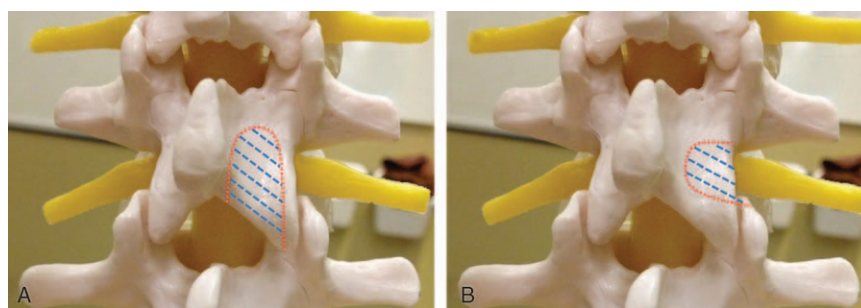


Figure 1. The transforaminal fenestration (TFF) approach. (A) Conventional interlaminar fenestration approach (shaded area). (B) TFF approach (shaded area). TFF = transforaminal fenestration.

of the isthmus for sufficient exposure of the disc, but the suitable range of resection has not been analyzed.^[16,17]

We proposed a transforaminal fenestration (TFF) approach with partial resection of the posterior wall of the intervertebral foramina. The proper scope of resection during the TFF approach was carefully measured and provided in this study to fully expose the intervertebral foramina, minimize the damage to soft tissue, lamina, and facet joints, and thus preserve spinal stability. The purpose of this approach is to treating diseases involving intervertebral foramina.

2. Materials and methods

2.1. TFF approach on cadaver specimens

2.1.1. Cadaver specimens. All procedures in this study were approved by the Ethics Committee of Tianjin Hospital. In this study, we examined 30 formalin-fixed adult lumbar spines (19 male spines; mean age of death 49.8 years [range 32–68 years]) to

study the scope of resection during the TFF approach. The skin, subcutaneous and muscle tissue were all cleared, leaving intact vertebrae, intervertebral discs, and ligaments from L1 to S1.

2.1.2. TFF approach. The TFF approach was designed to fully expose the intervertebral foramina (Fig. 1), and the borders of resection were as follows: the superior edge of the intervertebral foramina (inferior edge of vertebral pedicle) as the cephalic border; the inferior edge of the disc as the caudal border; and the endostoma of the intervertebral foramina (lateral edge of the dural sac and traversing nerve root) as the medial border. The TFF approach was performed on the 30 specimens.

2.1.3. Manual measurement. The specimens were manually measured by use of a caliper with accuracy 0.02 mm before and after the TFF approach. The following parameters (Fig. 2) were measured to investigate the variation from L1 to S1 segments and assess the scope of resection with the TFF approach.

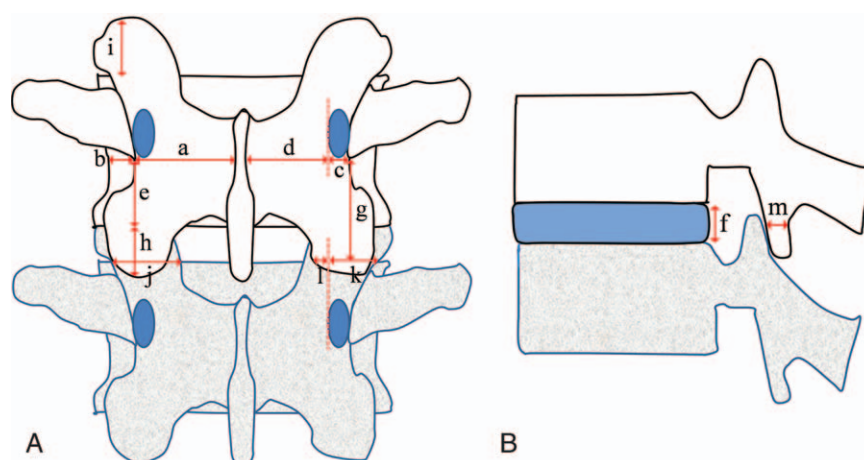


Figure 2. Parameters used to measure cadaver specimens before and after TFF approach. (A) Horizontal distance from the lateral edge of the isthmus to lineae mediana posterior; (B) horizontal distance from the lateral edge of the vertebral body to the lateral edge of the isthmus; (C) width of the resected cephalic lamina (horizontal distance from the lateral edge of isthmus to the inner edge of vertebral pedicle); (D) width of remaining cephalic lamina (horizontal distance from the lamina after resection to the midpoint of spinous process); (E) vertical distance from the inferior edge of the pars basilaris of the transverse process to the inferior edge of the vertebral body; (F) height of the posterior edge of intervertebral disc; (G) length of the resected lateral edge of the lamina (vertical distance from the inferior edge of vertebral pedicle to the inferior edge of intervertebral disc); (H) length of the inferior articular process (vertical distance from the inferior edge of upper vertebral body to the tip of inferior articular process); (I) Length of the resected superior articular process (vertical distance from the superior edge of the lower vertebral body to the top of superior articular process; as for the sacrum, the vertical distance from the top of superior articular process of sacrum to the plane of the sacral isthmus); (J) width between the medial and lateral edges of the facet joint at the inferior plane of intervertebral disc; (K) width of the facet joint resected (horizontal distance from the lateral edge of superior articular process to the inner edge of the pedicle at the inferior plane of the intervertebral disc); (L) width of the remaining inferior articular process (horizontal distance from the lateral edge of inferior articular process after resection to the inner edge of the inferior articular process); (M) minimum thickness of the remaining inferior articular process. TFF = transforaminal fenestration.

2.1.4. Radiographic measurement. Specimens underwent thin-slice CT and 3D reconstruction before and after the TFF approach with use of a 64-slice CT scanner (Siemens, Germany). The parameters measured manually above were measured on 3D CT images.

2.2. Measurement of parameters in patients on 3D CT

We used thin-slice CT imaging of L1-S1 for 31 patients (17 males; mean age 51.6 years [range 29–66 years]) with low back pain but no bone-structure abnormalities who were seen in our hospital from January 2008 to December 2010. The CT images were used for 3D reconstruction of the lumbar spine. The range needed to be resected from L1 to S1 during the TFF approach was determined according to the above experiments. The parameters in Fig. 2 were measured on 3D CT images.

2.3. Clinical application of the TFF approach

2.3.1. Patients. From December 2007 to September 2011, 30 patients (14 males; mean age 54.3 years [range 36–81 years]) with lumbar FLDH underwent the TFF approach. All patients had severe radicular leg pain on the side of disc herniation, and numbness in the corresponding innervation area. Twenty patients of L4/5 and L5/S1 herniation had weakness of foot dorsiflexion, and 3 patients of L3/4 herniation had weakness of knee extension. Decreased knee reflex or achilles tendon reflex was found on the affected side in all the patients. The duration of illness was from 3 months to 3 years, with an average of 1.2 years. Prior conservative treatment achieved poor results. The preoperative visual analog scale (VAS) score was 8.9 ± 2.2 , and the Oswestry Disability Index (ODI) score was 39.6 ± 2.9 . The Short Form-36 survey (SF-36) physical component summary score and mental component summary score were 34.1 ± 4.5 and 39.3 ± 6.7 , respectively.

According to preoperative MRI, the sequestered nucleus was localized within or lateral to the intervertebral foramina and originated from L3–4 in 5 patients, L4–5 in 14, and L5/S1 in 11. The direction of migration was cranial in all patients. Clinical symptoms and signs were consistent with imaging findings.

2.3.2. Mobile microendoscopic discectomy. The mobile microendoscopic discectomy (mMED) system (Endospine, Karl Storz, Germany) was used with all 30 patients. The system is self-balanced and not fixed on the operating table. The operating tube contains 3 integrated channels, for the endoscope, suction tube, and surgical instruments, which allows all the components to work together without disturbing each other. The surgeon can freely tilt the operating tube with suction or surgical instruments in all directions, with a movable field of vision, thus facilitating the use of surgical instruments.

2.3.3. Surgical method. All procedures were performed with patients under general anesthesia. The patient was placed in the prone position with the abdomen free and the spine flexed to open the interlaminar space. A vertical incision about 2 cm was made beside the spinous process on the affected side. The subcutaneous tissue and deep fascia were dissected with use of scissors. Tissue scissors were used close to the spinous process to retract the muscle along the direction of the intervertebral space and a 12-mm osteotome was used for subperiosteal dissection of the paraspinal muscles. The working channel with an obturator was placed on the lamina. Then, the obturator was removed and the soft tissue in the working

channel was cleaned out to expose the lateral border of the isthmus and the facet joint. The surgical instruments and the endoscope were placed in the working channel. The lateral border of the isthmus and facet joint was removed by high-speed burring until the lateral parts of the ligament flavum had been exposed. The ligament flavum was removed and the exiting nerve root was identified directly beneath the ligament. The fenestration was expanded inward along the direction of the exiting nerve root, and the free fragments and herniated disc materials were exposed at the medial and ventral side of the exiting nerve root. The sequestered herniations and any intraforaminal disc fragments were removed. The exiting nerve root, especially the ventral side of the nerve root, was carefully examined for residual fragments. If the annulus was torn, an incision was made and the remaining portion of the pulposus was removed to prevent recurrent disc herniation. The intervertebral space was washed with normal saline. The working channel and gauze piece were removed before applying sutures.

2.3.4. Postoperative treatment and follow-up. Patients were encouraged to walk the day after surgery, and all patients had CT scan and x-ray examination. Patients were followed-up at 3 months, 6 months, and every year, and x-ray examination was performed at every year. Clinical outcomes were evaluated by VAS, ODI, SF-36, and Macnab criteria.^[18] The Macnab criteria were evaluated as follows: excellent—being able to do all activities, with no pain or restriction; good—occasional pain with relief of symptoms and return to work with some modification; fair—improved function but still handicapped or unemployed; and poor—symptoms of root involvement or repeat surgery at the index level.^[19] Recurrence of lumbar disc herniation was defined as ipsilateral or contralateral disc herniation at the same surgical level, with a pain-free interval more than 6 months.^[20,21]

2.4. Statistical analysis

Data were analyzed by use of SPSS 16.0 (Chicago, IL) and were expressed as mean \pm SD. Differences between groups were assessed by the paired *t* test (Table 1 vs Table 2) and the unpaired *t* test (Table 3 vs Table 2 or Table 1, VAS, ODI, SF-36). *P* < .05 was considered statistically significant.

Table 1

Measurement of cadaver specimens manually (mean \pm SD, n=30).

Measurement, mm	Segments				
	L1–2	L2–3	L3–4	L4–5	L5/S1
a	13.8 \pm 1.8	14.6 \pm 1.5	16.8 \pm 2.2	20.5 \pm 1.7	22.8 \pm 2.4
b	7.2 \pm 1.3	6.8 \pm 1.8	5.8 \pm 1.8	4.5 \pm 1.6	3.3 \pm 2.2
c	1.8 \pm 1.2	2.5 \pm 1.6	3.5 \pm 1.6	4.6 \pm 1.3	5.8 \pm 1.5
d	11.6 \pm 1.5	12.2 \pm 1.7	12.8 \pm 1.9	13.1 \pm 1.2	15.2 \pm 2.2
e	10.3 \pm 2.2	9.8 \pm 1.8	8.3 \pm 1.5	7.8 \pm 1.6	7.6 \pm 1.8
f	4.5 \pm 0.5	4.8 \pm 0.8	5.6 \pm 1.1	6.7 \pm 0.8	7.6 \pm 0.8
g	8.3 \pm 2.1	9.5 \pm 1.7	10.8 \pm 2.2	12.2 \pm 1.5	14.5 \pm 1.6
h	12.6 \pm 2.8	13.8 \pm 1.8	14.6 \pm 1.6	13.5 \pm 2.8	14.8 \pm 2.5
i	7.3 \pm 1.2	7.5 \pm 1.3	7.6 \pm 1.6	8.5 \pm 2.2	6.5 \pm 1.8
j	10.8 \pm 1.8	15.3 \pm 1.6	17.6 \pm 1.2	18.5 \pm 1.6	19.6 \pm 1.8
k	8.5 \pm 1.8	10.8 \pm 1.2	14.5 \pm 1.2	16.8 \pm 2.3	17.6 \pm 1.8
l	4.5 \pm 1.2	3.8 \pm 1.5	3.5 \pm 1.3	2.8 \pm 1.2	2.2 \pm 1.8
m	6.5 \pm 1.2	5.8 \pm 1.1	5.5 \pm 1.5	3.8 \pm 1.3	3.3 \pm 1.2

SD = standard deviation.

Table 2**Measurement of cadaver specimens on CT (mean \pm SD, n=30).**

Measurement, mm	Segments				
	L1–2	L2–3	L3–4	L4–5	L5S1
a	13.1 \pm 2.0	13.9 \pm 1.6	16.4 \pm 1.5	19.6 \pm 2.2	21.9 \pm 2.4
b	6.3 \pm 2.2	6.3 \pm 1.3	5.1 \pm 1.7	4.6 \pm 2.1	3.2 \pm 1.5
c	1.7 \pm 2.5	1.8 \pm 2.2	3.3 \pm 1.4	4.5 \pm 1.7	5.5 \pm 1.6
d	11.3 \pm 1.2	11.5 \pm 1.9	12.2 \pm 1.8	13.5 \pm 1.2	14.2 \pm 2.2
e	10.5 \pm 2.5	9.6 \pm 1.5	8.5 \pm 1.5	7.6 \pm 2.2	7.3 \pm 2.2
f	4.8 \pm 1.2	4.6 \pm 0.8	5.6 \pm 1.5	6.3 \pm 1.3	7.4 \pm 0.7
g	7.5 \pm 1.6	8.8 \pm 1.8	9.9 \pm 1.8	11.6 \pm 1.8	13.8 \pm 2.2
h	12.5 \pm 2.5	13.6 \pm 1.5	14.8 \pm 1.8	13.8 \pm 1.8	14.3 \pm 2.2
i	6.8 \pm 1.3	6.9 \pm 1.3	7.6 \pm 1.8	8.3 \pm 1.2	7.3 \pm 1.6
j	10.8 \pm 1.3	14.8 \pm 1.7	17.8 \pm 1.2	18.8 \pm 1.5	19.2 \pm 1.2
k	7.8 \pm 1.3	10.3 \pm 1.5	13.8 \pm 1.9	15.9 \pm 2.1	17.3 \pm 1.2
L	4.2 \pm 1.8	3.8 \pm 1.1	3.3 \pm 1.2	2.8 \pm 1.2	2.5 \pm 1.1
M	5.8 \pm 1.8	5.2 \pm 1.7	4.9 \pm 1.5	3.3 \pm 1.1	3.1 \pm 1.2

CT = computed tomography, SD = standard deviation.

Table 3**Measurement of patients on CT (mean \pm SD, n=31).**

Measurement, mm	Segments				
	L1–2	L2–3	L3–4	L4–5	L5S1
A	13.2 \pm 1.8	14.1 \pm 1.6	15.9 \pm 1.8	19.9 \pm 1.5	22.3 \pm 2.5
B	6.8 \pm 1.3	6.5 \pm 1.8	5.5 \pm 1.7	4.3 \pm 1.2	2.8 \pm 1.4
C	1.5 \pm 1.8	2.1 \pm 1.8	3.0 \pm 1.9	4.2 \pm 1.6	5.1 \pm 1.6
D	11.1 \pm 1.8	11.7 \pm 1.2	12.4 \pm 1.7	13.4 \pm 2.0	14.8 \pm 1.8
E	11.3 \pm 1.8	10.3 \pm 1.6	8.5 \pm 1.8	7.6 \pm 1.5	7.2 \pm 1.8
F	4.5 \pm 0.8	4.3 \pm 1.1	5.8 \pm 1.3	6.6 \pm 0.9	7.5 \pm 1.2
G	8.1 \pm 1.7	9.6 \pm 2.0	10.1 \pm 1.5	12.1 \pm 1.3	14.8 \pm 2.5
H	12.3 \pm 1.5	13.3 \pm 1.8	14.2 \pm 1.2	14.1 \pm 1.6	14.5 \pm 1.2
I	6.8 \pm 1.3	7.1 \pm 1.8	7.2 \pm 1.6	7.8 \pm 1.6	7.2 \pm 1.2
J	10.6 \pm 1.9	15.3 \pm 1.2	17.4 \pm 1.6	18.7 \pm 1.8	19.8 \pm 1.5
K	8.1 \pm 1.7	10.5 \pm 2.2	14.3 \pm 1.8	16.4 \pm 1.5	16.6 \pm 2.2
L	4.7 \pm 1.7	3.5 \pm 1.8	3.8 \pm 1.2	3.1 \pm 1.8	3.0 \pm 1.5
M	6.2 \pm 1.8	5.2 \pm 1.3	4.8 \pm 1.8	3.3 \pm 1.5	2.8 \pm 1.8

CT = computed tomography, SD = standard deviation.

3. Results

3.1. TFF approach on cadavers

3.1.1. Feasibility of TFF approach. In cadavers, the lateral part of the ligament flavum was located on the lateral side of the isthmus and the dorsal side of the exiting nerve root from L1 to S1, and intervertebral discs were covered by a facet joint (Fig. 3).

During the TFF approach, the posterior wall of the intervertebral foramina needed to be partly resected. On the cephalic side, the structures needing to be resected from the lateral to medial side were the lateral edge of the ligamentum flavum and the lateral edge of the isthmus. On the caudal side, the structures needing to be resected were the laterosuperior part of facet joint, ligamentum flavum, and transitional part of joint capsule wrapping around the facet joint. After the TFF approach, the structure within the intervertebral foramina or the spinal canal was fully exposed (Fig. 4).

During the TFF approach, the lateral edge of the dural sac was exposed by a slight resection of the isthmus at L12, L23, and L34, because the width of the lamina is small and could not cover the lateral edge of the vertebral body. At L45 and L5S1, the enlarged lamina and facet joint covered the disc and lateral edge of the vertebral body, so more resection of the isthmus and facet joint

was needed to fully expose the posterolateral edge of the disc, especially for L5S1. As well, the lateral edge of the dural sac and transitional nerve root is difficult to expose and can be detected only by the nerve-stripping ion.

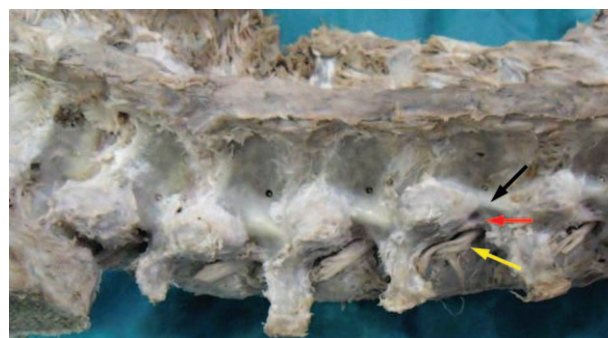

Figure 3. Posterior view of the intervertebral foramina from L1 to S1 in a representative cadaver. The structures from the lateral to medial side are as follows: lateral edge of ligamentum flavum (red arrow), lateral edge of isthmus and facet joint (black arrow). Exiting nerve roots (yellow arrow) are located on the ventral side of the ligamentum flavum.

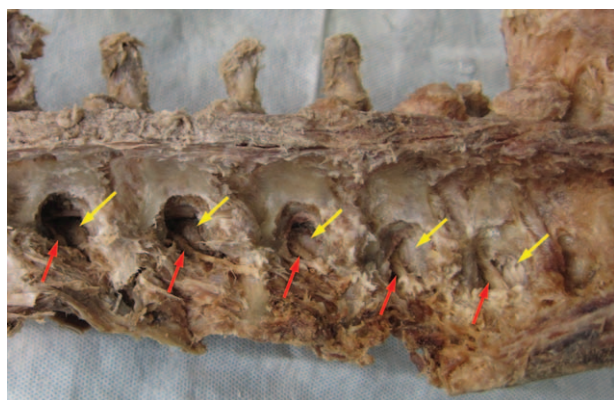


Figure 4. Posterior view of the intervertebral foramina from L1 to S1 in a representative cadaver after the TFF approach. The exiting nerve roots (red arrows) and posterolateral edge of intervertebral disc (yellow arrows) were exposed. TFF = transforaminal fenestration.

3.1.2. Measurement of TFF approach. The parameters measured manually (Table 1) were slightly larger than those measured by 3D CT (Table 2); however, there being no statistical difference between 2 groups of parameters ($P > .05$), which may be caused by the elasticity of soft tissue or no flat bone surface after resection. Some common features were revealed from the 2 types of measurement. From L1 to S1, the distance from the lateral edge of isthmus to the lineae mediana posterior gradually increases; the width of the lamina increases and covers the front vertebral body; the transverse process moves downward; the facet joint becomes larger and the height of the superior articular process increases; and the facet joint gradually covers the whole intervertebral space.

During the TFF approach, the resection range gradually increases from L1 to S1 including the width of the resected isthmus, the length of the resected lateral edge of lamina, the length of the resected superior articular process and the width of the resected facet joint. Meanwhile, the width or the minimum width of the remaining inferior articular process decreased. Still, the inferior articular process could be partly retained.

3.2. Radiographic measurement in patients

3D CT images of patients were used to measure parameters (Fig. 5). Measurements were very close to those from 3D CT

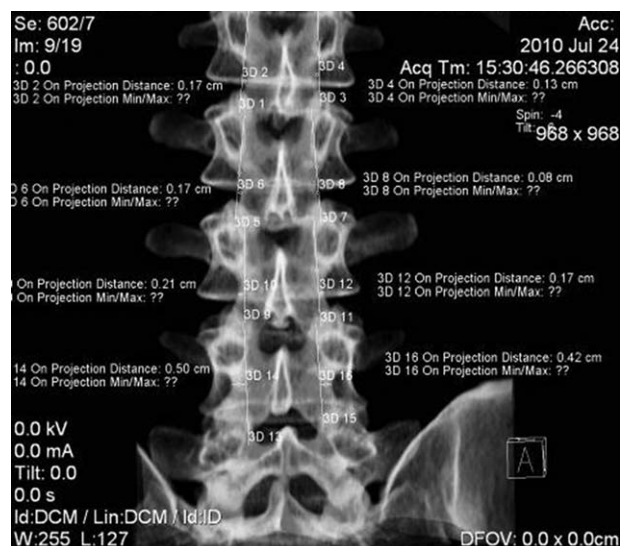

Figure 5. Range needed to be resected from L1 to S1 during the TFF approach measured by 3D CT images. TFF = transforaminal fenestration.

images and manual measurement of cadaver specimens (Table 3) ($P > .05$). The features mentioned above were also found for parameters measured in patients (Table 3). L1–3 feature ample space for the TFF approach and only a little resection is needed to expose the lateral edge of the exiting nerve root, dural sac, and transitional nerve root and posterior edge of the intervertebral disc. However, at L4/5 and L5/S1, especially L5/S1, the lamina and facet joint become larger and the transverse process moves downward, which results in a small space for the TFF approach, for more resection of isthmus and facet joint needed to fully expose the exiting nerve roots and the posterolateral edge of disc.

3.3. Clinical application of TFF approach with mMED

3.3.1. Merits of mMED system for TFF approach. Compared to open surgery with direct visualization, the endoscopy camera can reach deep into the incision, close to the lateral edge of the lamina, and therefore reduce the scope of bone resection (Fig. 6).^[22]

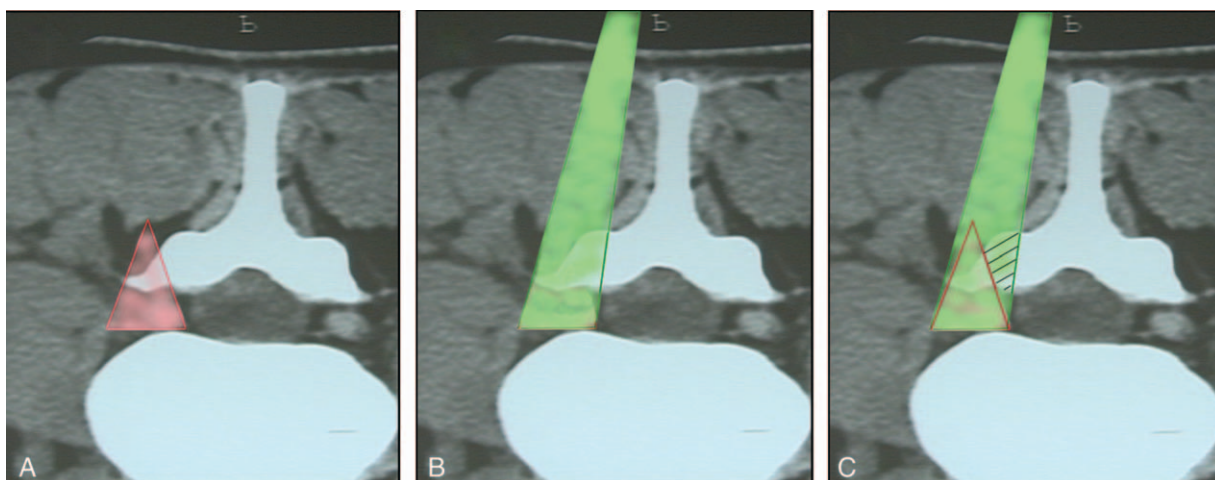


Figure 6. The scope of bone resection during the TFF approach with the mobile endoscopy system (A) and direct visualization (B). The resection scope with the endoscopy system is smaller than with direct visualization (shaded area in C). TFF = transforaminal fenestration.

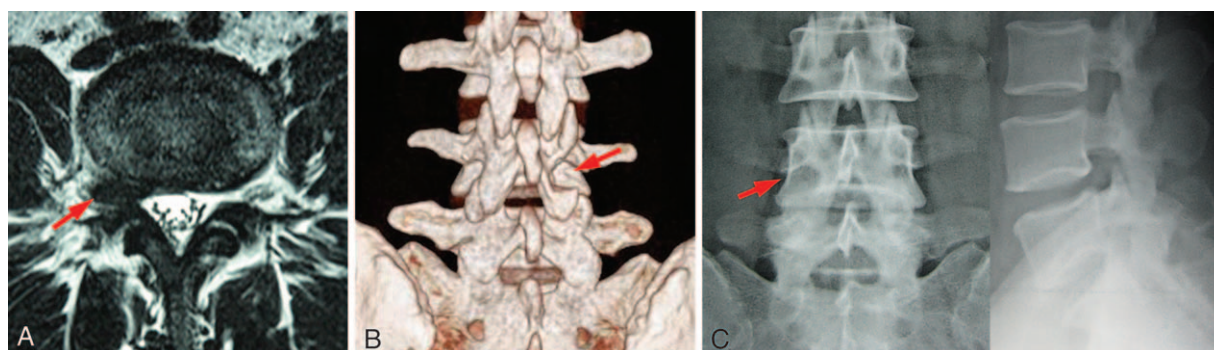


Figure 7. Female, 49 years old, with radiating pain to the medial malleolus along the right femoribis internus; cross-sectional MRI (A) showed intraforaminal herniations (arrow). Postoperative CT reconstruction (B) showing TFF fenestration (arrow). Radiating pain disappeared after surgery and the results were good through 12 months of follow-up. Plain radiograph 12 months later (C) showed regrowth of lamina at the periphery of fenestration (arrow). CT = computed tomography, MRI = magnetic resonance imaging, TFF = transforaminal fenestration.

3.3.2. Intraoperative findings. Surgery was successful in all 30 patients. The TFF approach achieved ample exposure and clear visualization in all patients. The exiting nerve root and ganglion were displaced cranially and dorsally against the pedicle, and the sequestered disc material was found at the ventral and medial side of exiting nerve root, which indicated migration between the exiting nerve root and the dural theca (axillary to the exiting nerve root). The dural theca and nerve root were thoroughly explored in all cases, with completely removal of sequestered herniations. No patient had serious complications during surgery. The mean operative time was 60 minutes (range 50–70 minutes), with mean blood loss of 150 mL (range 50–250 mL).

3.3.3. Clinical results. The leg pain was significantly relieved in all the patients after operation. All patients walked within 1 to 2 days of surgery, and the numbness and weakness in the leg resolved in varying degrees. Postoperative CT showed sufficient decompression and retained continuity of the lamina and facet joint (Fig. 7). Excessive resection of articular process and surface were observed in 3 patients of L5S1 herniation, however, the continuity of lamina and facet was present owing to luniform fenestration. None of the 3 patients has symptom of lumbar instability, and the regeneration and repair of residual lamina were observed on x-ray.

During follow-up, continuous resolve of symptom was experienced in all patients, including complete or nearly complete recover of muscle strength. At final follow-up, 5 patients (1 with L34 herniation, 4 with L45 herniation) were lost because of change of contact information, and 25 patients were followed-up for a mean of 24 months (range 12–48 months). For the 25 patients, the VAS score decreased from 8.9 ± 2.2 preoperative to 1.4 ± 1.2 at final follow-up, and ODI scores improved from 39.6 ± 2.9 preoperative to 6.9 ± 2.4 at final follow-up, all had statistical differences ($P < .05$). The SF-36 physical component summary score and SF-36 mental component summary score increased from 34.1 ± 4.5 preoperative to 46.8 ± 7.2 at final follow-up and 39.3 ± 6.7 preoperative to 49.8 ± 8.1 at final follow-up, respectively ($P < .05$). The clinical results at final follow-up were excellent for 19 patients and good for 6 according to Macnab criteria. All patients were satisfied with their outcome, and we found no recurrence of disc herniation during follow-up. Plain radiographs revealed no instability in any case.

4. Discussion

The approaches mainly used for lumbar FLDH include the conventional interlamina fenestration approach, the intertransverse approach, and the post-lateral approach. However, these approaches cause spinal instability or have difficulty in exposing the intervertebral disc. We proposed a TFF approach which can fully expose the intervertebral foramina and preserve spinal stability.

At L12, L23 and L34, the width of the isthmus and the distance from the lateral edge of the isthmus to the lateral edge of the dural sac are very small, with the lateral edge of the isthmus located on the medial side of the lateral border of the dural sac in some specimens, so only a little resection of bone is needed to expose the lateral border of the dural sac. As well, the widths of the facet joints are small, so the posterolateral edge of the intervertebral disc can be sufficiently exposed by partial resection of the lateral edge of the facet joint. Reulen et al^[23] studied the anatomy of L12 to L34 for lumbar FLDH. They also found that only a few millimeters of the isthmus need to be removed to identify the nerve root and the disc fragment, and the “operative window” at these levels is large, allowing the surgeon easy access to the herniated disc.

For L45, more resection of isthmus and lateral edge of the facet joint (approximately 14–18 mm) is needed to expose the lateral edge of the dural sac and the posterolateral edge of the intervertebral disc because the intervertebral space is covered by the enlarged isthmus and facet joint. After resection, a small part of the inferior articular process is retained (width of about 2–4 mm, minimum thickness about 2–4 mm), for spinal instability. A luniform fenestration of the lateral side of the facet joint was proposed to preserve more inferior articular process and spinal stability. Although exposing the dural sac and transitional nerve root is difficult, the transitional nerve root can be detected by nerve-stripping ion and the nucleus fragment can be removed by inserting a pith nucleus clamp into the intervertebral space. Likewise, Voyadzis et al^[24] performed minimally invasive discectomy to 5 patients of FLDH at L45 with a paramedian approach, with the lateral aspect of the pars interarticularis and inferior facet partially removed by a high-speed drill or Kerrison rongeurs to expose the herniated disc.

For L5S1, the width of the vertebral isthmus further increases and completely covers the vertebral body. The facet joint enlarges and covers the whole intervertebral space. The superior articular

process of vertebrae S1 is hypertrophied and the transverse process moves downward. As well, because of the wing of ilium covering, the space for surgery is very small. The above characteristics of L5S1 are consistent with the study conducted by Reulen et al,^[23] who found that the operative window became progressively smaller as the lateral approach moves from L1-L2 toward L5-S1. For L5S1, the resection ranges are larger for the vertebral isthmus (about 4–7 mm) and facet joint (about 16–20 mm), and the remaining scope is smaller for the inferior articular process (about 2–3 mm for width, minimum thickness about 1–3 mm) than other segments. Similar to L45, a luniform fenestration of lateral side of facet joint is recommended to preserve more inferior articular process. Although the exposure of the dural sac and transitional nerve root is also difficult, nerve-stripping ion can be used to detect the transitional nerve root, and a pith nucleus clamp can be obliquely inserted into the intervertebral space to remove the nucleus fragment. Similarly, Chun and Park^[25] successfully treated 1 case of FLDH at L5S1 through percutaneous endoscopic lumbar discectomy (PELD) with an approach similar to the transforaminal access.

In this study, we chose an incision beside the spinous process. It is more convenient and less invasive than the transmuscular approach for exposing the lateral border of isthmus, which needs to be resected in the TFF approach. We used MED combined with the mobile spine endoscopy system in our study. The camera of the system can be placed deep into the incision and close to the fenestration site, so the system can provide clearer visualization of the surgical field than conventional MED. In addition, the system can reduce the scope of resection and is better at preserving spinal stability as compared with open surgery with direct visualization. The operating tube can be freely tilted to offer a wide field of vision and exploration. The lateral edge of the isthmus and facet joint was removed by high-speed burring, which can easily remove the bone and control the range of fenestration. A luniform fenestration of the posterior wall of the intervertebral foramina was recommended to avoid excessive bone resection and fracture. In our study, 30 patients with lumbar FLDH underwent MED with the mobile spine endoscopy system via the TFF approach. The system provided ample exposure and clear visualization and the sequestered nucleus was completely removed. Therefore, MED with the mobile spine endoscopy system is suitable for complete removal of sequestered nucleus in treating lumbar FLDH via the TFF approach.

There were some limitations in our study. First, no control group was included in this study, making it difficult to determine that the TFF approach is better than other present approaches for lumbar FLDH. As we know, percutaneous endoscopic lumbar discectomy has been used for far lateral disc herniation with good results in selected patients, but the exposition is limited and complete removal of sequestered disc material is difficult to guarantee. The transforaminal lumbar interbody fusion provides sound exposition and complete removal of disc but with fusion of functional segment and more operative trauma. The results of our study suggest that the TFF approach is a safe approach for lumbar FLDH and has the potential to expose the intervertebral foramina sufficiently with preservation of structural continuity and stability. However, randomized control research will be critical to better investigate the efficacy, merits and demerits of TFF approach. Second, the TFF approach should be applied in more patients and long-term follow-up is needed in order to investigate the

complications and the long-term results, including the recurrence, the degeneration of operated segment.

5. Conclusion

The TFF approach in treatment for lumbar FLDH can provide sufficient exposure to the intervertebral foramina at all lumbar segments with preservation of structural continuity and stability and can be used effectively with MED.

References

- [1] Liao Z, Chen W, Wang CH. Transforaminal percutaneous endoscopic surgery for far lateral lumbar intervertebral disk herniation. *Orthopedics* 2014;37:e717–27.
- [2] Vogelsang JP, Maier H. Clinical results and surgical technique for the treatment of extreme lateral lumbar disc herniations: the minimally invasive microscopically assisted percutaneous approach. *Zentralbl Neurochir* 2008;69:35–9.
- [3] Yoshimoto M, Iwase T, Takebayashi T, et al. Microendoscopic discectomy for far lateral lumbar disk herniation: less surgical invasiveness and minimum 2-year follow-up results. *J Spinal Disord Tech* 2014;27:E1–7.
- [4] Lee HO, Eun JP, Park SS. The clinical value of 3-T magnetic resonance myelography in far lateral disk herniation. *J Spinal Disord Tech* 2012;25:E23–27.
- [5] Lee DY, Lee SH. Effects of facet tropism and disk degeneration on far lateral lumbar disk herniation: comparison with posterolateral lumbar disk herniation. *Neurol Med Chir (Tokyo)* 2009;49:57–61.
- [6] Li F, Zhang ZC, Zhao GM, et al. Clinical classification and surgical options of the far-lateral lumbar disc herniation. *Zhonghua Wai Ke Za Zhi* 2009;47:1553–6.
- [7] Berra LV, Foti D, Ampollini A, et al. Contralateral approach for far lateral lumbar disc herniations: a modified technique and outcome analysis of nine patients. *Spine (Phila Pa 1976)* 2010;35:709–13.
- [8] Peltier E, Blondel B, Dufour H, et al. Minimally invasive transmuscular approach for the treatment of lumbar herniated disc: far lateral lumbar disc herniation: a clinical study. Applications for cervical and thoracic disc herniation. *J Neurosurg Sci* 2013;57:123–7.
- [9] Madhok R, Kanter AS. Extreme-lateral, minimally invasive, transpoas approach for the treatment of far-lateral lumbar disc herniation. *J Neurosurg Spine* 2010;12:347–50.
- [10] Nakajima Y, Hara M, Makino K, et al. A case of far lateral lumbar disk herniation treated with Transforaminal Lumbar Interbody Fusion (TLIF). *No Shinkei Geka* 2013;41:629–36.
- [11] Papavero L, Kothe R. The translaminar approach for cranially extruded lumbar disc herniations. *Oper Orthop Traumatol* 2013;25:6–15.
- [12] Koga S, Sairoyo K, Shibuya I, et al. A Minimally invasive removal of a recurrent lumbar herniated nucleus pulposus by the small incised microendoscopic discectomy interlaminar approach. *Asian J Endosc Surg* 2012;5:34–7.
- [13] Schulz C, Abdeltawab A, Mauer UM. Translaminar approach to cranio-laterally herniated lumbar disc prolapse. *Acta Neurochir (Wien)* 2012; 154:711–4.
- [14] Wang B, Lü G, Liu W, et al. Full-endoscopic interlaminar approach for the surgical treatment of lumbar disc herniation: the causes and prophylaxis of conversion to open. *Arch Orthop Trauma Surg* 2012;132:1531–8.
- [15] Wang QP, Lee NS, Zhang Y, et al. Intertransverse approach for extraforaminal herniations. *Spine (Phila Pa 1976)* 1997;22:701–5.
- [16] Lee DH, Kim NH, Park JB, et al. CT scan assessment of the pathway of the true lateral approach for transforaminal endoscopic lumbar discectomy: is it possible? *J Bone Joint Surg Br* 2011;93:1395–9.
- [17] Uribe JS, Smith WD, Pimenta L, et al. Minimally invasive lateral approach for symptomatic thoracic disc herniation: initial multicenter clinical experience. *J Neurosurg Spine* 2012;16:264–79.
- [18] Macnab I. Negative disc exploration. An analysis of the causes of nerve-root involvement in sixty-eight patients. *J Bone Joint Surg Am* 1971;53:891–903.
- [19] Jhala A, Mistry M. Endoscopic lumbar discectomy: experience of first 100 cases. *Indian J Orthop* 2010;44:184–90.
- [20] Shimia M, Babaei-Ghazani A, Sadat BE, et al. Risk factors of recurrent lumbar disk herniation. *Asian J Neurosurg* 2013;8:93–6.
- [21] Kim JM, Lee SH, Ahn Y, et al. Recurrence after successful percutaneous endoscopic lumbar discectomy. *Minim Invasive Neurosurg* 2007;50: 82–5.

- [22] Xu B, Tan Q, Xia Q, et al. Bilateral decompression via unilateral fenestration using mobile microendoscopic discectomy technique for lumbar spinal stenosis. *Orthop Surg* 2010;2:106–10.
- [23] Reulen HJ, Müller A, Ebeling U. Microsurgical anatomy of the lateral approach to extraforaminal lumbar disc herniations. *Neurosurgery* 1996;39:345–50.
- [24] Voyadzis JM, Gala VC, Sandhu FA, et al. Minimally invasive approach for far lateral disc herniations: results from 20 patients. *Minim Invasive Neurosurg* 2010;53:122–6.
- [25] Chun EH, Park HS. A modified approach of percutaneous endoscopic lumbar discectomy (PELD) for far lateral disc herniation at L5-S1 with foot drop. *Korean J Pain* 2016;29:57–61.