

# Solitary Hepatic Gastrinoma Treated With Laparoscopic Radiofrequency Ablation

Zöe K. Deol, MD, Eldo Frezza, MD, Steven DeJong, MD, Jack Pickleman, MD

## ABSTRACT

**Background:** This is a case of a solitary hepatic gastrinoma in a 65-year-old male. The patient was diagnosed with Zollinger-Ellison syndrome in 1991. He had negative radiologic and surgical explorations at that time. He was maintained on proton-pump inhibitors for the next 10 years without symptoms.

**Methods:** A computed tomographic (CT) scan done in April 2001 demonstrated a 5-cm right hepatic lesion. Radionuclide scanning with octreotide demonstrated intense activity in the same area in the right hepatic lobe. His serum gastrin was 317 pg/mL. He underwent laparoscopic radiofrequency ablation of the lesion.

**Results:** Treatment resulted in a 6-cm ablative area giving a 1-cm margin on the tumor. One- and 3-month follow-up CT scans demonstrated adequate ablation of the tumor. An octreotide scan done 3 months postoperatively did not reveal any areas of abnormal uptake.

**Conclusion:** We report success with laparoscopic radiofrequency ablation as an alternative to major hepatic resection in patients with a solitary hepatic gastrinoma.

**Key Words:** Laparoscopy, Radiofrequency ablation, Hepatic gastrinoma.

## INTRODUCTION

The annual incidence of the 2 most common neuroendocrine tumors, insulinoma and gastrinoma, is about 1 per million.<sup>1</sup> Although insulinomas are usually benign, 60% to 80% of gastrinomas are malignant. Hepatic or nodal metastases are found in 60% of patients diagnosed with Zollinger-Ellison syndrome (ZES).<sup>2</sup> Long-term (5-year) survival of patients with resected extrahepatic gastrinoma is 95%.<sup>3</sup> This number is decreased to 85% in patients with resected hepatic metastases.<sup>4</sup> However, 5-year survival in patients with unresected hepatic gastrinoma is a dismal 30%.<sup>2,5,6</sup> Hepatic resection continues to be an effective treatment for a solitary hepatic gastrinoma.<sup>2</sup> Other methods have been tried in patients with tumor locations or medical problems prohibiting major hepatic resection. These include embolization, chemoembolization, immunotherapy (interferon alpha), liver transplantation, and chemotherapy. These methods all have yielded unsatisfactory results with no reports of complete remission.<sup>5,7-11</sup> More recently, radiofrequency ablation (RFA) has been used in cases of unresectable hepatocellular or colorectal metastases.

Two large studies on RFA for primary hepatocellular and colorectal metastases showed varied results. Curley et al<sup>12</sup> demonstrated a 1.8% recurrence at a mean follow-up of 15 months in a series of 169 patients. Wood et al,<sup>13</sup> in a series of 231 patients, cited an 18% recurrence rate at a mean follow-up of 9 months. No series has had efficacious RFAs in patients with hepatic gastrinoma. We report a case of a 5-cm solitary hepatic gastrinoma treated with RFA with a resulting 1-cm margin on the tumor. We propose RFA as an alternative to major hepatic resection in patients with solitary hepatic gastrinoma.

## METHODS

Our patient is a 65-year-old male who was originally treated at an outside hospital in 1988 for a perforated gastric ulcer. This was repaired with a modified Graham patch technique. He was then followed up with EGD and treated medically for several recurrent ulcers. He was referred to our institution in 1991 after a workup of his ulcer disease led to a diagnosis of ZES. This diagnosis was based on elevated serum gastrin levels, a positive

Loyola University Medical Center, Maywood, Illinois, USA (all authors).

Address reprint requests to: Zöe K. Deol, MD, Loyola University Medical Center, 2160 South 1st Ave, EMS Bldg 3rd Floor, Department of Surgery, Ste 3293, Maywood, IL 60153, USA. Telephone: 708 327 3041, Fax: 708 327 2810, E-mail: zoedeol@msn.com

© 2003 by JSLS, *Journal of the Society of Laparoendoscopic Surgeons*. Published by the Society of Laparoendoscopic Surgeons, Inc.

secretin stimulation test, and refractory ulcer disease. He underwent several localizing studies including an abdominal computed tomographic (CT) scan and radionuclide scanning with octreotide. The CT scan revealed a 2-cm left adrenal nodule and no other masses. The octreotide scan characterized the adrenal nodule as being inactive. No other areas of activity were found on the octreotide scan. At exploratory laparotomy, a thorough examination, including the gastrinoma triangle, was carried out. Several biopsies were taken from the following locations: left lateral lobe of the liver, right lobe of the liver (diaphragmatic surface), peri-portal lymph nodes, and 2 anterior pancreatic nodules were shelled out. In addition, an anterior duodenotomy was performed from the pylorus through the third portion. Once again, no tumor was identified. He has since been managed on proton-pump inhibitors and routine medical follow-up, including repeat CT scans.

In April 2001, a CT scan revealed a 5-cm mass in the right lobe of the liver. In addition, the previous left adrenal mass had increased to 5 cm. Octreotide scanning at this time demonstrated intense activity in the right lobe of the liver; however, the left adrenal nodule remained inactive. Over the course of the past 10 years, the patient has developed advanced emphysematous disease of the lungs, gained 100 lbs, and developed type II diabetes.

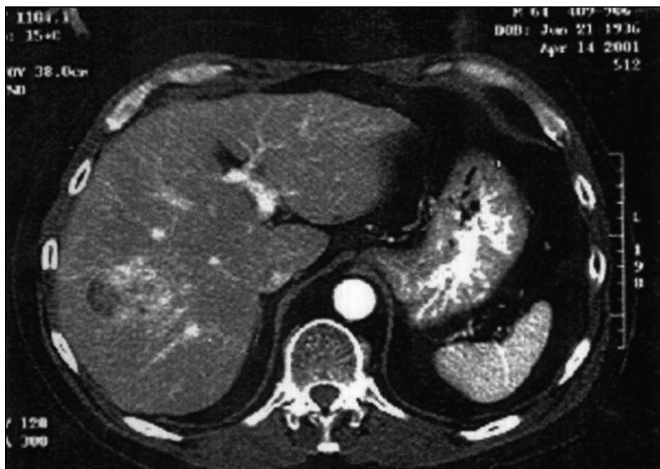
The location of the tumor near major branches of the portal vein would have necessitated a major right hepatic lobectomy (**Figure 1**). After discussion with the patient and his family regarding his surgical options, the patient

was given the additional option of RFA via a laparoscopic approach for his liver tumor. It was also recommended that he undergo a laparoscopic left adrenalectomy due to the enlarging left adrenal nodule.

The patient underwent successful laparoscopic left adrenalectomy and laparoscopic right hepatic tumor RFA. We used the Aloka, reticulating laparoscopic ultrasound to examine the liver and guide RFA probe placement. The RITA model 1500 radiofrequency generator was used in our patient at a frequency of 460 kHz. The ablation device was the RITA, StarBurst XL (for 3- to 5-cm ablation). The electrode was first deployed at the most posterior interface, and then, after ablation, was subsequently withdrawn and redeployed at the most anterior interface in the tumor to create overlapping zones of necrosis (**Figure 2**). Power delivery was set at 50 watts, and the lesion was heated to a temperature of 90°C for 10 minutes. Upon withdrawing the electrode, the temperature was maintained to ablate the tract of the needle.

## RESULTS

The patient's RFA was complicated by an intraoperative right pneumothorax, believed to be caused by a puncture to the diaphragm by the 25-gauge-needle used to locate the tumor. This was treated by placement of a 22-French chest tube, which was removed on post-



**Figure 1.** CT scan of patient's right hepatic tumor.



**Figure 2.** Intraoperative ultrasound of tumor ablation.

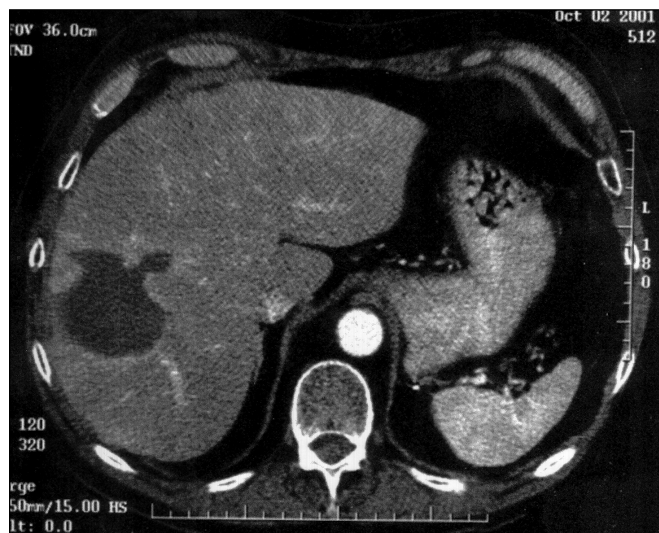
operative day 2. The patient was discharged home on postoperative day 3 without any further sequelae. Pathologic examination of the adrenal gland revealed a 4.5 x 5.1 x 4.5-cm adrenal cortical adenoma. The patient was seen in the office 2 weeks postoperatively and was doing well. His follow-up CT scan (**Figure 3**) demonstrated complete destruction of the lesion seen on the preoperative CT scan with an apparent 1-cm additional margin based on the increased size of the ablative lesion to 6.0 cm x 6.0 cm x 5.1 cm. Postoperative blood work revealed the following: gastrin 473 pg/mL, insulin 24 U/mL, serotonin 244 ng/mL, and pancreatic polypeptide 852 pg/mL. These hormones are sensitive markers for hepatic gastrinoma and useful for monitoring tumor recurrence.<sup>14</sup>

A second follow-up CT scan was done 3 months postoperatively to reevaluate this lesion (**Figure 4**). This demonstrated a decrease in size of the ablated lesion, and no evidence of new lesions. Repeat blood work at this time revealed an elevated serum gastrin of 754 pg/mL. His serum pancreatic polypeptide and serotonin, however, were decreased to 660 pg/mL and 161 ng/mL, respectively. In light of this, a radionuclide scan with octreotide was performed. This revealed no areas of abnormal uptake in the body. This patient will be followed with octreotide scans and CT scans on a biannual basis.

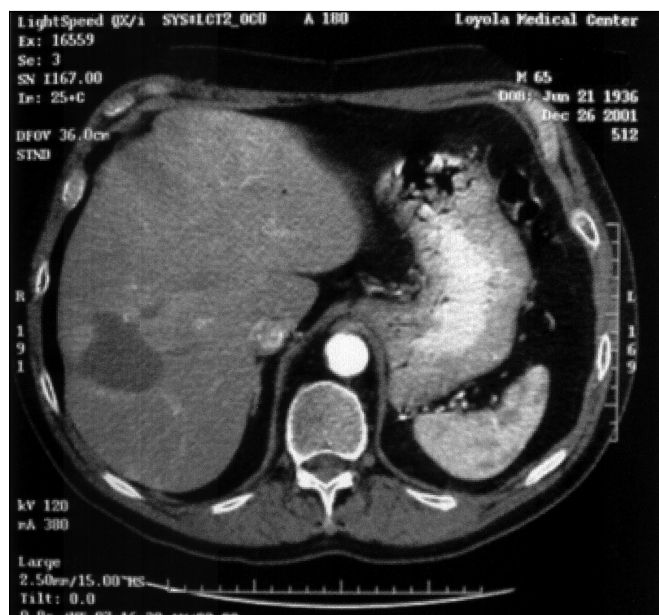
## DISCUSSION

Neuroendocrine tumors (NETs) typically arise from the islet cells of Langerhans. NETs fall into 1 of 5 categories: insulinoma, gastrinoma, glucagonoma, vipoma, and somatostatinoma. The majority of primary gastrinomas are found in the duodenum (40% to 50%), the head of the pancreas (30% to 50%), and lymph nodes (17%) within the gastrinoma triangle (defined by the junction of the cystic duct with the common bile duct, junction of the second and third portion of the duodenum, and the junction of the neck and the body of the pancreas). Ectopic gastrinomas can be found in the stomach, parathyroids, kidney, common bile duct, ovary, lymph nodes, and liver. Patients with localized resectable liver metastases from gastrinoma are rare.<sup>4</sup> The presence of neuroendocrine cells in the normal bile duct explains the possible development of ectopic primary hepatic gastrinoma.<sup>15</sup> Although a 20% correlation exists between ZES and multiple endocrine neoplasia type 1 (MEN 1), no corre-

lation appears to exist between primary hepatic gastrinoma and MEN 1, based on the cases reported in the literature.<sup>15</sup>



**Figure 3.** One month post-radiofrequency ablation CT scan demonstrating ablated lesion.



**Figure 4.** Three month post-radiofrequency ablation CT scan demonstrating ablated lesion.

Making a diagnosis of primary hepatic gastrinoma relies on preoperative localizing studies and a thorough intraoperative exploration to rule out an occult primary with hepatic metastases. CT and magnetic resonance imaging (MRI) are both of limited use. CT can miss smaller hepatic lesions, with 1 study citing 63% sensitivity for gastrinoma.<sup>4</sup> MRI was found to be more sensitive (78%) but cannot distinguish between gastrinomas and small hepatic hemangiomas.<sup>4</sup> Recent studies have shown somatostatin receptor scintigraphy (SRS) to have a sensitivity of 90% with few false positives.<sup>4</sup> Intraoperative ultrasound (IOUS) is the most sensitive device for detection of hepatic tumors. IOUS is even more sensitive than palpation, which can miss some smaller lesions located deep in the liver parenchyma.

Once the diagnosis of hepatic gastrinoma has been made, the next step is treatment. Currently, surgery is the only effective treatment for gastrinoma.<sup>3</sup> For those patients who are not candidates for surgical resection, other treatment options must be explored. In 1 prospective randomized study of 213 patients with ZES, only 17 (8%) had localized liver gastrinoma and were candidates for surgical resection.<sup>4</sup> One of the newest treatment alternatives for unresectable liver tumors is RFA.<sup>12</sup> This has been used for treating primary hepatocellular carcinoma and hepatic colorectal metastases that were unresectable secondary to the number of lesions, anatomic location near main portal vessels, or inability of the patient to tolerate major hepatic resection.<sup>12</sup>

Radiofrequency ablation (RFA) is a thermal treatment technique designed to produce localized tumor destruction by heating tumor tissue to temperatures that exceed 50°C. When tumor cells are heated to temperatures above 45° to 50°C for more than 3 minutes, intracellular protein denaturation and melting of lipid bilayers results in direct tumor cell death.<sup>16</sup> RFA uses alternating currents passed across needle electrode arrays placed directly into the tumor. Ionic stimulation induced by the alternating current in tissue surrounding the electrode array produces gradual frictional heating, and the tissue temperatures rise to 80° to 110°C, which results in coagulative necrosis of the tissue in proximity to the electrode. The basic principle is similar to that of the surgical electrocautery units used to achieve intraoperative hemostasis.<sup>17</sup>

Novel RF needle designs have been developed with multiple-array hook electrodes that are deployed from the needle tip into the tumor.<sup>12</sup> The insulated 14- to 18-gauge

needle electrode shaft is placed into the tumor with the multiple-hook array retracted. Using real-time ultrasonographic guidance, the array is deployed from the needle tip into the tumor. The multiple-array hook electrodes are available in maximum diameters of 2.0 to 5.0 cm. In contrast to the small areas of tumor tissue ablation created by simple needle electrodes, multiple-array electrodes, such as the LeVein electrode, can produce zones of coagulative necrosis 2.0 to 6.0 cm in diameter.<sup>17</sup> For tumors less than 2.5 cm in diameter, the multiple arrays are deployed into the center of the tumor. For larger lesions, the array is first deployed at the most posterior interface (ultrasonographically) between tumor and normal liver parenchyma; it is subsequently withdrawn and redeployed at 2.0- to 2.5-cm intervals in the tumor. Optimal positioning of the electrode permits complete destruction of the tumor and at least a 1-cm zone of normal liver parenchyma.<sup>17</sup>

In our case, we describe a successful laparoscopic RFA of a 5-cm hepatic gastrinoma with a 1-cm margin. The patient was discharged from the hospital on postoperative day number 3, and avoided major hepatic resection. As had been previously demonstrated, intraoperative ultrasound provides better resolution of the tumor for RFA treatment compared with transabdominal ultrasound or CT for percutaneous treatment.<sup>18</sup> Incomplete tumor destruction has been reported in up to 18% of liver cancers treated percutaneously with RFA.<sup>18</sup> This underscores both the importance of careful treatment planning to overlap the zones of necrosis and the need for early post-RFA, CT, or MRI to detect incompletely treated tumors after percutaneous RFA.<sup>18</sup>

## CONCLUSION

No studies exist at this time documenting long-term follow-up of patients with hepatic gastrinoma treated with RFA. In our case, we achieved satisfactory immediate results based on postoperative CT showing adequate ablation of the tumor with a 1-cm margin. These results were supported by 3-month follow-up studies including a CT scan and an octreotide scan, both showing evidence of adequate ablation of the tumor. Concern still exists about the presence of an unidentified gastrinoma primary as is evidenced by the patient's persistent elevated serum gastrin. The slow-growing nature of this tumor, however, will make radiologic surveillance for treatable disease possible. Although surgical resection

remains the gold standard for treatment of hepatic gastrinomas, RFA may be a promising alternative for those patients in whom hepatic resection is not possible.

**References:**

1. Meko JB, Norton JA. Endocrine tumors of the pancreas. *Curr Opin Gen Surg.* 1994;186-194.
2. Weber HC, Venzon DJ, Lin JT, et al. Determinants of metastatic rate and survival in patients with Zollinger-Ellison syndrome: a prospective long-term study. *Gastroenterology.* 1995;108;1637-1649.
3. Norton JA, Doppman J, Jensen RT. Curative resection in Zollinger-Ellison syndrome: results of a 10-year prospective study. *Ann Surg.* 1992;215:8-18.
4. Norton JA, Doherty GM, Fraker DL, et al. Surgical treatment of localized gastrinoma within the liver: a prospective study. *Surgery.* 1998;124(6):1145-1152.
5. Ericksson B, Oberg K. Interferon therapy of malignant endocrine pancreatic tumors. *Front Gastrointest Res.* 1995;23:451-460.
6. Norton JA, Sugarbaker PH, Doppman JL, et al. Aggressive resection of metastatic disease in selected patients with malignant gastrinoma. *Ann Surg.* 1986;203:352-359.
7. Arcenas AG, Ajani AJ, Carrasco H, Levin B, Wallace S. Vascular occlusive therapy of pancreatic endocrine tumors metastatic to the liver. *Front Gastrointest Res.* 1995;23:439-450.
8. Venook A, Stagg R, Frye J, Gordon R, Ring E. Chemoembolization of patients with liver metastases from carcinoid and islet cell tumors [abstract]. *Proc Annu Meet Am Soc Clin Oncol.* 1991;10:A386.
9. Azouley D, Bismuth H. Role of liver surgery and transplantation in patients with hepatic metastases from pancreatic endocrine tumors. *Fron Gastrointest Res.* 1995;23:461-476.
10. von Schrenck T, Howard JM, Doppman JL, et al. Prospective study of chemotherapy in patients with metastatic gastrinoma. *Gastroenterology.* 1988;94:1326-1334.
11. Arnold R, Neuhaus C, Benning R, Schwerk W, Trautmann ME. Somatostatin analog Sandostatin and inhibition of tumor growth in patients with metastatic endocrine gastroenteropancreatic tumors. *World J Surg.* 1993;17:511-519.
12. Curley S, Izzo F, Delrio P, et al. Radiofrequency ablation of unresectable primary and metastatic hepatic malignancies: results in 123 patients. *Ann Surg.* 1999;230(1):1-8.
13. Wood TF, Rose M, Chung M, Allegra DP, Foshag IJ, and Bilchik AJ. Radiofrequency Ablation of 231 Unresectable Hepatic Tumors: Indications, Limitations and Complications. *Ann Surg.* 2000;7(8):593-600.
14. Wu PC, Alexander HR, Bartlett DL, et al. A prospective analysis of the frequency, location and curability of ectopic (non-pancreaticoduodenal, non-nodal) gastrinoma. *Surgery.* 1997;122:1176-1182.
15. Smyrniotis V, Kehagias D, Kostopanagiotou G, et al. Primary hepatic gastrinoma. *Am J Gastroenterol.* 1994;94(11):3380-3381.
16. Rossi S, Formari F, Paties C, Buscarini L. Thermal lesions induced by 480-KHz localized current field in guinea pigs and in pig livers. *Tumor.* 1990;76:54-57.
17. Curley S, Izzo F, Ellis L, et al. Radiofrequency ablation of hepatocellular cancer in 110 patients with cirrhosis. *Ann Surg.* 2000;232(3):381-391.
18. Rhim H, Dodd G. Radiofrequency thermal ablation of liver tumors. *J Clin Ultrasound.* 1999;5:221-229.