

Deep peroneal nerve palsy after opening wedge high tibial osteotomy

A case report

Jin Hwa Jeong, MD^a, Moon Chong Chang, MD, PhD^a, Seung Ah Lee, MD, PhD^{b,*}

Abstract

Rationale: Peroneal nerve injury is one of the major complications that may occur after closing wedge high tibial osteotomy (CWHTO). In contrast, the reduced risk of the peroneal nerve injury has been considered as one of the advantages of opening wedge HTO (OWHTO).

Patient concerns: A 61-year-old male who underwent OWHTO showed a dropped big toe immediately after surgery.

Diagnosis: Injury of deep peroneal nerve was confirmed by electrodiagnostic study. It was probably caused by a posterolaterally protruded screw.

Interventions: The protruded screw was replaced with a shorter one 3 weeks after OWHTO.

Outcomes: The motor weakness and sensory reduction were completely recovered at 9 months after surgery.

Lessons: OWHTO has been known to be safe from peroneal nerve injury. However, considering the anatomical course of deep peroneal nerve, great care should be taken to avoid damage to the deep peroneal nerve while drilling holes and inserting distal screws toward the posterolateral aspect of the proximal tibia.

Abbreviations: CWHTO = closing wedge high tibial osteotomy, OWHTO = opening wedge high tibial osteotomy.

Keywords: closing wedge high tibial osteotomy, deep peroneal nerve injury, opening wedge high tibial osteotomy, recovery

1. Introduction

High tibial osteotomy (HTO) is one of the most frequently used surgical treatments for relatively young patients with medial compartmental knee osteoarthritis (OA) with varus deformity.^[1–5] Among the several techniques used to perform HTO, medial opening wedge HTO (OWHTO) has recently become more popular. One of the reasons for this is that there is less risk of peroneal nerve injury during surgery compared to the lateral closing wedge HTO (CWHTO).

Peroneal nerve injury is one of the major complications that may occur after HTO such as correction loss, non-union of

osteotomy site, hinge fracture, and early progression of OA.^[6] Peroneal nerve injury can occur without clear surgical damage and confuses both the surgeon and the patient. While performing the CWHTO, concomitant fibular osteotomy or release of the proximal tibiofibular joint is necessary.^[7–9] These surgical procedures increase the likelihood of peroneal nerve injury.^[10,11] Previously, it was revealed that there was peroneal nerve injury in 4% of patients who underwent CWHTO.^[6] In contrast, there has been a lack of information on the rate of peroneal nerve injury while performing MOHTO in the literature.^[6,12–14]

In the current report, we present a rare case of the deep peroneal nerve (DPN) palsy after OWHTO in a 61-year-old male patient who had medial knee OA with varus deformity.

We obtained informed written consent from the patient for reporting this case.

2. Case report

A 61-year-old male visited the outpatient clinic of our institute due to pain and swelling on his left knee. He had varus knee OA (Kellgren-Lawrence grade 4). Conventional radiographs showed medial joint space narrowing whereas the spaces of the lateral compartment and patellofemoral joint were relatively preserved. He had a varus malalignment of 12° of the lower limb. We decided to perform the OWHTO after explaining to the patient the advantages and disadvantages of the surgery. Under spinal anesthesia, we performed biplane OWHTO and used a locked plate to fix the osteotomy. The correction angle was 14°. The osteotomy gap was 15 mm and was filled with an allogeneous chip bone graft (Fig. 1A). The shape of the locked plate did not fully fit into the bone construct. Therefore, the plate was compressed to

Editor: N/A.

The authors have no conflicts of interest to disclose.

^aDepartment of Orthopedic Surgery, Seoul National University College of Medicine, SMG-SNU Boramae Medical Center, ^bDepartment of Physical Medicine & Rehabilitation, College of Medicine, Kyung Hee University, Seoul, Republic of Korea.

*Correspondence: Seung Ah Lee, Department of Physical Medicine & Rehabilitation, Kyung Hee University College of Medicine, 7–13, Kyunghaedae-ro 6-gil, Dongdaemun-gu, Seoul, 02453, Republic of Korea (e-mail: Isarang80@gmail.com).

Copyright © 2019 the Author(s). Published by Wolters Kluwer Health, Inc. This is an open access article distributed under the terms of the Creative Commons Attribution-Non Commercial-No Derivatives License 4.0 (CCBY-NC-ND), where it is permissible to download and share the work provided it is properly cited. The work cannot be changed in any way or used commercially without permission from the journal.

Medicine (2019) 98:27(e16253)

Received: 17 January 2019 / Received in final form: 3 May 2019 / Accepted: 7 June 2019

<http://dx.doi.org/10.1097/MD.00000000000016253>

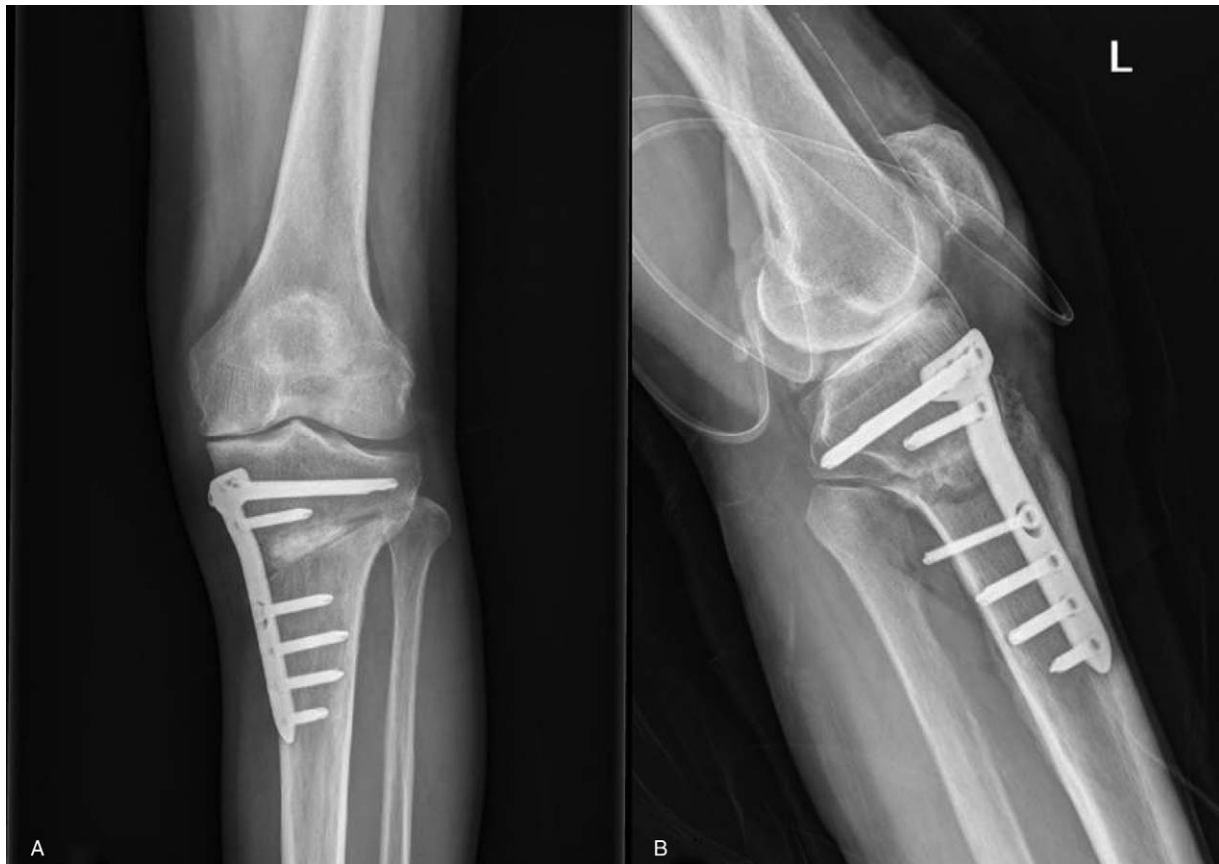

Figure 1. (A) The opening wedge high tibial osteotomy was performed using a locked plate. (B) On lateral projection conventional radiograph, the first distal screw was protruded towards the posterolateral aspect of proximal tibia.

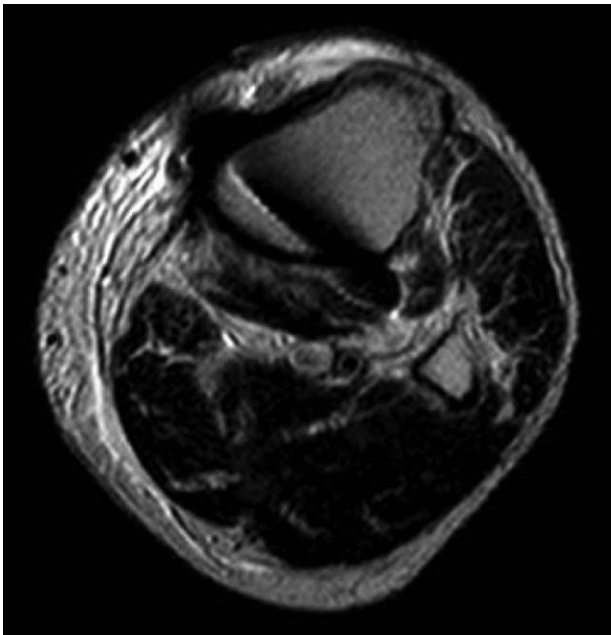


Figure 2. Magnetic resonance imaging was performed to rule out hematoma formation around the osteotomy site. There was a lack of hematoma formation, and the screw tip was located within the soleus muscle.

the cortical bone using a cortical screw inserted through the first distal screw hole. Even if we deducted the initial gap between the cortical bone and the plate from the screw length measured, the screw protruded 4 mm out from posterolateral cortex of the tibia (Fig. 1B). However, we did not change the protruded cortical screw to the locking screw because the hole had no optional hole for the locking screw, and we were concerned about losing the fixation strength by changing the screw. At that time, we accepted the protrusion of the cortical screw because we thought that the protruding screw was placed somewhere in the posterolateral portion of the calf muscle.

Immediately after surgery, he was unable to extend his left big toe even if he could extend the ankle joint. When we checked the sensory of the dorsal surface of the foot, he had decreased sensation of the first web space. At this time, we were not sure whether the peroneal nerve was damaged or the symptoms were caused by the prolonged effect of spinal anesthesia. The day after surgery, we noticed that there was a high possibility of deep peroneal nerve injury. At this stage, we performed magnetic resonance imaging to detect lesion that might have compressed the DPN such as hematoma around the osteotomy site (Fig. 2). However, there were no compressive lesions around the DPN, and thus we decided to perform a nerve conduction study (NCS) after a couple of weeks without urgent nerve exploration.

The NCS was performed on the 21 days after the surgery. The left common peroneal nerve motor conduction study recording

the extensor digitorum brevis showed decreased amplitudes (0.2 and 4.5 mV on the left and right sides, respectively) and delayed latency. Even if the NCS for the left deep peroneal sensory nerve showed no definite abnormality at this time, the combined results of the NCS and physical examination indicated severe axonotmesis in the left DPN. Thus, we were confident of the DPN damage and decided to change the screw to the shorter screw to remove any possible cause of nerve compression (Fig. 3). The follow-up NCS was performed 42 days after the surgery. The left common peroneal nerve motor conduction study recording the extensor digitorum brevis showed decreased amplitudes (0.2 and 4.5 mV on the left and right sides, respectively) and delayed latency. The follow-up sensory NCS for the left DPN showed decreased amplitudes (2.1 and 5.1 μ V on the left and right sides). The needle electromyography indicated positive sharp waves and fibrillation potentials at rest in the left extensor hallucis brevis and extensor digitorum brevis muscles. Single interference patterns in the left extensor hallucis longus were observed at maximal volition. The motor unit action potentials were not observed in the left extensor digitorum brevis at maximal volition. These electrodiagnostic studies were consistent with left deep peroneal neuropathy, at the level between the tibialis anterior and extensor hallucis longus, with moderate axonotmesis.

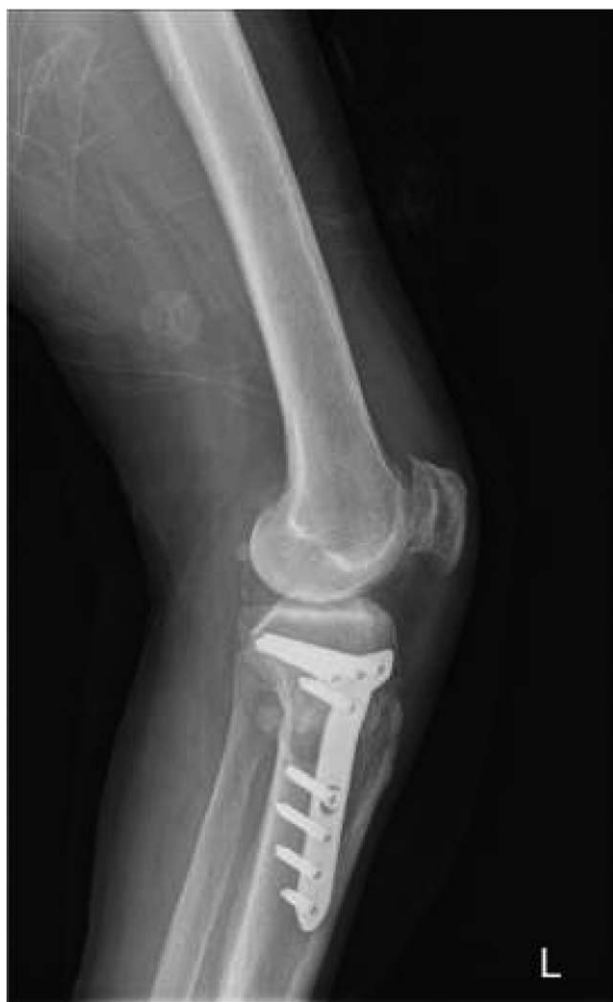

Figure 3. The protruding screw was replaced with a shorter one 3 weeks after the initial surgery.

There were no improvements after the screw was changed until 6 months after the surgery. However, the symptoms gradually improved from 6 to 9 months after surgery. Even if the patient refused the follow-up electrodiagnostic study, the motor weakness and sensory reduction was completely recovered at 9 months after the surgery.

3. Discussion

Peroneal nerve injury could occur during CWHTO with concomitant fibular osteotomy or release of the proximal tibiofibular joint.^[14] In contrast, many studies have shown that there was less risk of peroneal nerve injury after OWHTO.^[6,12,13] In addition to the lower risk of peroneal nerve injury compared to CWHTO, as the fixation devices became more technologically advanced, OWHTO became more popular.^[4,5] Although OWHTO has been known to be safe from peroneal nerve injury, we experienced a case of DPN injury.

The DPN innervates the extensor muscle of the anterior compartment of the lower leg including tibialis anterior, extensor digitorum longus, extensor hallucis longus, peroneus tertius, and extensor digitorum brevis (Fig. 4). In addition, the DPN provides a cutaneous innervation to the first web space of the foot dorsum. The DPN is bifurcated from the common peroneal nerve at the fibular neck and passes to the anterior compartment of the lower leg. The DPN is located beside the fascia that divides the anterior and lateral compartments at the proximal portion of the lower leg

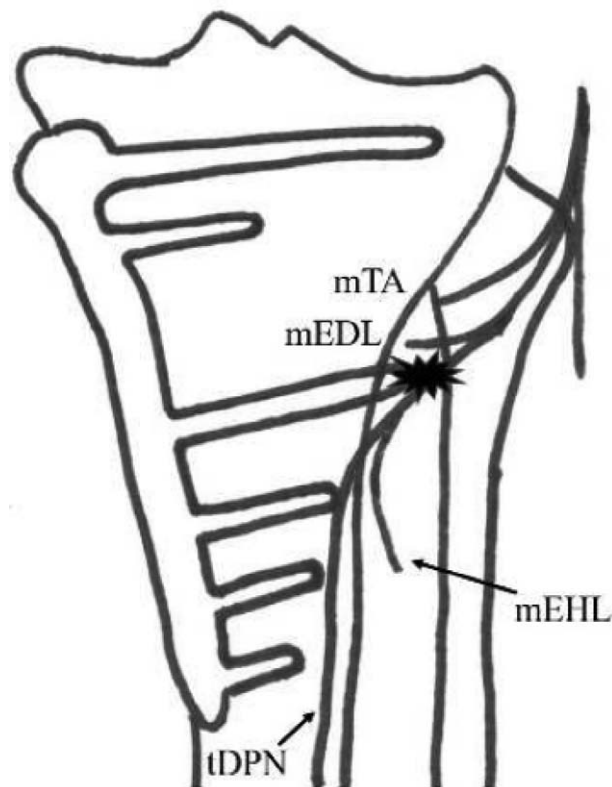


Figure 4. The findings of the physical examination and electrodiagnostic study confirmed that there was damage on the trunk of the deep peroneal nerve, which is located on the tibia. mEDL= motor branch to extensor digitorum longus, mEHL= motor branch to extensor hallucis longus, mTA= motor branch to tibialis anterior, SPN= superficial peroneal nerve, tDPN= trunk of deep peroneal nerve.

and descends along the lateral border of the tibia to end up anterior to the ankle joint.^[15] Under the ankle level, DPN bifurcates to the lateral and medial branches, which provides cutaneous innervation to the 1st web space of the foot dorsum.

A few reports on DPN sole injury during orthopedic surgery have been published. Several authors warned of DPN injury at the distal level of the lower leg while performing the minimal invasive plate osteosynthesis technique for tibial shaft fractures.^[16,17] In a previous study, the location of the nerve at the distal level which is close to the lateral cortex of the tibia could be considered to be the causative factor of iatrogenic DPN injury. It was previously reported that the trunk of the DPN was in close relation to the fibular periosteum just until 6 cm from the fibular head.^[11] At more than 6 cm distally, the DPN starts coursing across the interosseous membrane, and the DPN in a tibial-related position at 11 cm distal to the fibular head (Fig. 4).^[18] In the current OWHTO case, the trunk of the DPN, which was close to the tibial cortex, was probably damaged because of long diaphyseal screws or the drill bit advanced farther from the lateral cortex of the tibia.

In contrast, it was revealed that the isolated extensor hallucis longus paralysis could occur while performing the fibular osteotomy in the proximal tibial osteotomy.^[11,18] In this previous anatomical study, the authors reported that there were many variations in motor supply of the extensor hallucis longus in terms of subdivision sites, course, and places of entry of nerve branches into the extensor hallucis longus.^[11] The authors described an anatomical variant in which the nerve to the extensor hallucis longus was close to the fibula such that it was at risk of injury during a fibular osteotomy.^[18] If there was an isolated motor branch injury, the sensory of the first web space of the foot dorsum would be normal. Therefore, checking the sensory of the first web space of the foot dorsum is important to clinically distinguish an isolated extensor hallucis longus motor branch injury with an injury of the DPN trunk. Furthermore, sensory deficits are usually detected later than motor deficits in electrodiagnostic studies, and a follow-up electrodiagnostic study is mandatory to distinguish the 2 types of injuries that showed the same clinical manifestation of a dropped big toe.

There are several limitations to be considered. First, this report consisted of only one case of DPN palsy after OWHTO. Additional reports are needed to corroborate this case report. Secondly, we did not perform surgical exploration of the DPN to confirm if the nerve was compressed by the protruded screw or injured by other causes such as damage while drilling to make screw holes. Thirdly, there was no follow-up electrodiagnostic study to confirm complete recovery of the injured DPN. However, we believe that, in clinical practice, physical examinations are sufficient to confirm whether the nerve recovered or not.

OWHTO has been known to be safe from peroneal nerve injury. However, considering the anatomical course of DPN, a great care should be taken to not cause damage to the DPN while drilling holes and inserting distal screws toward the posterolateral aspect of proximal tibia.

Author contributions

Conceptualization: Jin Hwa Jeong, Moon Chong Chang, Seung Ah Lee.

Data curation: Jin Hwa Jeong, Moon Chong Chang, Seung Ah Lee.

Formal analysis: Jin Hwa Jeong, Moon Chong Chang, Seung Ah Lee.

Investigation: Jin Hwa Jeong, Moon Chong Chang.

Methodology: Jin Hwa Jeong, Moon Chong Chang, Seung Ah Lee.

Supervision: Moon Chong Chang, Seung Ah Lee.

Validation: Seung Ah Lee.

Writing – original draft: Jin Hwa Jeong.

Writing – review & editing: Moon Chong Chang, Seung Ah Lee.

References

- [1] Brouwer RW, Huizinga MR, Duivenvoorden T, et al. Osteotomy for treating knee osteoarthritis. *Cochrane Database System Rev* 2014;12: Cd004019.
- [2] Ha JK, Yeom CH, Jang HS, et al. Biomechanical analysis of a novel wedge locking plate in a porcine tibial model. *Clin Orthop Surg* 2016;8:373–8.
- [3] Lee SK, Yang BS, Park BM, et al. Medial meniscal root repair using curved guide and soft suture anchor. *Clin Orthop Surg* 2018;10:111–5.
- [4] Ryu SM, Park JW, Na HD, et al. High tibial osteotomy versus unicompartmental knee arthroplasty for medial compartment arthrosis with kissing lesions in relatively young patients. *Knee Surg Relat Res* 2018;30:17–22.
- [5] Lee HI, Park D, Cho J. Clinical and radiological results with second-look arthroscopic findings after open wedge high tibial osteotomy without arthroscopic procedures for medial meniscal root tears. *Knee Surg Relat Res* 2018;30:34–41.
- [6] Duivenvoorden T, van Diggele P, Reijman M, et al. Adverse events and survival after closing- and opening-wedge high tibial osteotomy: a comparative study of 412 patients. *Knee Surg Sports Traumatol Arthrosc Off J ESSKA* 2017;25:895–901.
- [7] Bicer EK, Basa CD, Gunay H, et al. The fate of fibular osteotomies performed during high tibial osteotomy. *Arch Orthop Trauma Surg* 2016;136:1085–90.
- [8] Ramanoudjame M, Vandebussche E, Baring T, et al. Fibular nonunion after closed-wedge high tibial osteotomy. *Orthop Traumatol Surg Res* 2012;98:863–7.
- [9] Ozcan O, Eroglu M, Boya H, et al. Proximal tibiofibular joint pain versus peroneal nerve dysfunction: clinical results of closed-wedge high tibial osteotomy performed with proximal tibiofibular joint disruption. *Knee Surg Sports Traumatol Arthrosc* 2017;25:2936–41.
- [10] Sabzevari S, Ebrahimpour A, Roudi MK, et al. High tibial osteotomy: a systematic review and current concept. *Arch Bone Jt Surg* 2016;4:204–12.
- [11] Kirgis A, Albrecht S. Palsy of the deep peroneal nerve after proximal tibial osteotomy. An anatomical study. *J Bone Jt Surg Am Vol* 1992;74:1180–5.
- [12] Martin R, Birmingham TB, Willits K, et al. Adverse event rates and classifications in medial opening wedge high tibial osteotomy. *Am J Sports Med* 2014;42:1118–26.
- [13] Woodacre T, Ricketts M, Evans JT, et al. Complications associated with opening wedge high tibial osteotomy—a review of the literature and of 15 years of experience. *Knee* 2016;23:276–82.
- [14] Song EK, Seon JK, Park SJ, et al. The complications of high tibial osteotomy: closing- versus opening-wedge methods. *J Bone Jt Surg Br Vol* 2010;92:1245–52.
- [15] Wolinsky P, Lee M. The distal approach for anterolateral plate fixation of the tibia: an anatomic study. *J Orthop Trauma* 2008;22:404–7.
- [16] Pichler W, Grechenig W, Tesch NP, et al. The risk of iatrogenic injury to the deep peroneal nerve in minimally invasive osteosynthesis of the tibia with the less invasive stabilisation system: a cadaver study. *J Bone Jt Surg Br Vol* 2009;91:385–7.
- [17] Lidder S, Masterson S, Grechenig C, et al. The risk of neurovascular injury in minimally invasive plate osteosynthesis (MIPO) when using a distal tibia anterolateral plate: a cadaver study. *Acta Chir Orthop Traumatol Cech* 2014;81:313–6.
- [18] Satku K, Kumar VP. Palsy of the deep peroneal nerve after proximal tibial osteotomy. An anatomical study. *J Bone Joint Surg Am* 1993;75:1736.