

# Retina-Brain Homology: The Correlation Between Ophthalmic or Retinal Artery Occlusion and Ischemic Stroke

Yufeng Yao <sup>1,2</sup>, Qiyuan Song<sup>3</sup>, Jingnan Zhang<sup>2,4</sup>, Yingying Wen<sup>2,4</sup>, Xiaoyan Dou <sup>2</sup>

<sup>1</sup>Shantou University Medical College, Shantou, Guangdong Province, People's Republic of China; <sup>2</sup>Department of Ophthalmology, Shenzhen Second People's Hospital, the First Affiliated Hospital of Shenzhen University, Shenzhen, Guangdong Province, People's Republic of China; <sup>3</sup>Department of Ophthalmology, Shenzhen Children's Hospital, Shenzhen, Guangdong Province, People's Republic of China; <sup>4</sup>Shenzhen University Medical College, No.1066 Xueyuan Road, Shenzhen University, Shenzhen, Guangdong Province, People's Republic of China

Correspondence: Xiaoyan Dou, Email douxy08@163.com

**Abstract:** The retina's similar structure and function to the brain make it a unique visual "window" for studying cerebral disorders. Ophthalmic artery occlusion (OAO) or retinal artery occlusion (RAO) is a severe ophthalmic emergency that significantly affects visual acuity. Studies have demonstrated that patients with OAO or RAO face a notably higher risk of future acute ischemic stroke (AIS). However, ophthalmologists often overlook multidisciplinary approach involving the neurologist, to evaluate the risk of AIS and devise clinical treatment strategies for patients with OAO or RAO. Unlike the successful use of thrombolysis in AIS, the application of thrombolysis for OAO or RAO remains limited and controversial due to insufficient reliable evidence. In this review, we aim to summarize the anatomical and functional connections between the retina and the brain, and the clinical connection between OAO or RAO and AIS, compare and review recent advances in the effectiveness and safety of intravenous and intra-arterial thrombolysis therapy in patients with OAO or RAO, and discuss future research directions for OAO or RAO. Our goal is to advance the development of multidisciplinary diagnosis and treatment strategies for the disease, as well as to establish expedited pathways or thrombolysis guidelines for vascular intervention.

**Keywords:** retina, brain, ophthalmic artery occlusion, retinal artery occlusion, stroke, thrombolysis

## Introduction

Ophthalmic artery occlusion (OAO) or retinal artery occlusion (RAO) is a retinal infarction results from the interruption of blood flow in the ophthalmic or retinal artery due to thromboembolism or vasospasm. This often leads to painless vision loss, visual field damage, and fundus ischemic changes like retinal pale edema.<sup>1</sup> The severity of symptoms correlates with the size of the obstructed blood vessels and the duration of occlusion. According to the vascular involvement, RAO can be classified into central retinal artery occlusion (CRAO) and branch retinal artery occlusion (BRAO). The most common site of occlusion for CRAO is the lamina cribrosa.<sup>2</sup> CRAO typically results in severe visual impairment, often limited to hand motion or even perception of light, and exhibit delayed direct light reflex in the ipsilateral pupil; while BRAO is associated with relatively favorable visual acuity and prognosis, with localized visual field defects corresponding to the areas of obstructed blood supply.<sup>1</sup> The yearly incidence rate of CRAO is 1–2 cases per 100,000 individuals, with a higher prevalence among men compared to women.<sup>3</sup> Moreover, the incidence rate of CRAO rises with age, and individuals over 80 years old can experience rates as high as 10 cases per 100,000.<sup>4</sup> OAO is relatively rare, whereas branch retinal artery occlusion (BRAO) accounts for approximately 1/3 of RAO.<sup>3</sup> The incidence rate of transient monocular vision loss (TMVL) is not well-established due to patients often not seeking medical attention for its transient symptoms. Fundus photography is commonly relied upon for the diagnosis of OAO and RAO, as the characteristic alterations in the patient's fundus facilitate a relatively straightforward diagnosis; while fundus fluorescence imaging is considered the gold standard for diagnosing these conditions.<sup>5</sup>

Stroke, like OAO or RAO, is an acute cerebrovascular disease caused by the occlusion or rupture of cerebral blood vessels, leading to tissue damage in the brain.<sup>6</sup> Acute ischemic stroke (AIS) is the predominant type of stroke, representing 69.6–70.8% of all strokes in China.<sup>6</sup> Data from the Global Burden of Diseases showed that stroke is the primary cause of death and disability among adults in China, with an incidence rate of 0.201% for stroke and 0.145% for AIS in 2019, making it the highest prevalence in the world.<sup>7</sup> According to TOAST classification, the etiology of AIS mainly includes aortic atherosclerosis, cardiogenic embolism, arteriole occlusion and other factors, which share the same pathogenesis with OAO or RAO.<sup>8</sup> Due to collateral circulation, when AIS occurs, although some neurons experience a loss of electrophysiological function, their cellular structure remains intact, and these neurons could regain normal electrophysiological function if tissue perfusion is restored.<sup>9</sup> However, structural damage eventually occurs as ischemia progresses, and normal physiological function cannot be recovered even with restored tissue perfusion. These neurons are referred to as the “penumbra”.<sup>9</sup> Similarly, a penumbra also exists in CRAO.<sup>10</sup> When retinal blood flow suddenly ceases, a retinal “penumbra” consisting of hypoxia and hypoxia-tolerant cells emerges due to variations in oxygen supply from the choroidal circulation and different of hypoxia tolerance among retinal cells in different regions.<sup>9,10</sup> The retinal “penumbra” appears similar to normal retinal tissue in fundus images but exhibits signal attenuation in electrophysiological testing.<sup>9</sup> Unlike the cerebral penumbra that ultimately transforms into an infarct core, the retinal penumbra can persist and eventually induce the formation of intraocular neovascularization.<sup>9,11</sup> In fact, OAO or RAO could be viewed as special types of AIS in terms of pathogenesis. There is growing support for classifying OAO or RAO as AIS and implementing comparable treatment and prevention strategies due to the rapid and severe damage caused, which would benefit secondary and tertiary prevention strategies for the disease.<sup>5</sup> In 2013, a statement from the American Stroke Association and the American Heart Association defined central nervous system infarction as the permanent ischemic death of brain, spinal cord, and retinal cells, based on imaging, pathology, and clinical symptoms, thus categorizing OAO or RAO as types of stroke.<sup>12</sup> Relevant guidelines recommend prompt intervention and multidisciplinary consultation for assessing neurological function in patients with OAO or RAO.<sup>5</sup>

In this review, we firstly summarize the anatomical and functional connections between the retina and the brain. Next, we compile a list of common cardiovascular and cerebrovascular risk factors found in previous similar studies comparing OAO or RAO and AIS. Additionally, we summarize the future risk of AIS and its associated risk factors in patients with OAO or RAO. Lastly, we compare and review the recent advancements in the effectiveness and safety of intravenous and intra-arterial thrombolysis therapy in patients with OAO or RAO. Our goal is to provide inspiration and ideas for the development of a standardized multidisciplinary approach and the establishment of expedited pathways or thrombolysis guidelines for vascular interventions in the future.

## Retina and Brain

The retina and optic nerve develop directly from the mesencephalon during the embryonic stage.<sup>13</sup> Retinal ganglion cells are morphologically similar to cerebral neurons, composed of soma, dendrites, and axons.<sup>14</sup> And the optic nerve, optic chiasm, and optic tract are formed by the successive axons of ganglion cells, terminating in the lateral geniculate body.<sup>14</sup> Ganglion cells convert visual information from photoreceptors into action potentials and transmit it along their axons, which eventually reach the visual cortex in the occipital lobe by passing through the lateral geniculate body.<sup>14</sup> Due to the neural homology and correlation between the retina and the brain, retinal degeneration has been suggested to be accompanied by cerebral neurodegeneration.<sup>15,16</sup>

The blood perfusion of the retina and brain is closely interconnected. The ophthalmic artery is the first branch of the internal carotid artery, while the anterior and middle cerebral arteries are its terminal branches.<sup>17</sup> Consequently, stenosis of the internal carotid artery would lead to ocular and cerebral ischemia. Under this condition, the Willis loop can compensate for the blood supply to the ophthalmic artery,<sup>18</sup> and the ophthalmic artery can enhance cerebral vascular perfusion as collateral circulation when cerebral blood supply is insufficient.<sup>19</sup>

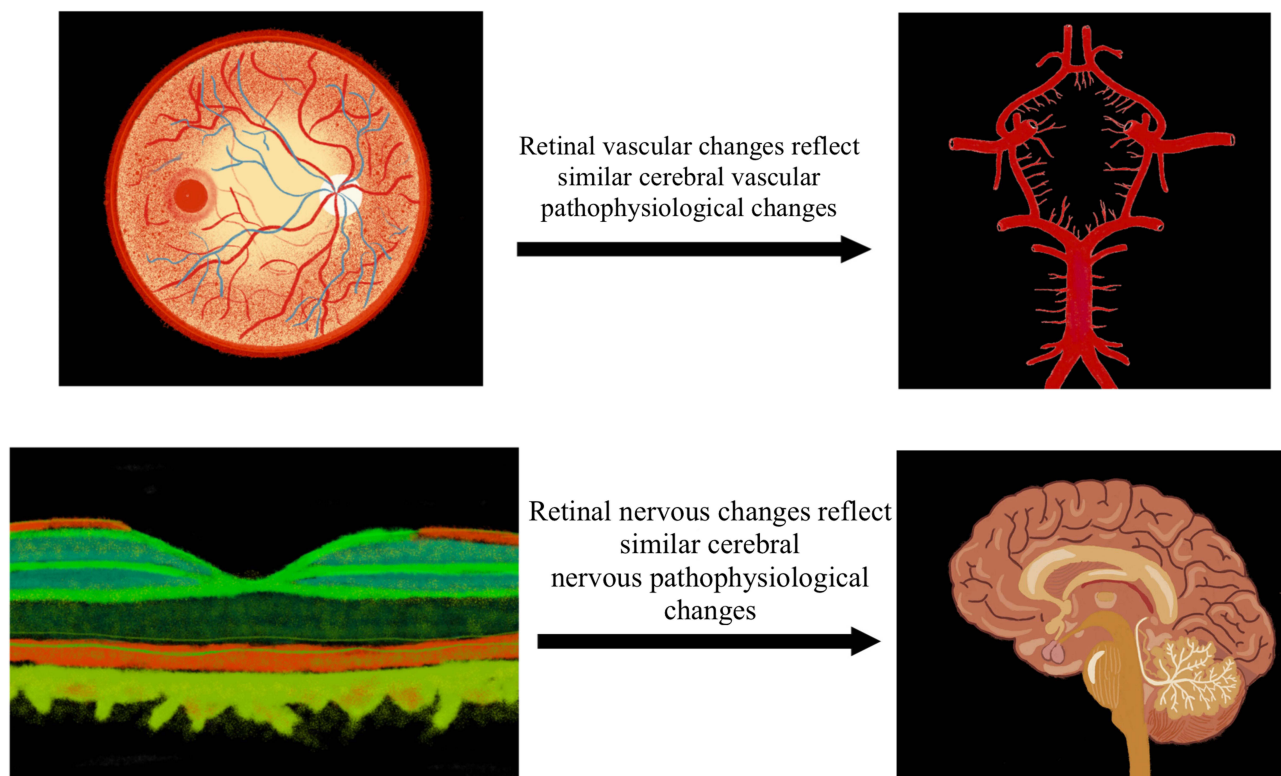
The retinal vessels have similar structural and physiological properties to the cerebral small vessels. Retinal vessels have a diameter of approximately 100um to 300um, which is similar to that of the cerebral small vessels.<sup>20</sup> They both exhibit low flow and high oxygen uptake, and can regulate vascular resistance and blood flow by contracting vascular smooth muscle or altering local metabolic demand to maintain tissue perfusion under hypoxia-ischemia.<sup>21</sup> Similar to the

blood-brain barrier, the inner blood-retinal barrier consists of pericytes and tight junctions between vascular endothelial cells, giving it the function to block macromolecules from the bloodstream from entering the tissues.<sup>22</sup> Aqueous humor, containing abundant anti-inflammatory and immunomodulatory mediators, shares similar properties and functions with cerebrospinal fluid, thus making the eye an immune-privilege site similar to the brain.<sup>23,24</sup> The permeability of the blood-retinal barrier and blood-brain barrier increases under hypoxia-ischemia, ultimately leading to impaired barrier function and tissue edema.<sup>22</sup>

Due to the shared embryonic origins and numerous similarities in anatomical structures and physiological functions, research on fundus diseases may offer insights for the onset, diagnosis, and prognosis of cerebral diseases. Additionally, research advancements in diagnosing and treating cerebral diseases are relevant for the development of diagnosis and treatment strategies for fundus diseases. Furthermore, fundus imaging enables the non-invasive visualization and quantification of the structure and function of retinal vessels and neural tissues, serving as a unique “window” for researching cerebral vascular and nervous tissues (Figure 1).<sup>25</sup>

## The Correlation Between Ophthalmic or Retinal Artery Occlusion and Acute Ischemic Stroke

OAO or RAO shares a similar development pattern with AIS, often linked to underlying cardiovascular and cerebrovascular conditions.<sup>2</sup> Most patients with OAO or RAO present with multiple major vascular risk factors, including hypertension, diabetes mellitus, and hyperlipidemia (Table 1).<sup>2,26–46</sup> The blood supply to retinal and cerebral tissues primarily originates from the internal carotid artery, and multiple studies have demonstrated the presence of severe atherosclerotic stenosis ( $\geq 70\%$  stenosis) in the internal carotid artery among patients with OAO or RAO (Table 1).<sup>26,32,33,35,38,43,45–48</sup> Cardiogenic embolism is another significant cause of OAO or RAO.<sup>46</sup> Thus, the combination of cardiac disorders in these patients should not be neglected. Several researches have indicated that these patients are frequently detected with coronary artery disease, heart valvular disease, atrial fibrillation and other cardiac disorders (Table 1).<sup>29,33,36,39,40,42,43,45–50</sup> Interestingly, several studies have revealed that some



**Figure 1** Retina as a “window” to brain.

**Table 1** Prevalence (%) of Cardio Cerebral Vascular Disease in Patients with OAO or RAO

	Year	Country	Disease	Sample Size	HTN	DM	HLP	ACS $\geq$ 70%	AF	CHD	VHD	OCI
Benavente et al <sup>26</sup>	2001	America	TMVL	397	55.4	14.4	36.3	41	/	40.3	/	/
Chang et al <sup>27</sup>	2012	China	RAO	464	38	22	10	/	/	/	/	/
Chang et al <sup>28</sup>	2015	China	RAO	688	43	24	12	/	1	/	/	/
Callizo et al <sup>46</sup>	2015	Germany	CRAO	77	73	14	23	40	20	22	17	/
Rim et al <sup>29</sup>	2016	South Korea	RAO	401	77	61	74	/	9	44	/	/
Hong et al <sup>30</sup>	2017	South Korea	RAO	151	58	23	23	/	6	/	/	11
Lavin et al <sup>48</sup>	2018	America	CRAO	103	/	/	/	37	14	20	/	/
French et al <sup>51</sup>	2018	America	CRAO	3338	26	8	/	/	21	/	/	1
Christiansen et al <sup>31</sup>	2018	Denmark	RAO	706	73	36	65	/	/	/	/	23
Avery et al <sup>32</sup>	2019	Canada	OAO, RAO	236	74	24	47	6	14	/	/	21
Mir et al <sup>33</sup>	2019	America	CRAO	17117	72	26	51	22	16	35	12	9
Kang et al <sup>34</sup>	2019	China	CRAO	3778	30	15	7	/	1	/	/	/
Zarkali et al <sup>35</sup>	2019	England	RAO, TMVL	400	51	14	35	8	9	/	/	5
Schorr et al <sup>36</sup>	2020	America	RAO, TMVL	4871	62	24	60	/	16	/	13	/
Laczynski et al <sup>37</sup>	2020	America	RAO	221	66.1	29	58.4	/	/	16.7	/	/
Shaikh et al <sup>39</sup>	2020	America	RAO	19809	67.36	22.48	45.44	/	12.84	/	9.16	/
Wałek et al <sup>47</sup>	2021	Poland	RAO	131	84.7	20.6	/	13.5	14.5	39.7	/	13
Scoles et al <sup>52</sup>	2021	America	RAO	16193	86.8	40.3	/	/	/	17.5	/	/
Wałek et al <sup>40</sup>	2022	Poland	RAO	139	85.61	20.14	73.38	/	15.11	41.73	/	12.23
Chodnicki et al <sup>41</sup>	2022	America	CRAO	89	92.1	29.2	52.8	/	/	/	/	31.5
Suri et al <sup>42</sup>	2022	America	RAO	14527	82	32	61	/	13	33	18	16
Smith et al <sup>43</sup>	2022	Canada	CRAO	27	85.2	51.9	81.5	10	11.1	40.7	/	33.3
Orskov et al <sup>49</sup>	2022	Denmark	RAO	7960	40.4	14.6	/	/	9.0	18.3	/	11.8
Dropinski et al <sup>44</sup>	2022	Poland	CRAO	126	38.9	19	67.5	/	/	/	/	/
Orskov et al <sup>50</sup>	2022	Denmark	RAO	5683	40	15.3	/	/	8	14.3	/	/
Gao et al <sup>45</sup>	2023	China	OAO, RAO	69	59.4	20.3	15.9	31.9	1.4	11.6	0	17.4

**Abbreviations:** OAO, ophthalmic artery occlusion; RAO, retinal artery occlusion; HTN, hypertension; DM, diabetes mellitus; HLP, hyperlipidemia; CAS, carotid stenosis; AF, atrial fibrillation; VHD, valvular heart disease; OCI, old cerebral infarction; TMVL, transient monocular vision loss; CRAO, central retinal artery occlusion.

patients with OAO or RAO have a history of stroke (Table 1).<sup>30–33,35,38,40–43,45,47,49,51</sup> Nonetheless, the onset of OAO or RAO still elevates the risk of AIS.<sup>26,42</sup>

Most studies have shown that patients with OAO or RAO were at an increased risk of AIS. The AIS risk was significantly higher within a few days after the onset of visual loss, and the AIS morbidity within the next three years ranged from 2% to 20% (Table 2).<sup>2</sup> Differences in the occurrence probability may be related to variations in follow-up times, patient populations, and study designs. Several clinical studies have revealed that cranial magnetic resonance imaging (MRI) of patients with RAO within 1 week of disease onset showed a high incidence (13% to 24%) of asymptomatic and multifocal of fresh cerebral infarcts caused by microarterial embolism. These infarcts were also predictive of a high incidence of AIS in the future.<sup>53–55</sup> One possible explanation is that when OAO or RAO occurs, it suggests the patients' blood vessels, especially the microscopic arteries, undergo ischemic pathological changes. And due to the common vascular source between the retinal and cerebral microvasculature and their similar structural and functional characteristics,<sup>21</sup> these patients have a high probability of experiencing cerebral ischemic events in microvasculature perfusion areas. They also have a higher future risk of cardiovascular and cerebrovascular events. A real-world study in America showed that patients with acute CRAO had an incidence of AIS of approximately 12.15% during hospitalization (Table 2).<sup>33</sup> And the risk of AIS would increase by 28-fold in the first week and 33-fold in the second week after the onset of CRAO.<sup>51</sup> A related meta-analysis showed that the proportion of CRAO patients exhibiting AIS on MRI within 7 days was 30%, while for BRAO patients, it was 25%.<sup>56</sup> Additionally, a statistical analysis of a readmission database in the United States showed that the highest proportion of RAO patients who were readmitted due to AIS occurred within 150 days of RAO.<sup>36</sup> However, cerebral tissue has more collateral circulation and functional compensation than the retina, and the symptoms of cerebral neurological damage caused by arteriole spasm or occlusion are mild in early stage and progress chronically. Therefore, it is hard to draw ophthalmologists' attention to seek help from

**Table 2** Morbidity (%) of Future AIS in Patients with OAO or RAO

	Year	Country	Disease	Sample Size	Follow-up Time	Morbidity (%)
Benavente et al <sup>26</sup>	2001	America	TMVL	397	One year	14.10
Chang et al <sup>27</sup>	2012	China	RAO	464	Three years	19.61
Park et al <sup>59</sup>	2015	South Korea	CRAO	1655	Half a year	8.77
Callizo et al <sup>46</sup>	2015	Germany	CRAO	77	Four weeks	14.29
Rim et al <sup>29</sup>	2016	South Korea	RAO	401	Ten years	14.96
Hong et al <sup>30</sup>	2017	South Korea	RAO	151	One year	8.61
French et al <sup>51</sup>	2018	America	CRAO	3338	Half a year	4.22
Avery et al <sup>32</sup>	2019	Canada	OAO, RAO	236	Three years	9.62
Mir et al <sup>33</sup>	2019	America	CRAO	17117	In hospital	12.15
Chodnicki et al <sup>60</sup>	2019	America	CRAO	300	Fifteen days	3.00
Kang et al <sup>34</sup>	2019	China	CRAO	3778	One year	4.00
Zarkali et al <sup>35</sup>	2019	England	RAO, TMVL	400	Three months	10.50
Schorr et al <sup>36</sup>	2020	America	RAO, TMVL	4871	One year	5.23
Laczynski et al <sup>37</sup>	2020	America	RAO	221	Two years	2.26
Ayrignac et al <sup>38</sup>	2020	France	RAO, TMVL	103	Three months	19.50
Leisser et al <sup>61</sup>	2020	Austria	RAO	30	One year	6.67
Scoles et al <sup>52</sup>	2021	America	RAO	16193	One year	9.92
Wątek et al <sup>47</sup>	2021	Poland	RAO	131	Eleven years	9.9
Wątek et al <sup>40</sup>	2022	Poland	RAO	139	Twelve years	10.07
Chodnicki et al <sup>41</sup>	2022	America	CRAO	89	Fifteen days	2.20
Suri et al <sup>42</sup>	2022	America	RAO	14527	Half a year	10.90
Smith et al <sup>43</sup>	2022	Canada	CRAO	27	Three months	7.40
Orskov et al <sup>49</sup>	2022	Denmark	RAO	7960	One year	7.10
Gao et al <sup>45</sup>	2023	China	OAO, RAO	69	Two years	15.90

**Abbreviations:** AIS, acute ischemic stroke; OAO, ophthalmic artery occlusion; RAO, retinal artery occlusion; TMVL, transient monocular vision loss; CRAO, central retinal artery occlusion.

neurologists to screen for cerebral disorders in patients with OAO or RAO.<sup>20,26</sup> Nearly 90% of patients who exhibited combined AIS imaging signs within 1 week of the onset of RAO had no neurologic symptoms.<sup>54</sup> However, the EXPRESE study and the SOS-TIA study demonstrated that early aggressive intervention in patients with TIA or minor stroke reduced the risk of recurrent AIS by 80%.<sup>57,58</sup> These studies emphasize the urgency and importance of early neurological screening, stroke risk assessment, and tertiary prevention strategies for patients with OAO or RAO.

The occurrence of OAO or RAO is associated with an increased incidence of distant AIS. A large national study in South Korea revealed that the morbidity rate of AIS was approximately 14.96% within 10 years after the onset of CRAO (Table 2). This represents an approximate 70-fold increase compared to the population without RAO.<sup>29</sup> Studies in China and Poland showed that the incidence of AIS in RAO patients was 19.61% within 3 years and 10.07% within 12 years, respectively (Table 2).<sup>27,40</sup> Therefore, it is urgent and necessary to assess the risk of stroke or other cerebral disorders and develop a treatment approach or prevention strategy for patients with OAO or RAO in clinical practice, yet it is neglected by a large proportion of ophthalmologists.<sup>5</sup>

Most researches have confirmed the increased risk of AIS in patients with OAO or RAO. However, there is limited exploration of risk factors or predictive models related to the future AIS risk in these patients. Nonetheless, valuable insights could still be gleaned from the existing researches. Two clinical studies in South Korea confirmed that age and atherosclerosis were the primary risk factors for future AIS in RAO patients, respectively (Table 3).<sup>29,30</sup> Similar conclusions were drawn by several studies in China and America, which identified additional risk factors such as male and history of stroke or TIA (Table 3).<sup>26,33,34,42</sup> It was noteworthy that three studies published relevant prediction models (Table 3).<sup>29,33,42</sup> However, the validation of these models was hindered by differences in statistical methods and the absence of reported baseline survival probabilities. Efforts are underway to establish the first clinical database of OAO or RAO patients in Shenzhen, China, with the aim of developing a prediction model for the risk of AIS in these patients

**Table 3** Influence Factors for Future AIS Risk in Patients with OAO or RAO

	Year	Country	Disease	Sample Size	Statistics	Risk Factors (HR/OR)
Benavente et al <sup>26</sup>	2001	America	TMVL	397	Single-factor correlation analysis	Age (2.9), male (2.2), stroke/TIA history (2.3), intermittent claudication history (2.2), internal carotid artery stenosis (2.2), without cerebral collateral circulation (2.4).
Rim et al <sup>29</sup>	2016	South Korea	RAO	401	COX regression model	Hypertension (1.95), coronary heart disease (1.89), atrial fibrillation (1.78), age ≥65 years old (3.11).
Hong et al <sup>30</sup>	2017	South Korea	RAO	151	Correlation analysis	Large artery atherosclerosis (3.94)
Mir et al <sup>33</sup>	2019	America	CRAO	17117	Logistic regression model	Age ≥75 years old (0.90), female (1.19), hypertension (1.22), internal carotid artery stenosis (1.91), aortic valve disease (1.65), smoke (1.30), alcoholism (1.39)
Kang et al <sup>34</sup>	2019	China	CRAO	3778	Correlation analysis	Male (1.46), age (1.14)
Suri et al <sup>42</sup>	2022	America	RAO	14527	Logistic regression model	Stroke/TIA history (1.39), Elixhauser comorbidities index ≥3 (1.29)
Gao et al <sup>45</sup>	2023	China	OAO, RAO	69	Single-factor correlation analysis	Carotid stenosis ≥70% (6.77)

**Abbreviations:** AIS, acute ischemic stroke; OAO, ophthalmic artery occlusion; RAO, retinal artery occlusion; TMVL, transient monocular vision loss; TIA, Transient ischemic attack; CRAO, central retinal artery occlusion.

[ChiCTR2300072813]. However, the limited sample size poses a challenge to the study. The establishment and validation of future prediction models should be pursued through large-sample, multicenter OAO or RAO cohort studies.

## Comparison and Advance of Thrombolysis for Ophthalmic or Retinal Artery Occlusion with Acute Ischemic Stroke

Given that OAO or RAO shares the same pathogenesis with AIS and considering the success and widespread use of thrombolysis in AIS, an increasing number of healthcare organizations are progressively exploring the development of thrombolysis for OAO or RAO. In AIS, the purpose of thrombolysis is to rescue the neurons in the penumbra. Therefore, imaging assessments of the perfusion and function of penumbra can help evaluate the necessity for thrombolytic therapy.<sup>9</sup> While in CRAO, thrombolysis aims to salvage the ischemic and anoxic cells in retinal posterior pole, preventing irreversible failure of ion pumps.<sup>9</sup> As for the penumbra in the retinal peripheral part, its survival status is not influenced by the intervention timing due to continuous mild oxygen supply from the choroidal circulation.<sup>9</sup> Currently, thrombolysis for OAO and RAO is primarily divided into intravenous thrombolysis and intra-arterial thrombolysis. The main adverse effects include hemorrhage of intracranial, intraocular, or other organ, as well as unpredictable stroke-like neurological signs or symptoms. A network meta-analysis using the SUCRA method concluded that intravenous thrombolysis was more effective and safer than intra-arterial thrombolysis.<sup>62</sup> However, it is important to consider the impact of onset-intervention time, thrombolytic duration and procedural complexity on the outcomes. The time window for thrombolysis remains uncertain. Animal experiments have demonstrated that when the retina is completely ischemic and anoxic for more than 97 minutes, retinal ganglion cells and photoreceptors start to experience irreversible damage, which gradually expands; and by 4 hours, almost the entire retina is affected.<sup>63</sup> Another study found that when retinal neurons ischemia occurs between 97 to 120 minutes, even if reperfusion is achieved, the electrophysiological activity cannot be restored.<sup>64</sup> Therefore, if neurons function rather than structure is used as a criterion, the time window may be shorter. However, the onset-intervention time for patients with OAO or RAO in clinical practice often exceeds 2 hours, 4 hours or even longer, and there is a lack of data from large-scale, well-designed randomized controlled trials (RCTs). Additionally, the proportion of visual function recovery after thrombolysis in patients with CRAO occurring >4 hours is comparable to the spontaneous visual recovery in the natural state,<sup>9</sup> and most emboli of

OAO or RAO are cholesterol or calcitonin,<sup>65</sup> which are not effectively treated with thrombolytic drugs. Consequently, the use of thrombolysis for vascular OAO or RAO remains a topic of controversy. In this part we will discuss intravenous thrombolysis and intra-arterial thrombolysis for OAO or RAO, respectively, and compare them with thrombolysis for AIS.

## Intravenous Thrombolysis

Similar to AIS, the primary intravenous thrombolytic drug used for OAO or RAO is recombinant human tissue plasminogen activator (rtPA), with alteplase being the most frequently employed medication. The recommended dosage is 0.9 mg/kg, administered as a 10% intravenous bolus within the initial minute, followed by the remaining 90% infused over 1 hour.<sup>66</sup> The time window for intravenous thrombolysis in AIS is within 4.5 hours from symptom onset,<sup>67</sup> and the EXTEND RCT results suggest that this time window could be extended to 9 hours.<sup>68</sup> For OAO or RAO, the management of CRAO from American Heart Association in 2021 recommends initiating intravenous thrombolysis within 4.5 hours of disease onset.<sup>66</sup> Two prospective studies in Germany and America have also demonstrated that intravenous thrombolysis within 4.5 hours can lead to positive visual outcomes in patients with CRAO (Table 4).<sup>69,70</sup> A meta-analysis indicated that intravenous thrombolysis within 4.5 hours led to a 74.3% improvement in visual acuity of  $\geq 0.3$  logMAR, and a 39% effective rate of visual acuity  $\geq 20/100$ .<sup>71</sup> Another meta-analysis demonstrated that intravenous thrombolysis performed within 4.5 hours resulted in superior prognostic visual outcomes compared to administration after 4.5 hours.<sup>62</sup> However, retinal ganglion cells are more vulnerable to ischemia and hypoxia compared to cerebral neurons,<sup>26</sup> which suggests that the time window for intravenous thrombolysis should be shorter than 4.5 hours. Currently, double-blind, double-dummy, multicenter RCTs comparing the efficacy and safety in intravenous thrombolysis for CRAO patients between alteplase and placebo are underway in France [NCT03197194, THEIA] and Germany [NCT04965038, REVISION] and these studies are anticipated to conclude in 2024 and 2026, respectively, which will contribute to the understanding of the efficacy, safety, and time window of intravenous thrombolysis in OAO or RAO.

New thrombolytic drugs teneplase, have garnered significant attention due to its rapid onset of action, prolonged half-life, ease of administration, lower injection concentration (0.25 mg/kg), shorter treatment duration, and improved efficacy and safety profile.<sup>79</sup> Currently, a Phase III double-blind, double-dummy, multicenter RCT on teneplase for intravenous thrombolysis in CRAO is ongoing in Norway [NCT04526951, TenCRAOS] and is anticipated to conclude in 2024. In the near future, teneplase may potentially replace alteplase as the first-line agent for intravenous thrombolysis in AIS, OAO, or RAO.

## Intra-Arterial Thrombolysis

Because of the absence of evidence-based medicine, intra-arterial thrombolysis is not currently recommended as the primary treatment for AIS in the guidelines, leading to its limited use in clinical practice. There have been no large-scale

**Table 4** Efficacy and Safety of Intravenous Thrombolysis in Patients with OAO or RAO

	Year	Country	Study type	Sample Size	Intervention Time (h)	Efficient	Complication
Kattah et al <sup>72</sup>	2002	America	Retrospective	12	5.75±3.98	83.33%	4 Neovascular glaucoma
Hattenbach et al <sup>73</sup>	2008	Germany	Prospective	28	6.46±3.17	32.14%	/
Chen et al <sup>74</sup>	2011	Australia	RCT	8	14.4±6.5	25%	1 ICH, 1 Vitreous hemorrhage
Nedelmann et al <sup>75</sup>	2015	Germany	Prospective	11	4.96±2.47	72.73%	None
Wu et al <sup>76</sup>	2016	China	RCT	24	/	87.5%	3 Periodontal hemorrhage
Preterre et al <sup>77</sup>	2017	France	Retrospective	30	4.55±1.05	55.2%	3 ICH, 1 Hematuria
Schultheiss et al <sup>69</sup>	2018	Germany	Prospective	20	3.05±1.03	25%	1 Angioedema, 1 AAAH
Mac et al <sup>70</sup>	2020	America	Prospective	25	Within 6h	44%	5 ICH, 1 Oral edema, 1 AAAH
Baumgartner et al <sup>78</sup>	2023	Switzerland	Prospective	47	4.37 (0.5,14.42)	44.68%	2 ICH, 1 Intraocular hemorrhage

**Abbreviations:** OAO, ophthalmic artery occlusion; RAO, retinal artery occlusion; RCT, randomized controlled trial; ICH, intracerebral hemorrhage; AAAH, abdominal aortic aneurysm hemorrhage.

multicenter RCTs on the efficacy and safety of intra-arterial thrombolysis in AIS. However, insights can still be gleaned from existing studies. According to the PROACT II study, arterial thrombolysis (9mg urokinase + heparin) significantly enhances the mRS score at 90 days for patients with AIS who undergo thrombolysis beyond the venous system.<sup>80</sup> Additionally, the CHOICE study showed that supplementary intra-arterial thrombolysis (0.225 mg/kg alteplase) resulted in improved mRS scores at 90 days for AIS patients who remained unvascularized after mechanical thrombolysis, without any observed adverse effects.<sup>81</sup>

In contrast to the unfavorable status of intra-arterial thrombolysis in AIS, superselective intra-arterial ophthalmic thrombolysis has been extensively researched in OAO or RAO. However, the majority of these studies are small-sample, single-center retrospective studies (Table 5). The present thrombolytic drugs of intra-arterial ophthalmic thrombolysis are urokinase or rtPA, typically administered at a consistent rate, without standardized concentration and duration of administration.<sup>82</sup> In contrast to the favorable results of intra-artery thrombolysis in CRAO reported in most clinical studies,<sup>83–88</sup> the European EAGLE study, the sole prospective multicenter RCT on the efficacy and safety of intra-arterial thrombolysis in CRAO, concluded that intra-arterial thrombolysis was not recommended as a treatment option for acute CRAO due to a comparable visual prognosis to conservative treatment and increased adverse effects (Table 5).<sup>89</sup> However, in the EAGLE study, only 4 people in the intra-arterial thrombolysis group intervened within 6 hours, compared to 10 in the conservative treatment group. Considering the significant impact of the onset-intervention time on visual prognosis, the negative results may be attributed to delayed interventions during intra-arterial thrombolysis. Consequently, we should consider the impact of variations in the onset-intervention time on conclusions when literature reviewing. The optimal time window for intra-arterial thrombolysis in OAO or RAO remains uncertain, as some studies indicated that the most favorable outcomes were attained within 4 hours,<sup>85,87</sup> whereas others suggested that improved visual prognosis was still obtained within 6 hours or even 8 hours.<sup>83,90</sup> One meta-analysis indicated that even intra-arterial thrombolysis within 24 hours could result in a 60% improvement in visual acuity of  $\geq 0.3$  logMAR, and a 21.9% effective rate of visual acuity  $\geq 20/100$ ,<sup>71</sup> while another meta-analysis revealed that the visual acuity prognosis following intra-arterial thrombolysis was more favorable within 6 hours, with limited improvement beyond this time frame.<sup>91</sup>

**Table 5** Efficacy and Safety of Intra-Arterial Thrombolysis in Patients with OAO or RAO

	Year	Country	Study Type	Sample Size	Intervention Time (h)	Efficient	Complication
Schumacher et al <sup>92</sup>	1993	Germany	Retrospective	23	15.86±16.84	26.09%	2 Arterial thromboembolism, 1 Puncture hematoma, 1 Orbital pain
Weber et al <sup>93</sup>	1998	Switzerland	Retrospective	17	4.2 (1, 6)	29.41%	2 TIA
Richard et al <sup>83</sup>	1999	Germany	Retrospective	53	13.74±9.7	66.04%	2 TIA, 1 Hypertensive crisis
Schmidt et al <sup>84</sup>	2002	Germany	Retrospective	62	10.8±8.5	58.06%	2 TIA
Butz et al <sup>94</sup>	2003	Switzerland	Retrospective	22	7.6±1.8	40.91%	2 TIA, 1 AIS, 1 ICH
Arnold et al <sup>85</sup>	2004	Switzerland	Retrospective	37	4±1	21.62%	2 TIA, 1 AIS
Petterson et al <sup>95</sup>	2005	England	Retrospective	9	9.72±3.71	66.67%	None
Aldrich et al <sup>86</sup>	2008	America	Prospective	21	3.4±2.0	76.2%	2 Puncture hematoma
Zhang et al <sup>90</sup>	2009	China	Retrospective	49	Median 4.5h	36.73%	1 TIA, 2 Fundus hemorrhage
Schumacher et al <sup>89</sup>	2010	Germany and Austria	RCT	44	12.78±5.77	57.14%	2 ICH, 12 Neurological disorders
Ahn et al <sup>96</sup>	2013	South Korea	Retrospective	57	22.7±30.6	31%	2 Puncture hematoma, 2 Ocular hypertension, 1 Hemianopsia, 1 Headache, 1 Tinnitus, 1 Hyperesthesia
Mercier et al <sup>97</sup>	2014	France	Retrospective	14	7.9±3.4	42.86%	None
Wang et al <sup>87</sup>	2017	China	Prospective	50	22 (8, 76)	42%	1 TIA
Sobol et al <sup>88</sup>	2021	America	Retrospective	15	8.83±2.29	53.33%	None
Ko et al <sup>98</sup>	2021	South Korea	Retrospective	44	16.96±16.93	70.45%	2 ICH, 1 Recurrent CRAO, 9 Dizzy, 8 Headache, 1 Ophthalmodynia, 2 Hand tremor

**Abbreviations:** OAO, ophthalmic artery occlusion; RAO, retinal artery occlusion; TIA, transient ischemic attack; AIS, acute ischemic stroke; ICH, intracerebral hemorrhage; RCT, randomized controlled trial; CRAO, central retinal artery occlusion.



Regrettably, the EAGLE study was terminated in 2009, resulting in the absence of ongoing large-scale, multicenter RCTs on the efficacy and safety of intra-arterial thrombolysis in OAO or RAO. Due to the unverified efficacy and safety, it is still not endorsed as the primary treatment option for OAO or RAO in the guidelines. In theory, thrombolytic drugs administered directly into the ophthalmic artery for thrombolysis using superselective microcatheter placement are expected to exhibit improved efficacy and safety. However, based on the existing evidence, it's plausible that intra-artery thrombolysis may only be advantageous if the intervention occurs within 4 or 6 hours and if the embolic composition is a fibrin embolus. Consequently, the management of CRAO from American Heart Association in 2021 suggests that intra-arterial thrombolysis could be contemplated for patients with OAO or RAO who have contraindications to intravenous thrombolysis, following a comprehensive assessment of the benefits and risks.<sup>66</sup> Nevertheless, it's important to acknowledge that this technique has been utilized for over two decades in accessible medical facilities.

Kadonosono et al in Japan recently developed a new technique for intra-arterial thrombolysis. They conducted vitrectomy on 13 patients with CRAO within 26–48 hours of onset, followed by a direct injection of 200ug of rtPA into retinal arteries. Postoperative funduscopic angiography revealed a 76.9% complete recanalization rate of the vessels and a 92.3% improvement in visual acuity of  $\geq 0.3$  logMAR, with a mean visual acuity improvement to 20/130. There was only one case of severe vitreous hemorrhage requiring reoperation.<sup>99</sup> While the reported results are promising, this technique remains highly challenging, and its efficacy and safety require further confirmation through robust RCT studies involving larger sample sizes.

## Ophthalmic or Retinal Artery Occlusion in Coronavirus Disease of 2019

The Coronavirus Disease 2019 (COVID-19) has emerged as a significant global health event in recent years, claiming the lives of thousands and profoundly impacting the global economy. While in May 2023, the World Health Organization declared COVID-19 was no longer in its emergency phase, it is highly likely that coronavirus will persist alongside humanity in the long term. COVID-19, caused by a virus, can lead to severe vascular damage. It affects vascular endothelial cells through the angiotensin-converting enzyme 2 (ACE2) receptor, triggering vascular inflammation, resulting in circulatory disturbances and tissue ischemia.<sup>100,101</sup> Moreover, endothelial cell damage induces vasoconstriction, promotes thrombus formation, and elevates the body into a procoagulant state.<sup>102,103</sup> Additionally, endothelial cell impairment can activate inflammatory pathways, inciting a “cytokine storm” that leads to further organ damage.<sup>102,103</sup> Since ACE2 receptors are also expressed in retinal vascular endothelial cells,<sup>104</sup> theoretically, coronavirus could damage retinal vascular endothelial cells, triggering blood hypercoagulability and vascular inflammation, increasing the incidence of OAO or RAO.<sup>105,106</sup> A cohort study examining the prevalence of retinal artery occlusion (RAO) in the United States during the pre-COVID-19 period (January 2019 to February 2020) and the COVID-19 pandemic (March 2020 to December 2020) hinted at a slight increase in RAO incidence after the COVID-19 outbreak, but no significant difference compared to pre-outbreak levels was observed.<sup>107</sup> Another cohort study suggested that the prevalence of RAO was approximately 3 per million during six months after contracting the coronavirus, showing no significant disparity from pre-infection rates.<sup>108</sup> Although cases of COVID-19 patients developing OAO or RAO have been reported,<sup>109,110</sup> the low incidence of RAO, coupled with a lack of corresponding causal studies, currently does not substantiate a direct correlation between COVID-19 and OAO or RAO incidence. Further mechanistic research is needed to confirm their relationship.

Interestingly, some case reports suggest that RAO may be a complication of receiving the COVID-19 vaccine.<sup>111,112</sup> One possible explanation is that vaccination triggers the immune system, leading to immune-mediated retinal vascular inflammation in some individuals.<sup>109</sup> Summarizing the current published case reports, RAO often occurs after the first dose of viral vector vaccines and the second dose of mRNA vaccines.<sup>111</sup> However, due to the extremely low incidence of RAO post-vaccination,<sup>113</sup> the lack of the corresponding causal studies, the association between COVID-19 vaccine administration and RAO incidence cannot currently be definitively established.

## Comparison of Hyperbaric Oxygen Therapy for Ophthalmic or Retinal Artery Occlusion with Acute Ischemic Stroke

Hyperbaric oxygen therapy (HBOT) can increase the partial pressure of oxygen in plasma and the dissolved oxygen content in plasma by 23-fold.<sup>114</sup> Under normoxic conditions, approximately 15% of the oxygen supply to the retina originates from the

choroidal circulation.<sup>114</sup> And HBOT can significantly increase the oxygen partial pressure in the choroidal circulation, allowing oxygen from the choroidal circulation to diffuse into the inner layers of the retina.<sup>9,115</sup> Several clinical studies have also confirmed the effectiveness of HBOT in improving visual prognosis in patients with CRAO,<sup>116</sup> and suggesting that the effective treatment window should be within 24 hours of CRAO onset,<sup>117,118</sup> and possibly up to 72 hours,<sup>119</sup> with an effective treatment duration exceeding 9 hours.<sup>116</sup> It is important to note that irreversible neuronal damage has not yet occurred,<sup>120</sup> and the choroidal circulation is still able to provide oxygenation to the retina<sup>121</sup> for HBOT to be effective. OAO severely affect the choroidal circulation, which is why HBOT cannot be used for OAO.<sup>9,115</sup> Theoretically, HBOT can diffuse oxygen to ischemic areas inaccessible to blood in AIS, thereby increasing the oxygenation level in the penumbra to prevent further infarct expansion.<sup>122</sup> However, when the penumbra has fully transformed into infarction, HBOT will no longer be effective. Therefore, the application of HBOT in AIS is time-limited.<sup>122</sup> Animal experiments suggest that the time window is approximately within 12 hours of AIS occurrence. However, due to the lack of high-quality clinical studies, the efficacy and time window of HBOT for AIS patients cannot be definitively determined.<sup>123</sup> Consequently, the American Heart Association/American Stroke Association's 2019 AIS guidelines classified HBOT as a Class III recommendation, suggesting its use "only in the context of clinical trials or in patients with cerebral air embolism".<sup>124</sup> Large-sample RCTs should be conducted to investigate the efficacy and safety of HBOT in patients with AIS or CRAO, and to establish a standardized treatment regimens (including time window, oxygen concentration, pressure, duration, frequency and course).

## Conclusions and Future Directions

OAO or RAO share the same pathogenesis and cardio-cerebrovascular risk factors with AIS. Due to the high risk of future AIS, the central nervous system function of these patients should be promptly screened and evaluated. It is necessary to establish and validate a predictive model through a large-sample, multicenter cohort study of OAO or RAO due to the differences in conclusions among previous similar studies and the lack of reliable prediction models. Such a model would be a valuable tool for ophthalmologists to assess the risk of future AIS and implement intervention measures in these patients, as well as to raise patients' awareness about AIS prevention and improve therapies for OAO or RAO. In addition, there is a lack of reliable evidence-based medicine on the efficacy and safety of intra-arterial thrombolysis in OAO or RAO, therefore, future large-sample, multicenter RCTs about this should be conducted, despite the challenges posed by the high demands on the onset-intervention time. And since the visual prognosis of patients with OAO or RAO depends on the onset-intervention time, it is important to develop an "retinal stroke" map network similar to that of AIS and collaborate with emergency physicians, ophthalmologists, interventionalists, and neurologists to establish a fast track for thrombolysis for these patients, aiming to increase the salvage rate and improve the visual prognosis. Lastly, the strong link between retina and brain may have implications for the development of co-treatments for retinal and cerebral disorders, and future research is worthwhile to verify whether the treatment of each has beneficial effects on the other.

## Search Strategy and Selection Criteria

Data were identified by searches of PubMed and references from relevant articles using the terms "ophthalmic artery occlusion", "retinal artery occlusion", "stroke", "thrombolysis", "COVID-19", "COVID-19 vaccine" and "hyperbaric oxygen". Articles published in English between Jan 1, 1990, and June 1, 2023, were included.

## Funding

This work was supported by Shenzhen Second People's Hospital Clinical Research Fund of Shenzhen High-level Hospital Construction Project under Grant No. 2023yjlcjy006.

## Disclosure

The authors report that there are no competing interests in this work.

## References

1. Hayreh SS. Ocular vascular occlusive disorders: natural history of visual outcome. *Prog Retin Eye Res.* 2014;41:1–25. doi:10.1016/j.preteyeres.2014.04.001
2. Scott IU, Campochiaro PA, Newman NJ, et al. Retinal vascular occlusions. *Lancet.* 2020;396(10266):1927–1940. doi:10.1016/S0140-6736(20)31559-2
3. Leavitt JA, Larson TA, Hodge DO, et al. The incidence of central retinal artery occlusion in Olmsted County, Minnesota. *Am J Ophthalmol.* 2011;152(5):820–823.e822. doi:10.1016/j.ajo.2011.05.005
4. Park SJ, Choi NK, Seo KH, et al. Nationwide incidence of clinically diagnosed central retinal artery occlusion in Korea, 2008 to 2011. *Ophthalmology.* 2014;121(10):1933–1938. doi:10.1016/j.ophtha.2014.04.029
5. Bioussé V, Nahab F, Newman NJ. Management of acute retinal ischemia: follow the guidelines! *Ophthalmology.* 2018;125(10):1597–1607. doi:10.1016/j.ophtha.2018.03.054
6. Wang W, Jiang B, Sun H, et al. Prevalence, incidence, and mortality of stroke in China: results from a nationwide population-based survey of 480 687 adults. *Circulation.* 2017;135(8):759–771. doi:10.1161/CIRCULATIONAHA.116.025250
7. Longde W, Bin P, Hongqi Z, et al. Brief report on stroke prevention and treatment in China, 2020. *Chin J Cerebrovasc Dis.* 2022;19(02):136–144. doi:10.3969/j.issn.1672-5921.2022.02.011
8. Peng B, Wu B. Chinese guidelines for diagnosis and treatment of acute ischemic stroke 2018. *Chin J Neurol.* 2018;51(09):666–682. doi:10.3760/cma.j.issn.1006-7876.2018.09.004
9. McLeod D, Beatty S. Evidence for an enduring ischaemic penumbra following central retinal artery occlusion, with implications for fibrinolytic therapy. *Prog Retin Eye Res.* 2015;49:82–119. doi:10.1016/j.preteyeres.2015.06.001
10. McLeod D. Central retinal artery occlusion and cerebral stroke. *Eye.* 2013;27(12):1422. doi:10.1038/eye.2013.219
11. Jacobs N. Concerning central retinal artery occlusion (CRAO) and cerebral stroke. *Eye.* 2014;28(10):1269–1270. doi:10.1038/eye.2014.118
12. Sacco RL, Kasner SE, Broderick JP, et al. An updated definition of stroke for the 21st century: a statement for healthcare professionals from the American heart association/American stroke association. *Stroke.* 2013;44(7):2064–2089. doi:10.1161/STR.0b013e318296aeca
13. Muller F, O’Rahilly R. The first appearance of the neural tube and optic primordium in the human embryo at stage 10. *Anat Embryol.* 1985;172(2):157–169. doi:10.1007/BF00319598
14. Wassle H. Parallel processing in the mammalian retina. *Nat Rev Neurosci.* 2004;5(10):747–757. doi:10.1038/nrn1497
15. Ho WL, Leung Y, Tsang AW, et al. Review: tauopathy in the retina and optic nerve: does it shadow pathological changes in the brain? *Mol Vis.* 2012;18:2700–2710.
16. London A, Benhar I, Schwartz M. The retina as a window to the brain—from eye research to CNS disorders. *Nat Rev Neurol.* 2013;9(1):44–53. doi:10.1038/nrneurol.2012.227
17. Wolman DN, Moraff AM, Heit JJ. Anatomy of the intracranial arteries: the internal carotid artery. *Neuroimaging Clin N Am.* 2022;32(3):603–615. doi:10.1016/j.nic.2022.04.006
18. Klijn CJ, Kappelle LJ, Tulleken CA, et al. Symptomatic carotid artery occlusion. A reappraisal of hemodynamic factors. *Stroke.* 1997;28(10):2084–2093. doi:10.1161/01.str.28.10.2084
19. Powers WJ. Cerebral hemodynamics in ischemic cerebrovascular disease. *Ann Neurol.* 1991;29(3):231–240. doi:10.1002/ana.410290302
20. Cheung CY, Ikram MK, Chen C, et al. Imaging retina to study dementia and stroke. *Prog Retin Eye Res.* 2017;57:89–107. doi:10.1016/j.preteyeres.2017.01.001
21. Patton N, Aslam T, Macgillivray T, et al. Retinal vascular image analysis as a potential screening tool for cerebrovascular disease: a rationale based on homology between cerebral and retinal microvasculatures. *J Anat.* 2005;206(4):319–348. doi:10.1111/j.1469-7580.2005.00395.x
22. Kaur C, Foulds WS, Ling EA. Blood-retinal barrier in hypoxic ischaemic conditions: basic concepts, clinical features and management. *Prog Retin Eye Res.* 2008;27(6):622–647. doi:10.1016/j.preteyeres.2008.09.003
23. Wilbanks GA, Streilein JW. Fluids from immune privileged sites endow macrophages with the capacity to induce antigen-specific immune deviation via a mechanism involving transforming growth factor-beta. *Eur J Immunol.* 1992;22(4):1031–1036. doi:10.1002/eji.1830220423
24. Streilein JW. Ocular immune privilege: therapeutic opportunities from an experiment of nature. *Nat Rev Immunol.* 2003;3(11):879–889. doi:10.1038/nri1224
25. Wu HQ, Wu H, Shi LL, et al. The association between retinal vasculature changes and stroke: a literature review and Meta-analysis. *Int J Ophthalmol.* 2017;10(1):109–114. doi:10.18240/ijo.2017.01.18
26. Benavente O, Eliasziw M, Streifler JY, et al. Prognosis after transient monocular blindness associated with carotid-artery stenosis. *N Engl J Med.* 2001;345(15):1084–1090. doi:10.1056/NEJMoa002994
27. Chang YS, Jan RL, Weng SF, et al. Retinal artery occlusion and the 3-year risk of stroke in Taiwan: a nationwide population-based study. *Am J Ophthalmol.* 2012;154(4):645–652.e641. doi:10.1016/j.ajo.2012.03.046
28. Chang YS, Chu CC, Weng SF, et al. The risk of acute coronary syndrome after retinal artery occlusion: a population-based cohort study. *Br J Ophthalmol.* 2015;99(2):227–231. doi:10.1136/bjophthalmol-2014-305451
29. Rim TH, Han J, Choi YS, et al. Retinal Artery Occlusion and the Risk of Stroke Development: twelve-Year Nationwide Cohort Study. *Stroke.* 2016;47(2):376–382. doi:10.1161/STROKEAHA.115.010828
30. Hong JH, Sohn SI, Kwak J, et al. Retinal artery occlusion and associated recurrent vascular risk with underlying etiologies. *PLoS One.* 2017;12(6):e0177663. doi:10.1371/journal.pone.0177663
31. Christiansen CB, Torp-Pedersen C, Olesen JB, et al. Risk of incident atrial fibrillation in patients presenting with retinal artery or vein occlusion: a nationwide cohort study. *BMC Cardiovasc Disord.* 2018;18(1):91. doi:10.1186/s12872-018-0825-1
32. Avery MB, Magal I, Kherani A, et al. Risk of stroke in patients with ocular arterial occlusive disorders: a retrospective Canadian study. *J Am Heart Assoc.* 2019;8(3):e010509. doi:10.1161/JAHA.118.010509
33. Mir TA, Arham AZ, Fang W, et al. Acute vascular ischemic events in patients with central retinal artery occlusion in the United States: a nationwide study 2003–2014. *Am J Ophthalmol.* 2019;200:179–186. doi:10.1016/j.ajo.2019.01.009
34. Kang EY, Lin YH, Wang NK, et al. Aspirin use in central retinal arterial occlusion to prevent ischaemic stroke: a retrospective cohort study in Taiwan. *BMJ Open.* 2019;9(2):e025455. doi:10.1136/bmjopen-2018-025455

35. Zarkali A, Cheng SF, Dados A, et al. Atrial fibrillation: an underestimated cause of ischemic monocular visual loss? *J Stroke Cerebrovasc Dis.* 2019;28(6):1495–1499. doi:10.1016/j.jstrokecerebrovasdis.2019.03.017
36. Schorr EM, Rossi KC, Stein LK, et al. Characteristics and outcomes of retinal artery occlusion: nationally representative data. *Stroke.* 2020;51(3):800–807. doi:10.1161/STROKEAHA.119.027034
37. Laczynski DJ, Gallop J, Lyden SP, et al. Retinal artery occlusion does not portend an increased risk of stroke. *J Vasc Surg.* 2020;72(1):198–203. doi:10.1016/j.jvs.2019.08.279
38. Ayrignac X, Zagroun C, Coget A, et al. Acute retinal arterial ischaemia: silent brain infarcts prevalence and short-term recurrence. *Eur J Neurol.* 2020;27(12):2517–2522. doi:10.1111/ene.14485
39. Shaikh IS, Elsamna ST, Zarbin MA, et al. Assessing the risk of stroke development following retinal artery occlusion. *J Stroke Cerebrovasc Dis.* 2020;29(9):105002. doi:10.1016/j.jstrokecerebrovasdis.2020.105002
40. Roskal-Walek J, Walek P, Biskup M, et al. Retinal artery occlusion and its impact on the incidence of stroke, myocardial infarction, and all-cause mortality during 12-year follow-up. *J Clin Med.* 2022;11(14). doi:10.3390/jcm11144076
41. Chodnicki KD, Tanke LB, Pulido JS, et al. Stroke risk before and after central retinal artery occlusion: a population-based analysis. *Ophthalmology.* 2022;129(2):203–208. doi:10.1016/j.ophtha.2021.07.017
42. Suri K, Majmundar M, Kumar A, et al. Outcomes and readmission in patients with retinal artery occlusion (from the nationwide readmission database). *Am J Cardiol.* 2022;183:105–108. doi:10.1016/j.amjcard.2022.07.040
43. Smith MJ, Benson MD, Tennant M, et al. Central retinal artery occlusion: a retrospective study of disease presentation, treatment, and outcomes. *Can J Ophthalmol.* 2022. doi:10.1016/j.cjco.2022.02.015
44. Dropinski J, Dziedzic R, Kubicka-Trzaska A, et al. Central retinal artery occlusion is related to vascular endothelial injury and left ventricular diastolic dysfunction. *J Clin Med.* 2022;11(8). doi:10.3390/jcm11082263
45. Gao Y, Zhao W, Wu D, et al. Risk and risk factor of ischemic stroke after acute retinal arterial ischemia. *Int Ophthalmol.* 2023. doi:10.1007/s10792-023-02645-x
46. Callizo J, Feltgen N, Pantenburg S, et al. Cardiovascular risk factors in central retinal artery occlusion: results of a prospective and standardized medical examination. *Ophthalmology.* 2015;122(9):1881–1888. doi:10.1016/j.ophtha.2015.05.044
47. Roskal-Walek J, Walek P, Biskup M, et al. Central and branch retinal artery occlusion-do they harbor the same risk of further ischemic events? *J Clin Med.* 2021;10(14). doi:10.3390/jcm10143093
48. Lavin P, Patrylo M, Hollar M, et al. Stroke risk and risk factors in patients with central retinal artery occlusion. *Am J Ophthalmol.* 2018;196:96–100. doi:10.1016/j.ajo.2018.08.027
49. Orskov M, Vorum H, Larsen TB, et al. Evaluation of risk scores as predictive tools for stroke in patients with retinal artery occlusion: a Danish nationwide cohort study. *TH Open.* 2022;6(4):e429–e436. doi:10.1055/s-0042-1758713
50. Orskov M, Vorum H, Larsen TB, et al. Similarities and differences in systemic risk factors for retinal artery occlusion and stroke: a nationwide case-control study. *J Stroke Cerebrovasc Dis.* 2022;31(8):106610. doi:10.1016/j.jstrokecerebrovasdis.2022.106610
51. French DD, Margo CE, Greenberg PB. Ischemic stroke risk in medicare beneficiaries with central retinal artery occlusion: a retrospective cohort study. *Ophthalmol Ther.* 2018;7(1):125–131. doi:10.1007/s40123-018-0126-x
52. Scoles D, McGeehan B, VanderBeek BL. The association of stroke with central and branch retinal arterial occlusion. *Eye.* 2022;36(4):835–843. doi:10.1038/s41433-021-01546-6
53. Helenius J, Arsava EM, Goldstein JN, et al. Concurrent acute brain infarcts in patients with monocular visual loss. *Ann Neurol.* 2012;72(2):286–293. doi:10.1002/ana.23597
54. Lauda F, Neugebauer H, Reiber L, et al. Acute silent brain infarction in monocular visual loss of ischemic origin. *Cerebrovasc Dis.* 2015;40(3–4):151–156. doi:10.1159/000437274
55. Cho KH, Kim CK, Woo SJ, et al. Cerebral small vessel disease in branch retinal artery occlusion. *Invest Ophthalmol Vis Sci.* 2016;57(13):5818–5824. doi:10.1167/iovs.16-20106
56. Fallico M, Lotery AJ, Longo A, et al. Risk of acute stroke in patients with retinal artery occlusion: a systematic review and meta-analysis. *Eye.* 2020;34(4):683–689. doi:10.1038/s41433-019-0576-y
57. Rothwell PM, Giles MF, Chandratheva A, et al. Effect of urgent treatment of transient ischaemic attack and minor stroke on early recurrent stroke (EXPRESS study): a prospective population-based sequential comparison. *Lancet.* 2007;370(9596):1432–1442. doi:10.1016/S0140-6736(07)61448-2
58. Lavalley PC, Meseguer E, Abboud H, et al. A transient ischaemic attack clinic with round-the-clock access (SOS-TIA): feasibility and effects. *Lancet Neurol.* 2007;6(11):953–960. doi:10.1016/S1474-4422(07)70248-X
59. Park SJ, Choi NK, Yang BR, et al. Risk and risk periods for stroke and acute myocardial infarction in patients with central retinal artery occlusion. *Ophthalmology.* 2015;122(11):2336–2343e2332. doi:10.1016/j.ophtha.2015.07.018
60. Chodnicki KD, Pulido JS, Hodge DO, et al. Stroke risk before and after central retinal artery occlusion in a US cohort. *Mayo Clin Proc.* 2019;94(2):236–241. doi:10.1016/j.mayocp.2018.10.018
61. Leisser C, Findl O. Rate of strokes 1 year after retinal artery occlusion with analysis of risk groups. *Eur J Ophthalmol.* 2020;30(2):360–362. doi:10.1177/1120672119830925
62. Liu Y, Cao S, Zhao Y, et al. Network meta-analysis of different thrombolytic strategies for the treatment of central retinal artery occlusion. *Semin Ophthalmol.* 2023;1–10. doi:10.1080/08820538.2023.2249539
63. Hayreh SS, Zimmerman MB, Kimura A, et al. Central retinal artery occlusion. Retinal survival time. *Exp Eye Res.* 2004;78(3):723–736. doi:10.1016/s0014-4835(03)00214-8
64. Hayreh SS, Jonas JB. Optic disk and retinal nerve fiber layer damage after transient central retinal artery occlusion: an experimental study in rhesus monkeys. *Am J Ophthalmol.* 2000;129(6):786–795. doi:10.1016/s0002-9394(00)00384-6
65. Arruga J, Sanders MD. Ophthalmologic findings in 70 patients with evidence of retinal embolism. *Ophthalmology.* 1982;89(12):1336–1347. doi:10.1016/s0161-6420(82)34626-6
66. Mac Grory B, Schrag M, Biousse V, et al. Management of central retinal artery occlusion: a scientific statement from the American heart association. *Stroke.* 2021;52(6):e282–e294. doi:10.1161/STR.0000000000000366

67. Tsvigoulis G, Katsanos AH, Sandset EC, et al. Thrombolysis for acute ischaemic stroke: current status and future perspectives. *Lancet Neurol.* 2023;22(5):418–429. doi:10.1016/S1474-4422(22)00519-1
68. Ma H, Campbell BCV, Parsons MW, et al. Thrombolysis guided by perfusion imaging up to 9 hours after onset of stroke. *N Engl J Med.* 2019;380(19):1795–1803. doi:10.1056/NEJMoa1813046
69. Schultheiss M, Hartig F, Spitzer MS, et al. Intravenous thrombolysis in acute central retinal artery occlusion - A prospective interventional case series. *PLoS One.* 2018;13(5):e0198114. doi:10.1371/journal.pone.0198114
70. Mac Grory B, Nackenoff A, Poli S, et al. Intravenous fibrinolysis for central retinal artery occlusion: a cohort study and updated patient-level meta-analysis. *Stroke.* 2020;51(7):2018–2025. doi:10.1161/STROKEAHA.119.028743
71. Shahjouei S, Bavarsad Shahripour R, Dumitrascu OM. Thrombolysis for central retinal artery occlusion: an individual participant-level meta-analysis. *Int J Stroke.* 2023;17474930231189352. doi:10.1177/17474930231189352
72. Kattah JC, Wang DZ, Reddy C. Intravenous recombinant tissue-type plasminogen activator thrombolysis in treatment of central retinal artery occlusion. *Arch Ophthalmol.* 2002;120(9):1234–1236.
73. Hattenbach LO, Kuhl-Hattenbach C, Scharrer I, et al. Intravenous thrombolysis with low-dose recombinant tissue plasminogen activator in central retinal artery occlusion. *Am J Ophthalmol.* 2008;146(5):700–706. doi:10.1016/j.ajo.2008.06.016
74. Chen CS, Lee AW, Campbell B, et al. Efficacy of intravenous tissue-type plasminogen activator in central retinal artery occlusion: report from a randomized, controlled trial. *Stroke.* 2011;42(8):2229–2234. doi:10.1161/STROKEAHA.111.613653
75. Nedelmann M, Graef M, Weinand F, et al. Retrobulbar spot sign predicts thrombolytic treatment effects and etiology in central retinal artery occlusion. *Stroke.* 2015;46(8):2322–2324. doi:10.1161/STROKEAHA.115.009839
76. Wu XJ, Gao F, Liu X, et al. Observation on therapeutic efficacy of rt-PA intravenous thrombolysis combined with compound anisidine injection on central retinal artery occlusion. *Exp Ther Med.* 2016;12(4):2617–2621. doi:10.3892/etm.2016.3681
77. Preterre C, Godeneche G, Vandamme X, et al. Management of acute central retinal artery occlusion: intravenous thrombolysis is feasible and safe. *Int J Stroke.* 2017;12(7):720–723. doi:10.1177/1747493016687578
78. Baumgartner P, Kook L, Altersberger VL, et al. Safety and effectiveness of IV Thrombolysis in retinal artery occlusion: a multicenter retrospective cohort study. *Eur Stroke J.* 2023;23969873231185895. doi:10.1177/23969873231185895
79. Hill MD, Michel P. Tenecteplase knocking on the door. *Stroke.* 2018;49(9):2276–2277. doi:10.1161/STROKEAHA.118.022318
80. Furlan A, Higashida R, Wechsler L, et al. Intra-arterial prourokinase for acute ischemic stroke. The PROACT II study: a randomized controlled trial. Prolyse in acute cerebral thromboembolism. *JAMA.* 1999;282(21):2003–2011. doi:10.1001/jama.282.21.2003
81. Renu A, Millan M, San Roman L, et al. Effect of intra-arterial alteplase vs placebo following successful thrombectomy on functional outcomes in patients with large vessel occlusion acute ischemic stroke: the choice randomized clinical trial. *JAMA.* 2022;327(9):826–835. doi:10.1001/jama.2022.1645
82. Dumitrascu OM, Newman NJ, Biousse V. Thrombolysis for central retinal artery occlusion in 2020: time is vision! *J Neuroophthalmol.* 2020;40(3):333–345. doi:10.1097/WNO.0000000000001027
83. Richard G, Lerche RC, Knosp V, et al. Treatment of retinal arterial occlusion with local fibrinolysis using recombinant tissue plasminogen activator. *Ophthalmology.* 1999;106(4):768–773. doi:10.1016/S0161-6420(99)90165-3
84. Schmidt DP, Schulte-Monting J, Schumacher M. Prognosis of central retinal artery occlusion: local intraarterial fibrinolysis versus conservative treatment. *AJNR Am J Neuroradiol.* 2002;23(8):1301–1307.
85. Arnold M, Koerner U, Remonda L, et al. Comparison of intra-arterial thrombolysis with conventional treatment in patients with acute central retinal artery occlusion. *J Neurol Neurosurg Psychiatry.* 2005;76(2):196–199. doi:10.1136/jnnp.2004.037135
86. Aldrich EM, Lee AW, Chen CS, et al. Local intraarterial fibrinolysis administered in aliquots for the treatment of central retinal artery occlusion: the Johns Hopkins hospital experience. *Stroke.* 2008;39(6):1746–1750. doi:10.1161/STROKEAHA.107.505404
87. Wang R, Qian L, Wang Y, et al. Evaluation of ophthalmic artery branch retrograde intervention in the treatment of central retinal artery occlusion (CRAO). *Med Sci Monit.* 2017;23:114–120. doi:10.12659/msm.898352
88. Sobol EK, Sakai Y, Wheelwright D, et al. Intra-arterial tissue plasminogen activator for central retinal artery occlusion. *Clin Ophthalmol.* 2021;15:601–608. doi:10.2147/OPHT.S272126
89. Schumacher M, Schmidt D, Jurklics B, et al. Central retinal artery occlusion: local intra-arterial fibrinolysis versus conservative treatment, a multicenter randomized trial. *Ophthalmology.* 2010;117(7):1367–1375e1361. doi:10.1016/j.ophtha.2010.03.061
90. Zhang X, Ji X, Luo Y, et al. Intra-arterial thrombolysis for acute central retinal artery occlusion. *Neurol Res.* 2009;31(4):385–389. doi:10.1179/174313209X444008
91. Hu H, Zhang B, Zhao Y, et al. Efficacy of intra-arterial thrombolysis for acute central retinal artery occlusion: a meta-analysis. *Eur Neurol.* 2022;85(3):186–194. doi:10.1159/000520443
92. Schumacher M, Schmidt D, Wakhloo AK. Intra-arterial fibrinolytic therapy in central retinal artery occlusion. *Neuroradiology.* 1993;35(8):600–605. doi:10.1007/BF00588405
93. Weber J, Remonda L, Mattle HP, et al. Selective intra-arterial fibrinolysis of acute central retinal artery occlusion. *Stroke.* 1998;29(10):2076–2079. doi:10.1161/01.str.29.10.2076
94. Butz B, Strotzer M, Manke C, et al. Selective intraarterial fibrinolysis of acute central retinal artery occlusion. *Acta Radiol.* 2003;44(6):680–684. doi:10.1080/02841850312331287829
95. Petterson JA, Hill MD, Demchuk AM, et al. Intra-arterial thrombolysis for retinal artery occlusion: the Calgary experience. *Can J Neurol Sci.* 2005;32(4):507–511.
96. Ahn SJ, Kim JM, Hong JH, et al. Efficacy and safety of intra-arterial thrombolysis in central retinal artery occlusion. *Invest Ophthalmol Vis Sci.* 2013;54(12):7746–7755. doi:10.1167/iovs.13-12952
97. Mercier J, Kastler A, Jean B, et al. Interest of local intra-arterial fibrinolysis in acute central retinal artery occlusion: clinical experience in 16 patients. *J Neuroradiol.* 2015;42(4):229–235. doi:10.1016/j.neurad.2014.02.007
98. Ko SJ, Shin IC, Kim DW, et al. Safety and efficacy of selective intra-arterial thrombolysis for central retinal artery occlusion. *Korean J Ophthalmol.* 2021;35(4):261–271. doi:10.3341/kjo.2020.0082
99. Kadosono K, Yamane S, Inoue M, et al. Intra-retinal arterial cannulation using a microneedle for central retinal artery occlusion. *Sci Rep.* 2018;8(1):1360. doi:10.1038/s41598-018-19747-7

100. Varga Z, Flammer AJ, Steiger P, et al. Endothelial cell infection and endotheliitis in COVID-19. *Lancet*. 2020;395(10234):1417–1418. doi:10.1016/S0140-6736(20)30937-5
101. Babadaei MMN, Hasan A, Bloukh SH, et al. The expression level of angiotensin-converting enzyme 2 determines the severity of COVID-19: lung and heart tissue as targets. *J Biomol Struct Dyn*. 2021;39(10):3780–3786. doi:10.1080/07391102.2020.1767211
102. Ackermann M, Verleden SE, Kuehnel M, et al. Pulmonary Vascular Endothelialitis, Thrombosis, and Angiogenesis in Covid-19. *N Engl J Med*. 2020;383(2):120–128. doi:10.1056/NEJMoa2015432
103. Gupta A, Madhavan MV, Sehgal K, et al. Extrapulmonary manifestations of COVID-19. *Nat Med*. 2020;26(7):1017–1032. doi:10.1038/s41591-020-0968-3
104. Senanayake P, Drazba J, Shadrach K, et al. Angiotensin II and its receptor subtypes in the human retina. *Invest Ophthalmol Vis Sci*. 2007;48(7):3301–3311. doi:10.1167/iovs.06-1024
105. Sen S, Kannan NB, Kumar J, et al. Retinal manifestations in patients with SARS-CoV-2 infection and pathogenetic implications: a systematic review. *Int Ophthalmol*. 2022;42(1):323–336. doi:10.1007/s10792-021-01996-7
106. Au SCL, Ko CKL. Central retinal artery occlusion in patients with COVID-19: imaging for underlying causes. *Radiology*. 2021;300(1):E315. doi:10.1148/radiol.2021210479
107. Al-Moujahed A, Boucher N, Fernando R, et al. Incidence of retinal artery and vein occlusions during the COVID-19 pandemic. *Ophthalmic Surg Lasers Imaging Retina*. 2022;53(1):22–30. doi:10.3928/23258160-20211209-01
108. Modjtahedi BS, Do D, Luong TQ, et al. Changes in the incidence of retinal vascular occlusions after COVID-19 diagnosis. *JAMA Ophthalmol*. 2022;140(5):523–527. doi:10.1001/jamaophthalmol.2022.0632
109. Yeo S, Kim H, Lee J, et al. Retinal vascular occlusions in COVID-19 infection and vaccination: a literature review. *Graefes Arch Clin Exp Ophthalmol*. 2023;261(7):1793–1808. doi:10.1007/s00417-022-05953-7
110. Au SCL. Central retinal artery occlusion in COVID-19. *Indian J Ophthalmol*. 2021;69(10):2905–2906. doi:10.4103/ijo.IJO\_1803\_21
111. Yeung M, Su CK, Au SCL. Vaccine-related retinal artery occlusion in adults: a review of the current literature. *J Stroke Cerebrovasc Dis*. 2023;32(11):106694. doi:10.1016/j.jstrokecerebrovasdis.2022.106694
112. Au SCL. The diagnosis of central retinal artery occlusion after mRNA-SARS-CoV-2 vaccination. *QJM*. 2022;115(12):880–881. doi:10.1093/qjmed/hcac011
113. Patel R, Kaki M, Potluri VS, et al. A comprehensive review of SARS-CoV-2 vaccines: pfizer, moderna & johnson & johnson. *Hum Vaccin Immunother*. 2022;18(1):2002083. doi:10.1080/21645515.2021.2002083
114. Chiabo J, Kauert A, Casolla B, et al. Efficacy and safety of hyperbaric oxygen therapy monitored by fluorescein angiography in patients with retinal artery occlusion. *Br J Ophthalmol*. 2023. doi:10.1136/bjo-2023-323972
115. St Peter D, Na D, Sethuraman K, et al. Hyperbaric oxygen therapy for central retinal artery occlusion: visual acuity and time to treatment. *Undersea Hyperb Med*. 2023;50(3):253–264.
116. Wu X, Chen S, Li S, et al. Oxygen therapy in patients with retinal artery occlusion: a meta-analysis. *PLoS One*. 2018;13(8):e0202154. doi:10.1371/journal.pone.0202154
117. Celebi ARC. Hyperbaric oxygen therapy for central retinal artery occlusion: patient selection and perspectives. *Clin Ophthalmol*. 2021;15:3443–3457. doi:10.2147/OPTH.S224192
118. Au SCL. The hyperbaric oxygen therapy protocol in acute central retinal artery occlusion seen within 24 hours at a tertiary institution. *J Stroke Cerebrovasc Dis*. 2021;30(11):106044. doi:10.1016/j.jstrokecerebrovasdis.2021.106044
119. Murphy-Lavoie H, Butler F, Hagan C. Central retinal artery occlusion treated with oxygen: a literature review and treatment algorithm. *Undersea Hyperb Med*. 2012;39(5):943–953.
120. Butler FK, Hagan C, Van Hoesen K, et al. Management of central retinal artery occlusion following successful hyperbaric oxygen therapy: case report. *Undersea Hyperb Med*. 2018;45(1):101–107.
121. Mori K, Ohta K, Nagano S, et al. A case of ophthalmic artery obstruction following autologous fat injection in the glabellar area. *Nippon Ganka Gakkai Zasshi*. 2007;111(1):22–25.
122. Yan Y, Zhang X, An X, et al. The application and perspective of hyperbaric oxygen therapy in acute ischemic stroke: from the bench to a starter? *Front Neurol*. 2022;13:928802. doi:10.3389/fneur.2022.928802
123. Bennett MH, Weibel S, Wasiaik J, et al. Hyperbaric oxygen therapy for acute ischaemic stroke. *Cochrane Database Syst Rev*. 2014;2014(11):CD004954. doi:10.1002/14651858.CD004954.pub3
124. Powers WJ, Rabinstein AA, Ackerson T, et al. Guidelines for the early management of patients with acute ischemic stroke: 2019 update to the 2018 guidelines for the early management of acute ischemic stroke: a guideline for healthcare professionals from the American heart association/American stroke association. *Stroke*. 2019;50(12):e344–e418. doi:10.1161/STR.0000000000000211

## Eye and Brain

Dovepress

### Publish your work in this journal

Eye and Brain is an international, peer-reviewed, open access journal focusing on clinical and experimental research in the field of neuro-ophthalmology. All aspects of patient care are addressed within the journal as well as basic research. Papers covering original research, basic science, clinical and epidemiological studies, reviews and evaluations, guidelines, expert opinion and commentary, case reports and extended reports are welcome. The manuscript management system is completely online and includes a very quick and fair peer-review system, which is all easy to use. Visit <http://www.dovepress.com/testimonials.php> to read real quotes from published authors.

Submit your manuscript here: <https://www.dovepress.com/eye-and-brain-journal>