

Pigmentary Glaucoma with Retinochoroidal Pigmentation

Syed Shoeb Ahmad, MS, FAEH, FCLI; Shuaibah Abdul Ghani, MD

Department of Ophthalmology, Queen Elizabeth Hospital, Kota Kinabalu, Malaysia

J Ophthalmic Vis Res 2016; 11 (1): 120-123.

PRESENTATION

Pigmentary glaucoma (PG) is considered as an entity within the spectrum of secondary open angle glaucomas. The condition usually starts in the third or fourth decades of life with disruption of the iris pigment epithelium. The released pigment granules deposit on anterior segment structures such as the corneal endothelium, trabecular meshwork and lens/zonules. This stage is known as primary pigment dispersion syndrome (PPDS). Genetic studies have shown it to be an autosomal dominant disorder with incomplete penetrance. A susceptibility locus for PPDS has also been identified on chromosome 7q35-q36.^[1,2] Over a period of time, intraocular pressure (IOP) may increase due to progressive trabecular meshwork dysfunction, which may manifest as ocular hypertension or lead to PG. The probability of PPDS converting to PG is reported to be 10% at 5 years and 15% after 15 years of diagnosis.^[3] Sivaraman et al have cited the probability of progression from PPDS to PG at 10-50%.^[4]

Significant diagnostic signs for PPDS/PG are limited to the anterior segment. The classic triad of PPDS is the presence of Krukenberg spindles (KS), transillumination

iris defects (TID), and trabecular pigmentation.^[2,5-8] Qing et al reported the clinical characteristics of PG in Chinese patients and stated that TID is rare in that ethnic group, a finding which is corroborated by our case report.^[9]

A 54-year-old gentleman of Chinese origin was first seen at the ophthalmology clinic of Queen Elizabeth Hospital, Malaysia for painless, progressive blurring of vision in both eyes since a few months ago. There was no history of red eye, trauma, itching or any medication use. Medical and surgical history was unremarkable and no significant family history could be elicited.

On examination, uncorrected visual acuity was 6/9 in both eyes; corrected to 6/6 with -1.00 D sphere in the right eye and -1.50 D sphere in the left eye. In both eyes, the cornea had prominent KS [Figure 1a and b] and extensive pigment deposition on the anterior and posterior lens capsules [Figure 2a and b]. Fundus examination revealed cup/disc ratio of 0.8 in right eye and 0.9 in left eye [Figures 3 and 4]. Bilaterally, the retinal periphery showed extensive areas of pigmentary changes [Figures 5 and 6]. IOP was 30 mmHg in the right eye and 34 mmHg in the left eye. Gonioscopic examination showed open angles with extensive pigment deposition in both eyes [Figures 7 and 8]. Optical coherence tomography of the retinal nerve fiber layer is shown in Figure 9. A diagnosis of bilateral PG was entertained, and the patient was started on Timolol 0.5% twice daily in both eyes. One week later, IOP was 16mmHg in both eyes and he was advised to continue Timolol 0.5% twice daily in both eyes.

Correspondence to:

Syed Shoeb Ahmad MS, FAEH, FCLI.
Department of Ophthalmology, Queen Elizabeth Hospital,
Kota Kinabalu 88586, Malaysia.
E-mail: syedshoebahmad@yahoo.com

Received: 08-05-2014

Accepted: 26-09-2014

Access this article online

Quick Response Code:



Website:
www.jovr.org

DOI:
10.4103/2008-322X.180710

This is an open access article distributed under the terms of the Creative Commons Attribution-NonCommercial-ShareAlike 3.0 License, which allows others to remix, tweak, and build upon the work non-commercially, as long as the author is credited and the new creations are licensed under the identical terms.

For reprints contact: reprints@medknow.com

How to cite this article: Ahmad SS, Ghani SA. Pigmentary glaucoma with retinochoroidal pigmentation. *J Ophthalmic Vis Res* 2016;11:120-3.

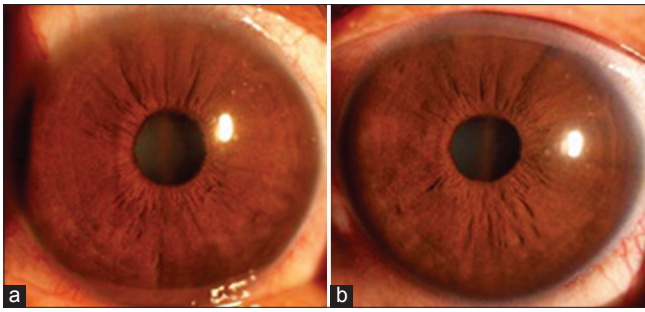


Figure 1. (a and b): Slit lamp images of the patient demonstrate Krukenberg spindles in right (a) and left (b) eyes.

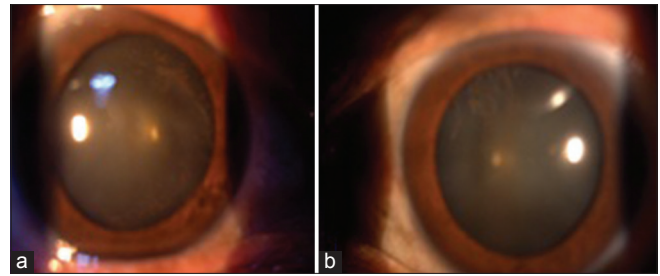


Figure 2. (a and b): Slit lamp image shows pigment deposition on the lens capsules in both eyes.

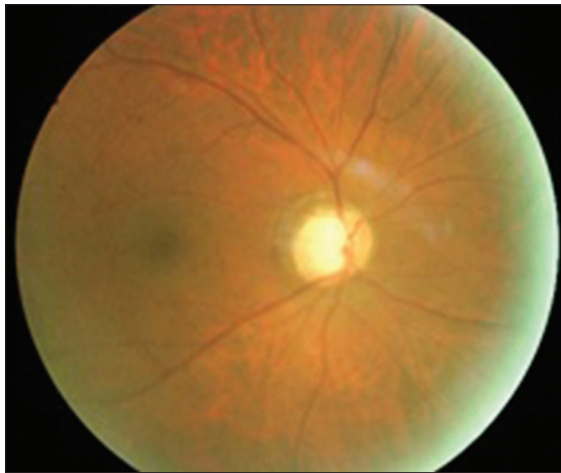


Figure 3. Fundus photograph of the right eye, note the glaucomatous cupping.

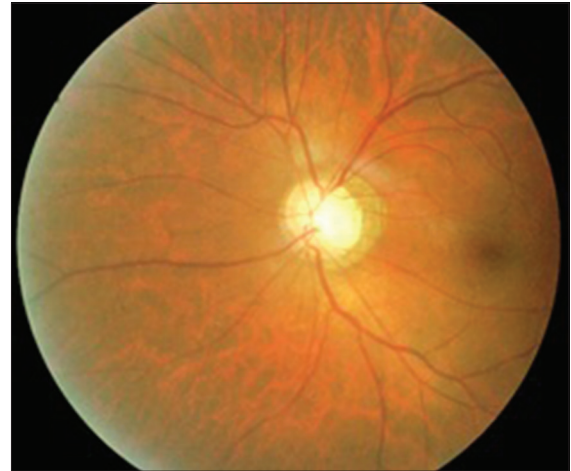

Figure 4. Fundus photograph of the left eye.

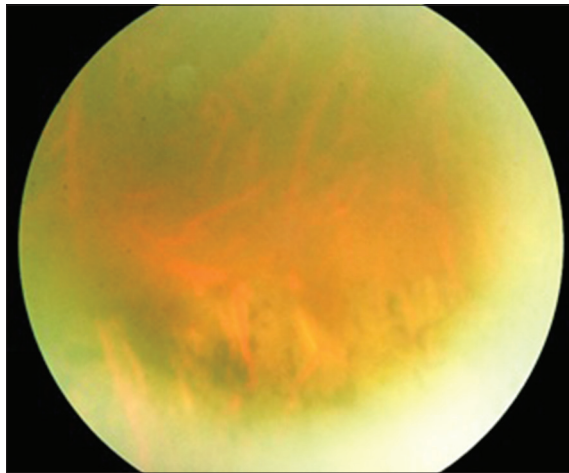


Figure 5. Retinal pigmentation in the periphery of the right eye.

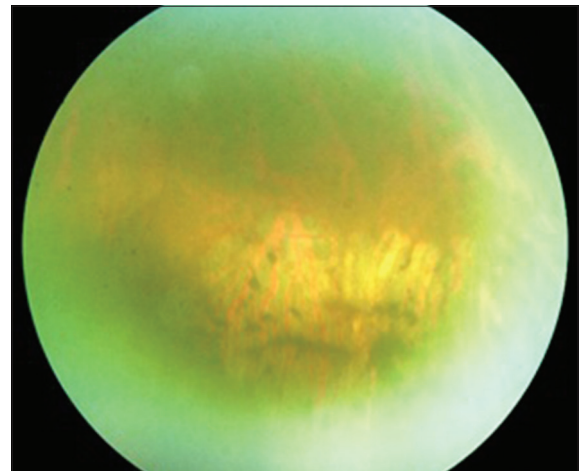


Figure 6. Retinal pigmentation in the periphery of the left eye.

DISCUSSION

Pigment dispersion in the eye could be part of the natural process of aging. The infant eye, especially the trabecular meshwork, is non-pigmented. However, with aging, various grades of pigmentation might become visible.^[10] Anterior segment pigment deposition in PPDS and PG has been widely reported in the literature, but pigment

deposition in the retinal periphery has not been reported so far.

In most cases, pigment dispersion is innocuous and does not cause any pathological changes in the eye. This condition, known as PPDS, is characterized by pigment deposition throughout the anterior segment. This can manifest as a KS, which is a vertically oriented line of pigment deposits on the corneal endothelium secondary to aqueous convection currents in the nasal and temporal halves of the anterior chamber.^[2,11,12] KS is more common

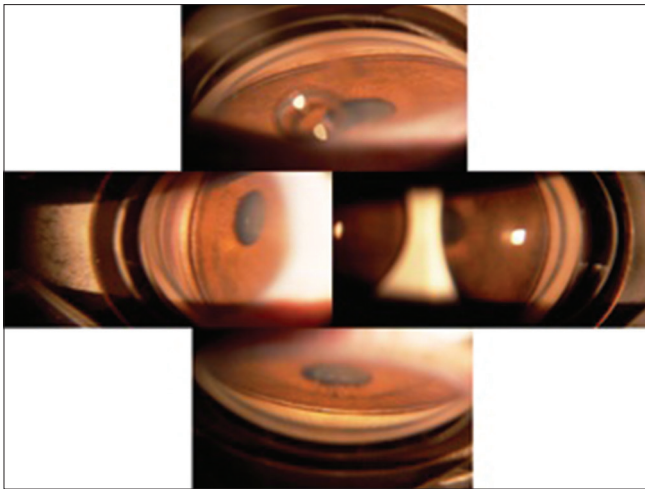


Figure 7. Gonioscopic appearance of the right eye, note the angle hyperpigmentation.

in females, suggesting a hormonal influence,^[13] and the presence of KS is associated with higher rate of conversion to glaucoma.^[6] Our patient had extensive pigment deposition on the corneal endothelium in the form of KS, on the anterior and posterior lens capsules, and in the angles bilaterally.

Pigment can also be deposited on the anterior iris surface, lens zonules and the anterior or posterior lens capsules. Accumulation of pigment may occur at the junction of zonules and posterior lens capsule, or medial to Wieger's ligament, which are called Zentmayer Ring and Scheie stripe, respectively.^[14-16]

Angle pigmentation is seen circumferentially, homogeneously or irregularly, and is more prominent in the inferior trabecular meshwork due to gravity. The pigment can be deposited at Schwalbe's line, producing a thin dark band resembling Sampaolesi's line seen in pseudoexfoliation syndrome. In asymmetric cases, glaucoma is found to be more severe in the eye with a greater degree of pigment dispersion and trabecular pigmentation.^[14,16]

Posterior segment changes reported in PPDS include lattice degeneration, retinal breaks, and retinal detachment. Scheie reported retinal detachment in 6.4% of patients diagnosed with PPDS; while, in Weseley's study, 20% of patients with PPDS had lattice degeneration, 11.7% had full thickness retinal breaks, and 3.3% had rhegmatogenous retinal detachments which required scleral buckling.^[7,17] Scuderi et al also reported retinoschisis, lattice degeneration and retinal detachment as the only retinal changes in PPDS.^[18] Similarly, Lehto and Vesti has reported lattice degeneration in 33.3% eyes with PPDS.^[19]

The peripheral pigmentary changes in our patient are unusual but quite plausible. It may be conjectured that the pigmentation seen in the posterior segment are in fact pigment granules which might have traveled by convection currents to those sites due to a more fluid




Figure 8. Gonioscopic appearance of the left eye.

vitreous in these myopic patients. Thus, this pigment may have deposited on the retina similar to the pigment deposition seen on the cornea, angles, and lens capsules. In another case report, Nagarajah and Shun-Shin stated that the presence of Scheie's line in PPDS demonstrates some flow of pigment from the anterior to the posterior chamber.^[20]

Chew and Deutman presented a case of PPDS associated with pigmented pattern dystrophy of the retinal pigment epithelium (RPE) at the macula. Such involvement of the iris and RPE has been explained on the basis of their common embryologic origin from the neural crest. The condition was assumed to represent a generalized congenital or degenerative disorder of pigment cells in the eye.^[21] Piccolino et al have reported two brothers diagnosed with PG and widespread salt-and-pepper RPE mottling and pigment clumping. According to the authors, an inherited defect in the pigment epithelium could be responsible for the changes seen in both the anterior and posterior segments.^[22]

Scuderi et al and also Greenstein et al have studied electrooculograms from patients with PPDS and PG and found mean Arden ratios for this group to be significantly lower than normal controls as well as patients with ocular hypertension or primary open angle glaucoma. These studies seem to support the hypothesis that integrity of the RPE/photoreceptor complex is affected in patients with PPDS/PG.^[23,24]

Management of PG is similar to other primary open angle glaucomas. Miotics may reduce irido-zonular contact and facilitate aqueous outflow; however, they may exacerbate myopia. Laser trabeculoplasty, laser iridotomy, and trabeculectomy might be performed as required. The prognosis for such patients is usually good with a reduction of IOP either with medical treatment or spontaneously over time.

In summary, although pigmentation of the anterior segment in PG has widely been reported, we are

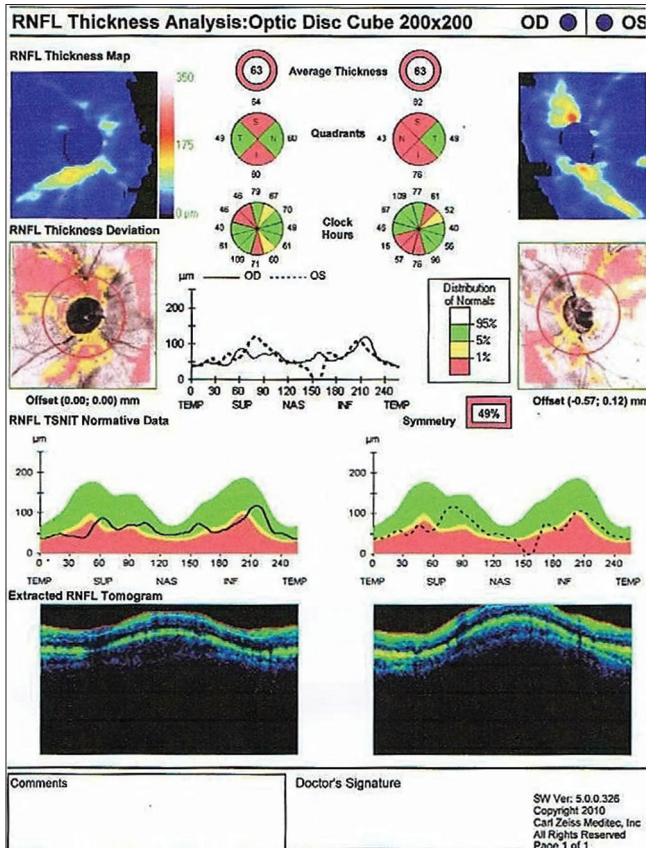


Figure 9. Retinal nerve fiber layer thickness, determined by optical coherence tomography.

unaware of any report documenting pigmentation of the peripheral retina. This could be due to movement of iris pigment granules to the posterior segment or a primary disorder of the retinal pigmentary epithelium.

Financial Support and Sponsorship

Nil.

Conflicts of Interest

There are no conflicts of interest.

REFERENCES

- Giardina E, Oddone F, Lepre T, Centofanti M, Peconi C, Tanga L, et al. Common sequence variants in the LOXL1 gene in pigment dispersion syndrome and pigmentary glaucoma. *BMC Ophthalmol* 2014;14:52.
- Joos KM, Richter CU. Pigmentary dispersion and pigmentary glaucoma. In: Higginbotham EJ, Lee DA, editors. *Clinical Guide to Glaucoma Management*. 1st ed. USA: Butterworth-Heinemann; 2004. p. 192-198.
- Siddiqui Y, Ten Hulzen RD, Cameron JD, Hodge DO, Johnson DH.

- What is the risk of developing pigmentary glaucoma from pigment dispersion syndrome? *Am J Ophthalmol* 2003;135:794-799.
- Sivaraman KR, Patel CG, Vajaranant TS, Aref AA. Secondary pigmentary glaucoma in patients with underlying primary pigment dispersion syndrome. *Clin Ophthalmol* 2013;7:561-566.
- Lascaratos G, Shah A, Garway-Heath DF. The genetics of pigment dispersion syndrome and pigmentary glaucoma. *Surv Ophthalmol* 2013;58:164-175.
- Farrar SM, Shields MB. Current concepts in pigmentary glaucoma. *Surv Ophthalmol* 1993;37:233-252.
- Scheie HG, Cameron JD. Pigment dispersion syndrome: A clinical study. *Br J Ophthalmol* 1981;65:264-269.
- Ritch R. A unification hypothesis of pigment dispersion syndrome. *Trans Am Ophthalmol Soc* 1996;94:381-405.
- Qing G, Wang N, Tang X, Zhang S, Chen H. Clinical characteristics of pigment dispersion syndrome in Chinese patients. *Eye (Lond)* 2009;23:1641-1646.
- Shields MB. Glaucomas associated with disorders of the iris and ciliary body. In: *Textbook of Glaucoma*. 4th ed. India: Williams and Wilkins; 1998. p. 241-251.
- Niyadurupola N, Broadway DC. Pigment dispersion syndrome and pigmentary glaucoma – A major review. *Clin Experiment Ophthalmol* 2008;36:868-882.
- Ball SF. Pigmentary glaucoma. In: Yanoff M, Duker JS, editors. *Ophthalmology*. St. Louis: Mosby; 2004. p. 1504-1507.
- Duncan TE. Krukenberg spindles in pregnancy. *Arch Ophthalmol* 1974;91:355-358.
- Singh K. Secondary glaucoma. In: Saxena S, editor. *Clinical Ophthalmology: Medical and Surgical Approach*. 2nd ed. India: Jaypee Medical Publishers (P) Ltd.; 2011. p. 191-193.
- Eye Net Magazine, American Academy of Ophthalmology, United States of America. Available from: <http://www.aaopt.org/publications/eyenet/200901/pearls.cfm>. [Last accessed on 2014 Sep 17].
- Sowka J. Pigment dispersion syndrome and pigmentary glaucoma. *Optometry* 2004;75:115-122.
- Wesley P, Liebmann J, Walsh JB, Ritch R. Lattice degeneration of the retina and the pigment dispersion syndrome. *Am J Ophthalmol* 1992;114:539-543.
- Scuderi G, Papale A, Nucci C, Cerulli L. Retinal involvement in pigment dispersion syndrome. *Int Ophthalmol* 1995-1996;19:375-378.
- Lehto I, Vesti E. Diagnosis and management of pigmentary glaucoma. *Curr Opin Ophthalmol* 1998;9:61-64.
- Nagarajaiah S, Shun-Shin GA. Pigment deposition on the central aspect of the posterior lens capsule in pigmentary dispersion. *Digit J Ophthalmol* 2011;17:69-71.
- Chew EY, Deutman AF. Pigment dispersion syndrome and pigmented pattern dystrophy of retinal pigment epithelium. *Br J Ophthalmol* 1983;67:538-541.
- Piccolino FC, Calabria G, Polizzi A, Fioretto M. Pigmentary retinal dystrophy associated with pigmentary glaucoma. *Graefes Arch Clin Exp Ophthalmol* 1989;27:335-339.
- Scuderi GL, Ricci F, Nucci C, Galasso MJ, Cerulli L. Electro-oculography in pigment dispersion syndrome. *Ophthalmic Res* 1998;30:23-29.
- Greenstein VC, Seiple W, Liebmann J, Ritch R. Retinal pigment epithelial dysfunction in patients with pigment dispersion syndrome: Implications for the theory of pathogenesis. *Arch Ophthalmol* 2001;119:1291-1295.