



Clopidogrel-induced liver failure

Patrícia Howell Monteiro • Luís dos Santos Pinheiro •
Lourdes Alvoeiro • Margarida Lucas • Rui MM Victorino

Serviço de Medicina 2/Clínica Universitária de Medicina 2 – Hospital de Santa Maria/Faculdade de Medicina de Lisboa, Lisbon, Portugal

Correspondence to: Patrícia Howell Monteiro. Email: patriciahowell78@gmail.com

DECLARATIONS

Competing interests

None declared

Funding

None

Ethical approval

Written consent to publication has been obtained from the patient or next of kin

Guarantor

PHM

Contributorship

PHM, LSP, LA, ML, RMMV conducted the manuscript elaboration and review; PHM reviewed the literature

Acknowledgements

None

Reviewer

David Wood

Hepatotoxicity is a rare adverse reaction to clopidogrel that can evolve to fulminant hepatitis if the drug is not discontinued.

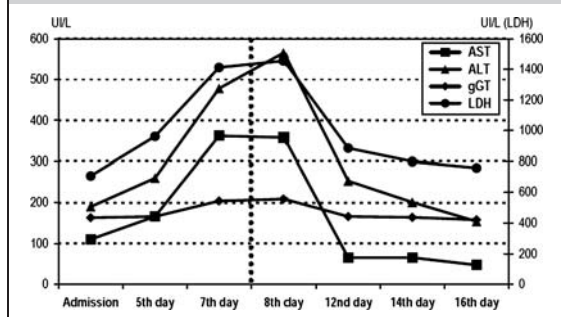
Case report

The thienopyridine derivative clopidogrel (CPG) inhibits ADP-induced platelet activation. It is rapidly hydrolysed in the liver via cytochrome P450 enzymes, by an irreversible and NADPH-dependent mechanism. Clopidogrel therapy is indicated in the prevention of thrombotic events in patients with acute coronary syndromes, ischemic stroke and peripheral arterial disease or after percutaneous stent placement.¹ Currently, it is widely used with a low occurrence of adverse side-effects.² Hepatotoxicity is extremely rare. There are 10 cases of pure liver injury reported in the literature,^{3–7} with liver failure in only one,³ and in two, liver injury was part of a systemic inflammatory response syndrome.^{8,9} We report here the second case of clopidogrel-associated hepatitis with acute liver failure.

An 80-year-old woman with history of hypertension, type 2 diabetes, heart failure and dyslipidaemia was on glibenclamide, furosemide, isosorbide dinitrate, acetylsalicylic acid and simvastatin for several years with no evidence of adverse effects. More recently clopidogrel was introduced following angioplasty and stent placement for treatment of acute myocardial infarction. The patient was not taking any over-the-counter, herbal or alternative medicines. Thirty days after starting clopidogrel she was admitted to the hospital with a one-week history of dyspnoea, orthopnoea, lower limb

oedema, nausea and vomiting. Physical exam revealed inspiratory rales and ankle oedema. Laboratory evaluation yielded the following abnormal values: AST 110 U/L (normal range [NR] 0–31 U/L); ALT 190 U/L (NR 0–31 U/L); total serum bilirubin 1.7 mg/dL (NR 0.1–1.1 mg/dL); direct serum bilirubin 0.7 mg/dL (NR 0–0.3 mg/dL), γ -glutamyltransferase 166 U/L (NR 5–36 U/L); lactate dehydrogenase 707 U/L (NR 240–480 U/L). Serum albumin levels and coagulation profile were normal. Therapy for congestive heart failure was optimized with resolution of the oedema and pulmonary stasis. Despite the improvement of heart failure, there was worsening of liver biochemical tests with AST 388 U/L; ALT 540 U/L; total serum bilirubin 3.5 mg/dL; γ -glutamyltransferase 209 U/L; alkaline phosphatase 139 U/L (NR 35–100 U/L) and lactate dehydrogenase 1412 U/L and development of liver failure as shown by increased prothrombin time (INR 1.6) and low levels of factor V (4%, NR >5%). Clopidogrel was then stopped. Serology for acute viral hepatitis was negative and there was no history of alcohol intake. Blood and urine cultures were also negative. Autoimmune hepatitis was excluded based on negative antinuclear, anti-neutrophil cytoplasmic, anti-mitochondria and anti-smooth muscle antibodies. The abdominal ultrasound and endoscopic retrograde cholangiopancreatography showed no abnormalities. Drug-induced liver disease with an hepatocellular pattern was therefore diagnosed and clopidogrel was considered the most probable causative drug given the close temporal relationship between therapy initiation and liver injury, exclusion of alternative causes and liver function/biochemical

Figure 1
Evolution of liver tests during hospitalization, before and after clopidogrel discontinuation (vertical dotted line)



tests normalization 29 days after drug discontinuation (Figure 1). Importantly, all the other drugs were taken continuously for several years with no record of adverse effects and moreover liver biochemical tests were normal at the time of clopidogrel initiation. The Clinical Diagnostic Scale for Drug Induced Hepatotoxicity¹⁰ was applied and revealed a high probability diagnosis (score 16). Despite the severity of the hepatic injury with signs of liver failure, biopsy was not performed as clopidogrel was the only imputable drug and in view of the rapid improvement of liver biochemistry after clopidogrel withdrawal. Re-exposition to the drug was not performed for ethical reasons.

Discussion

Clopidogrel is a widely used inhibitor of platelet aggregation associated with a low occurrence of adverse side-effects. The most frequent side-effects, detected in clinical studies and during the post commercialization experience, are haemorrhage, diarrhoea, abdominal pain and dyspepsia.² Hepatitis and acute liver dysfunction associated with clopidogrel are extremely rare considering the widespread use of this drug worldwide. The mechanism of clopidogrel hepatotoxicity is still unclear but is more likely to be non-dose-dependent, either by an hypersensitivity immunological mechanism or by a metabolic idiosyncratic process dependent upon individual susceptibility.

The diagnosis of clopidogrel-associated hepatitis in the present case is strongly supported by

the close temporal relationship between therapy initiation and liver injury, exclusion of alternative causes, liver function normalization after drug discontinuation and a high probability diagnosis in a previously validated scale.¹⁰

Only 12 cases of clopidogrel hepatotoxicity are described in the literature.^{3–9} These include eight men and four women, aged 56–89 years old, that developed liver injury 4 days to 6 months after clopidogrel intake. The pattern of liver injury was mainly mixed hepatocellular-cholestatic, but hepatocellular liver injury and systemic inflammatory response syndrome with hepatic injury were also observed. Our case has the particularity of exhibiting liver failure documented by factor V and prothrombin time alterations at the peak of cytolytic lesion, in contrast with all cases published before 2009. Interestingly, a recent case of clopidogrel liver injury with liver failure and fatal outcome was published.³

Considering the widespread use of clopidogrel, namely with new therapeutical targets, it is important to promote increased awareness of clinicians for this rare adverse liver reaction that can, in extremely rare cases, evolve to fulminant hepatitis if the drug is not discontinued at early stages of liver injury.

References

- 1 Jarvis B, Simpson K. Clopidogrel: a review of its use in the prevention of atherothrombosis. *Drugs* 2000;**60**:347–77
- 2 CAPRIE Steering Committee. A randomized, blinded, trial of clopidogrel versus aspirin in patients at risk of ischaemic events (CAPRIE). *Lancet* 1996;**348**:1329–39
- 3 Kastalli S, Ar'idi S, Zaiem A, Abdallah H, Daghfous R. Fatal liver injury associated with clopidogrel. *Fundam Clin Pharmacol* 2010;**24**:433–5
- 4 Goyal RK, Srivastava D, Lessnau KD. Clopidogrel-induced hepatocellular injury and cholestatic jaundice in an elderly patient: case report and review of the literature. *Pharmacotherapy* 2009;**29**:608–12
- 5 Wiper A, Schmitt M, Roberts DH. Clopidogrel-induced hepatotoxicity. *J Postgrad Med* 2008;**54**:152
- 6 Höllmüller I, Stadlmann S, Graziadei I, Vogel W. Clinico-histopathological characteristics of clopidogrel-induced hepatic injury: case report review of the literature. *Eur J Gastroenterology Hepatol* 2006;**18**:931–4
- 7 Chau TN, Yim KE, Mok NS et al. Clopidogrel-induced hepatotoxicity after percutaneous coronary stenting. *Hong Kong Med J* 2005;**11**:414–16
- 8 López-Vicente J, Garfía C, López-Medrano F, Yela C. Hepatic toxicity and clopidogrel-induced systemic inflammatory response syndrome. *Rev Esp Cardiol* 2007;**60**:323–4

- 9 Wolf I, Mouallen M, Rath S, Farfel Z. Clopidogrel-induced systemic inflammatory response syndrome. *Mayo Clin Proc* 2003;**78**:618–20
- 10 Maria VA, Victorino RM. Development and validation of a clinical scale for the diagnosis of drug-induced hepatitis. *Hepatology* 1997;**26**:664–9

© 2011 Royal Society of Medicine Press

This is an open-access article distributed under the terms of the Creative Commons Attribution License (<http://creativecommons.org/licenses/by-nc/2.0/>), which permits non-commercial use, distribution and reproduction in any medium, provided the original work is properly cited.