

# Classification and management of mild head trauma

Almir F Andrade  
Wellingson S Paiva  
Matheus S Soares  
Robson LO De Amorim  
Wagner M Tavares  
Manoel J Teixeira

Division of Neurosurgery, Hospital  
Das Clínicas University of Sao Paulo  
Medical School, Sao Paulo, Brazil

**Abstract:** Mild head trauma had been defined in patients with direct impact or deceleration effect admitted with a Glasgow Coma Scale score of 13–15. It is one of the most frequent causes of morbidity in emergency medicine. Although common, several controversies persist about its clinical management. In this paper, we describe the Brazilian guidelines for mild head trauma, based on a critical review of the relevant literature.

**Keywords:** head trauma, craniocerebral injuries, minor head injury, classification, management

## Introduction

Mild head trauma scoring 13–15 on the Glasgow Coma Scale (GCS)<sup>1</sup> cannot be neglected. This is a very common situation that may lead to severe morbidity or even mortality, depending on the history of the trauma, the patient's previous health status, and physical and neurological examination during hospital attendance.

Mild head trauma is caused by direct head impact or by an encephalic deceleration effect that produces a period of temporal and spatial disorientation, post-traumatic amnesia, or unconsciousness for up to 20 minutes.<sup>1–3</sup> Patients are admitted to the emergency room with a GCS score of 13–15, usually without focal neurological lesions.<sup>1,2,4–6</sup>

Dacey et al<sup>7</sup> estimate that 300,000–325,000 patients in the US need medical treatment due to mild head trauma each year, which represents 80% of all head trauma patients admitted to American hospitals. Between 52% and 72% of these patients need to stay in hospital for observation or specific treatment.<sup>8,9</sup> However, these figures are underestimated, because a large number of patients with mild head trauma do not seek medical attention, given the apparent trivial nature of the symptoms.

In 1981, Rimel et al<sup>10</sup> found a 35% increase in blood alcohol levels in patients admitted with mild head trauma (scoring 13–15 on the GCS). High levels of alcohol in the blood make it harder to diagnose head trauma, because of alterations in consciousness caused by alcohol that are independent of the severity of head trauma. Almost all patients show a significant decrease in GCS score when the concentration of alcohol in the blood is higher than 200 mL/dL.<sup>10,11</sup> Therefore, the initial assessment of such patients is difficult, and their first GCS scores need to be reconsidered by doctors. In this study, the authors review the classification and management of patients with mild head injury, and present the guidelines adopted by the Brazilian Neurosurgery Society and Brazilian Medical Association.

Correspondence: Wellingson Silva Paiva  
Alves Guimaraes Street 470 Apt 93,  
Sao Paulo Sp Brasil Cep 05403-000  
Email wellingsonpaiva@yahoo.com.br

## Trauma classification and management

A significant number of patients initially classified as having mild head trauma may have memory or neuropsychological disorders, or even severe headaches, which can lead to social dysfunction and loss of productivity, especially related to work.<sup>12</sup> They may also need neurosurgical intervention, and failure to make the correct diagnosis might have fatal consequences.

When dealing with patients suffering from mild head trauma, an ideal classification scale should establish which patients, even when neurological examinations are normal, may have an increased risk of intracranial hematomas or a negative progression such as “talk and deteriorate” or “talk and die”.<sup>4,12–16</sup>

Based on evidence in the literature and regional characteristics in our country, we classified mild head trauma using the GCS, as well as signs and symptoms during admission, into low-risk, medium-risk, and high-risk.

Figure 1 shows the flow chart for management of low-risk mild head trauma (GCS 15), which is divided into three groups. Group 1 consists of patients with low intensity head trauma, who are totally asymptomatic, with a normal physical and neurological examination, and who could be assisted by a general practitioner and sent for a simple skull X-ray according to medical criteria. If this is normal, the patient then receives medical orientation and is subsequently discharged. Group 2 consists of patients with mild head trauma and symptoms, including nonprogressive headache, dizziness, or temporary amnesia. These patients might be

submitted for a simple skull X-ray. If this is normal and the patient becomes asymptomatic, they receive specific orientation and are then discharged. In case of a normal examination with persistence of symptoms, the patient may stay under medical observation and undergo an encephalic computed tomography (CT) scan. Group 3 includes patients who show signs of fracture on X-ray. These patients need to undergo a CT scan. If this is normal, they can be discharged after 12 hours of observation. Patients with a CT scan showing intracranial air, traumatic subarachnoid hemorrhage, or intracranial hematoma need to stay in hospital and receive specific treatment for moderate head trauma.<sup>1,2</sup>

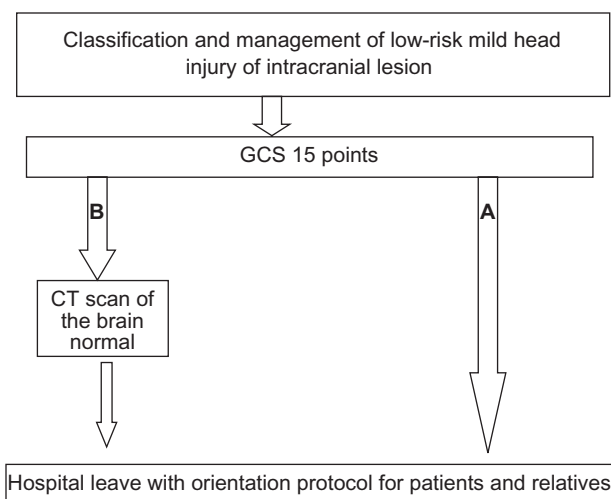
The literature shows an incidence of skull fractures in patients with low-risk mild head trauma of only 0.4%, and none of them developed intracranial hematomas.<sup>17</sup>

Patients who show any of the following findings can be classified as medium-risk mild head trauma:

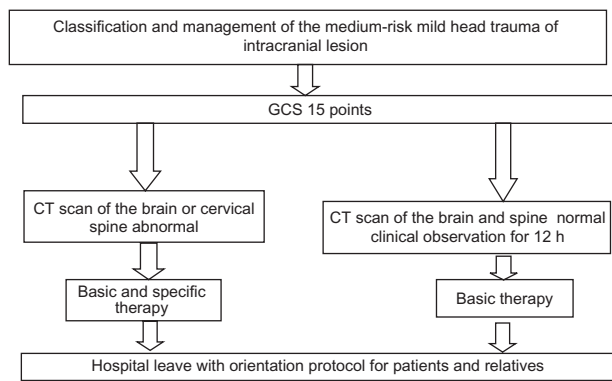
- Medical history of complex trauma with moderate kinetic energy, child battery, involvement in a severe accident, alcohol or drug intoxication, progressive headache, vomiting, convulsions, or transient loss of consciousness
- General physical examination findings of periorbital or postauricular ecchymosis (Battle’s sign), major scalp lesions, multiple body trauma, penetrating head trauma, severe facial lesions, or anosmia
- Neurological/neuropsychological findings of temporal and spatial disorientation, amnesia, memory disorder, and behavioral/attention or concentration disorders.<sup>15</sup>

Patients with medium-risk mild head trauma show a 4.2% incidence of skull fractures and a 4% incidence of intracranial lesions.<sup>18</sup> Therefore, these patients need to undergo a CT scan of their head and an X-ray of the cervical spine. If all examinations are normal, the patient receives specific orientation and is discharged after 12 hours of medical observation, provided he or she has become asymptomatic. If the examinations are not normal, the patient stays in hospital and is given care according to what is established by the protocol for management of medium-risk mild head trauma (Figure 2).<sup>1,2,18</sup>

Patients scoring 13 or 14 on GCS, or those who score 15 and also show a severe trauma mechanism, despite normal general and neurological examination, with loss of consciousness for up to 20 minutes and no intracranial lesions on the CT scan, are classified as patients with high-risk mild head trauma.<sup>19</sup> Other patients classified as high-risk include battered children with a head trauma, hemophiliacs, patients with pre-existing mental disabilities, pregnant women,



**Figure 1** Management of patients with low-risk mild head trauma. **A)** Asymptomatic patients. **B)** Patients with minor clinical symptoms.



**Figure 2** Management of medium-risk mild head trauma. All patients must undergo a computed tomography scan of the brain.

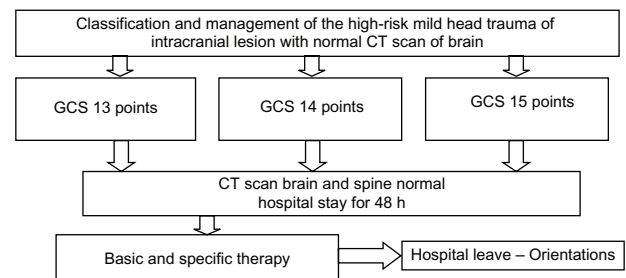
those with coagulation disorders, and those with visual deficit or signs of cerebrospinal fluid leak. All of these patients need a CT head scan and a cervical spinal X-ray, or even a spinal CT scan. Even if these examinations are normal, the patient should stay under medical observation for 48 hours. Even though the patient’s condition may progress to “talk and deteriorate” or “talk and die”, they usually show gradual improvement when they receive specific orientation, and are discharged after 48 hours of observation (Figures 3 and 4). According to Masters et al, these patients show skull fractures in 21.5% of cases, in addition to a 29% incidence of intracranial lesions.<sup>17</sup> In our service, we applied this protocol when attending 112 patients with mild traumatic brain injury, and found a patient with a head injury and a score of 15 on GCS as well as a case of epidural hematoma, in whom a CT scan would always be performed using this protocol.

In contrast, Mendelow et al<sup>18</sup> report that patients with a skull fracture and alteration of consciousness have a 25% chance of developing intracranial hematoma, and the incidence of such lesions in patients without a skull fracture is one in every 6000 persons.

### Mild head trauma and CT scan

Smits et al<sup>20</sup> described a CT scan protocol for head trauma based on an evaluation of 3181 patients. Pre-existing protocols based on signs and symptoms were used, and a high sensitivity and specificity for surgical and nonsurgical intracranial lesions were subsequently found. Therefore, the use of patients’ signs and symptoms as predictors of such lesions showed a high sensitivity and specificity.<sup>20</sup>

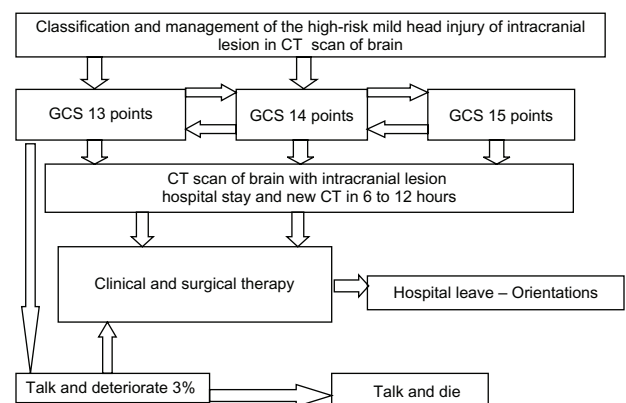
Patients who scored 15 on GCS, and were either sent for immediate CT scan or only stayed under medical observation, progress similarly. However, the early CT scan is the best



**Figure 3** Patients with high-risk mild head trauma and normal first computed tomography scan of the brain.

cost-benefit strategy, because when this is normal during the patient’s admission, it suggests a good prognosis without neurological complications.<sup>21</sup>

According to Advanced Trauma Life Support®, patients with mild head trauma are awake, but show amnesia for events that happened right before or after the trauma. Almost all patients with mild head trauma make good progress, with occasional, slight neurological alterations. However, about 3% of them may have a sudden deterioration.<sup>22</sup> The ideal practice is to perform a CT scan in all patients who show more than mere temporary unconsciousness, amnesia, or severe headache.<sup>20</sup> If a CT scan is not available and the patient is completely awake and asymptomatic, the patient should stay under medical observation for 12 to 24 hours at the hospital. A study with 658 patients with a history of post-trauma unconsciousness or amnesia revealed an 18% incidence of altered findings on CT scan and a 5% incidence of surgical lesions.<sup>23</sup> Among patients who scored 13 on the GCS, 40% of altered CT scans and 10% of surgical lesions<sup>24</sup> were described, more likely to be moderate head traumas. None of the 542 patients with a normal CT scan on admission showed deterioration or a need for surgery.



**Figure 4** Patients with high-risk mild head injury and intracranial lesion in the first computed tomography scan of the brain.

## Complications

Although mild head trauma has traditionally received less attention than severe head trauma, it represents a significant problem for the neurosurgeon and for emergency room doctors for a number of reasons. First of all, according to Dacey et al,<sup>7</sup> a small yet considerable number of patients with mild head trauma may have fatal complications that require urgent neurosurgical intervention. Also, the great majority of hospitalized head trauma patients have had a mild head trauma, which constitutes one of the most common reasons for hospitalization of post-trauma patients. Moreover, because of its high incidence and the risk of complications in a small proportion of patients, evaluation of those with mild head trauma requires considerable time and expenditure. Finally, some patients show persistent symptoms or neurological deficits that lead to high morbidity.<sup>25</sup> Rimel et al<sup>2</sup> described that 79% of these patients had headaches, 59% of them remained with memory disorders, and 34% were incapable to return to work.

In 1996, while studying the individual relationship between patients admitted with GCS scores of 13, 14, and 15 points and trauma severity, Culotta et al<sup>26</sup> demonstrated that the degree of brain injury and the need for neurosurgical intervention increase significantly with a decrease in the GCS from 15 to 13. Patients with mild head trauma which deteriorates (including death, a persistent vegetative state, and/or severe complications) are related in about 0.2%–3.4% of cases.<sup>27</sup>

With regard to postconcussion syndrome, if it persists, psychological features will entirely account for the symptoms in some individuals, and organic or quasi-organic features will entirely account for symptoms in others. Because the vast majority of patients with uncomplicated mild head injury will not receive extensive investigations, it may be prematurely inferred that organic processes are not present, and therefore psychological processes must be the only, or predominant, cause of the syndrome.<sup>28</sup> Coetzer<sup>29</sup> describes that future research on management could potentially enhance the prevention of chronic symptomatology developing into postconcussion syndrome. This might also explain our understanding of patients in whom postconcussion symptoms persist beyond one year following injury.

## Conclusion

Mild head injury is a very common condition seen in neurosurgery, and represents 80% of all head trauma patients admitted to hospital. Mortality is extremely rare and can be almost completely avoided by early diagnosis and treatment.

Identification of risk factors for an intracranial lesion is important to determine which patients can be assessed and discharged, and which patients should be admitted and investigated. Because patients with mild head trauma are not usually evaluated by neurosurgeons, it is vital that general practitioners and emergency doctors know what factors are reference points to perform adequately with when dealing with mild head trauma.

## Disclosure

The authors report no conflicts of interest in this work.

## References

1. Levin HS. Outcomes from mild head injury. In: Narayan RK, Wilberger JE, Povlishock JT, editors. *Neurotrauma*. New York, NY: McGraw-Hill; 1996.
2. Rimel RW, Giordani B, Barth JT. Moderate head injury: Completing the clinical spectrum of brain trauma. *Neurosurgery*. 1982;11:344–351.
3. Andrade AF, Ciquini O, Figueiredo EG, Brock RS, Marino JR Jr. Diretrizes do atendimento ao paciente com traumatismo craniocéfálico. *Arq Bras Neurocir*. 1999;18:131–176. Spanish.
4. Andrade AF, Marino R Jr, Ciquini O Jr, et al. Guidelines for neurosurgical trauma in Brazil. *World J Surg*. 2001;25:1186–1201.
5. Langfitt TW, Gennarelli TA, Obrist WD. Prospects for the future in the diagnosis and management of head injury: Pathophysiology, brain imaging in population based studies. In: Galbraith JG, editor. *Clinical Neurosurgery*. Baltimore, MD: Williams & Wilkins; 1982.
6. Kelly DF, Doberstein C, Becker DP. General principles of head injury management. In: Narayan RK, Wilberger JE, Povlishock JT, editors. *Neurotrauma*. New York, NY: McGraw-Hill; 1996.
7. Dacey RG Jr, Alves WM, Rimel RW. Neurosurgical complications after apparently minor head injury. *J Neurosurg*. 1986;65:203–210.
8. Kraus JF. Epidemiology of head injury. In: Cooper PR, editor. *Head Injury*. 3rd ed. Baltimore, MD: Williams & Wilkins; 1993.
9. Rose J, Valtonen S, Jennett B. Avoidable factors contributing to death after head injury. *Br Med J*. 1977;2:615–661.
10. Rimel RW, Giordani B, Barth JT. Disability caused by minor head injury. *Neurosurgery*. 1981;9:221–228.
11. Galbraith S, Murray WR, Patel AR. The relationship between alcohol and head injury and its effect on the conscious level. *Br J Surg*. 1976;63:128–130.
12. Williams DH, Levin HS, Eisenberg HM. Mild head injury classification. *Neurosurgery*. 1990;27:422–428.
13. French BN, Dublin AB. The value of computerized tomography in the management of 1000 consecutive head injuries. *Surg Neurol*. 1977;7:171–183.
14. Andrade AF, Ciquini O Jr, Figueiredo EG, et al. Diretrizes do atendimento ao paciente com TCE. In: Freire E, editor. *Trauma: A Doença do Século*. São Paulo: Atheneu; 2001.
15. Andrade AF, Marino R Jr, Miura FK, et al. *Projeto Diretrizes da Associação Médica Brasileira e Conselho Federal de Medicina. Diagnóstico e Conduta no Paciente com Traumatismo Craniocéfálico Leve*. São Paulo: AMB/CFM; 2001.
16. Lee JH, Martin NA, Alsina G, McArthur DL, Zaucha K, Hovda DA. Hemodynamically significant cerebral vasospasm and outcome after head injury: A prospective study. *J Neurosurg*. 1997;87:221–223.
17. Masters SJ, McClean PM, Arcarese JS. Skull x-ray examinations after head trauma. Recommendations by a multidisciplinary panel and validation study. *N Engl J Med*. 1987;316:84–91.
18. Mendelow AD, Teasdale G, Jennett B. Risk of intracranial hematoma in head injured adults. *Br Med J*. 1983;287:1173–1176.

19. Hsiang JNK, Yeung T, Ashley LM, Poon WS. High-risk mild head injury. *J Neurosurg.* 1997;87:234–238.
20. Smits M, Dippel DW, Steyerberg EW, et al. Predicting intracranial traumatic findings on computed tomography in patients with minor head injury: The CHIP prediction rule. *Ann Intern Med.* 2007;146:397–405.
21. af Geijerstam JL, Oredsson S, Britton M; OCTOPUS Study Investigators. Medical outcome after immediate computed tomography or admission for observation in patients with mild head injury: Randomized controlled trial. *Br Med J.* 2006;333:465.
22. Comitê de Trauma do Colégio Americano de Cirurgiões. Suporte Avançado de Vida no Trauma (SAVT-ATLS®). 6th ed. Chicago, IL: American College of Surgeons; 1997.
23. Stein SC, Spettell C, Young G, Ross SE. Limitations of neurological assessment in mild head injury. *Brain Inj.* 1993;7:425–430.
24. Stein SC, Ross SE. Moderate head injury: A guide to initial management. *J Neurosurg.* 1992;77:562–564.
25. de Andrade AF, de Almeida AN, Bor-Seng-Shu E, Lourenço L, Mandel M, Marino R Jr. The value of cranial computed tomography in high-risk, mildly head-injured patients. *Surg Neurol.* 2006; 65 Suppl 1:10–11.
26. Cullotta VP, Sementilli ME, Gerold K. Clinicopathological heterogeneity classification of mild head injury. *Neurosurgery.* 1996;38:245–250.
27. Servadei F, Ciucci G, Loroni L, Cuscini M, Piola C, Arista A. Diagnosis and management of minor head injury: A regional multicenter approach in Italy. *J Trauma.* 1995;39:696–701.
28. King NS. Post-concussion syndrome: Clarity amid the controversy? *Br J Psychiatry.* 2003;183:276–278.
29. Coetzer BR. Management of post-concussion syndrome. *Br J Psychiatry.* 2004;184:86–87.

### International Journal of General Medicine

Dovepress

### Publish your work in this journal

The International Journal of General Medicine is an international, peer-reviewed open-access journal that focuses on general and internal medicine, pathogenesis, epidemiology, diagnosis, monitoring and treatment protocols. The journal is characterized by the rapid reporting of reviews, original research and clinical studies across all disease

areas. A key focus is the elucidation of disease processes and management protocols resulting in improved outcomes for the patient. The manuscript management system is completely online and includes a very quick and fair peer-review system. Visit <http://www.dovepress.com/testimonials.php> to read real quotes from published authors.

Submit your manuscript here: <http://www.dovepress.com/international-journal-of-general-medicine-journal>