

# Arthroscopic Identification of the Knee Posterolateral Corner Structures and Anatomic Arthroscopic Posterolateral Corner Reconstruction: Technical Note – Part 1



Benjamin Freychet, M.D., Bertrand Sonnery-Cottet, M.D., Thais Dutra Vieira, M.S.,  
Thomas L. Sanders, M.D., Nicholas I. Kennedy, M.D., Aaron J. Krych, M.D.,  
Michael J. Stuart, M.D., and Bruce A. Levy, M.D.

**Abstract:** Arthroscopic assessment of posterior compartments of the knee and the posterior aspect of the proximal tibial and fibula is challenging because of the relative proximity of the neurovascular bundle. This Technical Note describes a reproducible arthroscopic surgical approach in a cadaveric model that aims to identify and expose the popliteus tendon, posterior fibular head, fibular collateral ligament, popliteal fibular ligament, biceps femoris tendon, and peroneal nerve.

**A** rthroscopic assessment of posterior compartments of the knee and the posterior aspect of the proximal tibial and fibula is challenging due to the relative proximity of the neurovascular bundle. Despite this difficulty, arthroscopic surgery of the posterior compartment of the knee has evolved rapidly over the past several decades.

Surgeons often access the posterior compartments of the knee to remove a loose body,<sup>1</sup> repair a posterior horn meniscus tear,<sup>2,3</sup> complete a subtotal synovectomy,<sup>4</sup> and perform arthroscopic-assisted posterior

cruciate ligament reconstruction.<sup>5</sup> Recently, several arthroscopic techniques have been described for the treatment of posterolateral instabilities.<sup>6-8</sup> Proximity of the neurovascular bundle leaves these structures susceptible to iatrogenic injury, so care must be taken when drilling tibial or fibular tunnels to reconstruct these posterolateral corner (PLC) structures, and precise visualization of the posterolateral compartment of the knee is necessary. Arthroscopic procedures have a significant learning curve, and the technique has been described only by experienced knee arthroscopy surgeons.

There are no published reports that describe a surgical approach to identify all the key posterolateral structures of the knee. This Technical Note describes a reproducible arthroscopic surgical approach to identify and expose the popliteus tendon (PT), posterior fibular head, fibular collateral ligament (FCL), popliteal fibular ligament (PFL), biceps femoris tendon, and peroneal nerve.

## Surgical Technique

This Technical Note is a cadaveric study conducted in 2 steps. In the first step, 5 arthroscopic portals are placed: anterolateral, anteromedial, posterolateral, posteromedial, and superolateral. In the second step, these portals are used to identify the key PLC structures (PT, FCL, PFL, fibular head, biceps femoris tendon, and peroneal nerve) ([Video 1](#)). Key steps, pearls, and pitfalls are presented in [Table 1](#).

*From the Department of Orthopedic Surgery and Sports Medicine, Mayo Clinic, Rochester, Minnesota, U.S.A. (B.F., T.L.S., N.I.K., A.J.K., M.J.S., B.A.L.); the Centre Orthopédique Santy, Lyon, France (B.F., B.S.-C., T.D.V.); and Hôpital Privé Jean Mermoz, Ramsay-Général de Santé, Lyon, France (B.F., B.S.-C., T.D.V.).*

*The authors report the following potential conflicts of interest or sources of funding: B.S.-C. reports personal fees, Arthrex. A.J.K. reports personal fees, Arthrex, Vericel, Aesculap/B, Braun, Arthritis Foundation, Ceterix, Histogenics. M.J.S. reports personal fees, Arthrex, Stryker. B.A.L. reports personal fees, Arthrex, Smith & Nephew, Stryker, Biomet. Full ICMJE author disclosure forms are available for this article online, as [supplementary material](#).*

*Received March 17, 2020; accepted August 29, 2020.*

*Address correspondence to Benjamin Freychet, M.D., 24 Ave Paul Santy, Lyon 69008, France. E-mail: [benjamin.freychet@gmail.com](mailto:benjamin.freychet@gmail.com)*

© 2020 by the Arthroscopy Association of North America. Published by Elsevier. This is an open access article under the CC BY-NC-ND license (<http://creativecommons.org/licenses/by-nc-nd/4.0/>).

2212-6287/20830

<https://doi.org/10.1016/j.eats.2020.08.026>

**Table 1.** Key steps, pearls, and pitfalls

Key Steps	Pearls	Pitfalls
Anterolateral portal placement	Place the standard anterolateral portal far enough lateral to work in the lateral gutter	If this portal is not lateral enough, an impingement with the lateral femoral condyle can occur.
Anteromedial portal placement	Adjacent to the medial patellar tendon margin above the medial meniscus	If this portal is placed too medially, the passage through the intercondylar notch into the posterior compartments can be restricted.
Posterolateral portal placement	Posterior to the fibular collateral ligament and popliteus tendon at the level of the joint line for adequate access to the popliteus tendon and fibular head	Misplacement of this portal can lead to a suboptimal attack angle at the time of debridement.
Transeptal approach	Face the shaver toward the joint (anterior) and away from the popliteal neurovascular bundle. Hold the shaver in this position directly posterior to the posterior cruciate ligament (PCL).	
Posterolateral capsulotomy	To open the capsule until distal insertion of PCL and enhance the work space	Minimal debridement in this area can prevent optimal visualization.
Fibular head	First landmark to be spotted and the best point to start dissection and return to	Once this landmark is missed, frequently the surgeon is off track.
Biceps femoris	It is always far more lateral from the fibular head than thought. Use a blunt instrument to identify the peroneal nerve instead of the shaver or radiofrequency device to prevent iatrogenic injury.	Common peroneal nerve safety is preserved when the work area is at the level of the fibular head tip.

### Step 1: Creation of Portals

Proper portal placement is critical to obtaining adequate access to the posterior compartments of the knee.

#### Anterolateral Portal

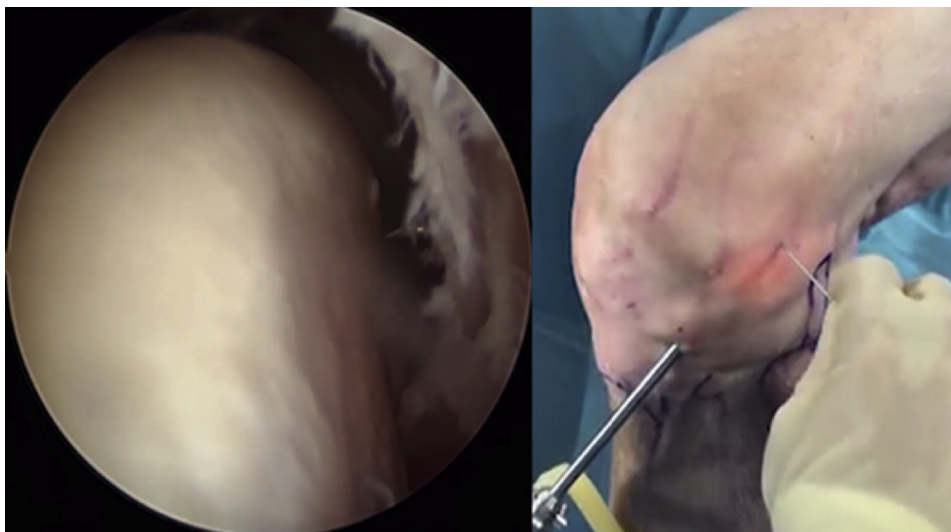Place the standard anterolateral portal far enough lateral to work in the lateral gutter and avoid impingement with the lateral femoral condyle. The landmark is the crossing point of the tangent lines of inferior and lateral borders of the patella with the knee in 90° flexion.

#### Anteromedial Portal

Position the standard anteromedial portal adjacent to the medial patellar tendon margin above the medial meniscus to allow easy passage of through the intercondylar notch into the posterior compartments.

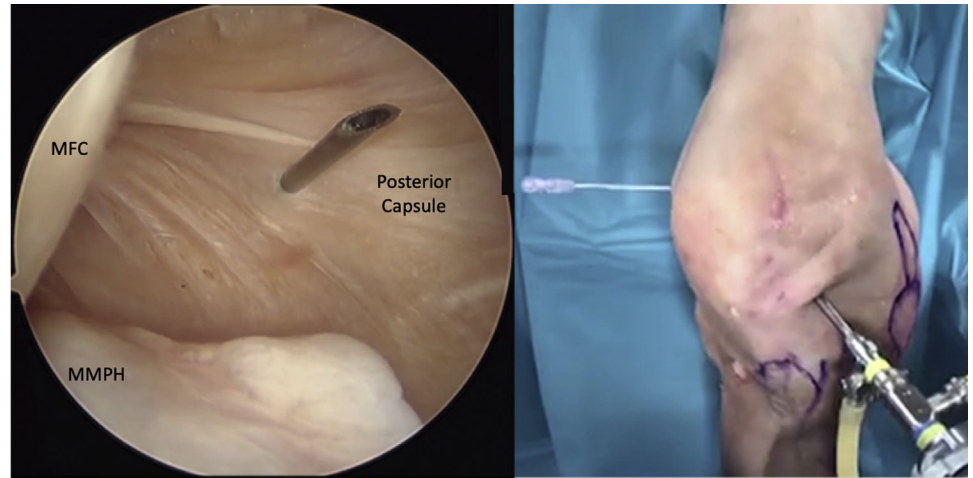
#### Superolateral Portal

Use the superolateral portal to access the popliteus tendon and FCL femoral attachment sites. Insert a spinal needle at the midpoint of the lateral border of the patella with the knee flexed at 90° to confirm access to both the lateral epicondyle and popliteus tendon (Fig 1).



**Fig 1.** Left knee in 90 degrees of flexion. Superolateral portal. Left: Arthroscopic view through anterolateral portal. Right: Extra-articular view, needle positioning in a transillumination technique.

**Fig 2.** Left knee in 90 degrees of flexion. 30 arthroscope through the anterolateral portal into the posteromedial compartment. Post-eromedial portal. Left: Arthroscopic view though anterolateral portal with needle through post-eromedial capsule. Right: Extra-articular view, needle positioning in a transillumination technique. Abbreviations: MFC, medial femoral condyle; MMPH, medial meniscus posterior horn.



**Posteromedial Portal**

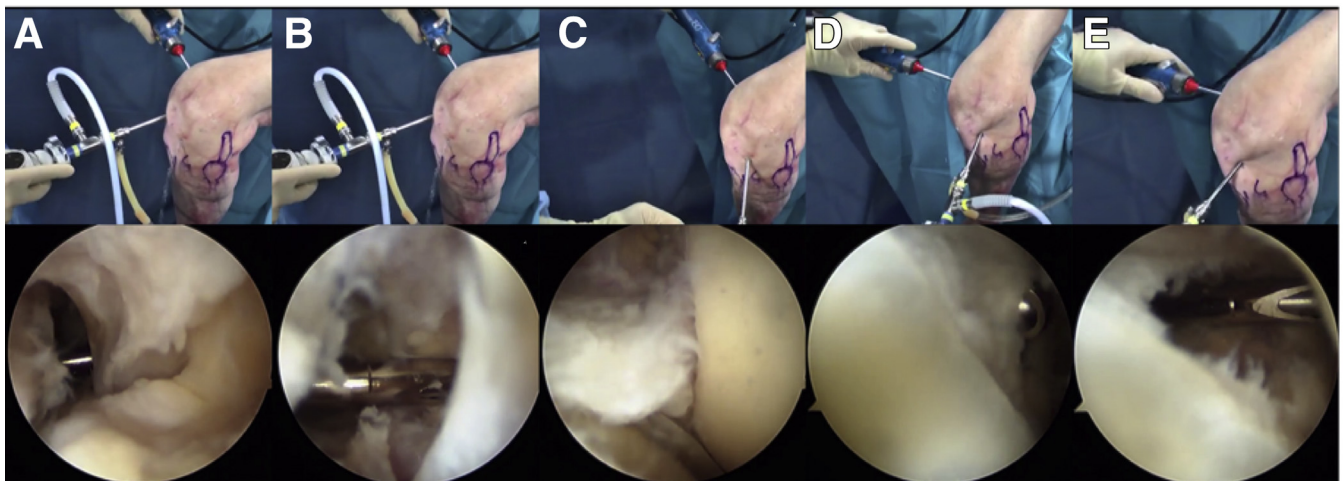
A posteromedial portal is created under direct arthroscopy by inserting the scope through the anterolateral portal into the posteromedial compartment. The sartorial branch of the saphenous nerve is avoided by transillumination with the knee flexed at 90°. Insert a spinal needle ~1 cm proximal and posterior to the joint line under direct arthroscopic visualization (Fig 2). Accurate portal placement is important to access to the PLC structures.

**Posterior Transeptal and Posterolateral Portals**

Place the 30° arthroscope through the anteromedial portal to access the posteromedial compartment (Fig 3A). Introduce the shaver through the posteromedial portal to gently remove the central-inferior septum to avoid iatrogenic injury to the middle genicular vessels (Fig 3A, B). Face the shaver toward the

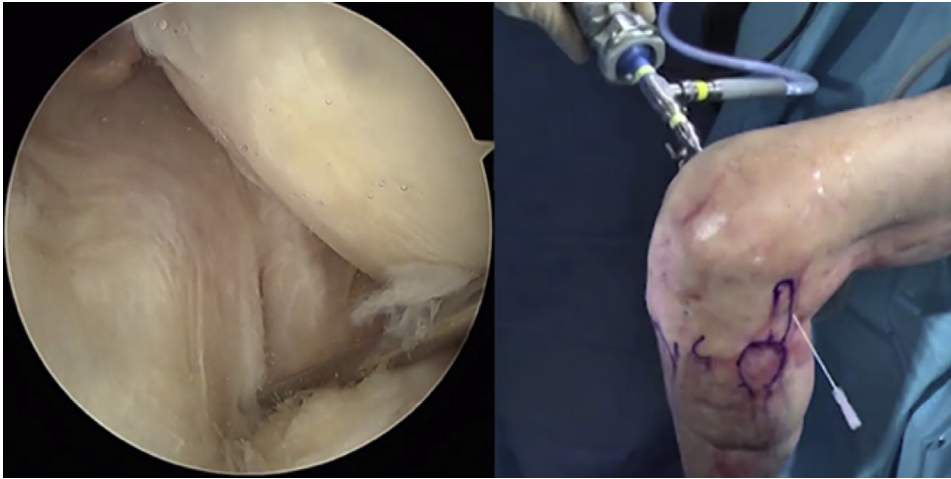
joint (anterior) and away from the popliteal neurovascular bundle. Carefully release the septum from medial to lateral until the tip of the shaver can no longer be fully visualized. Hold the shaver in this position directly posterior to the posterior cruciate ligament (PCL). Insert the arthroscope through the anterolateral portal to reach the posterolateral compartment (Fig 3C). Visualize the posterolateral border of the PCL, then move the shaver from the medial to the lateral compartment under direct observation. The window between the compartments expands as the septum is carefully removed (Fig 3D, E).

Insert the arthroscope in the posteromedial portal, travel past the PCL, and enter the posterolateral compartment. Establish the posterolateral portal under direct arthroscopic visualization with the knee flexed at 90° using the light source to transilluminate the skin incision and avoid neurovascular injury. Palpate the soft



**Fig 3.** Left knee in 90 degrees of flexion. 30 arthroscope through the anteromedial portal to access the posteromedial compartment. Transeptal approach (inside and outside views). (A) Access to the posteromedial compartment. (B) Central-inferior septum debridement. (C) Release of the septum from medial to lateral to reach the posterolateral compartment. (D) Shaver debridement from the medial to the lateral compartment under direct observation. (E) Window between the compartments.





**Fig 4.** Left knee in 90 degrees of flexion. Posterolateral portal (inside view from transeptal approach and outside views).

spot between the posterior border of the iliotibial band and the anterior border of the biceps femoris and position the spinal needle (Fig 4). Insert a scalpel blade in line with the needle to visualize entry into the joint. Use a hemostat to widen the portal. Portal placement should be posterior to the FCL and PT at the level of the joint line for adequate access to the popliteus tendon and fibular head. Insert the shaver into the posterolateral portal and resect the septum all the way to the level of the PCL.

### Step 2: Identification of Posterolateral Structures

The following technique describes the arthroscopic identification and exposure of the posterolateral structures.

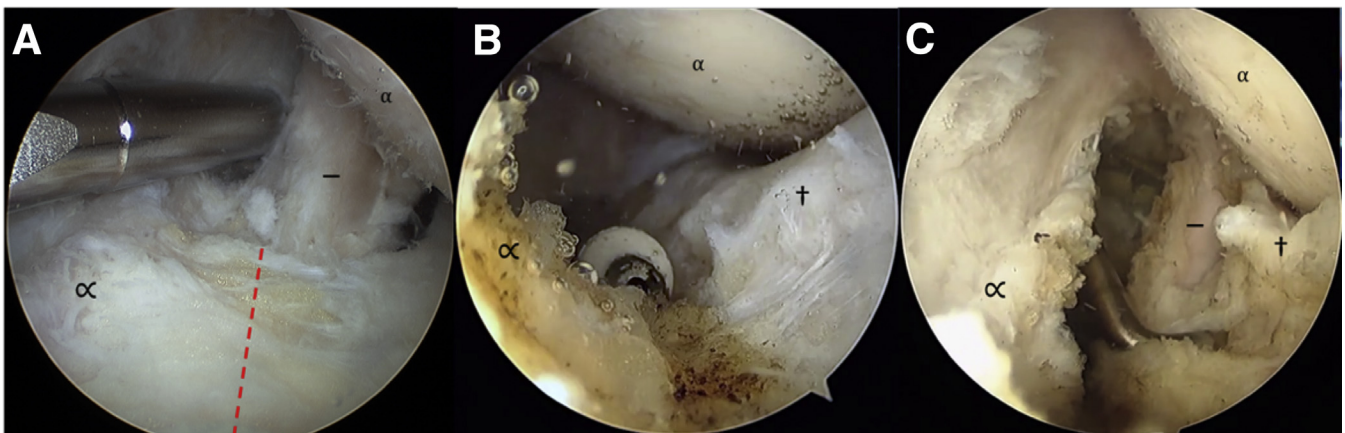#### Popliteus Tendon and Sulcus

Introduce the 30° arthroscope in the posteromedial portal and pass through the transeptal portal into the posterolateral compartment. The popliteus tendon, PFL,

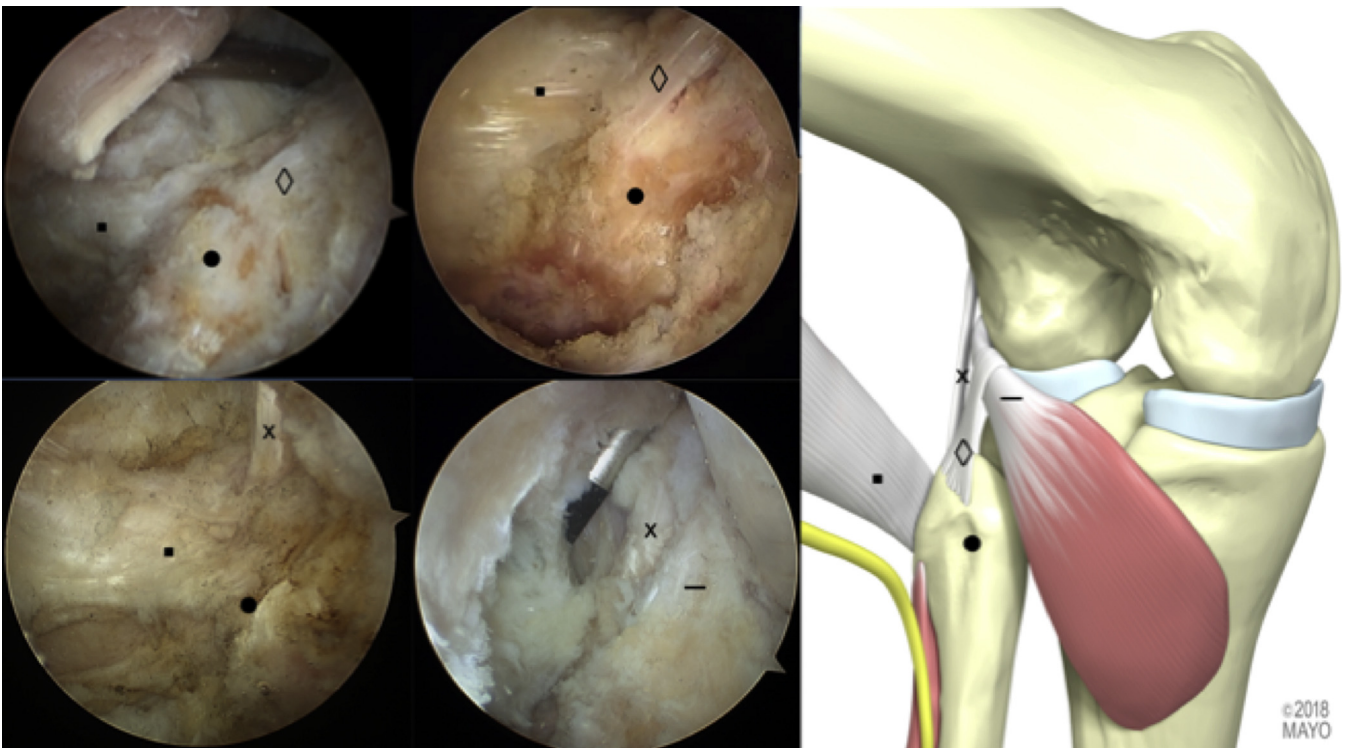
lateral femoral condyle, lateral meniscus, posterior capsule, fibular head, FCL, biceps femoris, and peroneal nerve are all well defined. Insert a radiofrequency device through the posterolateral portal and separate the posterolateral capsule from the lateral meniscus posterior horn for 2 cm to visualize the popliteal sulcus (Fig 5A, B). Identify the lateral meniscus, popliteus, and posterior capsule. The posterior capsule and gastrocnemius muscle fibers are seen distally, and the space between popliteus and gastrocnemius is opened (Fig 5C). Remove the synovium with the shaver jaws facing anteriorly until the popliteus musculotendinous junction is identified.

#### Fibular Head, Biceps Femoral, and FCL

Identification of the fibular head is paramount to identify the remaining PLC structures. After separating the posterolateral capsule from the posterior horn of the lateral meniscus, use the shaver to dissect lateral and slightly posterior to the popliteus until the fibular



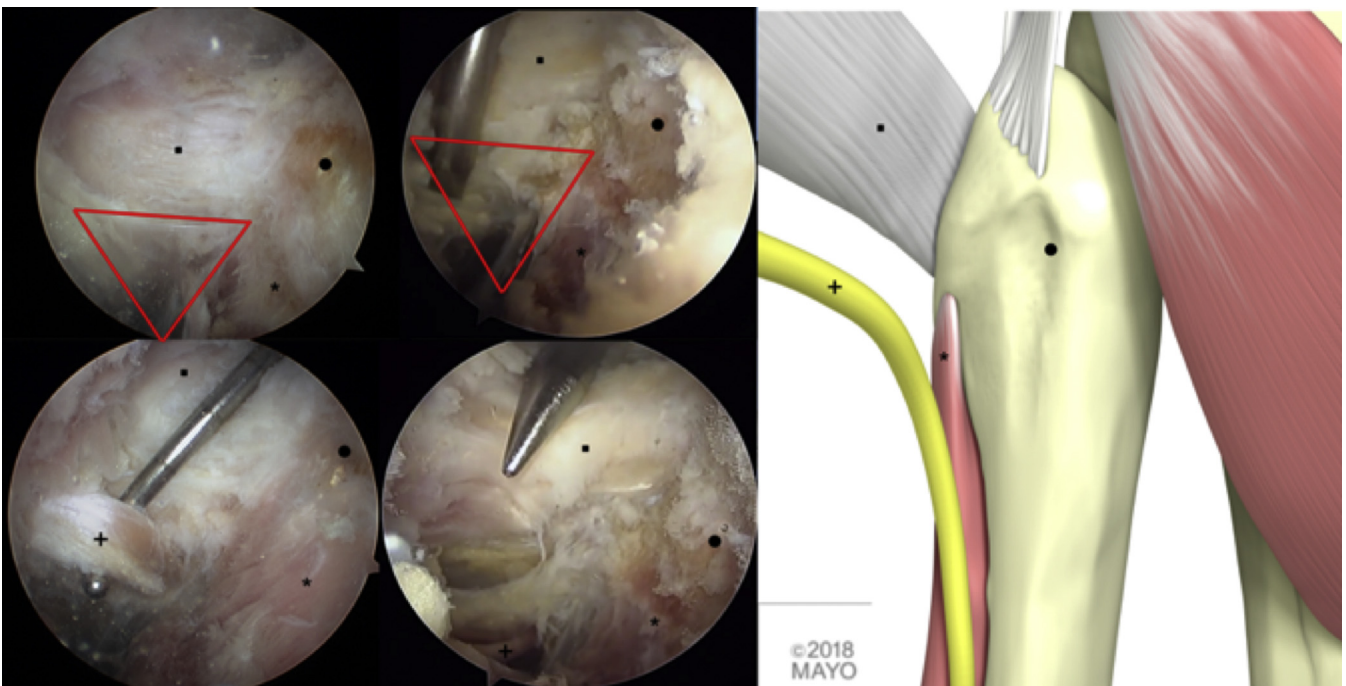
**Fig 5.** Left knee in 90 degrees of flexion. Posterolateral capsule of the knee joint is carefully separated from the synovial edge of the posterior horn of the lateral meniscus. (A) Aspect before capsulotomy. (B) Radiofrequency debridement separating the posterior capsule from the posterior horn of lateral meniscus, and the space between popliteus and gastrocnemius is opened. (C) Identification of the musculotendinous junction after capsulotomy. Symbols: —, popliteus tendon; †, lateral meniscus; α, femoral condyle; ∞, posterior capsule.



**Fig 6.** Left knee in 90 degrees of flexion. Posterolateral structures. Symbols: ■, biceps femoris; ●, fibular head; ◇, popliteofibular ligament; x, fibular collateral ligament; -, popliteus tendon.

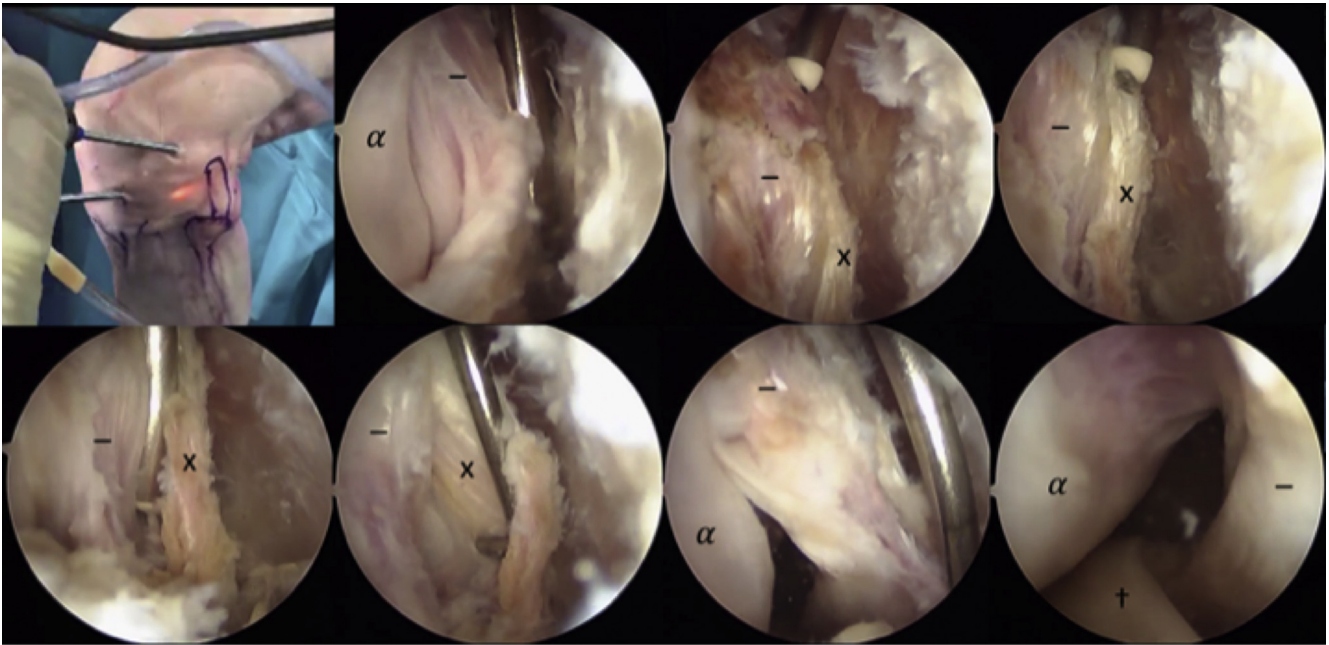
head comes into view. Palpate with any blunt instrument. Expose the posterosuperior part of the fibular head using the radiofrequency probe. Identify the biceps femoris by resecting the synovium from the posterior fibular head until the lateral border of the biceps

femoris comes into the view. Identify the biceps bursa proximal to the fibular head and carefully penetrate to expose the FCL. The FCL can also be found by following the biceps anteriorly to its attachment on the fibular head with the knee at 90° flexion. The FCL runs



**Fig 7.** Peroneal nerve dissection. Symbols: ■, biceps femoris; ●, fibular head; \*, peroneus longus; +, peroneal nerve.





**Fig 8.** Left knee in 90 degrees of flexion. Fibular collateral ligament (FCL) and popliteus tendon dissection on femoral side. Symbols: x, fibular collateral ligament; -, popliteus tendon; †, lateral meniscus;  $\alpha$ , femoral condyle.

perpendicular to the biceps and lateral to the popliteus tendon (Fig 6).

#### Peroneal Nerve

The landmarks to identify the peroneal nerve are the inferior border of the biceps femoris and posterolateral fibular neck. Find the fatty tissue at this corner (Fig 7) and carefully dissect with a blunt instrument instead of the shaver or radiofrequency device to prevent iatrogenic injury. The peroneal nerve is located just behind this fatty tissue.

#### Popliteus Tendon and FCL Femoral Attachments

Insert the 30° arthroscope from the anterolateral portal into the lateral gutter. Usually, the landmark is the crossing of the tangent line from the inferior and lateral border of the patella with the knee at 90° flexion. Establish an accessory superolateral portal with a spinal needle to reach the proximal insertion of the popliteus. Debride the synovium from the proximal popliteus tendon with the shaver in the superolateral portal to explore the insertion site with the knee at 90° flexion. Increase the lateral gutter space by debriding the synovial tissue between the popliteus tendon attachment and iliotibial band. Find the FCL insertion anterior and proximal to the popliteus tendon (Fig 8).

#### Cautions

This technique is not free of complications. The common peroneal nerve and the lateral inferior genicular artery are the structures potentially at risk. Common

peroneal nerve safety is preserved when the work area is at the level of the fibular head tip. The lateral inferior genicular artery is close to popliteus musculotendinous junction, so care must be taken while shaving this area, and the shaver's cutting surface should face antero-inferiorly. Moreover, iatrogenic compartment syndrome due to extravasation of irrigating fluid and deep vein thrombosis are possible complications related to the procedure.

#### Discussion

The surgically important ligaments of the PLC include the FCL, PT, and PFL.<sup>9,10</sup> Injuries to these structures results in posterolateral instability of the knee, challenging surgeons in this critical region. The arthroscopic approach to the posterior compartment of the knee joint is demanding because of the risk of injury to the popliteal artery and the peroneal nerve. Multiple authors have described transeptal approach techniques and verified their safety.<sup>4-8</sup> However, surgeons remain reluctant to perform the transeptal portal owing to the proximity of the neurovascular structures.

Several recent cadaveric and radiographic studies have helped to improve the safety of this technique by defining the dimensions of the posteromedial and posterolateral compartments, as well as the relationship between the PCL and popliteal artery.<sup>11-14</sup> After posterior capsule release, the mean distance between the PCL and the popliteal artery is 19.3 mm.<sup>12</sup> Positioning the knee at 90° flexion is the safest way to establish posterior and transeptal arthroscopic portals.<sup>13</sup>

Debridement of the posterior septum is performed distally to preserve the greatest number of blood vessels and mechanoreceptors.<sup>15</sup> The safe margin of the posteromedial compartment is consistently wider than the one in the posterolateral compartment. Debriding the septum from medial to lateral allows precise posterolateral portal placement by using direct visualization of the popliteus tendon as the key landmark.<sup>16</sup> To avoid peroneal nerve iatrogenic injury, the shaver and radiofrequency device should be replaced by a blunt instrument when nearing the inferior border of the biceps femoris.

In conclusion, PLC structures can be identified during arthroscopy, but with a steep learning curve. A thorough understanding of anatomy is key to surgical success when approaching injuries to this area of the knee. This reproducible arthroscopic technique to expose and identify all pertinent structures of the PLCs may set the stage for safe and successful arthroscopic reconstructive techniques.

## References

1. Lee YS, Ahn JH, Min B-H, Nha KW. Arthroscopic loose body removal and cyst decompression using a posterior trans-septal portal in the blind spot during knee arthroscopy—Technical report. *Knee* 2011;18:55-58.
2. Sonnery-Cottet B, Conteduca J, Thaunat M, Gunepin FX, Seil R. Hidden lesions of the posterior horn of the medial meniscus: A systematic arthroscopic exploration of the concealed portion of the knee. *Am J Sports Med* 2014;42:921-926.
3. Thaunat M, Jan N, Fayard JM, et al. Repair of meniscal ramp lesions through a posteromedial portal during anterior cruciate ligament reconstruction: Outcome study with a minimum 2-year follow-up. *Arthroscopy* 2016;32:2269-2277.
4. Lui TH. Arthroscopic treatment of pigmented villonodular synovitis of the proximal tibiofibular joint. *Knee Surg Sports Traumatol Arthrosc* 2015;23:2278-2282.
5. Ahn JH, Chung YS, Oh I. Arthroscopic posterior cruciate ligament reconstruction using the posterior trans-septal portal. *Arthroscopy* 2003;19:101-107.
6. Song G-Y, Zhang H, Zhang J, Li Y, Feng H. Anatomical popliteofibular ligament reconstruction of the knee joints: An all-arthroscopic technique. *Knee Surg Sports Traumatol Arthrosc* 2015;23:2925-2929.
7. Frosch K-H, Akoto R, Heitmann M, Enderle E, Giannakos A, Preiss A. Arthroscopic reconstruction of the popliteus complex: Accuracy and reproducibility of a new surgical technique. *Knee Surg Sports Traumatol Arthrosc* 2015;23:3114-3120.
8. Frings J, Kolb JP, Drenck TC, et al. Anatomic reconstruction of the posterolateral corner: An all-arthroscopic technique. *Arthrosc Tech* 2019;8:e153-e161.
9. Moorman CT, LaPrade RF. Anatomy and biomechanics of the posterolateral corner of the knee. *J Knee Surg* 2005;18:137-145.
10. McCarthy M, Camarda L, Wijdicks CA, Johansen S, Engebretsen L, LaPrade RF. Anatomic posterolateral knee reconstructions require a popliteofibular ligament reconstruction through a tibial tunnel. *Am J Sports Med* 2010;38:1674-1681.
11. Cosgarea AJ, Kramer DE, Bahk MS, Totty WG, Matava MJ. Proximity of the popliteal artery to the PCL during simulated knee arthroscopy: Implications for establishing the posterior trans-septal portal. *J Knee Surg* 2006;19:181-185.
12. Pace JL, Wahl CJ. Arthroscopy of the posterior knee compartments: Neurovascular anatomic relationships during arthroscopic transverse capsulotomy. *Arthroscopy* 2010;26:637-642.
13. Makridis KG, Wajsfisz A, Agrawal N, Basdekis G, Djian P. Neurovascular anatomic relationships to arthroscopic posterior and transseptal portals in different knee positions. *Am J Sports Med* 2013;41:1559-1564.
14. Kim S-J, Song H-T, Moon H-K, Chun Y-M, Chang W-H. The safe establishment of a transseptal portal in the posterior knee. *Knee Surg Sports Traumatol Arthrosc* 2011;19:1320-1325.
15. Ramos LA, Astur D, Novaretti JV, et al. An anatomic study of the posterior septum of the knee. *Arthroscopy* 2012;28:100-104.
16. Dilworth B, Fehrenbacher V, Nyland J, Clark J, Greene JW. Lateral knee compartment portals: A cadaveric study defining a posterolateral viewing safety zone. *Arthroscopy* 2018;34:2201-2206.