

# Spinal Tuberculosis: Current Concepts

S. Rajasekaran, PhD, FRCS, MCh<sup>1</sup>,  
Dilip Chand Raja Soundararajan, MS<sup>1</sup>,  
Ajoy Prasad Shetty, MS<sup>1</sup>, and Rishi Mugesh Kanna, MS<sup>1</sup>

Global Spine Journal  
2018, Vol. 8(4S) 96S-108S  
© The Author(s) 2018  
Article reuse guidelines:  
sagepub.com/journals-permissions  
DOI: 10.1177/2192568218769053  
journals.sagepub.com/home/gsj



## Abstract

**Study Design:** Review article.

**Objectives:** A review of literature on the epidemiology, diagnosis, and management of spinal tuberculosis (TB).

**Methods:** A systematic computerized literature search was performed using Cochrane Database of Systematic Reviews, EMBASE, and PubMed. Studies published over the past 10 years were analyzed. The searches were performed using Medical Subject Headings terms, and the subheadings used were “spinal tuberculosis,” “diagnosis,” “epidemiology,” “etiology,” “management,” “surgery,” and “therapy.”

**Results:** Tissue diagnosis remains the only foolproof investigation to confirm diagnosis. Magnetic resonance imaging and Gene Xpert help in early detection and treatment of spinal TB. Uncomplicated spinal TB has good response to appropriately dosed multimodal ambulant chemotherapy. Surgery is warranted only in cases of neurological complications, incapacitating deformity, and instability.

**Conclusions:** The incidence of atypical clinicoradiological presentations of spinal TB is on the rise. Improper dosing, inadequate duration of treatment, and inappropriate selection of candidates for chemotherapy has not only resulted in the resurgence of TB but also led to the most dreadful consequence of multidrug resistant strains. In addition, global migration phenomenon has resulted in worldwide spread of spinal TB. The current consensus is to diagnose and treat spinal TB early, prevent complications, promote early mobilization, and restore the patient to his or her earlier functional status.

## Keywords

infection, spondylitis, spondylodiscitis, MRI, decompression, deformity, cervical, thoracic, thoracolumbar, lumbar

## Introduction

The existence of tuberculosis (TB) in ancient times is evident from the fact that it was observed in mummies from Egypt and Peru (9000 BC) and has also been described as “Yakshama” in the oldest Indian medical treatises of *Charaka Samhita* and *Sushruta Samhita*, dating back to 1000 and 600 BC, respectively.<sup>1,2</sup> In 1779, Sir Percival Pott described tuberculous spondylitis and its clinical presentation of paraplegia in patients with kyphotic deformities in European population.<sup>3</sup> Significant progress has been achieved in 19th and 20th centuries including the discovery of the causative agent, *Mycobacterium tuberculosis*, development of Bacillus Calmette-Guerin (BCG) vaccine, invention of chemotherapeutic agents, advances in diagnostics, and improvement in surgical outcomes.<sup>4,5</sup>

Once believed to be a health burden due to its endemic nature in underprivileged sections of developing countries, TB is now an international concern, as it has its footprints spread all over the world due to the global migration

phenomenon. In spite of the major strides achieved in early diagnosis and efficient management of cases over the past 4 decades, increasing prevalence of immunodeficient survivors and the emergence of multidrug resistance (MDR) has resulted in resurgence of TB as a public health menace.<sup>6</sup>

## Epidemiology

The incidence of extrapulmonary TB (EPTB) is low at 3%, but there has been no significant reduction in incidence of EPTB when compared to pulmonary TB (PTB).<sup>7</sup> Skeletal TB (STB) contributes to around 10% of EPTB, and spinal TB has been the

<sup>1</sup> Ganga Hospital, Coimbatore, India

### Corresponding Author:

S. Rajasekaran, Department of Spine Surgery, Ganga Hospital, 313, Mettupalayam Road, Coimbatore 641043, India.  
Email: rajasekaran.orth@gmail.com



most common site of STB, amounting to around half of skeletal EPTB. Thoracolumbar junction remains to be the most affected region of the spinal column followed by lumbar spine and the cervical spine.<sup>8,9</sup>

In 2016, there was an estimated incidence of 10.4 million new TB cases as per the World Health Organization (WHO).<sup>10</sup> While European region contributed only 3%, the South East Asian Region alone had 46.5% of the global TB burden.<sup>11,12</sup> The deaths related to TB remained to be one of the top 10 causes of death worldwide, despite the decline of TB deaths by 22% from 2000 to 2015.

According to the United Nations, the number of international migrants had grown rapidly from 173 million to 244 million from 2000 to 2015. The majority of migrants belonged to middle-income countries and most of them moved to developed nations. India, which contributed to around 23% of the global TB burden, also had the largest diaspora in the world in 2015.<sup>13</sup> This global migration phenomenon along with emergence of MDR strains pose new challenges to the global health care system. In addition, the ever-increasing incidence of chronic debilitating medical diseases and HIV-affected individuals further portend to the resurgence of TB.<sup>14</sup> Consistent efforts are being taken by the WHO, and the WHO End TB Strategy for 2030 has been adopted by its member nations, which aims at 80% reduction of TB incidence rate and 90% reduction of TB deaths.<sup>15</sup>

## Pathophysiology of Spinal TB

TB is caused by *Mycobacterium tuberculosis* complex, which has around 60 species. Among them only *Mycobacterium tuberculosis* (the most common), *Mycobacterium bovis*, *Mycobacterium microti*, and *Mycobacterium africanum* are known to affect humans.<sup>16</sup> It is a slow-growing fastidious, aerobic bacillus. The primary site of infections can be in the lungs, lymph nodes of the mediastinum, mesentery, gastrointestinal tract, genitourinary system, or any other viscera. The bacilli tend to remain dormant for prolonged periods and multiplies every 15 to 20 hours in aerobic conditions whenever favorable. Spinal infection is always secondary and is caused by hematogenous dissemination of the bacillus from a primary focus.<sup>17,18</sup>

Anatomically the intervertebral disc is an avascular structure and the paradiscal arteries split on either side of the disc and reach the subchondral region of the upper and lower endplates of each disc. This arterial supply of the vertebra favors subchondral bone involvement on either side of the disc, “paradiscal,” which is the most common type observed.<sup>19</sup> The other patterns of involvement are “central,” resulting in vertebral body loss; “posterior,” when posterior appendicular structures are involved; and “nonosseous abscess” formation. TB results in granulomatous inflammation characterized by lymphocytic infiltration and epithelioid cells, which may merge to form the classical Langhans-type giant cells and end up in caseating necrosis of affected tissues forming cold abscess. With progressive destruction of the vertebral body, deformation of spine causes kyphosis.<sup>20,21</sup>

## Clinical Presentation of Spinal TB

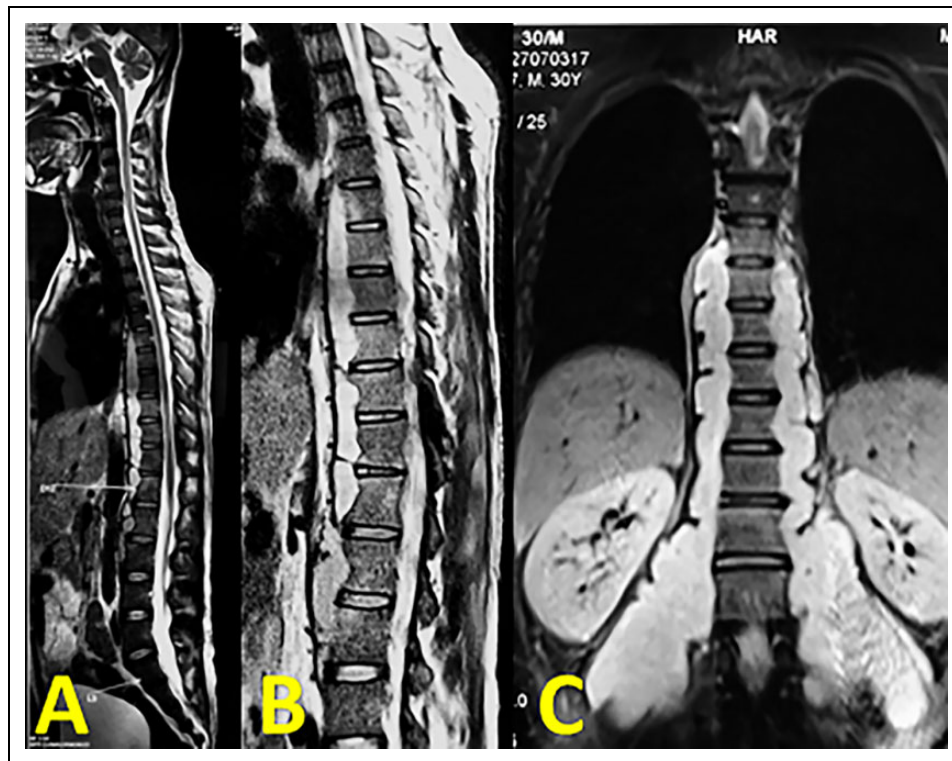
The clinical picture of spinal TB is extremely variegated. Spinal TB usually is insidious in onset and the disease progresses at a slow pace.<sup>22</sup> The diagnostic period, since onset of symptoms, may vary from 2 weeks to several years. The manifestation of spinal TB depends on the severity and duration of the disease, site of the disease, and the presence of complications such as abscess, sinuses, deformity, and neurological deficit.<sup>23</sup> Spinal TB can either be complicated or uncomplicated. In complicated TB, patients present with deformity, instability, and neurological deficit. Uncomplicated spinal TB is one in which diagnosis is made prior to development of such complications. Backache is the most common of all symptoms. During the active stage, it is primarily due to inflammation of the bone and rarely can be radicular in nature. Rest pain at the involved level is pathognomonic and the intensity is proportional to the amount of bone destruction and instability.<sup>24</sup> Constitutional symptoms such as loss of weight, loss of appetite, fever, and malaise are more frequently associated with PTB than spinal TB.<sup>25</sup>

## Cold Abscess

Cold abscess lacks inflammatory features and initially forms in the infective focus. Later, it takes the path of least resistance along the natural fascial and neurovascular planes as depicted in Figure 1. In the cervical spine, it can present as a retropharyngeal abscess or as a swelling in anterior or posterior triangle of neck or even in the axilla. Retropharyngeal abscess can produce dysphagia, hoarseness of voice, and respiratory stridor.<sup>26</sup> In the thoracic region, the cold abscess usually presents as a fusiform paravertebral swelling, seen radiographically, and it can track along the intercostal vessels and presents as a swelling in the chest wall. Thoracic cold abscess can track down through the arcuate ligament, or via the openings in the diaphragm.<sup>27</sup> The lumbar cold abscess usually present as a swelling in Petit’s triangle or in the groin and can track down along the psoas to cause pseudo-flexion deformity of the hip. Rarely they can track femoral or gluteal vessels to present as an abscess in Scarpa’s triangle or gluteal region.<sup>28,29</sup>

## Deformity

Owing to the involvement of anterior column, progressive destruction results in kyphotic deformity of spine most often. The clinical appearance depends on the number of vertebrae involved causing “knuckle” (1 vertebra), “gibbus” (2 vertebrae), and “rounded kyphosis” (>3 vertebral collapse). Rajasekaran et al proposed a formula to predict the final kyphotic deformity in adult population affected with spinal TB:  $Y = a + bx$ , where  $Y$  is the final angle, “ $a$ ” and “ $b$ ” are constants, 5.5 and 30.5, respectively, and  $x$  is the initial loss of vertebral height in thoracic and thoracolumbar spine.<sup>30</sup> Jain et al later observed that it was possible to predict final kyphotic deformity using this formula with a variability of  $\pm 10^\circ$ .<sup>31</sup> Jain



**Figure 1.** (A, B) Whole spine and focal T2 weighted sagittal MRI images of a 30-year-old individual showing unusually large prevertebral abscess with extensive tracking beneath the anterior longitudinal ligament. (C) Coronal image shows the abscess tracking along the psoas muscle to reach the anterior aspect of the thigh.

et al believed that any kyphotic deformity of  $60^\circ$  or above is disabling and may increase the likelihood of developing neurological sequelae.<sup>32</sup> The vertebral loss is well tolerated in cervical and lumbar spine unlike thoracic and thoracolumbar spine due to the inherent lordosis. However, rarely with active ongoing infection, progressive cervical kyphosis may necessitate surgical intervention, as shown in Figure 2.

### Pediatric Spinal TB

The immaturity and flexibility of spine in children is the reason why they are prone to rapid and severe deformity progression following vertebral collapse.<sup>33</sup> In childhood TB, even after healing of the disease, deformity may progress due to the growing nature of spine. Rajasekaran described the signs of instability that he noted in a 15-year follow-up of children affected with spinal TB. The 4 “spine at risk” signs were retropulsion, subluxation, lateral translation, or toppling.<sup>34</sup> He suggested that children with instability score of 2 or more had disruption of the posterior facet and advised surgery in such situations.<sup>35</sup> One such situation, managed surgically is shown in Figure 3.

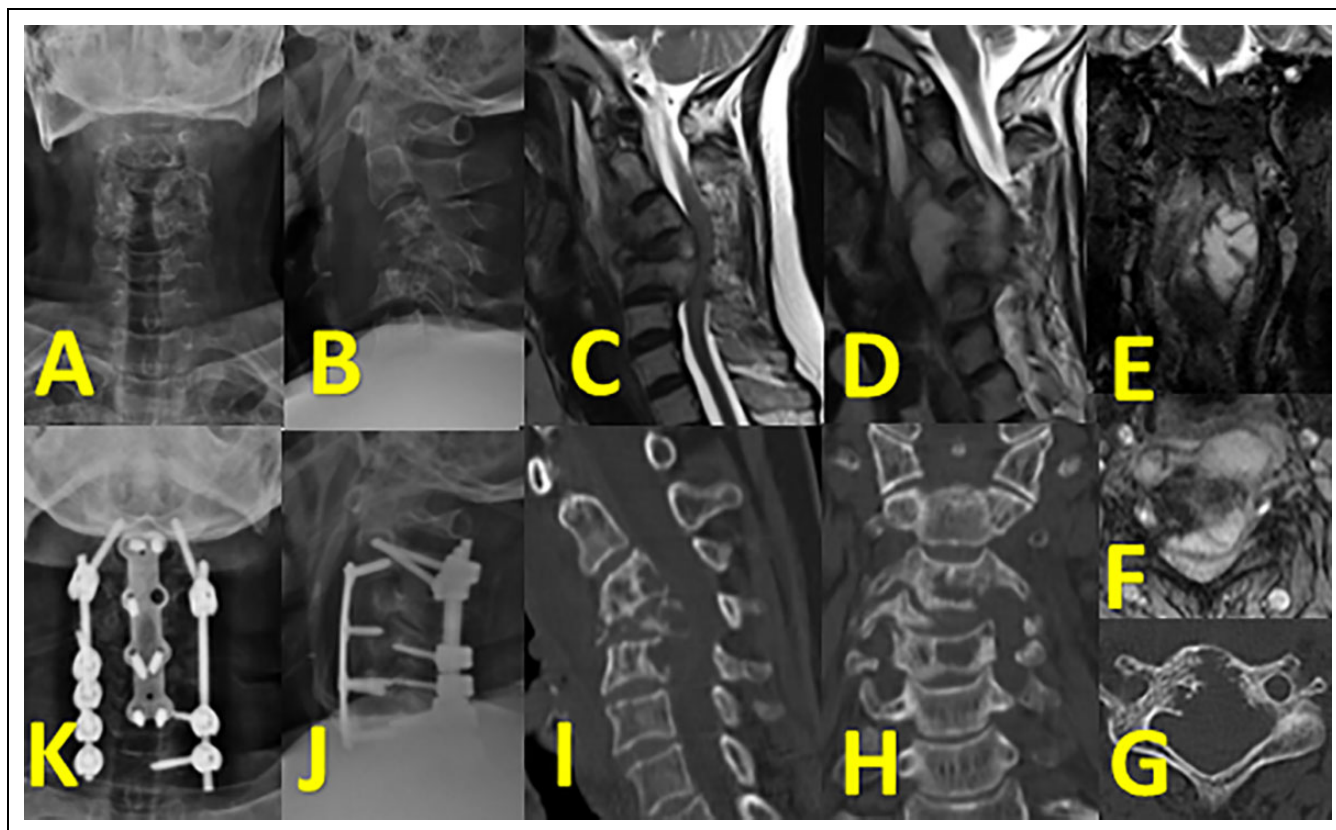
### Neurological Deficit

Neurological complications can occur either during the early active disease or in the late healed stage. Direct compression due to abscess, inflammatory tissue, or sequestrum and

instability are the usual causes for neural compromise in the active stage.<sup>36</sup> The mechanical stretch of cord over an internal gibbus results in delayed neurological issues even after the healing of TB. Late-onset neurological deficit due to ossification of ligamentum flavum proximal to the kyphosis is rare, but has been observed and believe to be due to exaggerated movements.<sup>37</sup>

### Atypical Spinal Tuberculosis

Patients without the typical clinical features of axial pain, constitutional symptoms, kyphosis, or typical radiological features (paradiscal) are considered as having atypical presentation.<sup>38</sup> Batson’s perivertebral venous plexus plays a role in skip lesions of spinal TB and is believed to be one cause for atypical presentations. Concentric vertebral collapse, isolated neural arch involvement, ivory vertebra, circumferential vertebral involvement, contiguous or skip vertebral lesions, and multifocal osseous involvement are some atypical radiographic patterns. Atypical clinical presentations such as prolapsed intervertebral disc as reported by Pande and Babhulkar, isolated cold abscess without bony involvement, and intraspinal pure soft tissue granulomas do occur.<sup>39</sup> Meningeal, neural, and perineural tissue involvement are rare, but easily identifiable in magnetic resonance imaging (MRI) and can cause features of compressive myelopathy without radiographic bony destruction.<sup>40</sup>



**Figure 2.** (A, B) Plain radiography of a 52-year-old female with active cervical spinal TB and cervical kyphosis. (C, D) T2 weighted sagittal and parasagittal image showing a huge prevertebral abscess and posterior abscess spreading along and confined within posterior longitudinal ligament with cord compression. (E, F) Coronal and axial trim images demonstrating asymmetrical paravertebral abscess more toward the left side. (G, H, I) Axial, coronal, and sagittal images showing fragmentary and osteolytic lesions with near complete destruction of C4 vertebra. (J, K) One-year follow-up lateral and AP X-ray following anterior corpectomy and iliac crest autografting with posterior instrumentation showing restoration of cervical lordosis and excellent healing.

## Diagnosis

Growth of *Mycobacterium* in culture specimens obtained from the infected tissue is the single most confirmatory diagnostic test of spinal TB and is considered the gold standard method. However, due to its very poor sensitivity, histopathological studies demonstrating classical granulomas and staining of smears to identify acid fast bacilli (AFB) are considered as reference standards for all other diagnostic modalities. Apart from indirect serological markers of inflammation, immunological tests have also been used with varied results. Molecular diagnostics are frequently being used because of its rapidity and reliability.

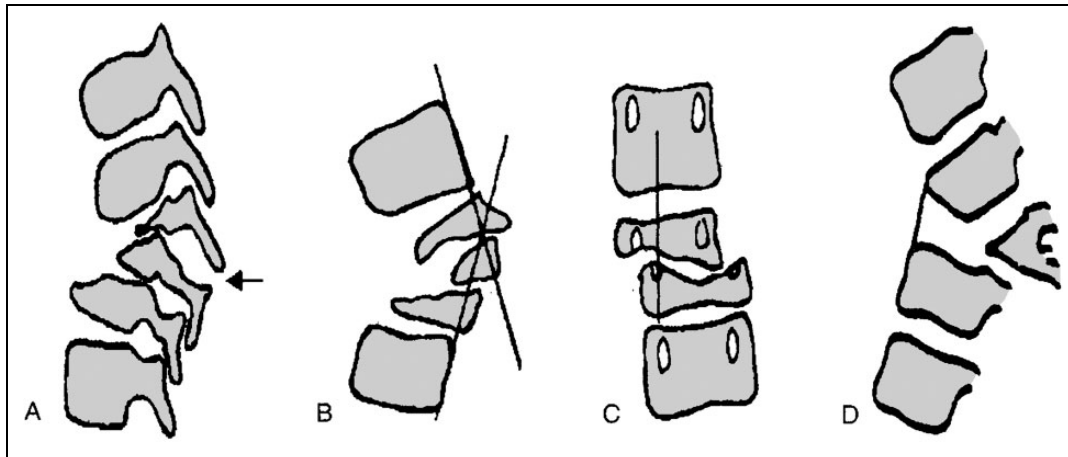
## Imaging

Plain radiographs have no role in early diagnosis of spinal TB. Disc space narrowing and rarefaction of vertebral end plates can be identified as the disease progresses and further destruction leading to kyphosis and instability can be made out only in late stages. It is useful in assessing coronal and sagittal alignment. Sixty percent to 70% of spinal TB may have an active pulmonary lesion, and thus chest radiography is essential.<sup>41</sup>

Computed tomography (CT) demonstrates vertebral destruction well before plain radiographs and is extremely useful in identifying extent of bony destruction, posterior column involvement, junctional pathologies, joint involvement, and regional stability.<sup>42</sup> Four types of destruction have been noticed in decreasing order of frequency: fragmentary, osteolytic, subperiosteal, and localized sclerotic lesion.<sup>43</sup> CT is also of immense value in obtaining percutaneous CT-guided biopsy for establishing diagnosis.<sup>44</sup>

MRI has been the imaging modality of choice as it has been able to detect earliest changes. Gadolinium-enhanced MRI further helps in differentiating TB from other causes of infective spondylodiscitis.<sup>45,46</sup> The extent of soft tissue involvement, spread of abscess, and neural compression are best visualized in MRI. Whole spine screening aids in identifying skip lesions (Figure 4). MRI is also of immense value in assessing the response to treatment.<sup>47</sup>

Nuclear imaging by 18F-fluorodeoxyglucose (18F-FDG) labelled positron emission tomography (PET) scan helps in real-time assessment of disease activity, compared with CT and MRI, as 18F-FDG is known to accumulate in inflammatory cells such as neutrophils and activated macrophages at the site



**Figure 3.** The “spine at risk” signs to identify children at risk for severe deformity include: (A) separation of facet joints in lateral radiographs which indicates instability, (B) retropulsion of the posterior part of affected vertebra, (C) lateral translation of vertebrae in the antero-posterior radiograph, and (D) toppling of one vertebra over the other vertebra. Here, a line drawn from the anterior surface of the caudal normal vertebra crosses the mid-point of the anterior surface of the cranial normal vertebra.

of inflammation.<sup>48</sup> However, none of the imaging options are reliable in distinguishing spinal infection and neoplasm, making histopathological examination mandatory to confirm the diagnosis or at least rule out neoplasm.<sup>49</sup>

### Laboratory Investigations

Erythrocyte sedimentation rate (ESR) is a sensitive marker of infection and can be used to monitor therapeutic response, but its low specificity is a concern. Usually in TB, ESR is  $>20$  mm/h and decreases as healing progresses. C-reactive protein (CRP) is more specific for acute infection rather than TB.<sup>50,51</sup> Serological examination of IgM and IgG levels, which are high in active and chronic infective stages of TB, respectively, would not be able to differentiate between active and healed disease or between natural infection and BCG vaccinated individuals; thus, they are not recommended.<sup>52,53</sup>

Though the WHO recommends usage of Mantoux tuberculin skin test in low-income countries, it is of no diagnostic value in endemic areas and may also be false negative in immunodeficient individuals and hence is of some use only in latent TB. Two other tests used in latent TB are interferon- $\gamma$  (IFN- $\gamma$ ) release assays and whole blood-based enzyme-linked immunosorbent assays, measuring the amount of IFN- $\gamma$  produced in response to *Mycobacterium tuberculosis* antigens.<sup>54</sup> Though they are specific and differentiate between natural TB and BCG vaccination, these tests cannot differentiate between latent TB and active TB.<sup>55,56</sup> The WHO has urged countries to ban inaccurate and unapproved blood tests and instead rely on accurate microbiological or molecular tests.<sup>57</sup>

The significance of tissue diagnosis is well established and it would be ideal to subject tissue samples obtained to AFB staining, AFB culture and aerobic culture along with antibiotic sensitivity testing by line probe assays, polymerase chain reaction (PCR), and other molecular diagnostic tests apart from histopathological examination.<sup>58</sup> BACTEC radiometric

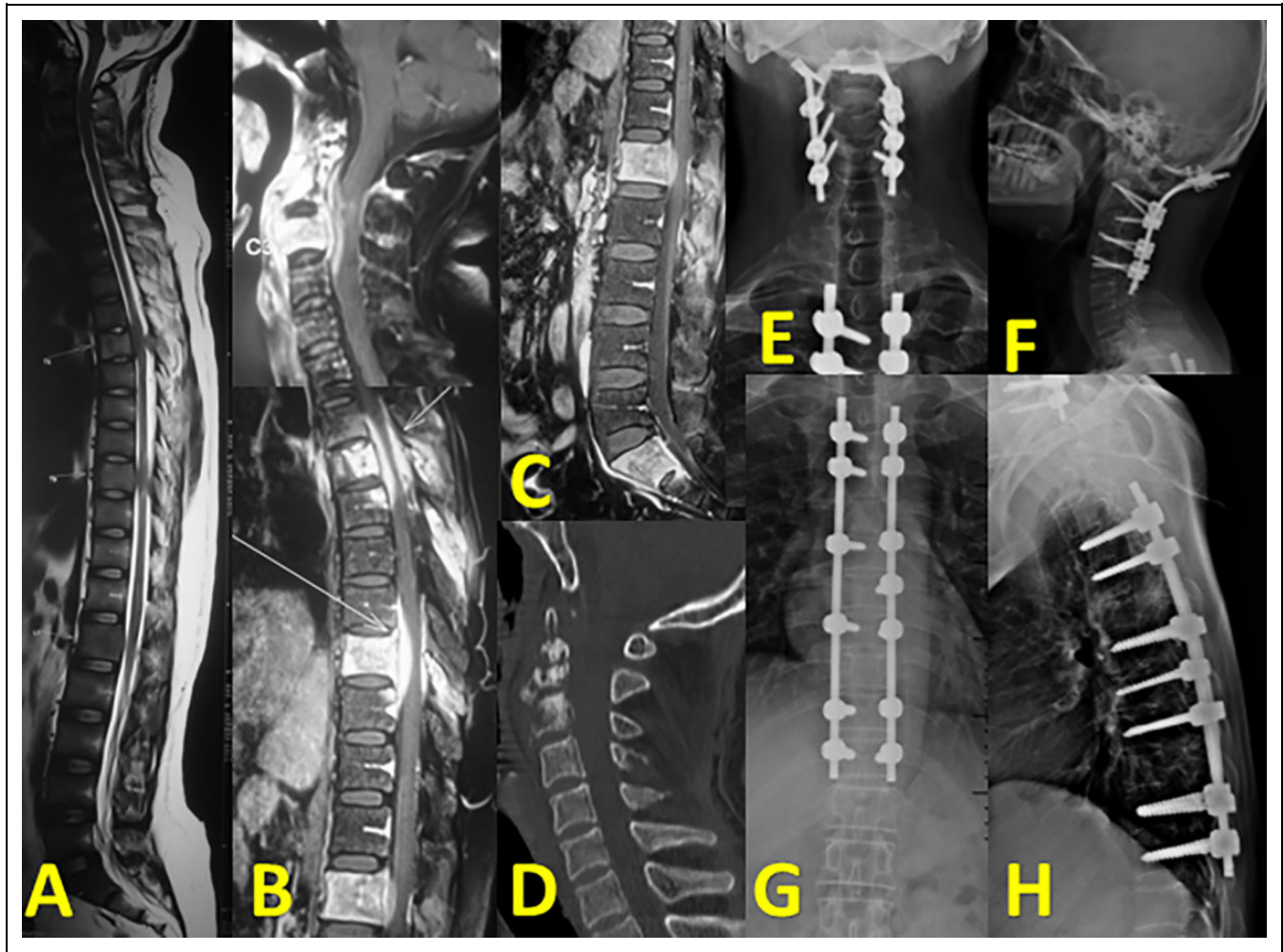
culture takes 2 weeks, less than the 4 weeks of incubation time in standard AFB culture techniques.<sup>59</sup> Gene Xpert MTB/RIF test is a fully automated diagnostic test that yields results as early as 90 minutes, and has a sensitivity of 95.6% and specificity of 96.2%.<sup>60,61</sup> In addition, it also aids in identifying resistance to rifampicin.

In March 2017, the WHO recommended the use of a next-generation Xpert MTB/RIF assay, named Xpert MTB/RIF Ultra, as they found it, to have better detection rates of *Mycobacterium tuberculosis* in specimens with low numbers of bacilli, especially in smear-negative, culture-positive specimens, in pediatric specimens and in extrapulmonary specimens.<sup>62</sup> The classical histological features of TB are the presence of caseative necrosis, epithelioid cell granuloma, and Langhans giant cells and have been reported in around 72% to 97%.<sup>63,64</sup> To summarize, the diagnosis of spinal TB is based on correlating clinical and classical imaging findings on MRI and is confirmed by either culture and sensitivity, Gene Xpert PCR test, or by histopathological evidence. The diagnostic battery of investigation currently available and its usefulness in diagnosing or monitoring spinal TB is listed in Table 1 along with their reported sensitivity and specificity.

### Management of Spinal TB

#### Chemotherapy

Multidrug antitubercular treatment (ATT) is the mainstay of treatment in both complicated and uncomplicated TB.<sup>65-68</sup> Multidrug ATT is essential, as varying categories of bacilli exist in a lesion. They may exist as intracellular, extracellular, dormant, or rapidly multiplying forms and each has different growth and metabolic properties.<sup>69</sup> In addition, multidrug ATT reduces instances of drug resistance.<sup>70</sup> The duration of chemotherapy for spinal TB has been long debated, and the WHO recommends 9 months of treatment where 4 drugs—isoniazid,



**Figure 4.** (A) Whole spine MRI screening showing multifocal lesions. (B, C) All suspected levels enhanced significantly with smooth uniform rims after contrast administration suggestive of TB. (D) Sagittal CT image with severe destruction of C1 and C2. (E, F) 1-year follow-up AP and lateral radiographs following occipitocervical stabilization. (G, H) Posterior thoracic stabilization done at the same stage.

rifampicin, pyrazinamide, ethambutol, or streptomycin—are administered in the “initiation” phase for 2 months, followed by isoniazid and rifampicin for 7 months in the “continuation” phase. Again there is controversy over superiority of “daily dose” regime over alternate day “intermittent regime.”<sup>71</sup>

The second-line ATT drugs (kanamycin, amikacin, capreomycin, levofloxacin, etc) have to be used judiciously as they have more side effects and are expensive than the standard first-line ATT drugs (isoniazid [INH], rifampicin, ethambutol, pyrazinamide).<sup>72</sup> A 2013 meta-analysis of both clinical trials and observational studies did not find any difference between Directly Observed Treatment, Short Course (DOTS) and self-administered therapy.<sup>73</sup> However, the WHO and all other TB programs continue to use DOTS as an important strategy in fear of drug resistance.<sup>74</sup> Uncomplicated spinal TB is a medical disease and can be effectively managed by chemotherapy alone, as evident in Figure 5. However, in patients with complicated TB, the combination of medical therapy and surgery will yield optimum results.<sup>75</sup>

### Drug-Resistant TB

MDR-TB is that which is resistant to INH and rifampicin. Primarily it occurs because of improper treatment, but resistant strains can also be communicable. Extensively drug-resistant TB (XDR-TB) is when there is resistance to INH and rifampicin, along with resistance to any fluoroquinolone and at least one injectable second-line anti-TB drugs.<sup>76,77</sup> Pawar et al suggested the following 5 predictors for successful outcome in MDR-TB: (1) progressive clinical improvement at 6 months following chemotherapy, (2) radiographic improvement during treatment, (3) disease with strains that are resistant to less than 3 ATT drugs, (4) use of less than 4 second-line drugs in treatment, and (5) no changes of regimen during treatment.<sup>78</sup> In 2009, the term “totally drug-resistant tuberculosis” (TDR-TB) for TB strains that showed in vitro resistance to all first- and second-line drugs tested was proposed by Velayati et al.<sup>79</sup> It would be more appropriate to get an opinion or refer such cases to an infectious disease specialist who is ought to have

**Table 1.** The Diagnostic Investigations Commonly Used in Spinal Tuberculosis.

No.	Investigation	Sensitivity	Specificity	Comments
1	Plain radiography	15%	NA	Changes prominent only after 30% of destruction
2	MRI	100%	80%	Gold standard imaging technique
3	CT	100%	NA	Fragmentary > osteolytic > subperiosteal > localized
4	Nuclear scan; FDG-PET scan	NA	NA	Does not differentiate from malignancy and other infections; detects activity and treatment response
5	ESR > 20 mm	60% to 90%	NA	Serial values show gradual drop after initiating treatment; second peak in case of reactivation
6	CRP	71%	NA	Reaches normal levels after 14 days of treatment
7	Mantoux assay	40% to 55%	75%	False positive results in BCG-vaccinated individuals
8	Interferon- $\gamma$	50% to 65%	85%	Latent infection; not useful in endemic regions
9	Gram staining	25% to 75%	99%	Ziehl-Neelsen technique—bright red bacilli; $10^4$ to $10^5$ bacilli/mL required
10	AFB culture	47%	100%	Lowenstein Jensen media, 6-8 weeks, requires $10^1$ to $10^2$ bacilli/mL (live bacilli)
11	BACTEC	56%	100%	4-10 days, radiometric assay
12	PCR	75%	97%	Requires only 1-10 bacilli/mL; useful in paucibacillary state
13	GeneXpert MTB/RIF	82.9%	98%	Results <48 hours+ rifampicin resistance detection
14	Xpert MTB/RIF Ultra	87.8%	94.8%	Useful in HIV associated and smear-negative TB
15	Histopathology	53% to 81%	NA	Epithelioid cell granulomas, Langhans giant cells, caseous necrosis

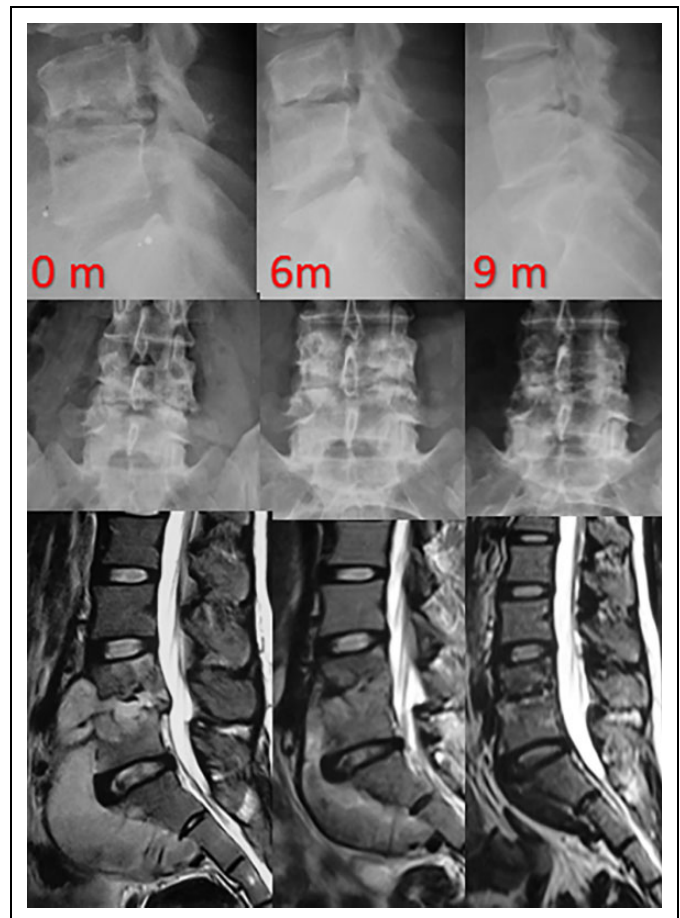
Abbreviations: MRI, magnetic resonance imaging; CT, computed tomography; PET, positron emission tomography; ESR, erythrocyte sedimentation rate; CRP, C-reactive protein; AFB, acid fast bacilli; PCR, polymerase chain reaction; NA, not available.

more experience in treating these resistant strains. Currently, new strategies and drugs (eg, delamanid, bedaquiline, SQ109, and sutezolid) are under trial to tackle these strains, which have been reported from India, Iran, Italy, and South Africa.<sup>80,81</sup>

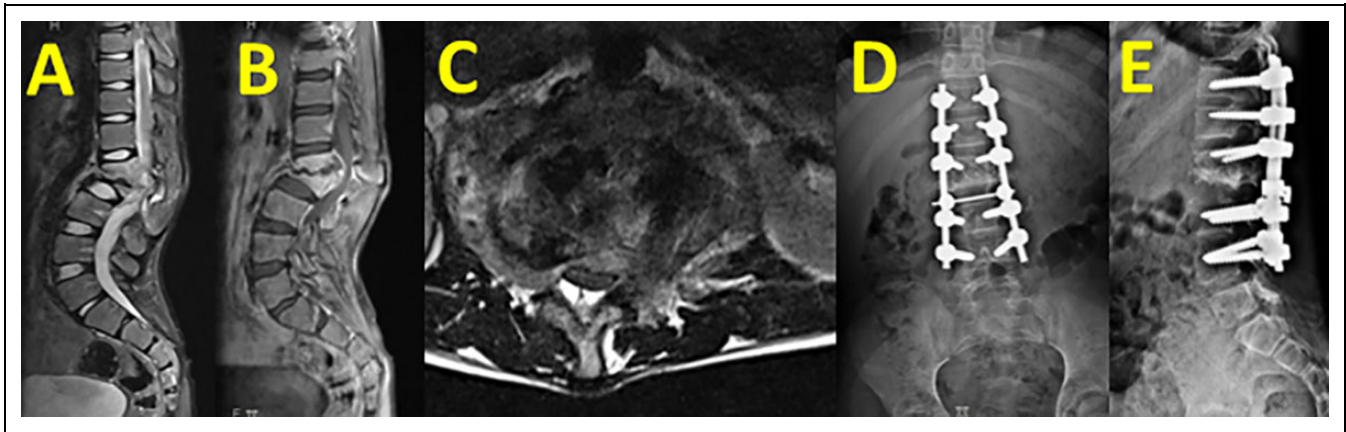
### Surgical Management

Anterior debridement and radical excision of the disease foci along with ATT therapy was the choice of treatment initially, in spite of the associated high morbidities.<sup>82,83</sup> The Medical Research Council after randomly subjecting spinal TB patients to chemotherapy alone, debridement, and radical debridement along with fusion found out similar functional outcomes in all 3 groups.<sup>84</sup> Encouraged by excellent outcomes of multidrug ATT, Tuli introduced the “middle path” regime, where chemotherapy is the fundamental treatment and surgery was advocated only in certain scenarios.<sup>85</sup> This concept is widely accepted and practiced. Certain situations necessitating surgical management are as follows: lack of response to chemotherapy or recurrence, severe weakness at presentation, and static or worsening neural deficit even after initiating chemotherapy, instability, incapacitating pain, and deformities.<sup>33</sup>

The advantages of surgical treatment include adequate sampling for histological confirmation of the diagnosis, early and better healing by removal of the disease focus, correction and prevention of the spinal deformity, reducing the rates of recurrence, and promoting early neurological recovery. Oga et al showed that tubercle bacilli, unlike pyogenic organisms, do not adhere to metal or form any biofilm and therefore surgical instrumentation is safe even in active disease.<sup>86</sup> The fundamentals of surgical management are adequate decompression and debridement, maintenance and reinforcement of stability, and correcting the deformity or halting the progress of deformity.<sup>87</sup>



**Figure 5.** Serial radiographs and MRI images showing good progressive bony healing and complete resolution of cold abscess after receiving 9 months of ambulatory chemotherapy alone.



**Figure 6.** (A, B, C) MRI images of a 40-year-old with active TB and regional kyphosis with severe canal stenosis. (D, E) 1-year follow-up after posterior column shortening and decompression along with fusion procedure employed to achieve deformity correction by posterior approach alone.

The surgical objectives are (1) abscess drainage, (2) debridement of the infected material, or (3) debridement and fusion with or without stabilization.<sup>88</sup> Chemotherapy alone resolves majority of the cold abscesses, and drainage is recommended only in certain scenarios such as respiratory distress or dysphagia, due to a large cervical paravertebral abscess and pseudo-hip flexion deformity due to a large psoas abscess.<sup>26</sup> Debridement alone does not prevent progression of deformity or improve healing rates, especially in children as it may lead to physal damage and rapid deformity progression.<sup>89,90</sup> Debridement and fusion with or without instrumentation is performed by anterior approach, posterior approach, global reconstruction through posterior approach, or combined procedures.

### Anterior Approach

Spinal TB mainly affects anterior column and thus anterior approaches enable adequate exposure, debridement, and reconstruction with ease.<sup>91</sup> Since anterior debridement alone failed to prevent deformity progression, Hodgson et al advocated radical debridement and arthrodesis.<sup>91-93</sup> However, these results were not reproducible in other studies and were associated with respiratory failure, mortality, and graft-related complications. Rajasekaran in his study observed graft slippage, fracture, absorption, or subsidence in 59% of cases with anterior body fusion without instrumentation and these complications were common when the graft spanned 2 or 3 vertebral bodies. Addition of anterior instrumentation in the form of plates, rods, and screws is essential especially when significant kyphosis correction has been attempted.<sup>94,95</sup> Anterior procedure is recommended when posterior structures are intact, and are best avoided in panvertebral disease.

### Posterior Approach

Nowadays posterior procedures are the most commonly performed, due to ease, familiarity of approach, and the lesser learning curve involved. The ability to achieve adequate

exposure for circumferential spinal cord decompression, better deformity control through pedicle screws (Figure 6), and possibility of extension of instrumentation whenever required in addition to avoidance of thoracotomy-related complications through posterior approach is encouraging.<sup>96</sup> Transpedicular decompression and posterior instrumentation facilitates faster recovery and also prevents deformity progression and neurological sequelae in early disease.<sup>97</sup>

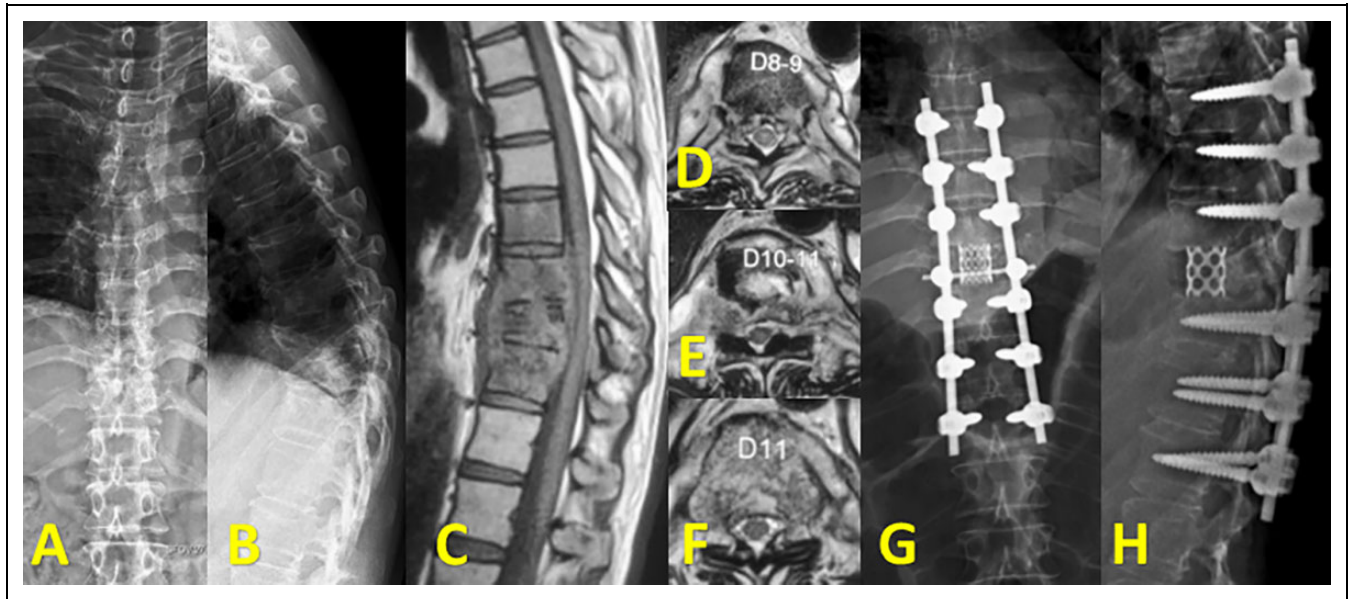
### Global Reconstruction by Posterior Alone Approach

Nowadays, global reconstruction is being advocated through posterior approach alone (Figure 7). Several posterior and posterolateral approaches have been described in the thoracic and lumbar spine where the anterior and lateral column can be reached safely.<sup>98,99</sup> They can be transpedicular, transfacetal, costotransversectomy, or extrapleural approaches.<sup>100,101</sup> Though transpedicular and transfacetal approaches can be used with ease in lumbar spine, reconstruction could be a challenge in thoracic spine without performing costotransversectomy. This approach is an extrapleural approach that allows decompression of spinal cord under direct vision and also allows placement of structural support anteriorly.<sup>102</sup> It can be done either by a posterior midline incision or with a T-shaped incision.<sup>103</sup>

### Combined Approach

The combined approaches play a vital role especially in osteoporotic bones, multiple vertebral body involvement, and in severe kyphotic deformities.<sup>104</sup> Posterior instrumentation with anterior decompression and fusion can be performed in 1 or 2 stages. Anterior debridement removes infected foci and allows for direct neural decompression and rigid anterior reconstruction. Posterior instrumentation enables better deformity correction and reduces the stress on grafts placed anteriorly, thus helping in maintaining sagittal deformity correction.<sup>105</sup> However, due to the high associated morbidities, combined





**Figure 7.** (A, B) AP and lateral radiographs of thoracolumbar spine with complete collapse of T10 vertebra resembling “vertebra plana.” (C, D, E, F) Sagittal and axial T2 weighted images of spine showing contiguous involvement of T8, T9, T10, and T11 with prevertebral abscess and concentric collapse of T10 vertebra. (G, H) AP and lateral postoperative radiographs following global anterior reconstruction through posterior-only approach.

approaches are reserved only in severe destructive lesions and junctional pathologies that are inherently unstable.<sup>106</sup>

### Minimally Invasive Surgery

Recently, minimally invasive surgery (MIS) has been used either as stand-alone or in combination with open procedures.<sup>107,108</sup> The MIS procedures include thoracoscopic debridement, posterolateral endoscopic debridement, and MIS transforaminal interbody fusion.<sup>109,110</sup> Successful outcomes have been reported; however, their role in cases with severe neurological deficits and extensive osseous destruction is questionable.

### Surgery in Healed Tuberculosis

Chemotherapy alone cures spinal TB; however, around 3% to 5% of cases progress to  $\geq 60^\circ$  kyphosis, requiring surgery.<sup>111</sup> Anterior procedures can be successfully employed in healed TB, but it becomes difficult to approach the apex of the curve in severe deformities.<sup>112,113</sup> Combined approaches employ anterior corpectomy, posterior shortening, and instrumentation and anterior and posterior grafting.<sup>114,115</sup> Due to the excess surgical duration, blood loss, and other morbidities, they are best avoided in moderate deformities. The options for posterior deformity correction procedures are transpedicular decancellation procedures, pedicle subtraction osteotomy and posterior closing wedge osteotomy, posterior vertebral column resection, and closing opening wedge osteotomy.<sup>115-117</sup> Rajasekaran et al, in a series of 17 patients, reported that the average kyphosis improved from  $69.2^\circ$

preoperatively to  $32.4^\circ$  postoperatively by closing opening wedge osteotomy.<sup>115,118</sup>

The surgical management of spinal TB should be tailored individually to achieve required outcomes. The factors to be taken into consideration are the age of the patient, location of the bony lesion, presence of medical comorbidities, severity of kyphosis, number of levels affected, region of the spine involved, and experience and preference of the surgeon. The recent trend is for all posterior global reconstruction in the thoracic and lumbar spine; however, anterior debridement and fusion remains the standard of care in lower cervical TB. Combined procedures becomes invaluable in patients with large vertebral defects involving 2 to 3 vertebrae, revision surgeries, and in thoracolumbar TB.<sup>119</sup>

### Conclusion

In spite of the advancements made in early diagnosis and effective management, spinal TB continues to haunt medical professionals especially in South East Asia due to parallel rise in drug-resistant strains. In addition, global migration phenomenon has now opened up the doors for this communicable disease in developed countries and the constant raise in survivors of chronic medical diseases, and HIV-infected individuals pose them at a high risk for clinically symptomatic disease as they are immunodeficient. The goals of treatment in spinal TB are to eradicate the disease and to prevent and/or correct spinal deformity and neurological deficits. Uncomplicated spinal TB is purely a medical disease. Surgery in spinal TB is directed toward achieving adequate decompression and debridement, maintenance, and reinforcement of stability and halting the

progress of deformity or finally correcting the deformity in healed disease. The unrelenting efforts of the WHO and the improved compliance to multidrug chemotherapy bear credence to this amelioration and has paved way in reducing relapse rate to about 2%.

### Declaration of Conflicting Interests

The author(s) declared no potential conflicts of interest with respect to the research, authorship, and/or publication of this article.

### Funding

The author(s) disclosed receipt of the following financial support for the research, authorship, and/or publication of this article: This Supplement was supported by funding from AOSpine North America.

### References

- Taylor GM, Murphy E, Hopkins R, Rutland P, Chistov Y. First report of *Mycobacterium bovis* DNA in human remains from the Iron Age. *Microbiology*. 2007;153(pt 4):1243-1249.
- Tuli SM. Historical aspects of Pott's disease (spinal tuberculosis) management. *Eur Spine J*. 2013;22(suppl 4):529-538.
- Dobson J. Percivall Pott. *Ann R Coll Surg Engl*. 1972;50:54-65.
- James J. The discovery of the *tubercle bacillus* by Robert Koch: a milestone for 123 years [in Dutch]. *Ned Tijdschr Geneesk*. 2005;149:2921-2926.
- Oettinger T, Jørgensen M, Ladefoged A, Hasløv K, Andersen P. Development of the *Mycobacterium bovis* BCG vaccine: review of the historical and biochemical evidence for a genealogical tree. *Tuber Lung Dis*. 1999;79:243-250.
- McLain RF, Isada C. Spinal tuberculosis deserves a place on the radar screen. *Cleve Clin J Med*. 2004;71:537-539, 543-549.
- Luk KDK. Tuberculosis of the spine in the new millennium. *Eur Spine J*. 1999;8:338-345.
- Pertuiset E, Beaudreuil J, Liote F, et al. Spinal tuberculosis in adults: a study of 103 cases in a developed country, 1980-1994. *Medicine (Baltimore)*. 1999;78:309-320.
- Kulchavenya E. Extrapulmonary tuberculosis: are statistical reports accurate? *Ther Adv Infect Dis*. 2014;2:61-70.
- World Health Organization. Global tuberculosis report 2016. [http://www.who.int/tb/publications/global\\_report/gtbr2016\\_executive\\_summary.pdf?ua=1](http://www.who.int/tb/publications/global_report/gtbr2016_executive_summary.pdf?ua=1). Published 2016. Accessed March 22, 2018.
- World Health Organization, Europe. <https://ecdc.europa.eu/sites/portal/files/media/en/publications/Publications/ecdc-tuberculosis-surveillance-monitoring-Europe-2016.pdf>. Published 2016. Accessed March 22, 2018.
- World Health Organization, South East Asia. Tuberculosis control in South-East Asia region. Annual report 2016. <http://www.searo.who.int/tb/annual-tb-report-2016.pdf?ua=1>. Published 2016. Accessed March 22, 2018.
- International Organization for Migration. World migration report 2015. <http://www.iom.int/world-migration-report-2015>. Accessed September 17, 2017.
- World Health Organization. Tuberculosis (TB). <http://www.who.int/tb/areas-of-work/drug-resistant-tb/en/>. Accessed March 22, 2018.
- World Health Organization. WHO end TB strategy. [http://www.who.int/tb/post2015\\_strategy/en/](http://www.who.int/tb/post2015_strategy/en/). Accessed March 22, 2018.
- Jain AK, Dhammi IK. Tuberculosis of the spine: a review. *Clin Orthop Relat Res*. 2007;460:39-49.
- Schirmer P, Renault CA, Holodniy M. Is spinal tuberculosis contagious? *Int J Infect Dis*. 2010;14:e659-e666.
- Tuli SM. Tuberculosis of the shoulder. In: *Tuberculosis of the Skeletal System*. ed. New Delhi, India: JayPee Brothers Medical; 1993.
- Rasouli MR, Mirkoochi M, Vaccaro AR, Yarandi KK, Rahimi-Movaghgar V. Spinal tuberculosis: diagnosis and management. *Asian Spine J*. 2012;6:294-308.
- Rajasekaran S, Kanna RM, Shetty AJ. Pathophysiology and treatment of spinal tuberculosis. *JBJS Rev*. 2014;2. doi:10.2106/JBJS.RVW.M.00130.
- Jain AK. Tuberculosis of the spine: a fresh look at an old disease. *J Bone Joint Surg Br*. 2010;92:905-913.
- Ansari S, Amanullah F, Ahmad K, Rauniyar RK. Pott's spine: diagnostic imaging modalities and technology advancements. *N Am J Med Sci*. 2013;5:404-411.
- Wibaux C, Moafo-Tiatsop M, Andrei I, et al. Changes in the incidence and management of spinal tuberculosis in a French university hospital rheumatology department from 1966 to 2010. *Joint Bone Spine*. 2013;80:516-519.
- Su SH, Tsai WC, Lin CY, et al. Clinical features and outcomes of spinal tuberculosis in southern Taiwan. *J Microbiol Immunol Infect*. 2010;43:291-300.
- Hayes AJ, Choksey M, Barnes N, Sparrow OC. Spinal tuberculosis in developed countries: difficulties in diagnosis. *J R Coll Surg Edinb*. 1996;41:192-196.
- Bhargava SK, Gupta S. Large retropharyngeal cold abscess in an adult with respiratory distress. *J Laryngol Otol*. 1990;104:157-158.
- Faure E, Souliamas R, Riquet M, et al. Cold abscess of the chest wall: a surgical entity? *Ann Thorac Surg*. 1998;66:1174-1178.
- Mallick IH, Thoufeeq MH, Rajendran TP. Iliopsoas abscesses. *Postgrad Med J*. 2004;80:459-462.
- Oniankitan O, Fianyo E, Kakpovi K, Agoda-Koussema LK, Mijiyawa M. Sacrum Pott's disease: a rare location of spine tuberculosis. *Egypt Rheumatol*. 2104;36:209-211.
- Rajasekaran S, Shanmugasundaram TK. Prediction of the angle of Gibbus deformity in tuberculosis of the spine. *J Bone Joint Surg Am*. 1987;69:503-509.
- Jain AK, Aggarwal PK, Arora A, Singh S. Behaviour of the kyphotic angle in spinal tuberculosis. *Int Orthop*. 2004;28:110-114.
- Jain AK. Treatment of tuberculosis of the spine with neurologic complications. *Clin Orthop Relat Res*. 2002;(398):75-84.
- Shetty A, Kanna RM, Rajasekaran S. TB spine—Current aspects on clinical presentation, diagnosis, and management options. *Semin Spine Surg*. 2016;28:150.
- Rajasekaran S. The natural history of post-tubercular kyphosis in children. Radiological signs which predict late increase in deformity. *J Bone Joint Surg Br*. 2001;83:954-962.
- Rajasekaran S. Buckling collapse of the spine in childhood spinal tuberculosis. *Clin Orthop Relat Res*. 2007;460:86-92.

36. Hodgson AR, Skinsnes OK, Leong CY. The pathogenesis of Pott's paraplegia. *J Bone Joint Surg Am.* 1967;49:1147-1156.
37. Subramani S, Shetty AP, Kanna RM, Shanmuganathan R. Ossified ligamentum flavum causing neurological deficit above the level of post-tuberculous kyphotic deformity. *J Clin Orthop Trauma.* 2017;8:174-177.
38. Babhulkar SS, Tayade WB, Babhulkar SK. Atypical spinal tuberculosis. *J Bone Joint Surg Br.* 1984;66:239-242.
39. Pande KC, Babhulkar SS. Atypical spinal tuberculosis. *Clin Orthop Relat Res.* 2002;(398):67-74.
40. Ahmadi J, Bajaj A, Destian S, Segali HD, Zee CS. Spinal tuberculosis: atypical observations at MR imaging. *Radiology.* 1993; 189:489-493.
41. Dharmalingam M. Tuberculosis of the spine—the Sabah experience. Epidemiology, treatment and results. *Tuberculosis (Edinb).* 2004;84:24-28.
42. Sinan T, Al-Khawari H, Ismail M, Ben-Nakhi A, Sheikh M. Spinal tuberculosis: CT and MRI feature. *Ann Saudi Med.* 2004;24:437-441.
43. Jain R, Sawhney S, Berry M. Computer tomography of vertebral tuberculosis: patterns of bone destruction. *Clin Radiol.* 1993;47: 196-199.
44. Adapon BD, Legada BD Jr, Lim EV, Silao JV Jr, Dalmacio-Cruz A. CT-guided closed biopsy of the spine. *J Comput Assist Tomogr.* 1981;5:73-78.
45. Kim NH, Lee HM, Suh JS. Magnetic resonance imaging for the diagnosis of tuberculous spondylitis. *Spine (Phila Pa 1976).* 1994;19:2451-2455.
46. de Souza CG, Gasparetto EL, Marchiori E, Bahia PRV. Pyogenic and tuberculous discitis: magnetic resonance imaging findings for differential diagnosis. *Radiol Bras.* 2013;46:173-177.
47. Kaila R, Malhi AM, Mahmood B, Saifuddin A. The incidence of multiple level noncontiguous vertebral tuberculosis detected using whole spine MRI. *J Spinal Disord Tech.* 2007;20:78-81.
48. Vorster M, Satheke MM, Bomanji J. Advances in imaging of tuberculosis: the role of 18F-FDG PET and PET/CT. *Curr Opin Pulm Med.* 2014;20:287-293.
49. Rajasekaran S, Jain AK, Shetty AP, Kanna RM, eds. Investigations for spinal tuberculosis: *Spinal Infections and Trauma.* New Delhi, India; Jaypee Brothers Medical; 2011:83-89.
50. Guo LX, Ma YZ, Li HW, Xue HB, Peng W, Luo XB. Variety of ESR and C-reactive protein levels during perioperative period in spinal tuberculosis [in Chinese]. *Zhongguo Gu Shang.* 2010;23: 200-202.
51. Rajasekaran S, Kanna RM, Shetty AP. Spinal tuberculosis. In: Su B, ed. *Textbook of Spine Surgery.* New Delhi, India: Jaypee Brothers Medical; 2016.
52. Jain AK, Jena SK, Singh MP, Dhammi IK, Ramachandran VG, Dev G. Evaluation of clinico-radiological, bacteriological, serological, molecular and histological diagnosis of osteoarticular tuberculosis. *Indian J Orthop.* 2008;42:173-177.
53. Chen CH, Chen YM, Lee CW, Chang YJ, Cheng CY, Hung JK. Early diagnosis of spinal tuberculosis. *J Formos Med Assoc.* 2016;115:825-836.
54. Kumar R, Das RK, Mahapatra AK. Role of interferon gamma release assay in the diagnosis of Pott disease. *J Neurosurg Spine.* 2010;12:462-466.
55. Brodie D, Lederer DJ, Gallardo JS, Trivedi SH, Burzynski JN, Schluger NW. Use of an interferon gamma release assay to diagnose latent tuberculosis infection in foreign-born patients. *Chest.* 2008;133:869-874.
56. Lee JY. Diagnosis and treatment of extra pulmonary tuberculosis. *Tuberc Respir Dis (Seoul).* 2015;78:47-55.
57. Ghanashyam B. Enforcement of the ban on serological tests for TB—where are we? [journalistsagainsttb.org/2013/02/16/enforcement-of-the-ban-on-serological-tests-for-tb-where-are-we/](http://journalistsagainsttb.org/2013/02/16/enforcement-of-the-ban-on-serological-tests-for-tb-where-are-we/). Published February 16, 2013. Accessed March 22, 2018.
58. Rajasekaran S, Kanna RM, Shetty AP. Granulomatous infections of the spine. In: Chapman MW, ed. *Chapman's Text of Orthopedic Surgery.* New Delhi, India: Jaypee Brothers Medical; 2016.
59. Cruciani M, Scarparo C, Malena M, Bosco O, Serpelloni G, Mengoli C. Meta-analysis of BACTEC MGIT 960 and BACTEC 460 TB, with or without solid media, for detection of mycobacteria. *J Clin Microbiol.* 2004;42:2321-2325.
60. Maynard-Smith L, Larke N, Peters JA, Lawn SD. Diagnostic accuracy of the Xpert MTB/RIF assay for extra pulmonary and pulmonary tuberculosis when testing non-respiratory samples: a systematic review. *BMC Infect Dis.* 2014;14:709.
61. Steingart KR, Sohn H, Schiller I, et al. Xpert® MTB/RIF assay for pulmonary tuberculosis and rifampicin resistance in adults. *Cochrane Database Syst Rev.* 2013;(1):CD009593.
62. World Health Organization. Tuberculosis (TB). Next-generation Xpert® MTB/RIF ultra assay recommended by WHO. [who.int/tb/features\\_archive/Xpert-Ultra/en/](http://who.int/tb/features_archive/Xpert-Ultra/en/). Published March 24, 2017. Accessed March 22, 2018.
63. Lifeso RM, Weaver P, Harder EH. Tuberculous spondylitis in adults. *J Bone Joint Surg Am.* 1985;67:1405-1413.
64. Alothman A, Memish ZA, Awada A, et al. Tuberculous spondylitis: analysis of 69 cases from Saudi Arabia. *Spine (Phila Pa 1976).* 2001;26:E565-E570.
65. Rajasekaran S, Khandelwal G. Drug therapy in spinal tuberculosis. *Eur Spine J.* 2013;22(suppl 4):587-593.
66. Wilkinson MC. Tuberculosis of the spine treated by chemotherapy and operative debridement. A long-term follow-up study. *J Bone Joint Surg Am.* 1969;51:1331-1342.
67. Zhang Z, Luo F, Zhou Q, Dai F, Sun D, Xu J. The outcomes of chemotherapy only treatment on mild spinal tuberculosis. *J Orthop Surg Res.* 2016;11:49. doi:10.1186/s13018-016-0385-y.
68. Jain A, Ravi S. Tuberculosis of spine. In: Weinstein SL, Buckwalter JA, eds. *Turek's Orthopaedics.* Philadelphia, PA: Wolters Kluwer; 2016:1412-1617.
69. Dickinson JM, Mitchison DA. In vitro studies on the choice of drugs for intermittent chemotherapy of tuberculosis. *Tubercle.* 1966;47:370-380.
70. de Medeiros RS, Abdo RCT, de Paula FC, et al. Treatment of spinal tuberculosis: conservative or surgical? *Acta Ortop Bras.* 2007;15:128-131.
71. World Health Organization. Tuberculosis (TB). Guidelines for treatment of drug-susceptible tuberculosis and patient care (2017 update). [http://www.who.int/tb/publications/2017/dstb\\_guidance\\_2017/en/](http://www.who.int/tb/publications/2017/dstb_guidance_2017/en/). Published April 2017. Accessed March 22, 2018.

72. Jawahar MS. Current trends in chemotherapy of tuberculosis. *Indian J Med Res.* 2004;120:398-417.
73. Cox HS, Morrow M, Deutschmann PW. Long term efficacy of DOTS regimens for tuberculosis: systematic review. *BMJ.* 2008; 336:484-487.
74. Volmink J, Garner P. Directly observed therapy for treating tuberculosis. *Cochrane Database Syst Rev.* 2003;(1):CD003343.
75. Valsalan R, Purushothaman R, Raveendran M, Zacharia B, Surendran S. Efficacy of directly observed treatment short-course intermittent regimen in spinal tuberculosis. *Indian J Orthop.* 2012;46:138-144.
76. Prasad R, Gupta N. MDR and XDR tuberculosis. In: *Multidrug Resistance: Diagnosis and Treatment. 1st ed.* New Delhi, India: Jaypee Brothers Medical; 2015:92-111.
77. Gandhi NR, Moll A, Sturm AW, et al. Extensively drug-resistant tuberculosis as a cause of death in patients co-infected with tuberculosis and HIV in a rural area of South Africa. *Lancet.* 2006;368: 1575-1580.
78. Pawar UM, Kundnani V, Agashe V, Nene A. Multidrug-resistant tuberculosis of the spine—is it the beginning of the end? A study of twenty-five culture proven multidrug-resistant tuberculosis spine patients. *Spine (Phila Pa 1976).* 2009;34:E806-E810.
79. Velayati AA, Masjedi MR, Farnia P, et al. Emergence of new forms of totally drug-resistant tuberculosis bacilli: super extensively drug-resistant tuberculosis or totally drug-resistant strains in Iran. *Chest.* 2009;136:420-425.
80. Mukherjee JS, Rich ML, Socci AR, et al. Programmes and principles in treatment of multidrug-resistant tuberculosis. *Lancet.* 2004;363:474-481.
81. Parida SK, Axelsson-Robertson R, Rao MV, et al. Totally drug-resistant tuberculosis and adjunct therapies. *J Intern Med.* 2015; 277:388-405.
82. Hodgson AR, Stock FE. Anterior spinal fusion a preliminary communication on the radical treatment of Pott's disease and Pott's paraplegia. *Br J Surg.* 1956;44:266-275.
83. Seddon HJ. Pott's paraplegia: prognosis and treatment. *Br J Surg.* 1935;22:769-799.
84. A controlled trial of six-month and nine-month regimens of chemotherapy in patients undergoing radical surgery for tuberculosis of the spine in Hong Kong. Tenth report of the Medical Research Council Working Party on Tuberculosis of the Spine. *Tubercle.* 1986;67:243-259.
85. Tuli SM. Results of treatment of spinal tuberculosis by "middle-path" regime. *J Bone Joint Surg Br.* 1975;57:13-23.
86. Oga M, Arizona T, Takasita M, Sugioka Y. Evaluation of the risk of instrumentation as a foreign body in spinal tuberculosis. Clinical and biologic study. *Spine (Phila Pa 1976).* 1993;18:1890-1894.
87. Rezai AR, Lee M, Cooper PR, Errico TJ, Koslow M. Modern management of spinal tuberculosis. *Neurosurgery.* 1995;36: 87-98.
88. Al Sebai MWM, Madkour MM, Al Moutaery KR. Surgical management of spinal tuberculosis. In: Madkour MM, ed. *Tuberculosis.* Berlin, Germany: Springer; 2004:493-534.
89. Rajasekaran S, Soundarapandian S. Progression of kyphosis in tuberculosis of the spine treated by anterior arthrodesis. *J Bone Joint Surg Am.* 1989;71:1314-1323.
90. Rajasekaran S, Shetty PA, Dheenadhayalan J, Reddy SJ, Babu NJ, Kishen T. Morphological changes during growth in healed childhood spinal tuberculosis: a 15-year prospective study of 61 children treated with ambulatory chemotherapy. *J Pediatr Orthop.* 2006;26:716-724.
91. Hodgson AR, Stock FE, Fang HS, Ong GB. Anterior spinal fusion: the operative approach and pathological findings in 412 patients with Pott's disease of the spine. *Br J Surg.* 1960; 48:172-178.
92. Tuli SM. Tuberculosis of the spine: a historical review. *Clin Orthop Relat Res.* 2007;460:29-38.
93. Govender S, Parbhoo AH. Support of the anterior column with allografts in tuberculosis of the spine. *J Bone Joint Surg Br.* 1999; 81:106-109.
94. Benli IT, Kaya A, Acaroglu E. Anterior instrumentation in tuberculous spondylitis: is it effective and safe? *Clin Orthop Relat Res.* 2007;460:108-116.
95. Christodoulou AG, Givissis P, Karataglis D, Symeonidis PD, Pournaras J. Treatment of tuberculous spondylitis with anterior stabilization and titanium cage. *Clin Orthop Relat Res.* 2006;444:60-65.
96. Chen YC, Chang MC, Wang ST, Yu WK, Liu CL, Chen TH. One-stage posterior surgery for treatment of advanced spinal tuberculosis. *J Chin Med Assoc.* 2003;66:411-417.
97. Lee SH, Sung JK, Park YM. Single-stage transpedicular decompression and posterior instrumentation in treatment of thoracic and thoracolumbar spinal tuberculosis: a retrospective case series. *J Spinal Disord Tech.* 2006;19:595-602.
98. Mizuno S. Posterior approaches in spondylotomy for spinal tuberculosis [in Japanese]. *Seikei Geka.* 1967;18:876-882.
99. Shang H, Wang DY, Wen GH. I-Stage surgical treatment for thoracolumbar spinal tuberculosis with kyphosis. *Chin Gen Pract.* 2010;32:042.
100. Botha AH, Davis JH. Costotransversectomy in thoracic spinal tuberculosis. *SA Orthop J.* 2016;15:83-86.
101. Jain AK, Dhammi IK, Jain S, Kumar J. Simultaneously anterior decompression and posterior instrumentation by extrapleural retroperitoneal approach in thoracolumbar lesions. *Indian J Orthop.* 2010;44:409-416.
102. Jain AK, Dhammi IK, Prashad B, Sinha S, Mishra P. Simultaneous anterior decompression and posterior instrumentation of the tuberculous spine using an anterolateral extrapleural approach. *J Bone Joint Surg Br.* 2008;90:1477-1481.
103. Moon MS. Development in the management of tuberculosis of the spine. *Curr Orthop.* 2006;20:132-140.
104. Chen WJ, Wu CC, Jung CH, Chen LH, Niu CC, Lai PL. Combined anterior and posterior surgeries in the treatment of spinal tuberculous spondylitis. *Clin Orthop Relat Res.* 2002; (398):50-59.
105. Turgut M. Spinal tuberculosis (Pott's disease): its clinical presentation, surgical management, and outcome. A survey study on 694 patients. *Neurosurg Rev.* 2001;24:8-13.
106. Talu U, Gogus A, Ozturk C, Hamzaoglu A, Domanic U. The role of posterior instrumentation and fusion after anterior radical debridement and fusion in the surgical treatment of spinal tuberculosis: experience of 127 cases. *J Spinal Disord Tech.* 2006;19: 554-559.

107. Ito M, Sudo H, Abumi K, et al. Minimally invasive surgical treatment for tuberculous spondylodiscitis. *Minim Invasive Neurosurg.* 2009;52:250-253.
108. Kandwal P, Garg B, Upendra B, Chowdhury B, Jayaswal A. Outcome of minimally invasive surgery in the management of tuberculous spondylitis. *Indian J Orthop.* 2012;46:159-164. doi:10.4103/0019-5413.93680.
109. Kapoor SK, Agarwal PN, Jain BK Jr, Kumar R. Video-assisted tharacoscopic decompression of tubercular spondylitis: clinical evaluation. *Spine (Phila Pa 1976).* 2005;30:E605-E610.
110. Jayaswal A, Upendra B, Ahmed A, Chowdhury B, Kumar A. Video-assisted tharacoscopic anterior surgery for tuberculous spondylitis. *Clin Orthop Relat Res.* 2007;460:100-107.
111. Rajasekaran S. Natural history of Pott's kyphosis. *Eur Spine J.* 2013;22(suppl 4):634-640.
112. Grevitt M, Kamath V, Avadhani A, Rajasekaran S. Correction of thoracic kyphosis with Ponte osteotomy. *Eur Spine J.* 2010;19:351-352.
113. Kalra KP, Dhar SB, Shetty G, Dhariwal Q. Pedicle subtraction osteotomy for rigid post-tuberculous kyphosis. *J Bone Joint Surg Br.* 2006;88:925-927.
114. Dalvie SS, Laheri VJ. Closed-wedge spinal osteotomy for the correction of post-tubercular kyphosis in children. *J Bone Joint Surg Br.* 2000;82:283-284.
115. Kanna RM, Shetty AP, Rajasekaran S. Surgical management of Pott's spine induced kyphosis in older children or adults. *Curr Orthop Pract.* 2017;28:15-22.
116. Rajasekaran S, Shanmugasundaram TK, Prabhakar R, Dheenadhayalan J, Shetty AP, Shetty DK. Tuberculous lesions of the lumbosacral region: a 15-year follow-up of patients treated by ambulant chemotherapy. *Spine (Phila Pa 1976).* 1998;23:1163-1167.
117. Rajasekaran S, Kanna RMP, Shetty AP. Closing-opening wedge osteotomy for severe, rigid, thoracolumbar post-tubercular kyphosis. *Eur Spine J.* 2011;20:343-348.
118. Rajasekaran S, Vijay K, Shetty AP. Single stage closing-opening wedge osteotomy of spine to correct severe post-tubercular kyphotic deformities of the spine: a 3-year follow-up of 17 patients. *Eur Spine J.* 2010;19:583-592.
119. Wang LJ, Zhang HQ, Tang MX, Gao QL, Zhou ZH, Yin XH. Comparison of three surgical approaches for thoracic spinal tuberculosis in adult: minimum 5-year follow up. *Spine (Phila Pa 1976).* 2017;42:808-817.