

Occipital Neuralgia from C2 Cavernous Malformation

Abstract

A unique case is presented of chronic occipital neuralgia (ON) caused by cavernous malformation (CM) in the intramedullary C2 spinal cord and subsequent pain relief and remodeling of allodynic pain following dorsal root rhizotomy. A 53-year-old male presented with a 30-year history of chronic allodynic, paroxysmal lancinating pain in the greater and lesser occipital nerves. Typically, the pain was aggravated with neck extension and head movement. Magnetic resonance imaging showed a CM in the right posterolateral side of the intramedullary C2 cord. Considering potential risks associated with removal of the lesion, intradural C1-3 dorsal root rhizotomy with dentate ligament resection was performed. The paroxysmal lancinating pain of ON was significantly alleviated, and the remodeling of the extent of allodynic pain was noted after C1-3 dorsal root rhizotomy. These changes gradually occurred during the second postoperative month, and this effect was maintained for 24 months postoperatively. Significant reduction in chronic allodynic pain of secondary ON caused by cervicomedullary CM involving central sensitization in the trigeminocervical complex was observed with reduction of irritating, afferent input with C1-C3 dorsal root rhizotomy.

Keywords: Cavernous malformation, dorsal root rhizotomy, occipital neuralgia, trigeminocervical complex

Introduction

Although most cases of occipital neuralgia (ON) are considered idiopathic,^[1] they may be related to various potential causes of irritation, which include trauma and vascular, neurogenic, muscular, and osteogenic causes.^[1] Among the vascular causes of secondary ON, C1-2 CM has only been described twice.^[2,3] Both cases presented typical manifestation of neuralgic, lancinating pain of ON.

Cavernous malformations (CMs) are vascular lesions consisting of dilated sinusoidal venous channels lined by a single layer of endothelium and lacking a complete vascular wall.^[4] It has been reported that 10–30% of CMs involve the brain stem and cerebellum and that 5–10% of CMs in the central nervous system arise within the spinal cord particularly at the cervical level.^[5,6] We report a rare case of a patient with chronic ON secondary to CM located in the right posterolateral C2 cervical cord.

Case Report

A 53-year-old male was referred to us because of a 30-year history of allodynic,

paroxysmal lancinating pain in the C2 and C3 nerves in the right occipitoparietal scalp, often radiating to retroauricular and anterolateral neck regions. The pain was distributed high in the C2 dermatome of the occipital scalp [Figure 1a]. Its onset was insidious, and he could not remember any precipitating event 30 years ago. The pain was described as a constant squeezing and crushing sensation, with an intermittent electrical and lancinating sensation.

On examination, marked hyperesthesia, hyperalgesia, and mechanical allodynia were present in the area of pain distribution. No hypesthesia was noted. The intensity of pain was moderate (4–6) on an 11-point numerical rating scale. The intermittent electrical, lancinating pain was aggravated instantly with certain physical activities including neck extension, brief head rotation, and hopping. The patient has rarely been able to perform rope jumping for the prior 30 years. There was no other neurological abnormality. Medical treatment and interventional block were not effective.

Magnetic resonance imaging (MRI) of the cervical spine showed a right intramedullary multilobulated lesion at the C2 level [Figure 2] with a mild contrast enhancement. The characteristic appearance of reticulated core of mixed signal intensity

How to cite this article: Ha Sw, Choi Jg, Son Bc. Occipital neuralgia from C2 cavernous malformation. *Asian J Neurosurg* 2018;13:442-5.

**Sang-woo Ha¹,
Jin-gyu Choi²,
Byung-chul Son^{2,3}**

¹Department of Neurosurgery, Chosun University Hospital, College of Medicine, Chosun University, Gwangju,

²Department of Neurosurgery, Seoul St. Mary's Hospital,

³Catholic Neuroscience Institute, College of Medicine, The Catholic University of Korea, Seoul, Republic of Korea

Address for correspondence:
Prof. Byung-chul Son,
Department of Neurosurgery,
Seoul St. Mary's Hospital,
Catholic Neuroscience Institute,
College of Medicine, The
Catholic University of Korea,
222 Banpo-daero, Seocho-gu,
06591 Seoul, Republic of Korea.
E-mail: sbc@catholic.ac.kr

Access this article online

Website: www.asianjns.org

DOI: 10.4103/1793-5482.181131

Quick Response Code:



This is an open access journal, and articles are distributed under the terms of the Creative Commons Attribution-NonCommercial-ShareAlike 4.0 License, which allows others to remix, tweak, and build upon the work non-commercially, as long as appropriate credit is given and the new creations are licensed under the identical terms.

For reprints contact: reprints@medknow.com

with a surrounding rim of hypointense signal indicating hemosiderin deposit was compatible with a diagnosis of CM.^[5] Considering the high risk related to the lesion site combined with the generally good condition of the patient, C1-C3 dorsal root rhizotomy instead of direct removal was performed to relieve the allodynic pain. To relieve a sudden, incident pain on neck extension and jumping, resection of the dentate ligament and arachnolysis along the right side of C1-3 spinal cord was also performed because tethering of right side of cord might cause a prompt stretching and irritation of the intramedullary CM [Figures 2 and 3].

Immediately, after the operation, the incident allodynic pain on neck extension disappeared completely. There was no sensory change, such as hypesthesia or paresthesia, according to dorsal root rhizotomy. During the next month, the squeezing pain and electrical shock-like intermittent pain progressively decreased by about 50% and the area of mechanical allodynic pain shrunk by about 50% in size and decreased more than 50% in intensity. The electrical

shock-like pain streaming down to the anterolateral neck disappeared and the retroauricular pain moved to a more medial occipital scalp [Figure 1b]. Subsequently, no change occurred in the intensity and distribution of ON during the follow-up of 24 months.

Discussion

Occipital neuralgia secondary to cavernous malformation

The occurrence of ON secondary to CM has only been reported twice.^[2,3] Unlike secondary ON from other causes, such as vascular compression, bony spur, and ligamentous or muscular entrapment, which are the lesions irritating the peripheral occipital nerves or extramedullary intradural course of C2 and C3 dorsal roots, ON from CM may have a different pathophysiology because they are truly central, intramedullary lesions. Including the present case, the location of CMs causing ON was very similar in the three cases: C1-C2, occupying the posterolateral portion of C1-C2 cervical cord corresponding the dorsal horn of the trigeminal nucleus caudalis including dorsal root entry zone [Table 1]. This area corresponds to the trigeminocervical complex (TCC), an anatomical and functional structure that plays a major role in allodynic phenomena during the migraine attack and chronic migraine.^[7,8]

The TCC extends from the medullary dorsal horn of the trigeminal nucleus caudalis to the segments of C2-C3 in the rat, cat, and monkey.^[8] The TCC neurons have convergence of input from dural afferents and cervical afferents in the greater occipital nerve. Convergence of nociceptive afferents along with subsequent central sensitization of TCC neurons provides a physiologic basis for the clinical phenomenon of spread and referred pain by which pain originating from an affected tissue is perceived as originating from a distant receptive field.^[7,8] In line with this pathophysiology, Bruti *et al.*^[2] described a case of a migraine-like headache associated with central sensitization phenomena followed by chronic ON in a patient with bulbocervical CM with subacute bleeding.

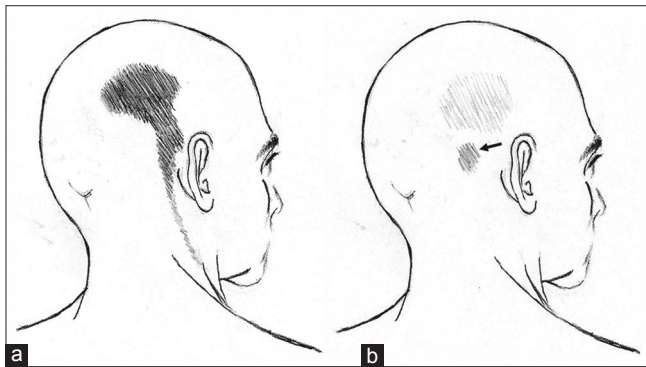


Figure 1: Drawings of pain distribution in a patient with secondary occipital neuralgia caused by high cervical cavernous malformation. The black area indicates the area of occipital neuralgic pain. (a) Preoperative distribution of occipital neuralgia in the high C2 dermatome in the occipital scalp and radiating allodynic pain along the C3 distribution, retroauricular and anterolateral neck. (b) Postoperative distribution of secondary occipital neuralgia. The intensity and extent of constant and allodynic, lancinating pain decreased in C2 dermatome and allodynic radiating pain along the lateral neck in C3 dermatome disappeared. The allodynic pain in the retroauricular area shrank and moved to medial occipital scalp of C2 distribution (arrow)

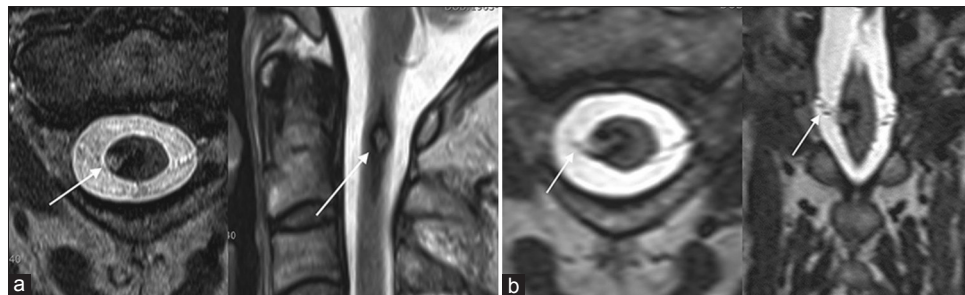


Figure 2: Magnetic resonance imaging findings of occipital neuralgia associated with cavernous hemangioma. (a) T2-weighted axial and sagittal images showing a reticulated core of high signal intensity with a surrounding rim of decreased signal intensity (arrow) indicating the presence of hemosiderin, thus suggesting the diagnosis of cavernous malformation. (b) Axial and coronal multiplanar reconstruction images showing the relationship between the cavernous malformation and C2 rootlets (arrow). Note the location of cavernous malformation at the right posterolateral C1-2 cord segment suggesting involvement of the dorsal horn, the dorsal root entry zone, and the caudalis trigeminal nucleus of C2. Characteristically, the dorsal root of C2 directly attached to the cavernous malformation (arrow)

Table 1: Reports of secondary occipital neuralgia caused by cavernous malformation

Case	Age/sex	Duration	Location of ON	Level of lesion	Location within cord	Associated findings	Trigeminal symptom	Diagnostic modality	Treatment	Prognosis follow-up
Cerato <i>et al.</i> ^[3] 2002	59/female	5 years	Right C2, C3	C1	Right posterolateral	Paresthesia allodynia (+)	(-)	C spine MRI nonenhancing	AMI, CBZP, GON block	Unchanged, 26 months
Bruti <i>et al.</i> ^[2] 2007	32/male	2 weeks	Right C2, C3	Medulla to C1	Right posterolateral	Acute migraine allodynia (+) hiccup	(+) numbness dysesthesia	C spin MRI nonenhancing	AMI	Spontaneous resolution, 6 months
Present case, 2015	51/male	30 years	Right C2, C3	C1-2	Right posterolateral	Pain aggravation with neck extension allodynia (+)	(-)	C-spine MRI nonenhancing	C1-C3 dorsal root rhizotomy no effect to medical tx	24 months 50% relief

AMI – Amitriptyline; CBZP – Carbamazepine; MRI – Magnetic resonance imaging; ON – Occipital neuralgia; Tx – Treatment; GON – Greater occipital nerve

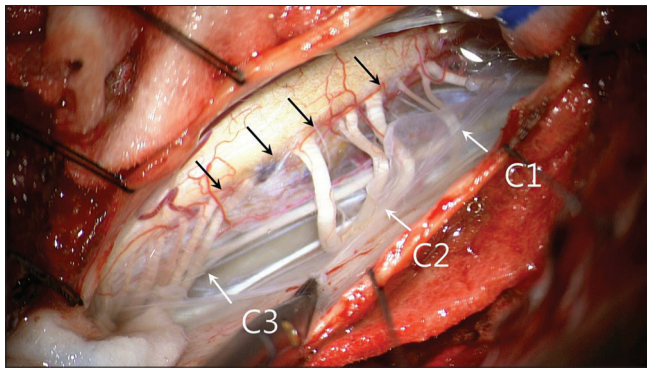


Figure 3: An intraoperative photograph showing the discolored, bulging pial surface of the C2 cord indicating the presence of cavernous malformation (black arrows). Note the extent of hemosiderin staining from C1 to upper C3 (arrows). The involved rootlets entering the cavernous malformation were the lower 2 rootlets of C1, all 3 C2 rootlets, and upper 3 C3 rootlets (white arrows)

Treatment of secondary occipital neuralgia

Treatment of underlying offending lesion is a reasonable approach in case of secondary ON. However, the natural history of CM is characterized as having a fairly benign course up to 21% of patients are asymptomatic.^[9] An acute exacerbation of the symptoms of any clinical pattern of CM is clearly related to hemorrhage. Symptomatic spinal lesions along with brain stem and basal ganglia lesions pose higher surgical risks.^[10] Treatment of high cervical CM has been confined to the two aforementioned case reports of secondary ON from cervicomedullary CM. Cerrato *et al.*^[3] described the case of a 59-year-old woman with a 5-year history of ON caused by CM located in C1 cord without any MRI evidence of rebleeding. The second case reported by Bruti *et al.*^[2] involved acute migraine attack with delayed development of ON from subacute bleeding of cervicomedullary CM. In previous 2-reported cases,^[2,3] symptomatic treatment with amitriptyline and carbamazepine were done with no symptomatic relief.

Spontaneous resolution of acute migrainous headache resolved spontaneously in the second reported case by Bruti *et al.*^[2] Direct surgical removal of C1–C2 CM was avoided for potential neurological risks in both cases.

Conclusions

We report a rare occurrence of ON from cervicomedullary CM involving central sensitization in TCC. Reducing an afferent signal with rhizotomy of corresponding dorsal root combined with division of the dentate ligament was effective in relieving the evoked pain, and resulted in reorganization of chronic neuropathic pain of ON caused by cervicomedullary CM.

Acknowledgment

We sincerely appreciate Professor Takaomi Taira in Tokyo Women's Medical University for his thoughtful comments and strategic guidance in performing dorsal root rhizotomy in intractable ON.

Financial support and sponsorship

Nil.

Conflicts of interest

There are no conflicts of interest.

References

1. Vanelderden P, Lataster A, Levy R, Mekhail N, van Kleef M, Van Zundert J. Occipital neuralgia. *Pain Pract* 2010;10:137-44.
2. Bruti G, Mostardini C, Pierallini A, Villani V, Modini C, Cerbo R. Neurovascular headache and occipital neuralgia secondary to bleeding of bulbo-cervical cavernoma. *Cephalalgia* 2007;27:1074-9.
3. Cerrato P, Bergui M, Imperiale D, Baima C, Grasso M, Giraud M, *et al.* Occipital neuralgia as isolated symptom of an upper cervical cavernous angioma. *J Neurol* 2002;249:1464-5.
4. Clatterbuck RE, Eberhart CG, Crain BJ, Rigamonti D. Ultrastructural and immunocytochemical evidence that an incompetent blood-brain barrier is related to the pathophysiology

- of cavernous malformations. *J Neurol Neurosurg Psychiatry* 2001;71:188-92.
5. Rigamonti D, Drayer BP, Johnson PC, Hadley MN, Zabramski J, Spetzler RF. The MRI appearance of cavernous malformations (angiomas). *J Neurosurg* 1987;67:518-24.
 6. Ogilvy CS, Louis DN, Ojemann RG. Intramedullary cavernous angiomas of the spinal cord: Clinical presentation, pathological features, and surgical management. *Neurosurgery* 2002;31:219-29.
 7. Burstein R, Cutrer MF, Yarnitsky D. The development of cutaneous allodynia during a migraine attack clinical evidence for the sequential recruitment of spinal and supraspinal nociceptive neurons in migraine. *Brain* 2000;123(Pt 8):1703-9.
 8. Bartsch T, Goadsby PJ. The trigeminocervical complex and migraine: Current concepts and synthesis. *Curr Pain Headache Rep* 2003;7:371-6.
 9. Hsu FP, Rigamonti D, Huhn SL. Epidemiology of cavernous malformations. In: Awad I, Barrow DL, editors. *Cavernous Malformations*. Park Ridge, IL: American Association of Neurological Surgeons; 1993. p. 18.
 10. Kivelev J, Laakso A, Niemelä M, Hernesniemi J. A proposed grading system of brain and spinal cavernomas. *Neurosurgery* 2011;69:807-13.