

Contents lists available at [ScienceDirect](http://www.sciencedirect.com)

## International Journal of Surgery Case Reports

journal homepage: [www.casereports.com](http://www.casereports.com)

# A closed loop obstruction caused by entrapment of the fallopian tube and herniation through the broad ligament



Michaela Cameron<sup>a,\*</sup>, Gnananandan Janakan<sup>b</sup>, David Birch<sup>c</sup>, Sarfraz Nazir<sup>d</sup>

<sup>a</sup> Foundation Year Two Doctor, General Surgery, University Hospital Lewisham, London, United Kingdom

<sup>b</sup> ST4 General Surgery, Queen Elizabeth Woolwich, Surgery, Stadium Road, London, United Kingdom,

<sup>c</sup> Consultant General Surgeon, University Lewisham Hospital, London, United Kingdom

<sup>d</sup> Consultant Radiologist, John Radcliffe Hospital, Oxford, United Kingdom

## ARTICLE INFO

### Article history:

Received 26 December 2014

Accepted 5 February 2015

Available online 9 February 2015

### Keywords:

Small bowel obstruction

Broad ligament

Fallopian tube

Internal hernia

## ABSTRACT

A 49-year-old female presented with one week history of severe abdominal pain, vomiting and constipation. Pertinent past surgical history consisted of caesarean section, laparoscopic right fallopian tube cystectomy and myomectomy. There was also recent left mastectomy and adjuvant chemotherapy for breast carcinoma. Clinical examination established a tensely distended abdomen with scanty bowel sounds but no clinical peritonism. Blood tests showed severe acute kidney injury and raised inflammatory markers. Computed tomography without intravenous contrast demonstrated small bowel obstruction of uncertain aetiology but with likely calibre change in the pelvis. At operation, the left fallopian tube had wrapped itself around ischemic bowel. A left salpingo-oophorectomy was performed to release the bowel. On closer inspection, an internal hernia caused by a defect in the broad ligament was diagnosed. This case report describes a differential of atypical small bowel obstruction to be considered when faced with a female acute abdomen.

© 2015 Published by Elsevier Ltd. on behalf of Surgical Associates Ltd. This is an open access article under the CC BY-NC-ND license (<http://creativecommons.org/licenses/by-nc-nd/4.0/>).

## 1. Background

Small bowel obstruction is a common cause of acute surgical admissions. This case report describes a markedly unwell surgical patient with an acute abdomen, which was initially unclear aetiology. A computed tomography (CT) scan with oral contrast was able to localise pathology to the distal small bowel in the left side of the pelvis.

At operation, small bowel obstruction was confirmed to be secondary to a defect in the broad ligament with small bowel herniation with a left dilated fallopian tube, mimicking a band adhesion.

This case highlights a rare source of small bowel obstruction to consider in the female patient. It further re-emphasises the importance of clinical judgement especially when faced with limited diagnostic imaging modalities.

## 2. Case presentation

A 49-year-old woman presented at night to the accident and emergency department with 1-week history of worsening severe

lower abdominal pain and distension with associated symptoms of vomiting and constipation.

Her surgical history consisted of previous breast, obstetric and gynaecological surgeries. She had been recently diagnosed with Grade 3 left breast carcinoma staged as T2N0M0. She underwent a left mastectomy with complete excision margin and 6 cycles of FEC – T chemotherapy; the latter completed 4 weeks prior to this current admission. She had a lower segment caesarean section in 2006 and a laparoscopic right fallopian tube cyst excision and myomectomy in 2002.

Her medication history consisted of herceptin and paracetamol only. There were documented drug allergies to oramorph and ibuprofen.

On general observation, she was tachycardic (P 110 beats/min), hypotensive (90/49 mm Hg) with moderately lower oxygen saturations of 89% on room air.

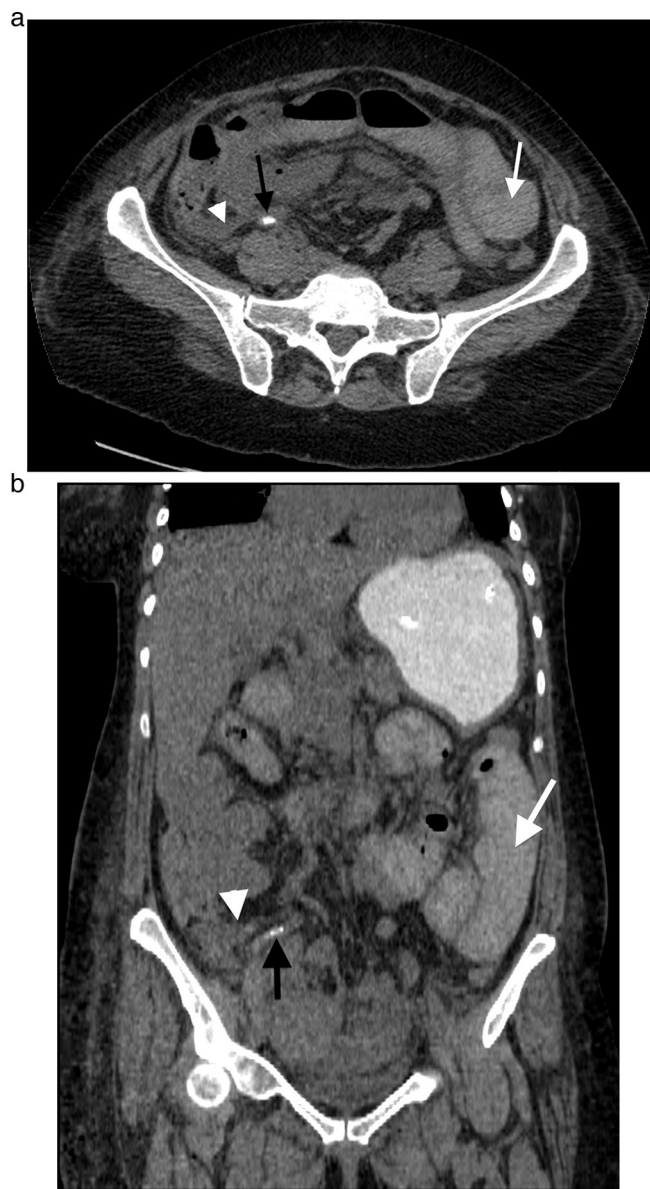
On physical examination, her abdomen was tensely distended but only mildly tender. Bowel sounds were present but scanty. There were no signs of peritoneal irritation. Rectal exam revealed hard stool.

## 3. Investigation

Serum renal biochemistry revealed severe acute kidney injury – eGRF 16 ml/min/1.73 m<sup>2</sup>. Inflammatory markers were raised

\* Corresponding author. Tel.: +44 07958121220.

E-mail addresses: [michaela.cameron@nhs.net](mailto:michaela.cameron@nhs.net) (M. Cameron), [drjanakan@gmail.com](mailto:drjanakan@gmail.com) (G. Janakan), [dbirch1@nhs.net](mailto:dbirch1@nhs.net) (D. Birch), [Sarfraz.Nazir@ouh.nhs.uk](mailto:Sarfraz.Nazir@ouh.nhs.uk) (S. Nazir).



**Fig. 1.** (a) An axial slice from the CT scan demonstrating dilated loops of small bowel (white arrow), collapsed terminal ileum (white arrowhead) and appendicoliths (black arrow). (b) Corresponding coronal plane reformatted image from the CT study demonstrating dilated loops of small bowel (white arrow), collapsed terminal ileum (white arrowhead) and appendicoliths (black arrow).

(WCC  $10.2 \times 10^9/\text{nL}$  and C-reactive protein of 201 ng/mL). Electrolytes and liver function tests were within normal range.

Dilated loops of small bowel were identified on plain film radiography.

An out of hours CT scan was subsequently performed with oral contrast in view of the existing acute renal insult (Fig. 1) and to attempt to delineate the pathology causing this patient's symptoms as this was still unclear.

Due to the lack of intravenous contrast, the on-call duty radiologist acknowledged the reduced sensitivity of the final CT images. There were multiple dilated loops of small bowel (Fig. 1) with an unclear transition point but it appeared to definitely involve distal small bowel in the pelvis. The terminal ileum and appendix looked of normal calibre, though the latter demonstrated several appendicoliths (Fig. 1) together with some mild inflammatory change in the right paracolic gutter and pelvis. The large bowel was collapsed. There was free fluid in the abdomen and pelvis. The radiologist was

unsure of the exact aetiology but a band adhesion in the pelvis was mentioned as a potential differential.

#### 4. Differential diagnosis

- Potential causes of the small bowel obstruction.
- Adhesions related to prior surgery.
- Band adhesion – congenital.
- Internal hernia.
- Ileus secondary to acute appendicitis.

#### 5. Treatment

Initial management involved aggressive fluid resuscitation. The patient, already in pre-renal renal failure, vomited a further 2 L of faeculent fluid. A nasogastric tube was sited which settled the patients' vomiting and improved her abdominal tenderness. A decision was made to slowly flush 500 mL of gastrograffin oral contrast through the nasogastric tube; adhesional obstruction was a possibility and, in some cases, use of gastrograffin can prove to be therapeutic. A CT scan was performed during the night of admission with the aforementioned findings.

Due to deteriorating observations, the patient proceeded to emergency laparotomy. At operation, a 10 cm segment of ischemic and necrotic small bowel was found in the pelvis with dilated bowel proximally. On initial inspection, the cause of the obstruction was thought to be due to the left fallopian tube wrapping itself around the small bowel. A left salpingo-oophorectomy was performed as it was felt to be the only way to release the necrotic bowel. After this procedure, the cause of the obstruction was then clearly identified to be a defect in the broad ligament, through which the bowel had originally herniated. Lastly, the non-viable small bowel had to be resected with a primary anastomoses to complete the operation.

#### 6. Outcome

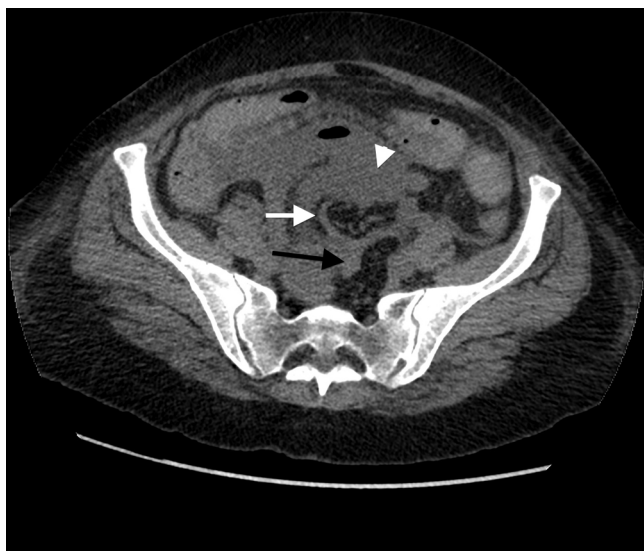Post-operatively, the nasogastric tube was left on free drainage. The patient continued with supportive intravenous fluid therapy and was commenced on a 5-day course of intravenous antibiotics; amoxicillin, metronidazole and gentamicin- the latter was at a reduce dose in line with current hospital guidelines. Post-surgical recovery was uncomplicated and the patient was discharged 7 days later.

#### 7. Discussion

Small bowel obstruction is a common cause for acute surgical admissions. The most common aetiology is adhesions, which are more commonly associated with lower abdominal and pelvic operations [1]. Other causes of small bowel obstruction include malignancy, hernia, inflammatory bowel disease and volvulus [2].

A PubMed engine searching for 'broad ligament' and 'obstruction' generated 50 case reports of small bowel obstruction secondary to a defect in the broad ligament. Zikry reported the first case of intestinal strangulation [3] and a most recent case report of a broad ligament hernia (2014) described successful treatment of viable bowel with laparoscopic techniques [4].

Bugmann et al. described a paediatric case of an ectopic fallopian tube found in the left paracolic gutter, causing local strangulation of the ileum requiring resection. A case of small bowel obstruction has resulted from adherence of the terminal ileum to a torted ovary, which was managed by laparoscopic adhesiolysis [5]. More recently, Pines et al. [6] have described small bowel obstruction due to a pyosalpinx. This was on a background of recurrent pelvic



**Fig. 2.** An axial CT slice from the pelvis at the level of the obstruction. The lack of intravenous contrast hinders interpretation but the dilated afferent (white arrow-head) and collapsed efferent loops (black arrow) at the site of obstruction are shown together with an intervening blind ending structure related to the uterus, which is assumed to be the fallopian tube (white arrow).

inflammatory disease with an intrauterine device in situ but without any previous surgical history.

However, there are no published case reports of small bowel obstruction being caused by both a defect in the broad ligament as well as a fallopian tube acting as a band around the bowel aggravating the obstruction. This double pathology undoubtedly presented a diagnostic challenge for both the on call radiologist and operating surgeon.

Clinical suspicion of small bowel obstruction is normally informed by diagnostic imaging modalities. Plain abdominal radiography may show cardinal signs of small bowel dilatation (>3 cm) and paucity of colon air [1]. However, post intravenous-contrast CT scanning is more effective at identifying the site of obstruction and can also show signs more suggestive of ischemia including bowel mural thickening, mesenteric oedema and asymmetrical enhancement [7].

Furthermore, extrinsic lesions are more clearly depicted with intravenous contrast CT imaging because the bowel wall can be imaged in contrast to its luminal contents. It also allows assessment of the mesenteric vasculature. In this case, the scan was performed in the absence of intravenous due to the acute kidney injury. For the reasons mentioned, this potentially underestimated the degree of bowel ischemia. Distinguishing the left fallopian tube from the small bowel loop presented added difficulties especially as both structures were pathologically dilated and fluid filled.

On review of the CT images for the purpose of writing this case report, there did appear to be a transition point in the region of the left adnexa (Fig. 2) but even this retrospective review still proved

difficult to interpret and could not definitively identify the left salpinx as the causative factor.

Concluding, we present the first case of small bowel obstruction and ischemia secondary to an internal hernia due to both a defect in the broad ligament and wrapping of the fallopian tube around the bowel. This case history also realises the importance of clinical judgement to direct the decision to operate when faced with small bowel obstruction of unknown cause not settling with conservative treatment. If the site and cause of this patient's small bowel obstruction could have been identified pre operatively, then an incision via her previous Pfannenstiel scar could have been considered as an alternative to a standard laparotomy.

#### Conflicts of interest

Nil.

#### Funding

Nil.

#### Author contribution

All authors contributed significantly to the writing of this case report.

#### Consent

Consent was obtained in written and verbal form.

#### References

- [1] M.R. Cox, I.F. Gunn, M.C. Eastman, R.F. Hunt, A.W. Heinz, The operative aetiology and types of adhesion causing small bowel obstruction, *Aust. N. Z. J. Med.* 63 (1993) 848–852.
- [2] A.J. Hayanga, K. Bass-Wilkins, G.B. Bulkley, Current management of small bowel obstruction, *Adv. Surg.* 39 (2005) 1–33.
- [3] A. Zikry, Intestinal strangulation through defects in the broad ligament; report of a case, *J. Egypt. Med. Assoc.* 34 (9–10) (1951) 670–676.
- [4] M. Matsunami, H. Kusanagi, K. Hayashi, S. Yamada, N. Kano, Broad ligament hernia successfully treated by laparoscopy: case report and review of literature, *Asian J. Endosc. Surg.* 7 (4) (2014) 327–329.
- [5] P.H. Bugmann, S. Hanquinet, M.A. Brundler, J. Birraux, B. Genin, C. Le Coultre, Intestinal obstruction caused by an ectopic fallopian tube in a child: case report and literature review, *J. Paediatr. Surg.* 36 (3) (2001) 508–510.
- [6] G. Pines, Y. Klein, A. Ben Arie, S. Machlenkin, H. Kashtan, Small bowel obstruction due to Tubo Ovarian Abscess, *IMAJ* 10 (2008) 481–482.
- [7] C. Vallicelli, F. Coccolini, F. Catena, L. Ansaloni, G. Montori, S. Di Saverio, A. Pinna, Small bowel emergency surgery: Literature's review, *World J. Emerg. Surg.* 6 (2011) 1.

#### Open Access

This article is published Open Access at [sciedirect.com](http://sciedirect.com). It is distributed under the [IJSCR Supplemental terms and conditions](#), which permits unrestricted non commercial use, distribution, and reproduction in any medium, provided the original authors and source are credited.