



Review

Management of intestinal obstruction in advanced malignancy

Henry John Murray Ferguson^{a,*}, Claire Irene Ferguson^b, John Speakman^b, Tariq Ismail^a^a Department of Colorectal Surgery, Queen Elizabeth Hospital, Mindelsohn Way, Birmingham B15 2TH, UK^b Department of Palliative Medicine, Queen Elizabeth Hospital, Mindelsohn Way, Birmingham B15 2TH, UK

HIGHLIGHTS

- We review up-to-date evidence on assessment and management of Malignant Bowel Obstruction (MBO).
- MBO is a complex entity, common in disseminated intra-abdominal malignancy.
- Treatment of true MBO with multilevel obstruction requires multispecialty involvement.
- Surgery is rarely indicated.
- If surgery is indicated, resection and anastomosis is preferable to bypass or stoma formation.

ARTICLE INFO

Article history:

Received 9 July 2015

Received in revised form
27 July 2015

Accepted 30 July 2015

Keywords:

Intestinal obstruction

Malignant

Palliative surgery

Palliative treatment

Terminal care

ABSTRACT

Patients with incurable, advanced abdominal or pelvic malignancy often present to acute surgical departments with symptoms and signs of intestinal obstruction. It is rare for bowel strangulation to occur in these presentations, and spontaneous resolution often occurs, so the luxury of time should be afforded while decisions are made regarding surgery. Cross-sectional imaging is valuable in determining the underlying mechanism and pathology. The majority of these patients will not be suitable for an operation, and will be best managed in conjunction with a palliative medicine team. Surgeons require a good working knowledge of the mechanisms of action of anti-emetics, anti-secretories and analgesics to tailor early management to individual patients, while decisions regarding potential surgery are made. Deciding if and when to perform operative intervention in this group is complex, and fraught with both technical and emotional challenges. Surgery in this group is highly morbid, with no current evidence available concerning quality of life following surgery. The limited evidence concerning operative strategy suggests that resection and primary anastomosis results in improved survival, over bypass or stoma formation. Realistic prognostication and involvement of the patient, care-givers and the multidisciplinary team in treatment decisions is mandatory if optimum outcomes are to be achieved.

© 2015 The Authors. Published by Elsevier Ltd on behalf of IJS Publishing Group Limited. This is an open access article under the CC BY-NC-ND license (<http://creativecommons.org/licenses/by-nc-nd/4.0/>).

1. Introduction

Acute and subacute intestinal obstruction are common occurrences among patients with disseminated abdominal and pelvic malignancies. Malignant bowel obstruction (MBO) is estimated to occur in 10–28.4% of colorectal cancers and 5.5–42% of ovarian malignancies [1]. Overall, it is estimated to occur in 2% of all patients with advanced malignancy [2]. It represents a presentation of recurrence in some patients, and a progression of disease in others.

Consequently, presentation with bowel obstruction has a significant impact upon both patients and their families [3]. This review outlines current management of MBO, expanding upon the medical, interventional and surgical approaches that are used in combination to optimise outcomes in these complex patients.

2. Pathophysiology

True MBO occurs secondary to diffuse peritoneal malignancy causing either direct obstruction, or secondary to malignant adhesions. This represents transcoelomic metastasis. In reality, a mixed picture with mechanical and ileus-related elements is most commonly encountered. Intestinal obstruction can also occur as a primary event, independent of a patient's malignancy, be it from

* Corresponding author.

E-mail addresses: fergusonh@doctors.org.uk (H.J.M. Ferguson), cwalker@doctors.org.uk (C.I. Ferguson), john.speakman@uhb.nhs.uk (J. Speakman), tariq.ismail@uhb.nhs.uk (T. Ismail).

intraoperative adhesions, an obstructed hernia, or intestinal or colonic volvulus. Synchronous and metachronous primary malignancies are relatively common in the cohort of patients with malignancy [4]. It is therefore possible for primary intestinal obstruction to occur from an unrelated colonic or gynaecological malignancy directly obstructing or infiltrating the colon or ileum, or indeed as a result of the patient's unresected primary tumour. MBO most commonly affects the small bowel in isolation (61%), but may also affect only the large bowel (33%) or both simultaneously (20%) [5]. The primary malignant diagnosis is relevant in suggesting the likelihood of MBO as a cause for obstructive symptoms. Cancers of abdominal origin that most frequently produce MBO are those of the ovary (20–50%) [6], colon (10–28%) [7], stomach (6–19%), pancreas (6–13%), bladder (3–10%), and endometrium (3–11%), with breast cancer and melanoma also described [2]. Peritoneal carcinomatosis is often also previously diagnosed, and should raise the index of diagnostic suspicion.

Alongside the primary mechanical process of MBO, there is evidence that the presence of multiple levels of subacute obstruction can lead to an upregulation of serotonin, which causes release of substance P, nitric oxide, acetylcholine, somatostatin, and vasoactive intestinal peptide, which have a further inhibitory effect on gut motility, as well as mediating mucosal oedema [2]. This increases retention of secretions, and raises intraluminal pressure, therefore further complicating the obstructive picture. This, coupled with the confounding effects of opioids, immobility, poor dietary intake and intestinal neural dysfunction (either as a result of the presence of tumour in the bowel wall or as part of a paraneoplastic process), can give rise to the mixed picture of mechanical obstruction and ileus commonly encountered among these patients.

3. Clinical assessment

In established MBO, nausea is present in 100%, vomiting in 87–100%, colicky abdominal pain in 72–80%, pain due to distension in 56–90%, and the absence of stools or emission of flatus in the previous 72 h in 85–93% [2]. However, subacute or intermittent presentations are common, where some or all of these symptoms may be absent, so a high index of suspicion must be held. Generally, the absence of colicky abdominal pain should point towards a biochemical or functional ileus rather than mechanical MBO. Constant pain may represent tumour related pain, abdominal distension or, in the presence of peritonism on examination, intestinal perforation. Within the history, it is also important to assess the patient and caregivers' understanding of the diagnosis and prognosis, as well as gaining a good grasp of the patient's coexisting medical conditions.

Inspection of the abdomen will often show abdominal distension, but other important signs such as previous abdominal incisions and abdominal wall hernias must be noted for accurate diagnostic synthesis. Abdominal palpation may identify a specific tumour mass, or indeed a 'woody' abdomen secondary to diffuse malignant infiltration. Percussion of the abdomen is useful to differentiate the tympanic note of intestinal obstruction, from the dull percussion note in cases where malignant ascites predominates as the cause of abdominal distension. In cases of true intestinal obstruction, hyperactive bowel sounds may be present, as may borborygmi. However, if a paralytic picture predominates, bowel sounds may be absent. This clinical sign is a useful discriminating factor when cross sectional imaging is unavailable. A digital rectal examination is essential, as severe constipation can mimic, worsen or coexist with symptoms of intestinal obstruction. A full rectum should be emptied by the use of local suppository or enema preparations before presuming a diagnosis of bowel

obstruction. Stercoral perforation can and does occur in terminal disease, often due to the combination of long-term opiate medication and immobility, so obstructive symptoms, especially with pain should be treated seriously, even when constipation is suspected [8].

The functional status of the patient with advanced malignancy can be objectively assessed using the World Health Organisation Performance Status (WHOPS) score (Table 1). This assessment forms a standard part of chemotherapy trials, typically with those patients with WHOPS 0–1 being fit for intervention, WHOPS 2, potentially able to be included, and those with a WHOPS 3–5 excluded [9]. The American Society of Anaesthesiologists (ASA) grade can be reasonably substituted for the WHOPS score in a surgical environment, with an ASA grade of 3 or greater corresponding to a the poor prognostic group of ECOG score of 2–5 [10].

4. Establishing the goals of care

When patients present during the terminal stages of a malignancy, it is imperative that the goals of care are discussed between the patient, care-givers and treating surgeons. This includes discussion of any prior advanced treatment decisions. All patients have profound needs for meaning, comfort, and direction in what remains of their life [11], and treatment decisions regarding surgery for MBO must take these important factors into account. These goals are highly patient-specific, and can be highly varied in the level of expected functional outcome, and the likely risk of the treatment required to achieve them (Table 2).

It is also interesting to bear in mind that the needs of patients and caregivers for information relating to terminal disease show a tendency to diverge as illness progresses, with caregivers needing more and patients wanting less information [12]. This dichotomy may result in a mismatch of understanding of the likely risks and benefits of any management, and should be carefully considered in any decision-making process, ideally in conjunction with a well-informed, objective medical practitioner.

5. Initial management

Initial resuscitative measures involve the placement of a nasogastric tube to aspirate gastrointestinal contents and prevent aspiration, and commencement of intravenous fluid and electrolyte replacement to normalise intravascular volume and physiology. It is, however, worth noting that this simple conservative management strategy in isolation will fail in 80% of patients with MBO [13]. Opiate analgesia should also be given in a dose appropriate to the patient's baseline tolerance. In the case of patients with advanced malignancy, it is of course important to consider if there is any advance treatment decision to refuse nasogastric intubation, or indeed, intravenous fluids. Patients with terminal disease often present to hospital out-of-hours or at crisis points, and this attendance should not be taken as an implied wish to pursue interventional management. Early involvement of the patient's oncological or palliative care team is essential for coordinated care, and for treatment planning in the light of any prognostic information available.

6. Investigation

Beyond the initial history and examination, a plain abdominal radiograph can give useful diagnostic information, especially the differentiation between evidence of upper gastrointestinal, small or large bowel obstruction. Specifically, there is an abundance of gas or fluid visible in bowel loops proximal to the level of obstruction, with a paucity distal to it [2]. Often, and more usefully in this

Table 1
The WHO performance status scale.

Grade	Explanation of activity
0	Fully active, able to carry on all pre-disease performance without restriction
1	Restricted in physically strenuous activity but ambulatory and able to carry out work of a light or sedentary nature, e.g., light house work, office work
2	Ambulatory and capable of all self-care but unable to carry out any work activities. Up and about more than 50% of waking hours
3	Capable of only limited self-care, confined to bed or chair more than 50% of waking hours
4	Completely disabled. Cannot carry on any self-care. Totally confined to bed or chair
5	Dead

Table 2
Possible goals of care in terminal disease, adapted from Ref. [11].

To be cured	To live longer	To improve or maintain function, quality of life or independence
To be comfortable	To achieve a specific life goal	To provide support for their family or care-giver
To remain at home	To allow them to prepare for a 'Good' death.	Spiritual needs

setting, it can identify the presence of gas within the large bowel, which is indicative of a subacute picture. The addition of oral contrast can be useful in this setting to ascertain the level and completeness of the obstruction. Gastrograffin is preferred to barium, as the latter has an inspissatory effect, whereas the hyperosmolar composition of gastrograffin does not, and can hasten the resolution of obstruction in some cases [14]. Rectal contrast can be utilised in cases of suspected distal LBO to aid in diagnosis.

The main differentiations required in new diagnoses of malignant obstruction are those between mechanical and paralytic obstruction, and single and multilevel obstruction. For complete decision-making, this requires cross-sectional imaging.

The most readily available advanced imaging modality is computed tomography (CT). A systematic review identified CT as having a sensitivity of 92% (range, 81–100%), specificity of 93% (range, 68–100%), PPV of 91% (range, 84–100%), and NPV of 93% (range, 76–100%) in the detection of complete bowel obstruction [15]. It has particular utility in identifying the site and cause for obstruction [16], but its use in the identification of diffuse peritoneal carcinomatosis is conventionally considered to be unreliable, with a predictive value of <20%, especially when peritoneal nodules are less than 1 cm in diameter, or located within the small bowel or pelvis [17]. Even with the recent advent of high-resolution, multi-detector CT scanning, identification rates of lesions less than 1 cm in diameter is considered poor, at 65.5% in a recent study [18].

Gadolinium-enhanced Magnetic Resonance Imaging (MRI) has been shown to be superior in distinguishing benign from malignant bowel obstruction in patients with known malignancy [19]. The sensitivity of MRI in diagnosing the extension of a neoplasm and the level of the obstruction is 93%–95%, with a specificity of 63%–100% and a predictive value of 81%–96% [2]. However, its relative lack of availability limits its functionality as the primary investigation of choice in these patients.

¹⁸F-fluorodeoxyglucose Positron Emission Tomography (FDG-PET) in combination with CT scanning has been described in the setting of malignant bowel obstruction, and has particular utility in refuting the presence of intra-abdominal malignancy in the patient with bowel obstruction, and a prior history of cancer [20]. Availability also poses a significant impediment to the routine use of PET in this setting.

7. Medical palliation

Unless an advance treatment decision has been made to decline all further treatment, medical palliation should be instigated once the diagnosis of malignant bowel obstruction has been made, either clinically or on cross-sectional imaging. Symptomatic

management will not affect potential future surgical outcome.

Medical palliation is divided into 2 mechanisms: obviating any precipitating factors, and decreasing the intraluminal pressure associated with MBO. Initially, efforts should be made to correct any biochemical imbalance that may be contributing to intestinal dysmotility, most commonly hypercalcaemia or hypokalaemia. Certain medications commonly used in advanced malignancy can also worsen the obstructive picture, notably opioids and anti-spasmodic medications. A careful symptom exploration should be performed to ascertain if it is possible to stop or reduce these medications without precipitating symptomatic crises. Opioids can rarely be omitted, as acute pain also needs to be addressed, and have originally been commenced for ongoing significant pain. Conversion of background opioids to fentanyl can markedly reduce gastrointestinal dysmotility in appropriate cases [21].

Active medical palliation in MBO focuses around the use of corticosteroids, anti-secretory medications and anti-emetics, with sufficient analgesia.

7.1. Steroids

The use of intravenous or subcutaneous dexamethasone has both an anti-emetic and anti-inflammatory effect, which logically should be beneficial in MBO. Evidence for this practice is conflicting. However, a Cochrane review article has been published on the subject [22], taking into account 3 placebo-controlled randomised trials [23,24], and 7 further studies of lesser quality. In summary, doses in the range 6–16 mg were suggested as sufficient to have the desired effect, with a number needed to treat of six. However, statistical analysis did not reach significance. It was felt that the side-effects of dexamethasone at this dose range were minimal, but it is worth bearing in mind the risks of gastrointestinal ulceration and immune suppression, so they can be appropriately recognised and managed. Total doses should be divided and given at breakfast and lunchtime to reduce psychotropic effects and insomnia.

7.2. Antisecretory medications

A simple step to decrease gastric secretions is to commence the patient on either a proton pump inhibitor or ranitidine [25], the latter of which has been shown to be superior in terms of volume reduction in a recent meta-analysis [26]. The antisecretory medications in common usage are anticholinergic agents such as hyoscine butylbromide or glycopyrronium, and somatostatin analogues such as octreotide, with octreotide demonstrating significantly increased benefits in a randomised trial [27]. Anticholinergics benefit from the extra effect of decreasing smooth

muscle spasm, but can be sedating. Glycopyrronium does not cross the blood–brain barrier, so is often preferred. Octreotide directly counteracts the action of VIP, thereby decreasing fluid retention in the intestinal lumen, as well as having inhibitory effects on gastric secretions, intestinal motility, and biliary flow [28]. Doses from 300 to 600 µg per day have been recommended, with good symptomatic outcomes reported [29,30]. However, cost constraints may limit its routine use in some centres. If GI secretions can be sufficiently reduced, some patients are able to symptomatically tolerate one or two vomits a day if a Ryles tube is removed.

7.3. Antiemetics

In MBO with significant colic and vomiting, cyclizine generally offers adequate antiemesis, and importantly, it also has an anti-secretory effect. Haloperidol can be a useful adjunct to cyclizine if it is partially effective. Prokinetic agents such as metoclopramide are best avoided in incomplete MBO. However, they can be very effective where there is incomplete bowel obstruction or an absence of colic. Maximal effectiveness may not be reached until doses well in excess of 30 mg/day are given. Specialist palliative care advice should be sought in this instance.

The medical management of MBO will often take several days before there is a significant resolution of symptoms. The spontaneous resolution of MBO occurs in 36% (31%–42%) of patients with inoperable MBO. 92% of those who settled spontaneously had done so by day 7. However, 72% of those who settled spontaneously, subsequently developed another episode of obstruction [2].

Those patients less likely to settle spontaneously include those with these features [31]:

- Cognitive failure,
- Cachexia,
- Dyspnoea at rest,
- Palpable abdominal masses,
- Hepatic failure and ascites,
- Obstruction involving the proximal stomach,
- Dehydration

Clearly, these patient characteristics share significant crossover with those who are also not candidates for surgical intervention.

8. Interventional palliation

Interventional radiology and endoscopic procedures offer additional therapeutic options in selected patients with MBO. They may be more appropriate in those with limited life expectancy or major comorbidities, which would make operative intervention unacceptable.

8.1. Self-expanding metallic stents

Where a single point of obstruction has been identified on cross-sectional imaging, endoscopic stenting can be considered for symptomatic relief in patients who are unable to undergo resection, or have declined surgery. Understandably, stents can only be placed within reach of either a gastroscope or colonoscope. Duodenal stenting in the setting of gastric outlet obstruction is associated with lower rates of complications, and a shorter length of stay with comparable short-term outcomes to gastro-jejunostomy in malignant obstruction [32]. Mean survival is however shorter, at 105 days after stent placement and 164 days after GJJ, in combination with a higher rate of recurrent obstruction in the stent group (18% vs. 1%) [33]. This may, however, represent patient selection bias, as patients deemed ‘fitter’, will more likely be considered for surgery. A

recent systematic review has suggested that current RCT evidence was not suitable to address this potential source of bias, and that further studies are needed [32].

Colonic Stenting has been a controversial topic in recent years, predominantly due to the risk of intra-procedural perforation, and consequent tumour dissemination [34] within an unselected cohort. However, a recent large scale analysis of outcomes has suggested that it is beneficial within the selected cohort of patients with unresectable metastatic disease or when they were not appropriate candidates for resection of the primary tumour because of co-morbidity and limited life expectancy [35]. Those undergoing colonic stenting did, however, have a reintervention rate of 30.8%, with 11% requiring creation of a stoma.

The stenting of malignant lesions between the duodenum and ileocaecal valve has also been described [36], with good results reported in single center case series [37]. Currently, this practice is not widespread, but may become more readily available as expertise with double balloon enteroscopy is gained in more centres.

8.2. Percutaneous gastrostomy

Where surgical relief of obstruction is impossible or inappropriate, and medical management is unable to relieve symptoms of vomiting, long-term nasogastric aspiration is not desirable predominantly due to the patient's discomfort in having a long-term wide-bore Ryles tube *in situ*. It also carries the inherent risks of non-elective extubation, the risk of tube misplacement, and the occasional need to check the position of the tube by x-ray [38]. In the situation where intractable volume related symptoms occur, then placement of a venting gastrostomy tube can be considered to aspirate gastric contents. Case series report acceptable symptomatic outcomes, with avoidance of repeat nasogastric intubation in 96% of patients (range 81.4–100%) and a mean survival of 63 days (range 8–444 days) post procedure [39]. Generally, Percutaneous Endoscopically-inserted Gastrostomy (PEG) or Radiologically-Inserted Gastrostomy (RIG) insertion for nutritional support is considered in non-obstructed patients with a prognosis of at least 1 month. However, in terms of decompressive gastrostomy, especially for malignant obstruction, it should be considered as a palliative treatment option for all patients unless there is no contraindication as a result of the patient's physical condition [39].

9. Surgical palliation

9.1. Decision making

The process of surgical decision-making relies upon an assessment of the likely benefits and risks of the proposed procedure to the patient. This balance becomes somewhat more difficult to interpret in advanced malignancy, particularly when the benefit of the procedure may be related to only an increase in the quality of life, with high operative risks of morbidity and mortality [40]. Broadly, consideration for palliative surgery in MBO should be given in situations where the patients are not actively dying, and reversal of enteral failure could make therapeutic options viable [41]. Clear communication with the patient, caregivers and the multidisciplinary team is likely to be the most fruitful, and the least likely to be affected by a single parties agenda. The end of life is of course an emotionally traumatic time for all involved, but the patient is potentially under a wide range of influences, which could cloud judgement including opiates, steroids, biochemical imbalance, pain or pre-existing mental health issues. Anecdotal evidence exists of patients hoping to shorten or end their lives by undergoing invasive procedures, and indeed of maleficent relatives with ulterior motives. Most often, however, relatives are just concerned that

'everything possible should be done' for the patient [42]. Clear assessments need to be made of the patient's understanding of the potential outcomes, and likely benefits of operative intervention [43].

Just as the benefit for each patient is highly individual, the risks incumbent on performing a surgical procedure in a patient with MBO is dependent on the underlying pathology and patient-related factors.

9.2. Patient related factors

While operative outcomes can be estimated using either the WHOPS or ASA grade, specific parameters have been repeatedly identified in cohorts less likely to benefit from surgical intervention [44]:

- Complete small bowel obstruction (SBO) as opposed to partial SBO or large bowel obstruction
- Non-gynaecological cancer
- Ascites
- Albumin below normal range
- Total white cell count outside normal range

In addition to this, age >65, malnutrition and a general decrease in functional status have been described as negative prognostic features. Within those patients with gynaecological cancer, worse outcomes are observed in those who have previously received chemotherapy [45].

9.3. Choice of procedure

A recent meta-analysis of obstruction in patients with peritoneal carcinomatosis has suggested that resection and primary anastomosis has the greatest operative survival (7.2 months) followed by defunctioning stoma formation (3.4 months) and enteral bypass (2.7 months) [41]. However, major complications occurred in 37.0% of patients that underwent resections. This latter point is important, as while longevity is desirable, quality of life must be considered paramount in patients with a limited life expectancy. No assessment was made of quality of life in the analysed studies. It is also important to note that a single level of obstruction is more likely to be amenable to resection and anastomosis, so this outcome benefit may reflect the relative severity of intra-abdominal disease. When any surgical procedure is being performed, it must be borne in mind the residual length of functioning intestine that will be left in continuity. It is generally considered that 200 cm of small bowel in isolation is the minimum length able to maintain acceptable function, or 50–70 cm of small bowel when the colon is still in continuity [46]. Lengths below this are associated with significant physical and psychological sequelae [47]. Likelihood of fistulation or adherence to other abdominal organs or soft tissues must also be assessed when assessing patients for surgery, as exenterative surgery or *en bloc* resection with major reconstructions are unlikely to benefit this cohort of patients. Likewise, intraoperative tumour debulking is not of benefit in non-gynaecological malignancies [48].

Total Parenteral Nutrition (TPN) has been described in the context of managing MBO, and forms a standard part of management of bowel obstruction in some health systems [41]. However, it is only recommended in MBO for those patients who are undergoing surgery to enable subsequent chemotherapy, and have a post-operative survival likely to be more than 3 months.

Ultimately, a standard surgical decision-making process can be followed (Fig. 1), albeit with the added complexities of a patient at the extremes of disease and a situation that is likely to be highly

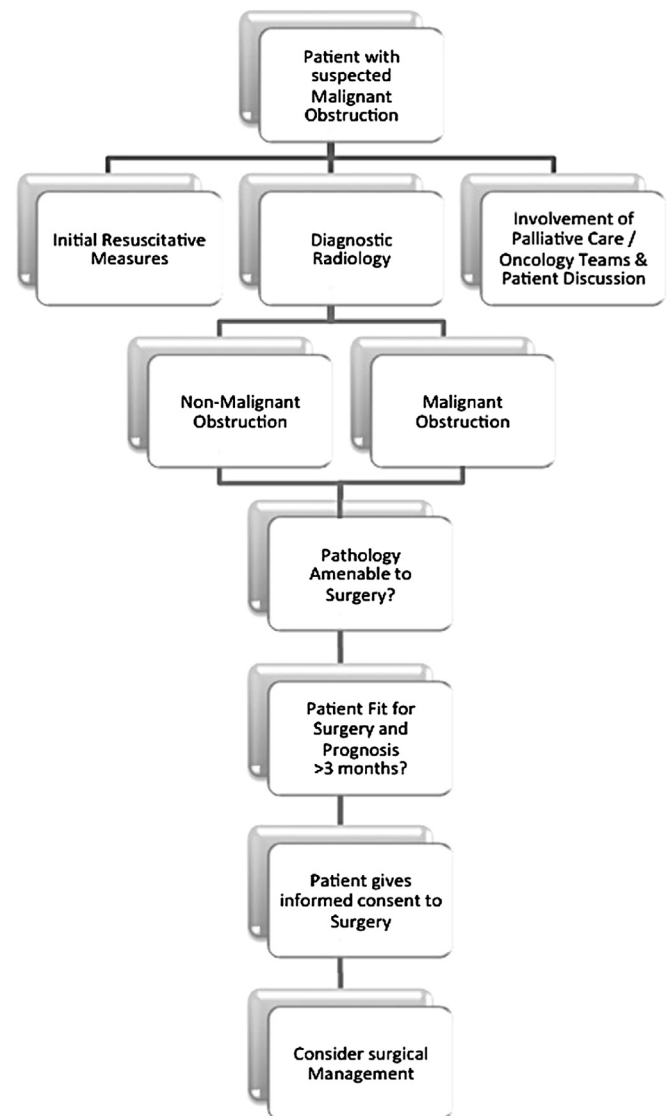


Fig. 1. Surgical management of bowel obstruction in patients with advanced malignancy.

emotionally charged.

10. Conclusions

Management of patients with MBO requires multidisciplinary involvement, and often multimodal therapy. It is rare for bowel strangulation to occur in these presentations, and spontaneous resolution does not infrequently occur, so the luxury of time should be afforded to what is always a highly complex and emotionally charged decision to offer surgery. Ultimately, the decision regarding the appropriateness of surgical intervention has to be taken on a case-by-case basis. Decisions need to be taken with as much collateral, psychosocial information available as possible to inform the multidisciplinary team's discussions. Optimal outcomes at the end of life rely upon a careful analysis of the patient, their pathology, and the likely benefits to be gained from intervention, be they psychological, social, or to enable further adjunctive treatment. If surgery is to be undertaken, resection and anastomosis, if feasible, should be performed in preference to formation of a stoma or enteric bypass. Ultimately, the aim of any therapy in MBO is to

restore intestinal function, but if this fails for whatever reason, management should enable the patient to be cared for in their chosen environment, which may not be an acute hospital.

Ethical approval

No ethical approval required.

Funding

No specific funding was acquired for this study.

Author contribution

HJMF – Study Concept and Design, Literature Review, Manuscript Preparation.

CIF – Study Concept and Design, Literature Review, Manuscript Preparation.

JS – Study Concept and Design, Manuscript Review.

TI – Study Concept and Design, Manuscript Review.

Conflict of interest

Nothing to declare.

Guarantor

HJMF and CIF act as Guarantors.

Consent

Not applicable.

References

- [1] C. Ripamonti, F. De Conno, V. Ventafriida, B. Rossi, M.J. Baines, Management of bowel obstruction in advanced and terminal cancer patients, *Ann. Oncol.* 4 (1993) 15–21.
- [2] A. Tuca, E. Guell, E. Martinez-Losada, N. Codorniu, Malignant bowel obstruction in advanced cancer patients: epidemiology, management, and factors influencing spontaneous resolution, *Cancer Manag. Res.* 4 (2012) 159–169.
- [3] E.A. Dolan, Malignant bowel obstruction: a review of current treatment strategies, *Am. J. Hosp. Palliat. Care* 28 (2011) 576–582.
- [4] A.B. Mariotto, J.H. Rowland, L.A.G. Ries, S. Scoppa, E.J. Feuer, Multiple cancer prevalence: a growing challenge in long-term survivorship 16 (2007) 566–571.
- [5] C. Ripamonti, R. Twycross, M. Baines, F. Bozzetti, S. Capri, F. De Conno, et al., Clinical-practice recommendations for the management of bowel obstruction in patients with end-stage cancer 9 (2001) 223–233.
- [6] C. Ripamonti, E. Bruera, Palliative management of malignant bowel obstruction 12 (2002) 135–143.
- [7] C.I. Ripamonti, A.M. Easson, H. Gerdes, Management of malignant bowel obstruction 44 (2008) 1105–1115.
- [8] P. Kumar, O. Pearce, A. Higginson, Imaging manifestations of faecal impaction and stercoral perforation 66 (2011) 83–88.
- [9] H.J. West, Patients with advanced non-small-cell lung cancer and marginal performance status: walking the tight rope towards improved survival 31 (2013) 2841–2843.
- [10] J. Young, T. Badgery-Parker, T. Dobbins, M. Jorgensen, P. Gibbs, I. Faragher, et al., Comparison of ECOG/WHO performance status and ASA score as a measure of functional status, *PubMed – NCBI, J. Pain Symptom Manag.* 49 (2) (2015 Feb) 258–264.
- [11] Review Article L.C. Kaldjian, A.E. Curtis, L.A. Shinkunas, K.T. Cannon, Goals of care toward the end of life: a structured literature review 25 (2009) 501–511.
- [12] S.M. Parker, J.M. Clayton, K. Hancock, S. Walder, P.N. Butow, S. Carrick, et al., A systematic review of prognostic/end-of-life communication with adults in the advanced stages of a life-limiting illness: patient/caregiver preferences for the content, style, and timing of information 34 (2007) 81–93.
- [13] *Gastrointestinal Symptoms*, in: M. Watson, C. Lucas, A. Hoy, J. Wells (Eds.), *Oxford Handbook of Palliative Care*, second ed., Oxford University Press, 2009.
- [14] B.C. Branco, G. Barmparas, B. Schnüriger, K. Inaba, L.S. Chan, D. Demetriades, Systematic review and meta-analysis of the diagnostic and therapeutic role of water-soluble contrast agent in adhesive small bowel obstruction, *Br. J. Surg.* 97 (2010) 470–478.
- [15] R.D. Mallo, L. Salem, T. Lalani, D.R. Flum, Computed tomography diagnosis of ischemia and complete obstruction in small bowel obstruction: a systematic review, *J. Gastrointest. Surg.* 9 (2005) 690–694.
- [16] A. Filippone, R. Cianci, M.L. Storto, Bowel obstruction: comparison between multidetector-row CT axial and coronal planes, *Abdom. Imaging* 32 (2007) 310–316.
- [17] S. Suri, S. Gupta, P.J. Sudhakar, N.K. Venkataramu, B. Sood, J.D. Wig, Comparative evaluation of plain films, ultrasound and CT in the diagnosis of intestinal obstruction, *Acta Radiol.* 40 (1999) 422–428.
- [18] U. Metser, C. Jones, L.M. Jacks, M.Q. Bernardini, S. Ferguson, Identification and quantification of peritoneal metastases in patients with ovarian cancer with multidetector computed tomography: correlation with surgery and surgical outcome 21 (2011) 1391–1398.
- [19] R.N. Low, S.C. Chen, R. Barone, Distinguishing benign from malignant bowel obstruction in patients with malignancy: findings at MR imaging, *Radiology* 228 (2003) 157–165.
- [20] W.-G. Wu, P. Dong, X.-S. Wu, M.-L. Li, Q.-C. Ding, L. Zhang, et al., Surgical management of patients with bowel obstructions secondary to gastric cancer 19 (2013) 4559–4567.
- [21] B. Donner, M. Zenz, M. Tryba, M. Strumpf, Direct conversion from oral morphine to transmucosal fentanyl: a multicenter study in patients with cancer pain 64 (1996) 527–534.
- [22] D.J. Feuer, K.E. Broadley, Corticosteroids for the resolution of malignant bowel obstruction in advanced gynaecological and gastrointestinal cancer, *Cochrane Database Syst. Rev.* (2000) CD001219.
- [23] J. Hardy, J. Ling, J. Mansi, R. Isaacs, J. Bliss, R. A'Hern, et al., Pitfalls in placebo-controlled trials in palliative care: dexamethasone for the palliation of malignant bowel obstruction, *Palliat. Med.* 12 (1998) 437–442.
- [24] G. Laval, J. Girardier, J.M. Lassaunière, B. Leduc, C. Haond, R. Schaefer, The use of steroids in the management of inoperable intestinal obstruction in terminal cancer patients: do they remove the obstruction? *Palliat. Med.* 14 (2000) 3–10.
- [25] G. Laval, B. Marcelin-Benazech, F. Guirmand, L. Chauvenet, L. Copel, A. Durand, et al., Recommendations for bowel obstruction with peritoneal carcinomatosis, *J. Pain Symptom Manag.* 48 (2014) 75–91.
- [26] K. Clark, L. Lam, D. Currow, Reducing gastric secretions—a role for histamine 2 antagonists or proton pump inhibitors in malignant bowel obstruction? 17 (2009) 1463–1468.
- [27] S. Mercadante, C. Ripamonti, A. Casuccio, E. Zecca, L. Groff, Comparison of octreotide and hyoscine butylbromide in controlling gastrointestinal symptoms due to malignant inoperable bowel obstruction 8 (2000) 188–191.
- [28] P. Nelligård, L. Bojö, J. Cassuto, Importance of vasoactive intestinal peptide and somatostatin for fluid losses in small-bowel obstruction 30 (1995) 464–469.
- [29] H. Watari, M. Hosaka, Y. Wakui, E. Nomura, H. Hareyama, F. Tanuma, et al., A prospective study on the efficacy of octreotide in the management of malignant bowel obstruction in gynecologic cancer 22 (2012) 692–696.
- [30] T. Hisanaga, T. Shinjo, T. Morita, N. Nakajima, M. Ikenaga, M. Tanimizu, et al., Multicenter prospective study on efficacy and safety of octreotide for inoperable malignant bowel obstruction 40 (2010) 739–745.
- [31] C. Ripamonti, S. Mercadante, Pathophysiology and management of malignant bowel obstruction, in: G. Hanks, N.I. Cherny, N.A. Christakis, M. Fallon, S. Kaasa, R.K. Portenoy (Eds.), *Oxford Textbook of Palliative Medicine*, fourth ed., Oxford University Press, 2010.
- [32] V. Nagaraja, G.D. Eslick, M.R. Cox, Endoscopic stenting versus operative gastrojejunostomy for malignant gastric outlet obstruction—a systematic review and meta-analysis of randomized and non-randomized trials 5 (2014) 92–98.
- [33] S.M. Jeurnink, C.H.J. van Eijck, E.W. Steyerberg, E.J. Kuipers, P.D. Siersema, Stent versus gastrojejunostomy for the palliation of gastric outlet obstruction: a systematic review 7 (2007) 18.
- [34] J.E. van Hooft, W.A. Bemelman, B. Oldenburg, A.W. Marinelli, M.F. Lutke Holzik, M.J. Grubben, et al., Colonic stenting versus emergency surgery for acute left-sided malignant colonic obstruction: a multicentre randomised trial 12 (2011) 344–352.
- [35] S. Abbott, T.W. Eglinton, Y. Ma, C. Stevenson, G.M. Robertson, F.A. Frizelle, Predictors of outcome in palliative colonic stent placement for malignant obstruction 101 (2014) 121–126.
- [36] F. Zhang, S.K. Amateau, M.A. Khashab, P.I. Okolo, Mid-gut stents, *Curr. Opin. Gastroenterol.* 28 (2012) 451–460.
- [37] N. Almeida, P. Figueiredo, S. Lopes, H. Gouveia, M.C. Leitão, Double-balloon enteroscopy and small bowel tumors: a South-European single-center experience, *Dig. Dis. Sci.* 54 (2009) 1520–1524.
- [38] C.B. Pearce, H.D. Duncan, Enteral feeding. Nasogastric, nasojejunal, percutaneous endoscopic gastrostomy, or jejunostomy: its indications and limitations 78 (2002) 198–204.
- [39] N. Kawata, N. Kakushima, M. Tanaka, H. Sawai, K. Imai, T. Hagiwara, et al., Percutaneous endoscopic gastrostomy for decompression of malignant bowel obstruction 26 (2014) 208–213.
- [40] B. Hofmann, L.L. Häheim, J.A. Søreide, Ethics of palliative surgery in patients with cancer 92 (2005) 802–809.
- [41] B. Shariat-Madar, T.T. Jayakrishnan, T.C. Gamblin, K.K. Turaga, Surgical management of bowel obstruction in patients with peritoneal carcinomatosis, *J. Surg. Oncol.* 110 (6) (2014 Nov) 666–669, <http://dx.doi.org/10.1002/jso.23707>, Epub 2014 Jul 2 [42].
- [42] N.S. Jecker, L.J. Schneiderman, When families request that “everything possible” be done 20 (1995) 145–163.

- [43] A. Jamjoom, S. White, S.M. Walton, J.G. Hardman, I.K. Moppett, Anaesthetists' and surgeons' attitudes towards informed consent in the UK: an observational study 11 (2010) 2.
- [44] J.C. Henry, S. Pouly, R. Sullivan, S. Sharif, D. Klemanski, S. Abdel-Misih, et al., A scoring system for the prognosis and treatment of malignant bowel obstruction, *Surgery* 152 (2012) 747–756 discussion 756–7.
- [45] D.J. Feuer, K.E. Broadley, J.H. Shepherd, D.P. Barton, Systematic review of surgery in malignant bowel obstruction in advanced gynecological and gastrointestinal cancer. The Systematic Review Steering Committee, *Gynecol. Oncol.* 75 (1999) 313–322.
- [46] M.K. Robinson, D.W. Wilmore, Short bowel syndrome, in: R.G. Holzheimer, J.A. Mannick (Eds.), *Surgical Treatment: evidence-based and Problem-oriented*, Zuckschwerdt, Munich, 2001. Available from: <http://www.ncbi.nlm.nih.gov/books/NBK6974/>.
- [47] E. Kalaitzakis, E. Carlsson, A. Josefsson, I. Bosaeus, Quality of life in short-bowel syndrome: impact of fatigue and gastrointestinal symptoms 43 (2009) 1057–1065.
- [48] L. Helyer, A.M. Easson, Surgical approaches to malignant bowel obstruction, *J. Support. Oncol.* 6 (2008) 105–113.