

Modified In-Office Maxillary Balloon Sinus Dilation for Post-Procedure Sinus Monitoring and Access

Gary J. Nishioka¹

¹Department of Otolaryngology, Willamette Ear Nose Throat, Salem, Oregon, United States

Int Arch Otorhinolaryngol 2018;22:68–72.

Address for correspondence Gary Jim Nishioka, MD, DMD, Department of Otolaryngology, Willamette Ear Nose Throat, 3099 River Road, S. Ste. 150, Salem, OR 97302, United States (e-mail: garyn@entsalem.com).

Abstract

Introduction As experience grows with in-office balloon sinus dilation (BSD) procedures, technique modifications will evolve to meet specific needs. The major disadvantage with the maxillary BSD procedure is that the intact uncinate process prevents visualization of and instrument access into the maxillary sinus both intraoperatively and postoperatively. Combining a partial or complete uncinectomy procedure with maxillary BSD could be beneficial in selected patients with certain maxillary sinus problems.

Objective The primary objective of this study was to see if, in selected patients, combining an uncinectomy and maxillary sinus BSD together allowed visualization of and access to the maxillary sinus cavity at the time of the procedure and at follow-up visits.

Method A chart review was completed for BSD cases performed from 2013 through mid-2015 identifying patients who underwent partial or complete uncinectomy with in-office maxillary sinus BSD. A total of 14 patients were identified, with 26 sinuses treated. The data collected included: difficulty or problems in performing an uncinectomy with the maxillary sinus BSD; visualization and access to the maxillary sinus cavity both intraoperatively and at follow-up visits; and occurrence of complications or late adverse sequelae. All patients completed a minimum 6-month follow-up.

Results Combined uncinectomy and maxillary sinus BSD procedures were easily completed for all patients without complications, and no late adverse sequelae were encountered. The maxillary sinuses could be visualized and accessed, if needed, intraoperatively and at all follow-up visits.

Conclusions In selected subsets of maxillary sinus conditions this procedure modification can provide significant benefits. A case is presented for illustration.

Keywords

- ▶ maxillary sinus
- ▶ sinusitis
- ▶ paranasal sinuses
- ▶ endoscope
- ▶ balloon dilation

Introduction

Balloon sinus dilation (BSD) or balloon sinuplasty (BSP) was introduced in September 2005 as a minimally invasive mucosal sparing alternative to traditional endoscopic sinus surgery in which sinus ostia or sinus outflow tracts are

dilated with a small balloon catheter.¹ Interest in and use of BSD is becoming more prevalent, and there is strong interest in utilizing balloon catheter devices in the physician's office as an office procedure^{2–9} (office rhinology).

Endoscopic examination of the sphenoid sinus dilation site following BSD can be visualized and accessed both

received
April 20, 2016
accepted
January 25, 2017
published online
April 27, 2017

DOI <https://doi.org/10.1055/s-0037-1601562>.
ISSN 1809-9777.

Copyright © 2018 by Thieme Revinter Publicações Ltda, Rio de Janeiro, Brazil

License terms



intraoperatively and postoperatively with relative ease. The frontal sinus dilation site is more difficult to visualize, and is dependent on the three dimensional (3-D) anatomy of the frontal outflow tract/frontoethmoid recess. As for BSD of the maxillary sinus *as it is currently performed*, while often technically difficult, verification of ostial patency can be reliably achieved, but may require a more angled rigid nasal endoscope (45°, 90°, or 120°), and is dependent on the position and dimensions of the uncinate process. Unfortunately, the intact uncinate process makes thorough inspection of and direct instrument access into the sinus cavity extremely difficult, if not impossible.

If thorough inspection of and instrument access into the maxillary sinus cavity is desired, either intraoperatively and or postoperatively in patients undergoing in-office maxillary sinus BSD, then partial or complete uncinectomy could be a solution. Complete uncinectomy is used in standard endoscopic sinus surgery to provide exposure for performing a maxillary antrostomy. A recent report has shown partial inferior uncinectomy can also be employed successfully without adverse sequelae.¹⁰

The primary objective of this retrospective “descriptive” study was to determine if the maxillary sinus could be thoroughly inspected and accessed with instrumentation (if needed), at the time of the procedure and at all follow-up visits, in patients who underwent a combined in-office uncinectomy and maxillary sinus BSD procedure compared with *the standard maxillary BSD procedure currently used*. Secondary objectives included observation of any difficulty in performing the procedure, and if any complications or late adverse sequelae occurred.

Methods

This study received institutional review board approval through IntegReview IRB (Austin, Texas). A chart review was made for BSD procedures performed from 2013 through mid-2015 to identify patients who underwent maxillary sinus BSD with partial or complete uncinectomies. Fourteen patients were identified for a total of 26 sides. Twelve partial uncinectomies and 14 complete uncinectomies were performed.

Patients who underwent this modified maxillary sinus BSD procedure included: 1) recurrent acute rhinosinusitis (RARS) patients with high (between episodes) baseline sinonasal outcome test (SNOT-22) scores¹¹ of 50 or greater (2 patients); 2) modified Lund-MacKay¹² maxillary sinus computed tomography (CT) scan scores of 2 or greater with significant soft tissue changes in the area of the medial maxillary wall and ethmoid infundibulum (8 patients); 3) very large maxillary sinus mucous retention pseudocysts (1 patient); 4) chronic maxillary sinus air-fluid levels (1 patient); and 5) mycetoma (2 patients). ▶ **Table 1.**

Recurrent acute rhinosinusitis (RARS) was defined principally using the American Academy of Otolaryngology – Head and Neck Surgery guidelines¹³ with at least 4 episodes of acute bacterial rhinosinusitis (ABRS) in the prior 12 months, without signs or symptoms between episodes (or significant changes above their baseline), but also incorporated 2 or more sinus CT scans to confirm the radiographic appearance of sinus disease and its resolution with medical therapy with at least 1 episode of ABRS.

In this retrospective study, RARS patients with high (between episodes) baseline SNOT scores underwent this

Table 1 Sinus profile data for modified maxillary sinus BSD patients

Patient	Diagnosis	Max. Sinus Mod. M-L Scores: RMS, R-OMC, LMS, L-OMC respectively
1	RARS/High BL SNOT	(1, 2, 1, 2)*
2	RARS/High BL SNOT	(1, 2, 1, 2)*
3	CRS	2, 2, 2, 2
4	CRS	3, 2, 2, 2
5	CRS	2, 2, 2, 2
6	CRS	2, 2, 3, 2
7	CRS	2, 2, 2, 2
8	CRS	2, 2, 2, 2
9	CRS	2, 2, 3, 2
10	CRS	2, 2, 2, 2
11	Large MRC	3, 2, 3, 2
12	A-F Level	2, 2, 2, 2
13	Mycetoma	2, 2, 0, 0
14	Mycetoma	0, 0, 2, 2

Abbreviations: A-F level, air fluid level; BSD, Balloon sinus dilation; CRS, chronic rhinosinusitis; High BL SNOT, high baseline SNOT-22 score between episodes; LMS, left maxillary sinus; L-OMC, left osteomeatal complex; Max. Sinus Mod. M-L scores, maxillary sinus modified Mackay-Lund scores; MRC, mucous retention pseudocyst; RARS, recurrent acute rhinosinusitis; RMS, right maxillary sinus; R-OMC, right osteomeatal complex.

*Between the acute rhinosinusitis episodes.

modification so diagnosis of any future ABRS episode could be made objectively, and not on symptom profile alone. Patients in the aforementioned category 2 (modified Lund-MacKay¹² maxillary sinus CT scan scores of 2 or greater with significant soft tissue changes in the area of the medial maxillary wall and ethmoid infundibulum) were chronic rhinosinusitis (CRS) patients who failed medical therapy over a minimal interval of 4 months and generally much longer (beginning from the time of their first sinus CT scan). Medical therapy included multiple courses of oral antibiotics (minimum of 3 weeks per course), oral and topical steroid therapy, nasal saline irrigation, with maxillary sinus disease demonstrated on 2 or more sinus CT scans. Evaluation for allergic rhinitis was a separate independent process, as well as any other pertinent comorbidities. The other patients underwent this modification to ensure patency of the dilation site with the desired ability to thoroughly inspect and instrument access inside the maxillary sinus.

Technique

All patients underwent the modified maxillary sinus BSD procedure as an in-office procedure in a dedicated procedure room. The patient preparation regimen for in-office BSD was performed per author protocol and included oral sedation (triazolam),¹⁴ application of topical local anesthesia and decongestant solution (mixture of 2 mL of 4% tetracaine, 1 mL 1:1000 of epinephrine, and 3 mL of normal saline moistening cottonoid pledgets, which are placed medial and lateral to the middle turbinates), and maxillary nerve blocks using local anesthesia injection through the greater palatine foramen. Periodic monitoring of level of consciousness, blood pressure, pulse, pulse oximetry without capnography was performed, with no intravenous access. The office surgical team consisted of two certified medical assistants in addition to the surgeon.

The endoscopy equipment used consisted of the Karl Storz Tele Pack X system with Hopkins 3mm 0° and 30° rigid nasal endoscopes (Karl Storz Endoscopy-America Inc., El Segundo, CA, US). When needed, the Linvatec (CONMED corporation, Utica, NY, US) microdebrider with wireless foot pedal was used. The BSD device used for all cases was the Acclarent Relieva Spin system (Johnson & Johnson, New Brunswick, NJ, US). (There are no financial disclosures with any manufacturer for this study).

After satisfactory local anesthesia was achieved, a ball tip probe was used to reflect the uncinat process medially. A micro-backbiting forcep (rotating), and straight and angled 45 degree (Weil-Blakesley) through cutting forceps were then used to remove the lower half of the uncinat process or the entire uncinat process, as determined by the surgical exposure needed at the time of the procedure. After exposure of the maxillary sinus natural ostia area, balloon dilation was performed under direct visualization with rigid nasal endoscopy. When an ethmoidectomy was performed, a power microdebrider was available, which allowed for a more rapid completion of the uncinat procedure. An olive tipped curved suction was then passed into the maxillary sinus to verify access to the sinus. If additional dilation of the

BSD site was desired, beyond the diameter of the inflated balloon catheter, for visualization or access, the olive tipped curved suction was used to push and stretch the posterior fontanelle posteriorly.

Partial or complete uncinectomy was determined by the exposure needs at the time of the procedure with no specific criteria guidelines.

All pre- and postoperative chart notes, operative reports, sinus CTscans, and endoscopic photographs were reviewed for each patient. The following data were collected: 1) difficulty or problems in performing the uncinectomy and/or balloon dilation; 2) intraoperative visualization of and access into the sinus cavity; 3) visualization of and access (if needed) into the sinus cavity at postoperative follow-up visits; 4) complications associated with the uncinectomy procedure; and 5) development of late adverse sequelae. All patients completed a minimum 6-month follow-up.

Results

A total of 26 sides successfully underwent either partial or complete uncinectomy and maxillary sinus BSD without difficulty as an office procedure. No problems were encountered. All maxillary sinus natural ostia appeared stenosed closed secondary to soft tissue hypertrophy prior to dilation. Bleeding was minimal, and did not require any intervention, but bipolar and suction bovie cautery were always available if needed. No intraoperative or postoperative complications were encountered.

All maxillary sinus cavities could be thoroughly visualized and accessed intraoperatively following dilation of the maxillary sinus natural ostia. At every postoperative follow-up appointment, all maxillary sinus cavities could be thoroughly visualized, and, if needed, accessed with instrumentation. No late adverse sequelae were identified. No differences were found with any parameter measured between partial or complete uncinectomy.

A patient case is presented to illustrate the potential benefit of employing an uncinectomy procedure with maxillary BSD in selected cases (► **Figs. 1–5**).

Discussion

In-office sinonasal procedures are rapidly increasing, especially BSD procedures. The principle disadvantage of the standard maxillary sinus BSD procedure is the intact uncinat process. While often technically difficult, reliable verification of ostial patency can be achieved, but the intact uncinat process, which can be medialized from the BSD procedure, prevents thorough inspection of and instrument access into the maxillary sinus cavity itself, and lateralization with nasal endoscopy is theoretically undesirable. It should be noted that there exists a balloon catheter device (Acclarent Relieva SpinPlus, Johnson & Johnson, New Brunswick, NJ, US) that can irrigate the maxillary sinus, but does so blindly.

The ability to thoroughly inspect and access the maxillary sinus postoperatively can potentially be very beneficial in selected patients. In RARS patients who have high baseline

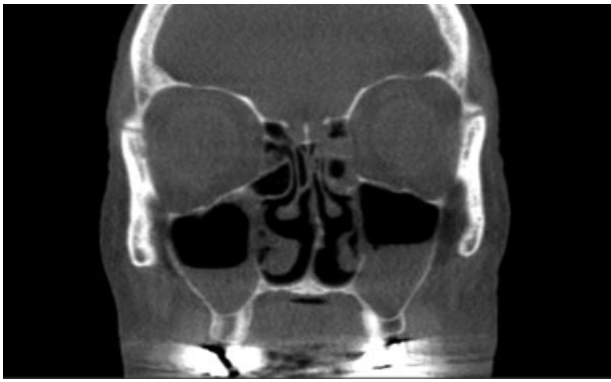

Fig. 1 Preoperative sinus CT scan^b frame showing ethmoid sinus mucosal disease and bilateral maxillary sinus air-fluid levels despite multiple medical management regimens over an eight-month period by multiple physicians. This patient underwent an in-office hybrid BSD procedure with bilateral maxillary BSD with partial uncinectomy, bilateral sphenoid and frontal sinus BSD, bilateral anterior and posterior ethmoidectomies, and bilateral outfracture of the inferior turbinates. The inspissated mucous in both maxillary sinuses were removed by suctioning. Recovery was rapid, with the patient playing golf in 48 hours.

SNOT scores (between episodes), diagnosis of an ABRS can be made more objectively, instead of relying on the severity and duration of subjective symptoms. Diagnostic and treatment decision making is made easier with this procedure modification, compared with standard BSD, as these patients were significantly symptomatic even between ABRS episodes.

The ability to inspect the maxillary sinus for inflammatory mucosal disease or fluid collection, recurrence of a mycetoma or mucous retention pseudocyst, without the need to perform a sinus CT scan is advantageous. Furthermore, with the uncinete process removed, the direct unobstructed sinus access permits a more effective application of topical medications with nasal irrigation. Instrumentation, suctioning and/or culture of the sinus, and, if needed, the ability to perform revision

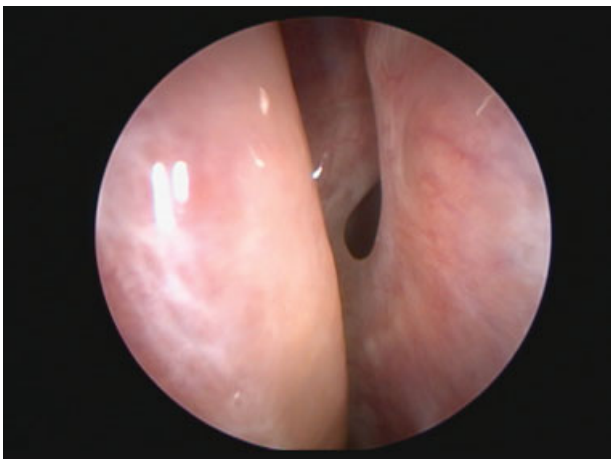


Fig. 2 Three-month follow-up of the patient in ►**Fig. 1** showing the typical appearance of a maxillary balloon sinus dilation site with partial uncinectomy (patient's left side), which allows monitoring of and access to the maxillary sinus. The patient reported postnasal drainage and cough.

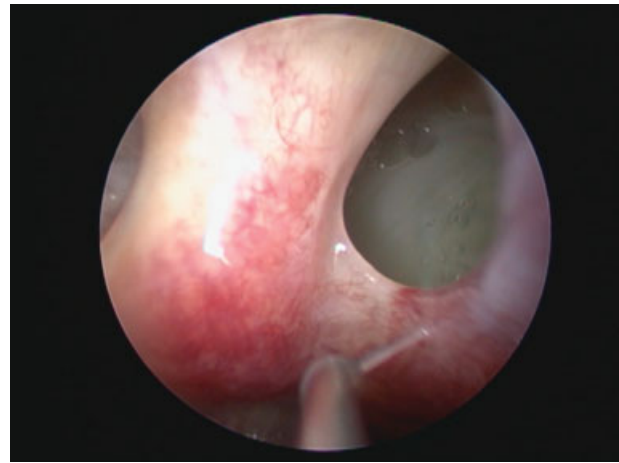


Fig. 3 Thick inspissated mucous covering the left maxillary sinus floor, visualized through the maxillary balloon dilation site. Same appointment as ►**Fig. 2**.

in-office dilation without a balloon device using a curved suction are potential additional benefits.

One observation found with the uncinectomy was improved visualization of and access to the ethmoid sinuses when performing a concomitant ethmoidectomy, because the uncinete process is often medialized with dilation of the infundibular space. As a theoretical problem-solving comment, if concern were to arise that formation of obstructive infundibular space synechiae could occur from mucosal trauma with the balloon device, partial or complete uncinectomy would prevent this from occurring. As aforementioned, the degree of uncinete process removal is determined by the surgeon at the time of the procedure to achieve the desired exposure.

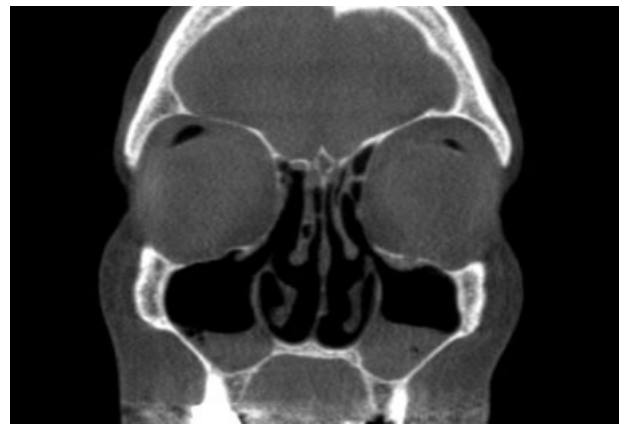

Fig. 4 Three-month postoperative sinus CT scan* frame demonstrating bilateral maxillary sinus air-fluid levels, and the postsurgical changes of the ethmoid surgery. A sinus CT scan was performed because of the maxillary sinus floor inspissated mucous found on nasal endoscopy in ►**Fig. 3**. The patient's only symptom complaint was postnasal drainage and cough. Both maxillary sinuses were suctioned of inspissated mucous and sent for culture. Same appointment as ►**Fig. 2**. The cultures showed no growth of bacteria. * Three hundred frame scans performed in this study using 0.09 mSev. Xoran MiniCAT™ Low Dose CT (MiniCAT™ Effective dose estimates. 5210 S. State Rd., Ann Arbor, MI 48108).

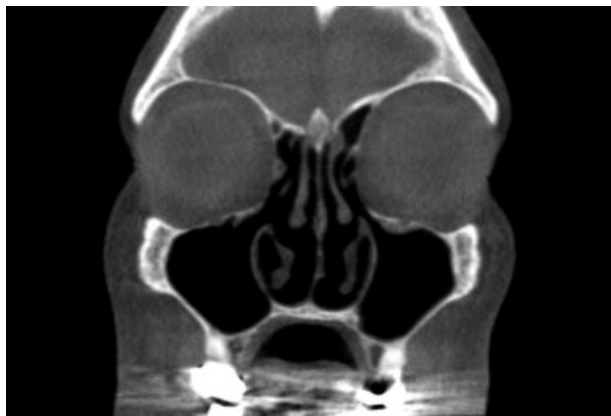

Fig. 5 Sinus CT scan* following suctioning of both maxillary sinuses. Same appointment as ►**Fig. 2**. Sinus culture results showed normal flora. The patient was placed on twice daily off-label Budesonide/saline nasal irrigation therapy for 2 weeks with continued nasal saline irrigation twice daily thereafter. There was no recurrence of inspissated mucous at the 9-month follow-up appointment, with resolution of symptoms.

* Three hundred frame scans performed in this study using 0.09 mSev. Xoran MiniCAT™ Low Dose CT (MiniCAT™ Effective dose estimates. 5210 S. State Rd., Ann Arbor, MI 48108).

Opening the “transition space” for the maxillary sinus by uncinectomy without enlarging a patent maxillary sinus natural ostia was presented by Setliff^{15,16} in the late 1990’s to describe the least invasive endoscopic sinus surgical approach at that time. Today, there appears to be a desire for a widely patent maxillary sinus opening. In this case series, the maxillary sinus natural ostia were stenosed closed secondary to soft tissue hypertrophy in all patients, even the two RARS patients, but using a balloon dilation device, this procedure is still less invasive than performing a surgical antrostomy with tissue removal at the natural ostium site, which is a desirable attribute with office rhinology.

Conclusion

This small retrospective case series found that partial or complete uncinectomy combined with maxillary sinus BSD was easily performed as an in-office procedure, with no intra-operative or postoperative complications, or late adverse sequelae encountered. All maxillary sinuses could be thoroughly inspected without radiographic imaging, and, if needed, instrument accessed at all follow-up visits over a minimum follow-up of 6 months.

A select subset of patients undergoing maxillary sinus BSD can potentially benefit from this modification, when theoretically compared with *the* standard maxillary sinus

BSD procedure currently used. Additional surgical situations in which this procedure modification could be useful are also described. A patient case is presented, highlighting the potential benefits of this procedure.

References

- 1 Stewart AE, Vaughan WC. Balloon sinuplasty versus surgical management of chronic rhinosinusitis. *Curr Allergy Asthma Rep* 2010;10(03):181–187
- 2 Karanfilov B, Silvers S, Pasha R, Sikand A, Shikani A, Sillers M; ORIOS2 Study Investigators. Office-based balloon sinus dilation: a prospective, multicenter study of 203 patients. *Int Forum Allergy Rhinol* 2013;3(05):404–411
- 3 Sikand A, Silvers SL, Pasha R, et al; ORIOS 2 Study Investigators. Office-based sinus dilation: 1-year follow-up of a prospective, multicenter study. *Ann Otol Rhinol Laryngol* 2015;124(08):630–637
- 4 Atkins J, Truitt T. In-office balloon dilation of the ethmoid infundibulum. *Oper Tech Otolaryngol* 2010;21(02):102–106
- 5 Gould J, Alexander I, Tomkin E, Brodner D. In-office, multisinus balloon dilation: 1-Year outcomes from a prospective, multicenter, open label trial. *Am J Rhinol Allergy* 2014;28(02):156–163
- 6 Mirante JP, Munier MA, Christmas DA Jr, Yanagisawa E. Balloon sinus dilation in the office setting. *Ear Nose Throat J* 2014;93(08):300–301
- 7 Albritton FD IV, Casiano RR, Sillers MJ. Feasibility of in-office endoscopic sinus surgery with balloon sinus dilation. *Am J Rhinol Allergy* 2012;26(03):243–248
- 8 Eloy JA, Shukla PA, Choudhry OJ, Eloy JD, Langer PD. In-office balloon dilation and drainage of frontal sinus mucocele. *Allergy Rhinol (Providence)* 2013;4(01):e36–e40
- 9 Sillers MJ, Melroy CT. In-office functional endoscopic sinus surgery for chronic rhinosinusitis utilizing balloon catheter dilation technology. *Curr Opin Otolaryngol Head Neck Surg* 2013;21(01):17–22
- 10 Byun JY, Lee JY. Usefulness of partial uncinectomy in patients with localized maxillary sinus pathology. *Am J Otolaryngol* 2014;35(05):594–597
- 11 Kennedy JL, Hubbard MA, Huyett P, Patrie JT, Borish L, Payne SC. Sino-nasal outcome test (SNOT-22): a predictor of postsurgical improvement in patients with chronic sinusitis. *Ann Allergy Asthma Immunol* 2013;111(04):246–251.e2
- 12 Okushi T, Nakayama T, Morimoto S, et al. A modified Lund-Mackay system for radiological evaluation of chronic rhinosinusitis. *Auris Nasus Larynx* 2013;40(06):548–553
- 13 Rosenfeld RM, Piccirillo JF, Chandrasekhar SS, et al. Clinical practice guideline (update): adult sinusitis. *Otolaryngol Head Neck Surg* 2015;152(2, Suppl):S1–S39
- 14 Donaldson M, Gizzarelli G, Chanpong B. Oral sedation: a primer on anxiolysis for the adult patient. *Anesth Prog* 2007;54(03):118–128, quiz 129
- 15 Setliff RC III. Minimally invasive sinus surgery: the rationale and the technique. *Otolaryngol Clin North Am* 1996;29(01):115–124
- 16 Setliff RC III. The small-hole technique in endoscopic sinus surgery. *Otolaryngol Clin North Am* 1997;30(03):341–354