



Use of halo fixation therapy for traumatic cranio-cervical instability in children: a systematic review

Mohammed Banat¹ · Martin Vychopen¹ · Johannes Wach¹ · Abdallah Salemdawod¹ · Jasmin Scorzin¹ · Hartmut Vatter¹

Received: 26 August 2021 / Accepted: 23 November 2021 / Published online: 9 December 2021
© The Author(s) 2021

Abstract

Purpose Traumatic cranio-cervical instability in childhood is rare and constitutes a challenge for the treating surgeon. The aim of therapy is to restore cervical stability without limiting the range of motion. The goal of this systematic review was to find out whether, over the last 10 years, halo fixation (HF) could still be considered a successful treatment option without major risks or complications.

Methods We analyzed studies describing the use of HF in traumatic injuries of the cranio-cervical junction in children under the age of 17. Searches were performed in PubMed, MEDLINE and Embase databases for the years from 2010 to 2020. The general success rate, the success rate related to underlying pathologies, and complication rates were evaluated.

Results The main indications for HF range from pre-surgical correction to postoperative fusion support. C2 is the most frequently injured vertebra in children. The overall success rate of HF was very high. Evaluation according to the underlying pathology showed that, except for atlanto-occipital dislocation, HF generates high fusion rates among different patient cohorts, mainly in C2 vertebra injuries and atlantoaxial rotatory subluxation. Only minor complications were reported, such as pin infections.

Conclusion The current data show that, when used according to the appropriate indication, HF is an effective conservative treatment option for cranio-cervical instability, associated with only minor complications.

Keywords Traumatic cranio-cervical instability · Pediatric · Halo fixation · Spine surgery

Abbreviations

AARS	Atlantoaxial rotatory subluxation
AOD	Atlanto-occipital dislocation
C1	First cervical vertebra
C2	Second cervical vertebra
CSI	Cervical spine injury
HF	Halo fixation
OCF	Occipital condyle fracture

Introduction

The use of halo fixation (HF) to treat cranio-cervical instability was first described in 1968 [32]. HF is in widespread use to treat a variety of disorders and pathologies in children

and adults [4, 7, 25, 33, 51]. The main indications for HF range from pre-surgical correction [8, 19, 28, 43] to postoperative fusion support [18, 21]. Used as an alternative to surgical treatment, HF enables the treating physician to preserve neck mobility and avoid side effects, such as restricted neck mobility and interference with spinal growth potential [8, 9, 28].

Traumatic cervical spine injuries in children are rare. Deciding whether to use HF to treat traumatic injuries of the upper cervical spine in children is challenging. The literature only records individual cases [36, 52] and series [12, 20, 40]. There are no standard recommendations for its pre-surgical or postoperative use, nor for its use as a conservative therapy option [3, 15, 27] or in combination with surgery [41, 51]. The decision to use HF has to consider possible complications as well as indications and the likelihood of success [9, 14, 23, 26, 34, 49].

The goal of this systematic review was to find out whether, over the last 10 years, HF could still be considered

✉ Mohammed Banat
Mohammed.Banat@ukbonn.de

¹ Department of Neurosurgery, University of Bonn, Venusberg-Campus 1, Building 81, 53127 Bonn, Germany

a successful treatment option without major risks or complications.

Methods

In this systemic review, we analyzed the success rates of HF for traumatic cervical instability in children. We searched the PubMed, MEDLINE and Embase databases for articles published between 2010 and 2020, using the terms “halo fixation”, “cranio-cervical instability”, and “cervical spine injury in children”. 488 papers were identified (after removal of duplicates). We included all clinical publications describing the use of HF as the primary therapy in traumatic injuries of the cranio-cervical junction. We excluded studies where HF was used for non-traumatic pathologies and for patients over the age of 17.

263 papers were excluded after title screening, and 165 were excluded after reviewing the abstract. After analysis of the full text, 41 further studies were excluded, resulting in 17 publications that fulfilled the inclusion criteria (Fig. 1).

The patient cohorts were stratified according to the most common underlying pathologies, namely atlanto-occipital dislocation (AOD), atlantoaxial rotatory subluxation (AARS), occipital condyle fracture (OCF), and traumatic injuries of the C2 vertebra.

Results

Summary of studies

Table 1 shows summary data from all included studies.

Atlanto-occipital dislocation (AOD)

We found two studies about HF therapy for AOD. Vachata et al. [48] reported that “two patients were in severe neurological states, with lesions of the upper cervical spinal cord and medulla oblongata on MRI, these patients were treated with external HF and died within 3 days of the trauma” [48]. In contrast, Able et al. recently reported that treatment with HF was a safe, viable, and definitive treatment option for selected children with AOD [1]. Although several factors biased their results, Able et al. reported good outcomes in eight out of ten patients with AOD (aged between newborn and 17) whose only therapy was external fixation with HF. The treatment lasted 3 months and only a pin-site complication was the only reported complication was pin-site complication [1].

Atlantoaxial rotatory subluxation (AARS)

We identified seven publications presenting conservative treatment with HF in patients with traumatic AARS. The results and success rates are presented in Table 2 [6, 11, 17, 29, 35, 44, 50].

Bakhshi et al. used primary pinless HF in 11 patients with an average age of 6.04 years. They reported success in every case [6].

Tauchi et al. treated seven children with HF. Six of these demonstrated remodeling of the deformed vertebra. Only one patient showed greater deformity and needed surgical C1-2 fixation [44]. Powel et al. [35] retrospectively describe a higher rate of traction in nine patients treated with HF (mean age 7.7 years). Two of these received secondary surgical fusion due to HF failure. Glotzbecker et al. reported

Fig. 1 Chart showing the search strategy

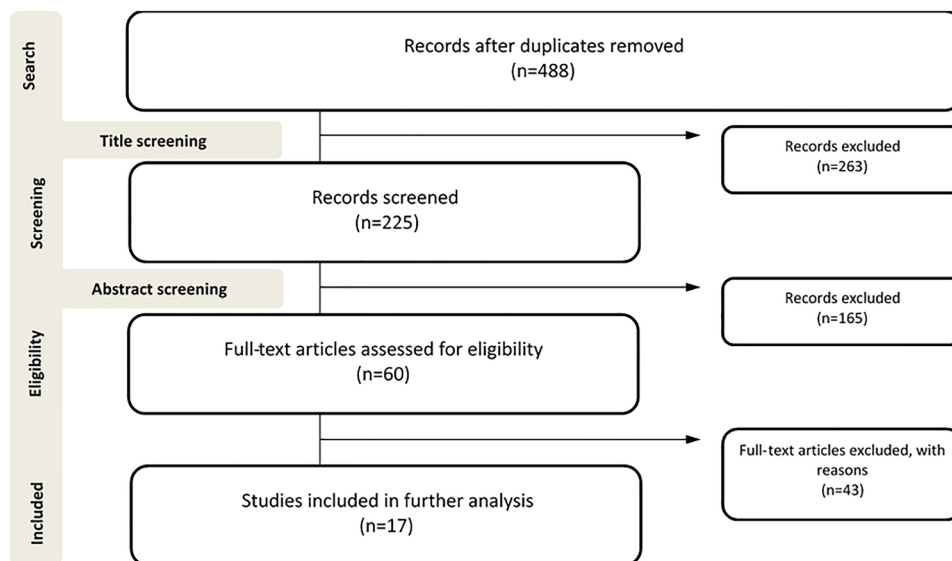


Table 1 Studies included

Study	Underlying pathology	Number of patients treated with HF	Treatment aim	Number of surgical conversions	Complications
Vachta 2020 [48]	AOD	4	Stabilization	1 secondary instrumentation	4 deaths
Abel T 2020 [11]	AOD	8	No fusion, neurologically intact, or stable	NA	Skin irritation
Powell 2017 [35]	AARS vs. CSI	9	NA		
Glantzbecker 2014 [17]	Immobilization	NA	NA		
	AARS	3	Fusion	NA	Neck pain, rotation reduced
Bakhshi 2015 [6]	AARS + OCF	11 AARS 2 OCF	Stability	NA	Skin irritation
Verhofste 2019 [50]	AARS	7	Fusion and angle correction	NA	Pin infection
Chechik 2013 [11]	AARS	1	Reduction of rotation and improve of motion	NA	NA
Misfud 2016 [29]	AARS	1	Fusion	NA	Pin infections
Tauchi 2011 [44]	AARS	2	Fusion and deformity correction	NA	NA
Tomaszewski 2018 [45]	C2 fracture	6	Fusion	NA	NA
Rusin 2015 [37]	C2 fracture	6	Fusion and correction of displaced and angulated fractures	NA	NA
Shamassian 2016 [39]	C2 fracture	1	Fusion	NA	NA
Tomaszewski 2014 [47]	Upper cervical spine fracture	6	Fusion	NA	Pin infection
Stulik 2013 [42]	Upper cervical spine fracture	4	Bone healing	NA	NA
Mitchell 2019 [30]	Upper cervical spine fracture	6 patients with HF in addition to surgery (after)	Fusion	NA	Pin infection
Hassler 2020 [18]	Injury of cranio-cervical junction	4 patients with HF in addition to surgery (after)	Fusion	NA	NA
Takahashi 2016 [43]	C1-2 fracture	1 patient with HF in addition to surgery (before)	NA	NA	NA

Table 2 Summary of studies with AARS

Study	HF treatment	Progression of subluxation	Surgically fused	HF successful
Powell et al. [35]	9	NA	NA	9
Glantzbecker et al. [17]	3 primary 1 secondary	NA	NA	3 NA
Bakhshi et al. [6]	11	NA	NA	11
Verhofste et al. [50]	7	NA	NA	7
Chechik et al. [11]	1	NA	NA	1
Misfud et al. [29]	1	NA	NA	1
Tauchi et al. [44]	2	NA	NA	2

on three patients with chronic traumatic AARS (average age of 7.2 years) who received primary conservative HF and another child who received secondary HF [17]. The only complication was mild neck pain and reduction of the cervical range of motion. Verhofste et al. reported that three out of seven patients successfully received primary HF and the other four received it in addition to surgery. Their mean age was 11.3 ± 5.58 years [50]. Chechik et al. successfully treated one girl, aged 7 [11]. Mifsud et al. reported on successful HF therapy for AARS [29].

Occipital condylar fracture (OCF)

Two patients with OCF were successfully treated with HF [6]. Mean therapy duration was 51 days. Skin irritation was the only reported complication. The average age was 12.61 years.

Traumatic injury of C2 vertebra

We identified eight studies, five of them favoring primary therapy with HF [37, 39, 42, 46, 47]. Takahashi et al. [43] used HF prior to surgery and other authors used it after surgery [18, 30]. The principal purpose of HF therapy for traumatic C2 fracture with instability is fusion or bone healing [39, 42, 46, 47].

a) Odontoid fracture—predominant injury in pediatric patients

C2 is the most commonly injured cervical vertebra in children [27]. This is due to the instability of the unfused odontoid synchondrosis (the final fusion happens between 5 and 7 years of age) [38]. The treatment of choice is HF with close radiological monitoring [16]. This enables the fracture to heal on its own, thus sparing the patient the limitation in movement reported after surgical fusion. The Neck Disability Index (NDI) for patients undergoing surgery because of C2 fracture can reach up to 44.4% [46], making HF the therapy of choice that prevents possible movement restrictions.

Surgical fixation is indicated for patients where HF failed to achieve fusion. Fulkerson et al. recommend that early surgical intervention should be considered in cases of odontoid angulation ($> 30^\circ$), significant displacement ($> 11\%$), and symptoms of spinal cord injury due to a higher probability of ligament disruption and greater instability of the fracture [16].

b) Synchondrosal fracture—new classification system

A new classification of C2 synchondrosal fractures in children has been proposed by Rusin et al. [37]. Type I fractures, described in 64% of the cases, were only treated with primary surgical fixation in two cases and with primary HF in six cases. HF failed to achieve

fusion in one patient and secondary surgical fixation was necessary. Type II fractures are rare, described in only two cases, and the therapy of choice was HF.

Primary surgical stabilization was mainly indicated for children with major displacement (subtype III). Subtype d fracture displacement was fatal in both cases [37]

c) Hangman's fracture—C2 injury

A hangman's fracture is a hyperextension C2 injury, which is almost exclusively seen in children under 2 years of age. The incidence increases again from the age of 16, and then has the same characteristics as C2 fractures in adults [38, 42]. The recommended treatment for a hangman's fracture varies according to the type and severity of the fracture instability. Types I and II are suitable for conservative treatment with HF, whereas patients with type IIA and III should undergo surgical instrumentation. However, internal fixation has a higher probability of secondary deformities and limitation in growth potential. HF seems to be beneficial not only in preserving movement capacity, but also in avoiding late consequences of surgery [31].

Discussion

Atlanto-occipital dislocation (AOD)

AOD is a devastating injury with high mortality, usually caused by high energy trauma [5, 40, 48]. Traction should be avoided because of the risk of deterioration [45]. The definitive treatment of traumatic AOD remains controversial, but a widely held view is that all patients with AOD should be treated with early surgical fusion (internal dorsal fixation and arthrodesis) [5, 45, 48]. In contrast to this opinion, external immobilization with HF on a small group of eight patients was found to be viable, safe and effective [1].

Atlantoaxial rotatory subluxation (AARS)

AARS is one of the more common cervical injuries which, due to their ligament elasticity, is found almost exclusively in children [35]. The decision of this study to prefer surgery to HF was based on the time from symptom onset, although very good outcomes have been described for delayed HF therapy in combination with traction [6, 11, 17, 24, 29, 35, 44, 50] or for delayed therapy with pinless HF [6]. The decision to prefer surgery to HF was based on the time from symptom onset. Although very good outcomes have been described after delayed therapy with HF [19, 29, 52], chronic pain lasting more than 6 weeks or acute neurological deficits are the most common indications for primary surgical therapy.

The main recommendation in the literature for this injury type is HF therapy.

Occipital condyle fracture (OCF)

OCF is a rare cervical spine injury after blunt trauma with a prevalence of 1.4–4.4% [3]. Generally, non-surgical management is recommended [6]. The Anderson–Montesano classification divides OCF into 3 types and non-surgical management with cervical orthosis is recommended for types 1 and 2 [3, 4]. External fixation with HF is recommended as a therapy of choice for OCT type 3 [37]. The possible complications, such as nerve palsies, are explained by pannus creation, which is not primarily associated with HF. Good healing chances are associated with immobilization for 1–3 months [3, 4]. Surgical fusion is indicated only in the case of severe brainstem compression or compression of the upper cervical spinal cord [22].

Traumatic injury of C2 vertebra

C2 is the most frequently injured cervical vertebra in children [27]. Successful conservative therapy avoids the limitations on movement reported after surgical fusion [39, 46]. Fulkerson et al. treated two patients with internal fixation and also reviewed similar cases in the literature. They recommended HF as the therapy of choice to prevent possible movement restrictions [16]. They also recommended considering early surgical intervention in cases of odontoid angulation ($> 30^\circ$), significant displacement, and symptoms of spinal cord injury, due to the higher probability of ligament disruption and the greater instability of the fracture. In line to above opinion recommended Rusin et al. his therapy management [37].

A hangman's fracture is a hyperextension C2 injury with upper cervical spine fracture, which is almost exclusively seen in children under the age of two. The incidence increases again from the age of 16, where it has the same characteristics as C2 fractures in adults [18, 30, 38, 42]. The recommended treatment for a hangman's fracture varies according to the type and severity of the fracture instability [2]. Unstable fractures should undergo surgical instrumentation [24, 30, 43]. The main recommendation for traumatic C2 injuries is primary treatment with HF. Cases with angulation or fracture displacement should be treated surgically with internal fixation.

Complications

Generally, HF was associated with only minor complications including pin loosening, pin tract infection, cranial nerve palsies, and vest-related pressure sores [1, 6, 29, 50]. An anatomical guide for safe pin placement, with recommended

pin sizes for different age groups, has been produced by Domenech-Fernandez et al. [13] and Chavasiri et al. [10].

The pinless halo was introduced to reduce the complications associated with HF pins [6]. Only one minor complication (skin irritation) was described in the literature we reviewed [6]. Because of the lack of data in this particular area, more studies are needed to evaluate the use of pinless HF in traumatic instabilities.

Conclusion

HF seems to play an important role in the treatment of traumatic cervical instabilities in pediatric patients. We suggest that primary therapy with HF is a safe and established procedure. However, there are cases that require treatment with HF in combination with surgery. Most of the studies we found were either retrospective cohort studies or single case series. We did not discover any controlled or randomized studies.

Limitations

Because of the low incidence of cranio-cervical injuries in children, all studies of HF between 2010 and 2020 provide only limited evidence. No randomized prospective trials on the treatment algorithm for cranio-cervical injuries have been conducted to date. Despite the wide use of HF as the conservative treatment of choice, the lack of clear indication criteria for surgical instrumentation prevents it being considered the standard choice of therapy. Another limitation of this work is that we only searched three databases.

Acknowledgements None.

Author contributions MB: Conceived, designed and performed the study, first draft of the manuscript and illustrations, analysis and interpretation of data. MV, JW, AS, JS: Critical review of the manuscript. HV: Critical review of the manuscript and supervision. The final manuscript was critically revised and approved by all authors.

Funding Open Access funding enabled and organized by Projekt DEAL. No funding was received for conducting this research.

Data availability All data generated or analyzed during this study are included in this published article.

Code availability Not applicable.

Declarations

Conflict of interest The authors report no conflicts of interest. The authors alone are responsible for the content and writing of this work.

Ethical approval All procedures performed were in accordance with the ethical standards of the institutional and national research committee (Ethics committee of the Rheinische Friedrich Wilhelms University Bonn) and with the 1964 Helsinki declaration and its later amendments or comparable ethical standards.

Study design Systematic review.

Consent to participate Not applicable.

Consent for publication The corresponding author transfers to the journal the non-exclusive publication rights and he warrants that his contribution is original and that he has full power to make this grant. The author signs for and accepts responsibility for releasing this material on behalf of any and all co-authors. This transfer of publication rights covers the non-exclusive right to reproduce and distribute the article, including reprints, translations, photographic reproductions, microform, electronic form (offline, online) or any other reproductions of similar nature.

Open Access This article is licensed under a Creative Commons Attribution 4.0 International License, which permits use, sharing, adaptation, distribution and reproduction in any medium or format, as long as you give appropriate credit to the original author(s) and the source, provide a link to the Creative Commons licence, and indicate if changes were made. The images or other third party material in this article are included in the article's Creative Commons licence, unless indicated otherwise in a credit line to the material. If material is not included in the article's Creative Commons licence and your intended use is not permitted by statutory regulation or exceeds the permitted use, you will need to obtain permission directly from the copyright holder. To view a copy of this licence, visit <http://creativecommons.org/licenses/by/4.0/>.

References

- Abel TJ, Yan H, Canty M, Remick M, Dewan M, Witiw C, Lamberti-Pasculi M, Drake JM. Traumatic atlanto-occipital dislocation in children: is external immobilization an option? *Child's Nervous Syst.* 2021;37:177–83.
- Al-Mahfoudh R, Beagrie C, Woolley E, Zakaria R, Radon M, Clark S, Pillay R, Wilby M. Management of Typical and Atypical Hangman's Fractures. *Global Spine J.* 2016;6:248–56.
- Anderson PA, Montesano PX. Morphology and treatment of occipital condyle fractures. *Spine.* 1988;13:731–6.
- Anderson RC, Ragel BT, Mocco J, Bohman LE, Brockmeyer DL. Selection of a rigid internal fixation construct for stabilization at the craniovertebral junction in pediatric patients. *J Neurosurg.* 2007;107:36–42.
- Astur N, Sawyer JR, Klimo P Jr, Kelly DM, Muhlbauer M, Warner WC Jr. Traumatic atlanto-occipital dislocation in children. *J Am Acad Orthop Surg.* 2014;22:274–82.
- Bakhshi H, Kushare I, Banskota B, Nelson C, Dormans JP. Pinless halo in the pediatric population: indications and complications. *J Pediatr Orthop.* 2015;35:374–8.
- Baum JA, Hanley EN Jr, Pallekines J. Comparison of halo complications in adults and children. *Spine.* 1989;14:251–2.
- Bono CM. The halo fixator. *J Am Acad Orthop Surg.* 2007;15:728–37.
- Bransford RJ, Stevens DW, Uyeji S, Bellabarba C, Chapman JR. Halo vest treatment of cervical spine injuries: a success and survivorship analysis. *Spine.* 2009;34:1561–6.
- Chavasiri C, Chavasiri S. The thickness of skull at the halo pin insertion site. *Spine.* 2011;36:1819–23.
- Chechik O, Wientroub S, Danino B, Lebel DE, Ovadia D. Successful conservative treatment for neglected rotatory atlantoaxial dislocation. *J Pediatr Orthop.* 2013;33:389–92.
- Dogan S, Safavi-Abbasi S, Theodore N, Horn E, ReKate HL, Sonntag VK. Pediatric subaxial cervical spine injuries: origins, management, and outcome in 51 patients. *Neurosurg Focus.* 2006;20:E1.
- Domenech-Fernandez P, Yamane J, Domenech J, Barrios C, Soldado-Carrera F, Knorr J, Canavese F. Analysis of skull bone thickness during growth: an anatomical guide for safe pin placement in halo fixation. *Euro Spine J.* 2021;30:410–5.
- Dormans JP, Criscitiello AA, Drummond DS, Davidson RS. Complications in children managed with immobilization in a halo vest. *The Journal of bone and joint surgery. American.* 1995;77:1370–3.
- Fassett DR, McCall T, Brockmeyer DL. Odontoid synchondrosis fractures in children. *Neurosurg Focus.* 2006;20:E7.
- Fulkerson DH, Hwang SW, Patel AJ, Jea A. Open reduction and internal fixation for angulated, unstable odontoid synchondrosis fractures in children: a safe alternative to halo fixation? *Journal of neurosurgery. Pediatrics.* 2012;9:35–41.
- Glottzbecker MP, Wasser AM, Hresko MT, Karlin LI, Emans JB, Hedequist DJ. Efficacy of nonfusion treatment for subacute and chronic atlanto-axial rotatory fixation in children. *J Pediatr Orthop.* 2014;34:490–5.
- Hassler KR, Jamshidi R, Vail SJ, Connell MJ, Chundu K, Lettieri SC, Feiz-Erfan I. Atlanto-Occipital Transarticular Screw Fixation for the Treatment of Traumatic Occipitocervical Instability in the Pediatric Population. *World Neurosurg.* 2020;140:e81–6.
- Herrada-Pineda T, Loyo-Varela M, Revilla-Pacheco F, Uribe-Leitz M, Manrique-Guzman S. Traumatic occipitocervical and atlanto-axial dislocation with clivus fracture in a child. Case report. *Cir Cir.* 2015;83:135–40.
- Hosalkar HS, Cain EL, Horn D, Chin KR, Dormans JP, Drummond DS. Traumatic atlanto-occipital dislocation in children. *The Journal of bone and joint surgery. American.* 2005;87:2480–8.
- Janjua MB, Hwang SW, Samdani AF, Pahys JM, Baaj AA, Hartl R, Greenfield JP. Instrumented arthrodesis for non-traumatic craniocervical instability in very young children. *Child's Nervous Syst.* 2019;35:97–106.
- Karam YR, Traynelis VC. Occipital condyle fractures. *Neurosurgery.* 2010;66:56–9.
- Limpaphayom N, Skaggs DL, McComb G, Krieger M, Tolo VT. Complications of halo use in children. *Spine.* 2009;34:779–84.
- Mahr D, Freigang V, Bhayana H, Kerschbaum M, Frankewycz B, Loibl M, Nerlich M, Baumann F (2019) Comprehensive treatment algorithm for atlanto-axial rotatory fixation (AARF) in children. *European journal of trauma and emergency surgery : official publication of the European Trauma Society*
- Majercik S, Tashjian RZ, Biffl WL, Harrington DT, Cioffi WG (2005) Halo vest immobilization in the elderly: a death sentence? *The Journal of trauma* 59:350–356; discussion 356–358
- Male KR, Guha A, James S, Ahuja S. Intracranial halo pin penetration causing brain injury secondary to poor halo care technique: a case report and literature review. *Cases J.* 2008;1:380.
- Mandabach M, Ruge JR, Hahn YS, McLone DG. Pediatric axis fractures: early halo immobilization, management and outcome. *Pediatr Neurosurg.* 1993;19:225–32.
- Mazur MD, Sivakumar W, Riva-Cambrin J, Jones J, Brockmeyer DL. Avoiding early complications and reoperation during occipitocervical fusion in pediatric patients. *J Neurosurg Pediatr.* 2014;14:465–75.

29. Mifsud M, Abela M, Wilson NI (2016) The delayed presentation of atlantoaxial rotatory fixation in children: a review of the management. *Bone Joint J.* 98-B:715–720
30. Mitchell A, Upasani VV, Bartley CE, Newton PO, Yaszay B. Rigid segmental cervical spine instrumentation is safe and efficacious in younger children. *Child's Nervous Syst.* 2019;35:985–90.
31. Montalbano M, Fisahn C, Loukas M, Oskouian RJ, Chapman JR, Tubbs RS. Pediatric hangman's fracture: a comprehensive review. *Pediatr Neurosurg.* 2017;52:145–50.
32. Nickel VL, Perry J, Garrett A, Heppenstall M (1989) The halo. A spinal skeletal traction fixation device. By Vernon L. Nickel, Jacquelin Perry, Alice Garrett, and Malcolm Heppenstall, 1968. *Clinical orthopaedics and related research*:4–11
33. Pang D, Li V (2005) Atlantoaxial rotatory fixation: part 3-a prospective study of the clinical manifestation, diagnosis, management, and outcome of children with atlantoaxial rotatory fixation. *Neurosurgery* 57:954–972; discussion 954–972
34. Papagelopoulos PJ, Sapkas GS, Kateros KT, Papadakis SA, Vlamis JA, Falagas ME. Halo pin intracranial penetration and epidural abscess in a patient with a previous cranioplasty: case report and review of the literature. *Spine.* 2001;26:E463–467.
35. Powell EC, Leonard JR, Olsen CS, Jaffe DM, Anders J, Leonard JC. Atlantoaxial rotatory subluxation in children. *Pediatr Emerg Care.* 2017;33:86–91.
36. Reinges MH, Mayfrank L, Rohde V, Spetzger U, Gilsbach JM. Surgically treated traumatic synchondrotic disruption of the odontoid process in a 15-month-old girl. *Child's Nervous Syst.* 1998;14:85–7.
37. Rusin JA, Ruess L, Daulton RS. New C2 synchondrosal fracture classification system. *Pediatr Radiol.* 2015;45:872–81.
38. Schrodel M, Hertlein H. Spinal injuries in children and adolescents. *Unfallchirurg.* 2013;116(1054):1056–61.
39. Shammassian B, Wright CH, Wright J, Onwuzulike TKL. Successful delayed non-operative management of C2 neurosynchondrosis fractures in a pediatric patient: a case report and review of management strategies and considerations for treatment. *Child's Nervous Syst.* 2016;32:163–8.
40. Steinmetz MP, Lechner RM, Anderson JS (2003) Atlantooccipital dislocation in children: presentation, diagnosis, and management. *Neurosurgical focus* 14:ecp1
41. Steinmetz MP, Verrees M, Anderson JS, Lechner RM. Dual-strap augmentation of a halo orthosis in the treatment of atlantooccipital dislocation in infants and young children. Technical note. *J Neurosurg.* 2002;96:346–9.
42. Stulik J, Nesnidal P, Kryl J, Vyskocil T, Barna M. Unstable injuries to the upper cervical spine in children and adolescents. *Acta Chir Orthop Traumatol Cech.* 2013;80:106–13.
43. Takahashi J, Hirabayashi H, Hashidate H, Ogihara N, Mukaiyama K, Komatsu M, Inaba Y, Kosho T, Kato H. Challenges of transarticular screw fixation in young children: report of surgical treatment of a 5-year-old patient's unstable os-odontoidum. *Asian Spine J.* 2016;10:950–4.
44. Tauchi R, Imagama S, Kanemura T, Yoshihara H, Sato K, Deguchi M, Kamiya M, Ishiguro N. The treatment of refractory atlantoaxial rotatory fixation using a halo vest: results of a case series involving seven children. *The Journal of bone and joint surgery. British.* 2011;93:1084–7.
45. Theodore N, Aarabi B, Dhall SS, Gelb DE, Hurlbert RJ, Rozzelle CJ, Ryken TC, Walters BC, Hadley MN. The diagnosis and management of traumatic atlanto-occipital dislocation injuries. *Neurosurgery.* 2013;72(Suppl 2):114–26.
46. Tomaszewski R, Koszutski T. Treatment of the dens fractures in children. *Neurol Neurochir Pol.* 2018;52:618–22.
47. Tomaszewski R, Pyzinska M. Treatment of cervical spine fractures with halo vest method in children and young people. *Ortop Traumatol Rehabil.* 2014;16:449–54.
48. Vachata P, Bolcha M, Lodin J, Sames M. Atlanto-occipital dissociation. *Rozhledy v chirurgii : mesicnik Ceskoslovenske chirurgicke spolecnosti.* 2020;99:22–8.
49. van Middendorp JJ, Slooff WB, Nellestein WR, Oner FC. Incidence of and risk factors for complications associated with halo-vest immobilization: a prospective, descriptive cohort study of 239 patients. *The Journal of bone and joint surgery. American.* 2009;91:71–9.
50. Verhofste BP, Glotzbecker MP, Birch CM, O'Neill NP, Hedequist DJ (2019) Halo-gravity traction for the treatment of pediatric cervical spine disorders. *Journal of neurosurgery. Pediatrics*:1–10
51. Vieweg U, Schultheiss R. A review of halo vest treatment of upper cervical spine injuries. *Arch Orthop Trauma Surg.* 2001;121:50–5.
52. Vining DJ, Benzel EC, Orrison W. Childhood odontoid fractures evaluated with computerized tomography. Case report. *J Neurosurg.* 1992;77:795–8.