

## Case Report

Junko Yamaguchi, Akihiro Noda, Akira Utagawa, Atsushi Sakurai, Kosaku Kinoshita\*

# Pediatric acute paradoxical cerebral embolism with pulmonary embolism caused by extremely small patent foramen ovale

<https://doi.org/10.1515/med-2019-0002>

received July 24, 2018; accepted November 5, 2018

**Abstract:** Herein, we report a pediatric case of acute paradoxical cerebral embolism complicated by serious acute pulmonary embolism that was caused by an extremely small patent foramen ovale (PFO). The patient had no medical history suggestive of any other reason.

Paradoxical cerebral embolism may occur even with an extremely small PFO because of the increased right-side pressure of the heart and a resulting right-to-left shunt from the acute pulmonary embolism. Although pediatric cases of pulmonary embolism are rare, when diagnosed, clinicians should consider the risk of a concurrent paradoxical cerebral embolism resulting from a latent PFO. The possibility of PFO should be assessed extremely carefully in pediatric critical care by checking for a thrombogenesis tendency and the existence of deep vein thrombosis in the patient.

**Keywords:** Pediatric pulmonary embolism; Patent foramen ovale (PFO); Paradoxical cerebral embolism, Diameter of PFO; Right-to-left shunt.

---

\*Corresponding author: **Kosaku Kinoshita**, Division of Emergency and Critical Care Medicine, Department of Acute Medicine, Nihon University School of Medicine, 30-1 Oyaguchi Kamimachi, Itabashi-ku, Tokyo 173-8610, Japan, Tel: +81-3-3972-8111, Ext: 2800, 2826, Fax: +81-3-5964-8037, E-mail: kinoshita.kosaku@nihon-u.ac.jp  
**Junko Yamaguchi, Akihiro Noda, Akira Utagawa, Atsushi Sakurai**, Division of Emergency and Critical Care Medicine, Department of Acute Medicine, Nihon University School of Medicine, 30-1 Oyaguchi Kamimachi, Itabashi-ku, Tokyo 173-8610, Japan

## 1 Introduction

We examined a pediatric case of acute paradoxical cerebral embolism complicated by serious acute pulmonary embolism; this was caused by an extremely small patent foramen ovale (PFO). The patient had no noteworthy medical history suggestive of any other reason.

Paradoxical cerebral embolism may occur even with an extremely small PFO, resulting from the increased right-side pressure of the heart and a resulting right-to-left shunt from the acute pulmonary embolism. Although pediatric cases of pulmonary embolism are rare, on diagnosis clinicians should consider the risk of a concurrent paradoxical cerebral embolism due to a latent PFO. The PFO should be assessed with exceptional care in pediatric critical care by checking for a thrombogenic tendency and the existence of deep vein thrombosis in the patient.

## 2 Case report

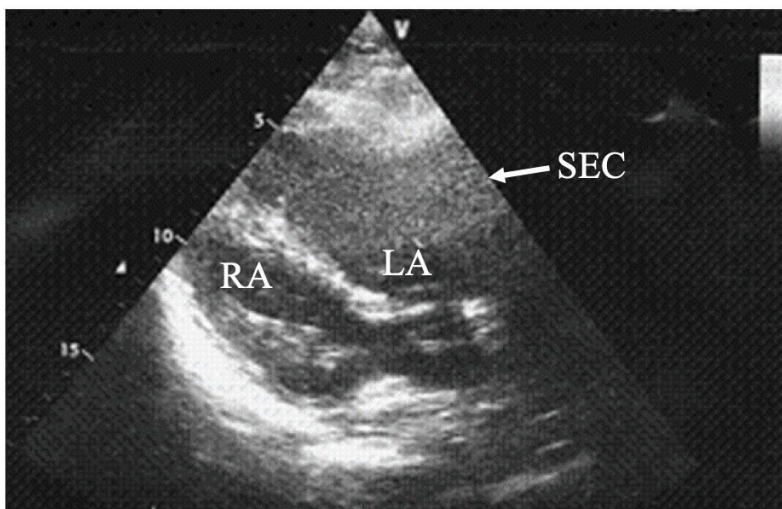
The patient was a boy of high school age with no relevant prior medical history. Four days before admission to the hospital, he experienced coughing and a runny nose. One day before admission, he was diagnosed with a common-form of pneumonia by the local physician and returned home. However, he later presented to the hospital emergency department due to breathing difficulty and disturbed consciousness.

The S I Q III T III pattern with sinus tachycardia was observed using a 12-lead electrocardiogram, and the knuckle sign was observed on chest X-ray. On transthoracic echocardiography, enlargement of the right ventricle, and left ventricular collapse were observed. The tricuspid regurgitation pressure gradient (TR-PG) was high, at 39.7 mmHg (normal range: 5–10 mmHg). The presence of foramen ovale was not clinically evident. Moreover, on transthoracic echocardiogram, spontaneous echo contrast (SEC) (Fig. 1a), which predicts formation of throm-

bus, could be observed. Thrombus was observed on both sides of the pulmonary artery with contrast enhanced computed tomography (CT) (Fig. 1b), but deep vein thrombosis of the legs could not be confirmed.

A low-density area indicative of cerebral infarction in the left middle cerebral artery area was observed on brain CT when the patient entered the operating room (Fig. 2). Acute respiratory failure due to acute pulmonary embolism was diagnosed and open pulmonary embolectomy was performed with the assistance of emergency extracorporeal circulation on the same day. Multiple embolisms were removed from the left and right sides of the pulmonary artery. A right-to-left shunt due to patent foramen ovale (PFO) was observed using intraoperative transesophageal cardiac ultrasonography; the diameter of the PFO was approximately 2 mm. PFO closure was performed at the same time and extracorporeal circulation was discontinued on the following day. The patient's family history indicated that his father had received warfarin anticoagulant treatment for deep vein thrombosis; however, no clear thrombotic predisposition or irregular heartbeat was observed as a possible cause of the cerebral infarction. The concentrations of plasma Protein C, Protein S, and antithrombin were normal. Four days before admission to the hospital, the patient had experienced coughing and a runny nose, but he was not suffering from severe infection and did not require extended bedrest. We concluded that there was no clear thrombotic predisposition factor.

Ethical approval: The research related to human use has been complied with all the relevant national regulations, a.



**Figure 1:** a. A transesophageal echocardiogram, in which the transthoracic echocardiogram view shows significant spontaneous echo contrast (SEC) in the left atrium (LA) (arrow), compared with the right atrium (RA); this predicts formation of thrombus.

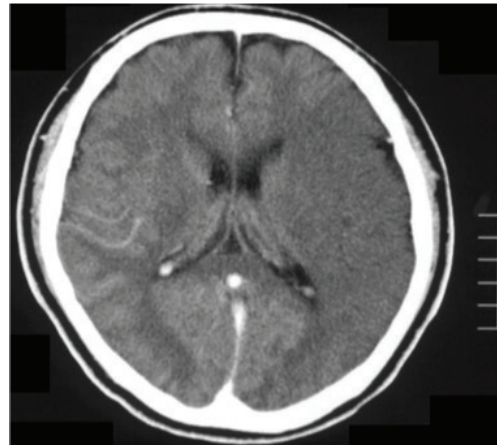
b. Thrombus was observed on both sides of the pulmonary artery (arrow) with contrast-enhanced computed tomography.

institutional policies and in accordance the tenets of the Helsinki Declaration, and has been approved by the authors' institutional review board or equivalent committee.

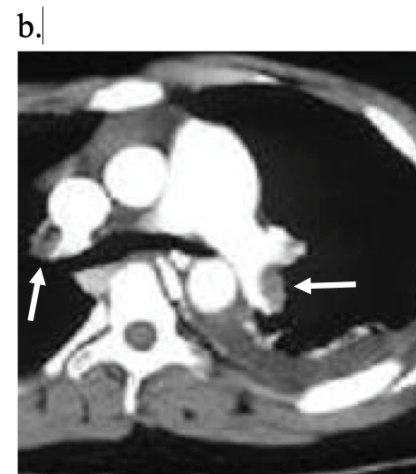Informed consent: Informed consent has been obtained from patients's family in this study.

### 3 Discussion

Cerebral infarction due to paradoxical cerebral embolism and a blood coagulation disorder can cause pediatric brain infarction. General autopsy reports show a PFO prevalence rate of 26% [1]. PFO can cause paradoxical



**Figure 2:** A low-density area indicating brain infarction in the left middle cerebral artery area was observed on brain computed tomography upon entering the operating room.



cerebral embolism, where thrombus in the venous system flows into the left side of the heart through the right-to-left shunt. In cases involving brain infarction of indeterminate cause in young people, PFO has been confirmed in 40% of the cases [2]; it is considered to be an important cause of pediatric brain infarction. However, cerebral embolism in a patient complicated with PFO does not always result in paradoxical cerebral embolism. Therefore, in patients who exhibit cerebral embolism with PFO, there must be an exclusion mechanism that enables the formation of cerebral embolism other than paradoxical cerebral embolism [2]. In contrast, there has been less discussion regarding latent and clinically undetectable PFO, including the so-called probe patency of the oval foramen [3], related to paradoxical cerebral embolism. Pediatric deep vein thrombosis occurs at a rate of 0.07 to 0.14 per 10,000 children [4] and is less frequent than in adults (approximately 2 to 20 per 10,000) [5]. The incidence increases markedly with age [5]. Because the frequency of latent PFO is higher in young children, when clinical conditions are complicated by increased right-sided pressure of the heart, the possibility of PFO should be confirmed using transthoracic echocardiography and transesophageal ultrasonography. Careful assessment of PFO is important for pediatric critical care.

Diagnosis of paradoxical cerebral embolism is determined by consideration of neuroradiologic characteristics indicative of cerebral infarction and deep venous thrombosis, with or without other embolic sources [6]. A larger PFO increases the risk of brain embolism [7]. However, general autopsy reports have shown that the average PFO size is 4.9 mm; 86% of PFOs are 2 to 8 mm in size. Notably, a thrombosis of 1 to 2 mm can cause cerebral infarction because paradoxical cerebral infarction is induced by the PFO itself, regardless of the size of the thrombosis [8]. Notably, paradoxical cerebral embolisms are formed by thrombus in the venous system, which flows into the left side of the heart through the right-to-left shunt. Therefore, the frequency of paradoxical cerebral infarction might not be much higher than the rate of PFO occurrence.

Pulmonary embolism can rapidly increase right-sided pressure of the heart, and a right-to-left shunt can occur even with an extremely small PFO, causing brain embolism. Even in cases of asymptomatic or clinically undetectable PFO in young children, physicians must recognize the risk of paradoxical cerebral embolism caused by increased right-sided pressure of the heart, such as pulmonary embolism [9, 10] because of the high prevalence rate of latent PFO.

Probe patency of the oval foramen has been considered because it does not allow intracardiac shunting of blood [3]. There might be a risk of paradoxical cerebral embolism when the right-side pressure of the heart increases as a result of pulmonary embolism. This is an important case, showing that even an extremely small foramen ovale can cause paradoxical cerebral embolism: it indicates the need for primary prevention of brain embolism for patients with PFO. With respect to the risk of a cerebral infarction in patients with atrial fibrillation, even if a thrombus in the left atrial appendage cannot be detected, it has been proven that a spontaneous echo contrast grade correlates with an increase in and coagulation of red blood cells through stagnation of the blood flow, whereas a high grade of spontaneous echo contrast as well as cases in which peak antegrade flow velocity of the left atrial appendage is 20 cm/second or less represent a risk of cerebral ischemia [11]. We suspect that detecting a general risk of embolism before its onset would have been difficult because the foramen ovale was very small in this case and the risk of a congenital thrombosis was not present. However, to assess the risk of a cardiogenic cerebral embolism prior to its onset in patients with foramen ovale, we believe it would be effective to assess the blood flow rate. Additionally, presence of a right to left shunt through transesophageal echocardiogram (TEE) or transthoracic echocardiogram (TTE) contrast, as well as a presence of spontaneous echo contrast and its grade, should also be considered.

In conclusion, we have reported an instructive case history that involved paradoxical cerebral embolism due to acute pulmonary embolism and PFO; we have described our imaging results. Although the diameter of the PFO was extremely small, right-sided pressure of the heart rapidly increased due to pulmonary embolism. Also, a right-to-left shunt occurred in the small diameter foramen ovale; this was suspected to have caused the brain embolism. Cases of pulmonary embolism in children are rare; however, when, diagnosed, the risk of paradoxical cerebral embolism due to PFO should be taken under consideration: it is necessary to identify whether PFO is present to prevent paradoxical cerebral embolism.

**Acknowledgements:** None.

**Conflicts of interest:** All authors declare no conflicts of interest.

## References

- [1] Homma S., Sacco R.L. Patent foramen ovale and stroke, *Circulation*, 2005,112,1063-1072
- [2] Lechat P., Mas J.L., Lascault, G., Loron, P., Theard, M., Klimczac, M., et al. Prevalence of Patent Foramen Ovale in Patients with Stroke, *N. Engl. J. Med.*, 1988, 318, 1148-1152
- [3] Saldler T.W. Cardiovascular system, in Landman's Medical Embryology (10th ed.), Philadelphia: Lippincott Williams & Wilkins, pp.159-194, 2006
- [4] Humes D.J., Nordenskjold A., Walker A.J., West J., Ludvigsson J.F. Risk of venous thromboembolism in children after general surgery, *J. Pediatr. Surg.*, 2015, 50,1870-1873
- [5] Fowkes F.J., Price J.F., Fowkes F.G. Incidence of diagnosed deep vein thrombosis in the general population: systematic review. *Eur. J. Vasc. Endovasc. Surg.*, 2003, 25,1-5
- [6] Yasaka M., Otsubo R., Oe H., Minematsu K. Is stroke a paradoxical embolism in patients with patent foramen ovale? *Intern. Med. (Tokyo, Japan)*, 2005, 44, 434-438
- [7] Cabanes L., Mas J.L., Cohen A., Amarenco P., Cabanes P.A., Oubary P., et al. Atrial septal aneurysm and patent foramen ovale as risk factors for cryptogenic stroke in patients less than 55 years of age. A study using transesophageal echocardiography, *Stroke*, 1993, 24, 1865-1873
- [8] Hagen P.T., Scholz D.G., Edwards W.D. Incidence and size of patent foramen ovale during the first 10 decades of life: an autopsy study of 965 normal hearts, *Mayo Clin. Proc.*, 1984, 59, 17-20
- [9] Dada R.,Dada J.,Abdelsalam M.,Agrawal Y. Thrombus straddling a patent foramen ovale, pulmonary embolism and paradoxical embolism: a rare trifecta. *BMJ Case Rep*, 2018 bcr-2018-227505
- [10] Zoltowska DM.,Agrawal Y.,Gupta V., Kalavakunta JK. Massive thrombus trapped within an atrial septal defect. *BMJ Case Rep*, 2018 bcr-2018-225647
- [11] Transesophageal echocardiographic correlates of thromboembolism in high-risk patients with nonvalvular atrial fibrillation. The Stroke Prevention in Atrial Fibrillation Investigators Committee on Echocardiography. *Ann. Intern. Med.* 1998, 128, 639-647