



Pharyngeal flap damage caused by nasotracheal intubation in a patient who underwent palatoplasty and pharyngoplasty

Jong-Shik Oh¹, Hong-Seok Choi¹, Eun-Jung Kim², Cheul-Hong Kim², Ji-Uk Yoon³, Ji-Young Yoon²

¹Department of Oral and Maxillofacial Surgery, School of Dentistry, Pusan National University, Yangsan, Korea

²Department of Dental Anesthesia and Pain Medicine, Pusan National University Dental Hospital, Dental Research Institute, Yangsan, Korea.

³Department of Anesthesia and Pain Medicine, Pusan National University Yangsan Hospital, Yangsan, Korea

Patients with cleft lip and palate (CLP) must undergo corrective surgeries during infancy and early childhood. Many patients with CLP undergo orthognathic surgery during their childhood for correction of skeletal asymmetries or pharyngoplasty with a pharyngeal flap to improve the quality of speech and velopharyngeal function. During orthognathic surgeries, nasotracheal intubation is performed under general anesthesia. In our case report, the patient had undergone palatoplasty and pharyngoplasty previously. During the orthognathic surgery, a flexible fiberoptic bronchoscope-guided nasotracheal tube was inserted through the pharyngeal flap ostium; however, active bleeding occurred in the nasopharynx. Bleeding occurred because the flap was torn. After achieving hemostasis, the surgery was completed successfully. Thus, if a patient may show the potential for velopharyngeal port obstruction, nasotracheal intubation should be performed with utmost care.

Keywords: Complication; Flap; Intubation; Tears.

This is an Open Access article distributed under the terms of the Creative Commons Attribution Non-Commercial License (<http://creativecommons.org/licenses/by-nc/3.0/>) which permits unrestricted non-commercial use, distribution, and reproduction in any medium, provided the original work is properly cited.

Nasotracheal intubation (NTI) is a common procedure performed in the operating room, especially in patients undergoing oral and maxillofacial surgeries. NTI improves the efficiency of surgical procedures for intra-oral pathological anomalies, structural abnormalities, and maxillofacial fracture and orthognathic surgery [1]. However, NTI may cause complications if the tube comes in contact with the surrounding structures when it passes through the nasopharynx and oropharynx. The incidence of cleft lip and palate (CLP) was 1 per 554 births in the Republic of Korea. Up to 20% of patients with cleft palate will develop velopharyngeal dysfunction after primary palatoplasty, requiring further treatment with pharyngo-

plasty [2]. Many patients will undergo further orthognathic surgeries, and NTI is performed under general anesthesia during these surgeries. If a pharyngeal flap is present, NTI can lead to tearing of the flap, which may result in a traumatic massive hemorrhage. In this case report, we describe a case of NTI-related pharyngeal flap damage in a patient who underwent palatoplasty and pharyngoplasty previously.

CASE REPORT

A 20-year-old man (height, 177 cm; weight, 60 kg)

Received: 2016. December. 16. • Revised: 2016. December. 19. • Accepted: 2016. December. 19.

Corresponding Author: Ji-Young Yoon, Department of Dental Anesthesia and Pain Medicine, Pusan National University Dental Hospital, Geumo-ro 20, Yangsan, Gyeongnam, 626-787, Republic of Korea

Tel: +82-55-360-5370 Fax: +82-55-360-5369 E-mail: dryoonji@pusan.ac.kr

Copyright© 2016 Journal of Dental Anesthesia and Pain Medicine

was hospitalized for an orthognathic surgery. He was diagnosed with bilateral CLP and mandibular prognathism associated with midface deficiency, and was scheduled to undergo LeFort I osteotomy, right iliac block bone graft procedure, and bilateral sagittal split osteotomy. He had previously undergone cheiloplasty, palatoplasty, cleft maxillary repair, and pharyngoplasty to correct the CLP. Preoperative laboratory findings, chest X-ray image, and electrocardiogram were normal. He had no other diseases, including upper airway obstruction or obstructive sleep apnea symptoms.

He had maxillary deficiency with malocclusion, mandibular prognathism, a scar due to a pharyngeal flap, and cheiloplasty. As a premedication, glycopyrolate (0.2 mg) was injected intramuscularly. Standard monitoring was performed in the operating room. After preoxygenation with 100% oxygen, general anesthesia was induced with remifentanyl (1 μ g/kg), propofol (120 mg), and rocuronium (50 mg). After providing adequate muscle relaxation, flexible fiberoptic bronchoscope (FFB)-guided NTI was attempted using a nasotracheal tube (NTT) of 6.5 mm internal diameter; this procedure was performed instead of a direct rigid laryngoscope because FFB technique and smaller sized NTT are more suitable for adults who have intact pharyngeal flaps. The FFB was inserted into the both nostrils for examination and passed through the posterior pharynx; we observed that the

velopharyngeal port (between the nasopharynx and oropharynx) was divided into two small-sized pharyngeal ports by the pharyngeal flap (Fig. 1). Because right side of pharyngeal port was a little wider, a scope was passed carefully through the right side pharyngeal port and vocal cords to the carina; NTT was passed over the FFB smoothly. There was no specific resistance during NTT insertion, but minor bleeding appeared on the nasopharynx. After the intubation, the patient was mechanically ventilated to administer desflurane (6 vol%), with a fresh gas flow rate of 3 L/min and 50% oxygen in air. After the induction of anesthesia, active bleeding was observed in the mouth immediately. To assess the bleeding focus, we examined the oral cavity with a dental mirror, and bleeding was seen at the pharyngeal flap. The flap was probably torn at the time of the NTI. Subsequently, hemostasis was achieved using a 4 × 4 gauze moistened with 1:1000 epinephrine solution. After the bleeding was controlled, cotton swabs soaked in 2% lidocaine and 1:1000 epinephrine were inserted into the torn flap and nostril. Subsequently, the pharyngeal bleeding stopped, and the surgery was completed without further complications. After the surgery, the patient recovered without any problems. A follow-up examination using a nasendoscopic view that was performed two years later showed that the pharyngeal

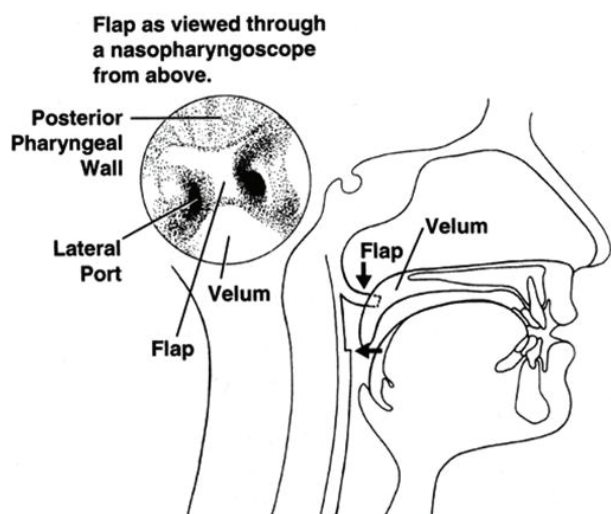


Fig. 1. Nasopharyngoscopic view of velopharyngeal port and flap.

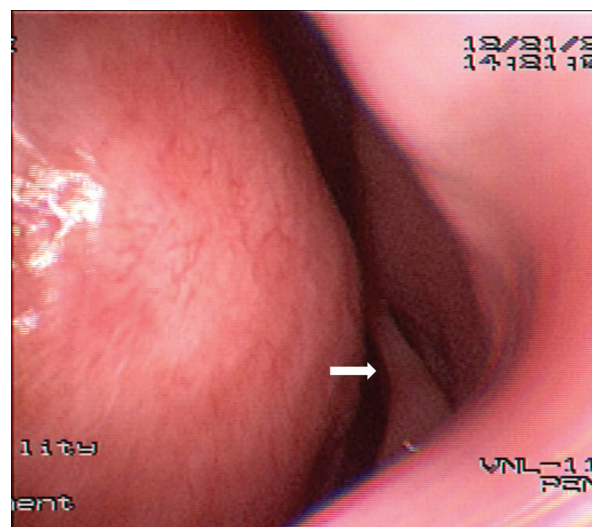


Fig. 2. Postoperative nasendoscopic examination shows intact pharyngeal flap (arrow).

flap remained intact after the recovery (Fig. 2). For this case presentation, we received consent from the patient.

DISCUSSION

Patients with congenital CLP must undergo a number of corrective surgical procedures during their infancy and early childhood. The scars that result from these procedures have been shown to affect the growth of the maxilla, and this often leads to maxillary deficiency [3]. Many patients with CLP require orthognathic surgery during their childhood for the correction of the skeletal asymmetry and often pharyngoplasty is performed with pharyngeal flap (in 20% of patients) to improve the quality of speech and velopharyngeal function [4]. This procedure causes a scar that obstructs the velopharyngeal port. Thus, the pharyngeal flap can be damaged during NTI, and it can lead to significant bleeding, thereby causing damage to the airway.

Bell et al. suggested that preoperative nasendoscopy must be performed in patients who underwent pharyngoplasty previously and were scheduled to undergo NTI [5]. Nasendoscopy is a minor procedure that is usually performed in the ear-nose-throat clinic to assess the structures of the nose and throat. This is useful for evaluating the position, shape, and size of the velopharyngeal port. However, this procedure requires the cooperation of the patient; hence, performing this procedure in patients below 6 years of age can be difficult [6].

A few guidelines for performing NTI in patients with a pharyngeal flap have been provided in the literature. For minimizing the damage to a pharyngeal flap, it is essential to establish some strategies for performing NTI in these patients. First, a suitable vasoconstrictor should be used prior to intubation. If pharyngoplasty is performed in patients without a nasendoscopic examination, a vasoconstrictor preparation should be applied to the velopharyngeal port to prevent bleeding [7]. In our case, hemostasis was achieved with 2% lidocaine and 1:1000

epinephrine solutions. However, prior to the insertion of FFB and NTT through the nose, it would be better to pre-treat the velopharyngeal port with a vasoconstrictor. The bleeding due to turbinates and septum damage also interferes with visualization; thus, it is necessary to pre-treat the nose with a vasoconstrictor. Second, after checking the pharyngeal flap with nasendoscopy, FFB must be used to visualize the pharyngeal flap ostium [8]. Furthermore, FFB-guided NTI must be performed with utmost care because NTI can injure the flap. Epistaxis is the most frequently observed complication, with an incidence ranging from 10% to 80% [9]. Other complications include impingement of the endotracheal tube (ETT) in the subglottic region, thereby further hindering the advancement of the tube after passing the glottis; sinusitis; bacteremia; and dislodgement of the adenoids [10-12]. In addition, pharyngoesophageal perforation and inadvertent intracranial placement of NTT have also been reported [13]. Third, small-sized NTT should be used, and the tube may also be softened by soaking it in warm saline and well lubricated with lidocaine jelly to decrease the incidence of epistaxis and pharyngeal flap damage [14].

This case report emphasizes that thorough history taking of the patient is essential. If a patient who has a possibility of velopharyngeal obstruction undergoes oral maxillofacial surgery, the aforementioned strategies must be followed to prevent the damage of pharyngeal flap.

ACKNOWLEDGMENTS: This study was supported by 2015 Clinical Research Grant, Pusan National University Dental Hospital

REFERENCES

1. Kopp VJ, Rosenfeld MJ, Turvey TA. Nasotracheal intubation in the presence of pharyngeal flap in children and adults. *Anesthesiology* 1995; 82: 1063-4.
2. Hee HI, Conskunfirat ND, Wong SY, Chen C. Airway

- management in a patient with a cleft palate after pharyngoplasty: a case report. *Can J Anesth* 2003; 50: 721-24.
3. Panula K, Lorus BB, Pospisil OA. The need for orthognathic surgery in patients born with complete cleft palate or complete unilateral cleft lip and palate. *Oral Surg Oral Diag* 1993; 4: 23-8.
 4. Davies. D. Cleft lip and palate: *British Medical Journal* 1985; 290: 625.
 5. Bell DN, Macintyre DR, Ross JW, Pigott RW, Weller RM. Pharyngoplasty: a hazard for nasotracheal intubation. *Br J Oral Maxillofac Surg* 1986; 24: 212-6.
 6. Robin NH, Baty H, Franklin J, Guyton FC, Mann J, Woolley AL, et al. The multidisciplinary evaluation and management of cleft lip and palate. *South Med J* 2006; 99: 1111-20.
 7. Piepho T, Thierbach A, Werner C. Nasotracheal intubation: look before you leap. *Br J Anaesth* 2005; 94: 859-60.
 8. Enk D, Palmes AM, Van Aken H, Westphal M. Nasotracheal intubation: a simple and effective technique to reduce nasopharyngeal trauma and tube contamination. *Anesth Analg* 2002; 95: 1432-6.
 9. Kihara S, Komatsuzaki T, Brimacombe JR, Yaguchi Y, Taguchi N, Watanabe S. A silicone-based wire reinforced tracheal tube with a hemispherical bevel reduces nasal morbidity for nasotracheal intubation. *Anesth Analg* 2003; 97: 1488-91.
 10. Hansen M, Poulsen MR, Bendixen DK, Hartmann-Andersen F. Incidence of sinusitis in patients with nasotracheal intubation. *Br J Anaesth* 1988; 61: 231-2.
 11. Onçag O, Cokmez B, Aydemir S, Balcioglu T. Investigation of bacteremia following nasotracheal intubation. *Paediatr Anaesth* 2005; 15: 194-8.
 12. Ng SY, Yew WS. Nasotracheal tube occlusion from adenoid trauma. *Anaesth Intensive Care* 2006; 34: 829-30.
 13. Krebs MJ, Sakai T. Retropharyngeal dissection during nasotracheal intubation: a rare complication and its Management. *J Clin Anesth* 2008; 20: 218-21.
 14. Kim YC, Lee SH, Noh GJ, Cho SY, Yeom JH, Shin WJ et al. Thermosoftening Treatment of the nasotracheal tube before intubation can reduce epistaxis and nasal damage. *Anesth Analg* 2000; 91: 698-701.