

# Tissue Fixation System ligament repair cures major pelvic organ prolapse in ageing women with minimal complications – a 10-year Japanese experience in 960 women

Hiromi Inoue<sup>1</sup>, Ryoko Nakamura<sup>2</sup>, Yuki Sekiguchi<sup>1</sup>, Yutaka Kohata<sup>1</sup>, Takanori Fukuda<sup>1</sup>, Kazuya Oonuma<sup>1</sup>, Yosie Uzawa<sup>1</sup>, Remi Watanabe<sup>1</sup>

<sup>1</sup>Urogynecology Center, Shonan Kamakura General Hospital, Kamakura, Japan

<sup>2</sup>LUNA Pelvic Floor Total Support Clinic, Women's Clinic LUNA Group, Yokohama, Japan

**Citation:** Inoue H, Nakamura R, Sekiguchi Y, et al. Tissue Fixation System ligament repair cures major pelvic organ prolapse in ageing women with minimal complications – a 10-year Japanese experience in 960 women. Cent European J Urol. 2021; 74: 552-562.

## Article history

Submitted: Aug. 17, 2021

Accepted: Sept. 19, 2021

Published online: Nov. 18, 2021

## Corresponding author

Hiromi Inoue  
Shonan Kamakura  
General Hospital  
Urogynecology Center  
1370-1 Okamoto  
Kamakura Street  
247-8533 Kamakura, Japan  
phone: +81 90 5780 4165  
ino-hiromi@jcom.home.ne.jp

**Introduction** Japan's ageing crisis has brought major prolapse and incontinence problems. We hypothesized the problem was collagen leaching out of ligaments which support organs and could be corrected by the TFS (Tissue Fixation System) minisling which uses 7 mm wide tapes to create new collagen for ligament reinforcement.

We analysed our 10-year experience (2009–2019) with TFS minisling prolapse repair with regard to one main question: "Is this technology of benefit to the ageing Japanese population?"

**Material and methods** Retrospective analysis from two tertiary referral units; 3100 tapes were implanted (variously) into cardinal, uterosacral, arcus tendineus fascia pelvis (ATFP), perineal body ligaments of 960 Japanese women (mean age 69.6 years), to repair POPQ 3<sup>rd</sup> or 4<sup>th</sup> degree prolapse (918/960), 50% under local anesthesia/sedation, remainder general/spinal anesthesia.

**Results** Patient discharge within 24 hours indicated minimal intra-operative problems. Prolapse cure at 12 months reached 90%. Complications requiring intervention were infected rectal perforation by tape, 3 delayed ileus complications. Eroded tapes (2.4–3.5%) were trimmed in the clinic. De novo long-term pain and major urine loss were virtually absent.

**Conclusions** The TFS system works by restoring ligament support (pubourethral, ATFP, cardinal, uterosacral, perineal body), differently from mesh sheets which work by blocking organ descent, which can lead to fibrosis of the vagina, and may cause chronic pain and massive incontinence. We had no such problems, because tapes have small volume, are applied transversely, with little vaginal contact. Specific ligament reinforcement with collagenopoietic tapes seems to be an important new direction for aged women with major prolapse, with high cure rate, acceptable complications, low erosions and virtually no long-term pain.

**Key Words:** POP repair ◊ Tissue Fixation System ◊ chronic pelvic pain ◊ overactive bladder ◊ nocturia

## INTRODUCTION

The world population is ageing, notably in Japan [1]. Ageing brings collateral medical problems including pelvic organ prolapse and incontinence [2]. The result is poor QoL (Quality of Life) and escalating community and government health costs. Bladder/

bowel dysfunctions are said to be responsible for 50% of all admissions to nursing homes. Age and collateral health problems in Japan have created a concomitant demand for minimally invasive operations to safely correct these problems.

The basis for this work is restoration of collagen to damaged ligaments by accurately implanted tapes.

This methodology began in 1990 with two important discoveries. Firstly, urinary incontinence and prolapse were ultimately caused by collagen defect in ligaments [3]. Second, the discovery of a new surgical principle which used the collagenopoietic wound reaction of an implanted tape in a positive way to create a collagenous artificial neoligament (Figure 1) [4]. The first application of this new surgical principle was the basis of the prototype midurethral sling operation, later known as the tension-free vaginal tape 'TVT' sling [5]. In 1997 the same surgical principle (essentially a 'reverse' TVT sling) was applied as a posterior sling, ('infracoccygeal sacropexy'), for repair of the uterosacral ligaments (USL) in women who had apical prolapse [6]. The senior authors (HI, YS) were early users of both sling operations. Despite good anatomical results, the posterior sling operations had limitations including 'blow-outs' of other prolapses such as cystocele in 16–20% of cases [7].

In 2009 the Tissue Fixation System (TFS) (Allenby Gardens South Australia) tensioned mini sling became commercially available (Figure 2). It is a less invasive day-care evolution of both TVT and posterior slings. The 5 TFS slings can repair all 3 levels of ligament support specified by De Lancey's anatomical studies [8].

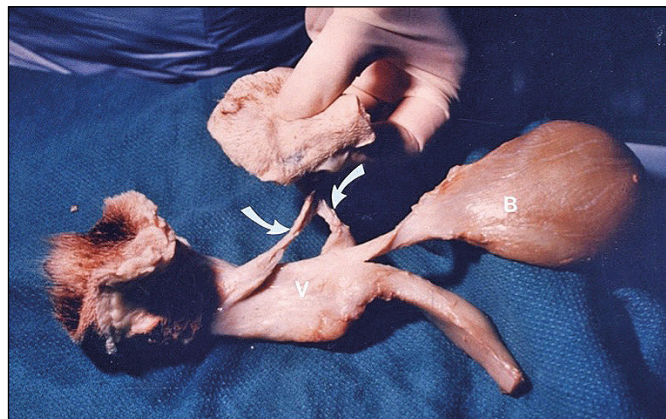
All these attributes were important in our decision to use TFS. Our patient base was becoming older, increasingly frail, with co-morbid conditions, usually with multiple anatomical defects, which the TFS could repair simultaneously (Figure 2), as a day or overnight stay procedure.

Before choosing TFS, we also researched transvaginal mesh sheet repair kits ('TVM'). We rejected TVM because they were major operations, based on blocking descent of the prolapsed organs, not repairing De Lancey's three anatomical levels of organ support [8]. Also, we were concerned about mesh shrinkages, pain (already being reported) and fibrosis of the vaginal elasticity so necessary for normal bladder function [3].

The TFS is not generally available in Japan, but the authors obtained permission for import and use of TFS from the Ministry of Health, Labour and Welfare in Japan. Since 2009, we have performed more than 3100 TFS implants to repair damaged ligaments in 960 Japanese women for prolapse and more than 500 for stress urinary incontinence (SUI) and intrinsic sphincter defect (ISD) which we have previously reported [9, 10].

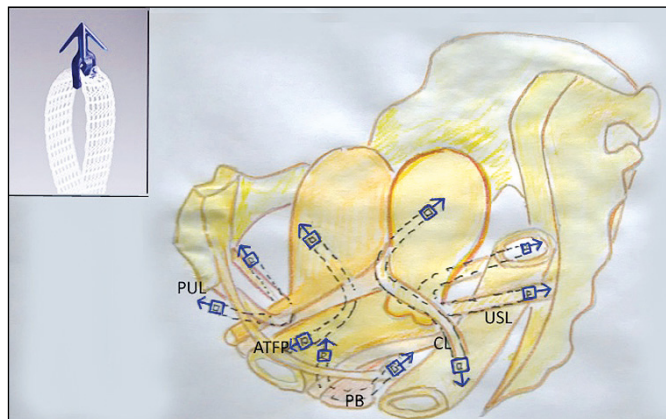
Our aim was to retrospectively analyse our collective misling experience in patients with major 3<sup>rd</sup>/4<sup>th</sup> degree prolapse for safety, effectiveness with regard to one main question: "Is this new technology of ben-

efit to the ageing Japanese population?". Our Review is based on collective data from two tertiary pelvic floor units, Yokohama and Kamakura.



**Figure 1.** Implanted tapes create new collagen to reinforce damaged ligaments. Specimen of vagina (V), vulva bladder (B) dissected from a dog 2 weeks after the implanted tape had been removed. Note the significant collagenous neoligament created by tissue reaction against the implanted tape (white arrows).

Reprinted with the author's permission: Petros PE, Ulmsten U, Papadimitriou J. The Autogenic Neoligament procedure: A technique for planned formation of an artificial neo-ligament. *Acta Obstet Gyn Scan.* 1990; 69 Suppl 153: 43-51.



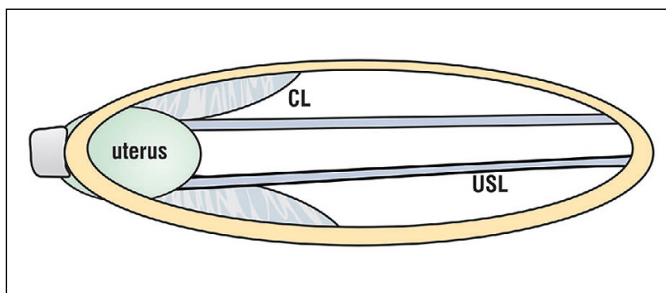
**Figure 2.** The TFS shortens and reinforces loose or damaged ligaments. The TFS sling is placed transversely, so it has very minimal contact with vagina. It directly re-attaches organs to the skeleton, mimicking exactly the De Lancey 3 level pelvic organ system [8]: PUL (pubourethral ligament); ATFP (arcus tendineus fascia pelvis); CL (cardinal ligament); USL (uterosacral ligament); deep transversus perinei part of PB (perineal body). Insert: TFS anchor and tape polypropylene anchor 11 x 4 mm sits on a stainless steel applicator. A lightweight macropore 7 mm wide monofilament tape passes through a one-way system at the anchor base which shortens and tensions the damaged ligament.

## MATERIAL AND METHODS

Of the 960 patients, 918, 95% of all patients had 3<sup>rd</sup> or 4<sup>th</sup> degree prolapse POP-Q. Almost all had multiple anatomical defects and these were all repaired concomitantly (Figure 2). Both units had received ethical approval for the surgeries in 2009. All surgery was performed with informed consent. This study was approved by the Ethics Committee in November 2020. We used an average of 3 implants per patient to repair the ligaments causing the various prolapses listed in Figure 2. About 50% of the operations were done under local anesthesia/sedation and the rest under general or spinal anesthesia. General inclusion criteria: patients with prolapse considered fit for surgery by ourselves, an anesthesiologist and where relevant, other attending physicians. Exclusion criteria: patients unfit for surgery.

The modus operandi of the TFS tensioned minisling is very different from mesh sheets which block descent of the organ. Ligaments suspending organs from the pelvis behave like wires of a suspension bridge [3]. Collagen defects in ligaments render them loose. Consequently, organs prolapse downwards as a bulge out of the vagina. Our method implants thin strips of tape 7 mm wide in ligaments to create new collagen to repair them, thus resuspending the organs. The TFS repairs the actual ligaments specified by De Lancey in his three-level organ support system [8]: pubourethral ligament (PUL), cardinal ligament (CL), uterosacral ligament (USL), arcus tendineus fascia pelvis (ATFP), ligamentous supports of perineal body (PB) (Figures 2–5). Dislocated or torn vagina (DeLancey level 2) was re-attached to the repaired ligaments (Figure 4), but never excised. The patients all had multiple defects which were repaired simultaneously.

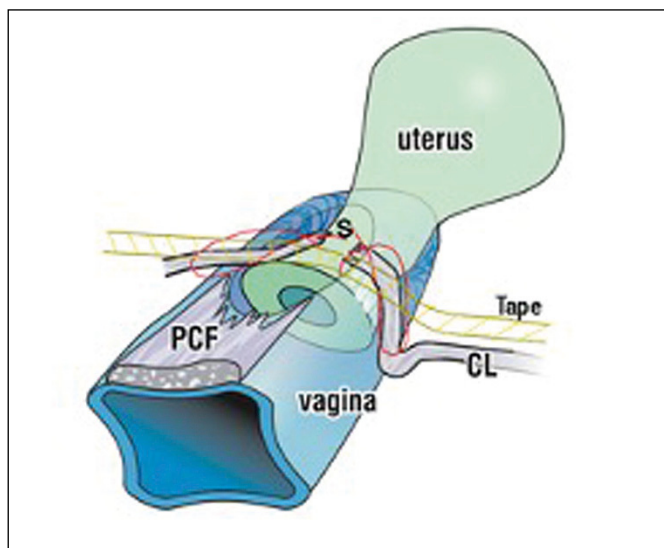
The TFS works in the exactly same way as the TVT. It repairs the loose/damaged ligaments Figures 2–5,



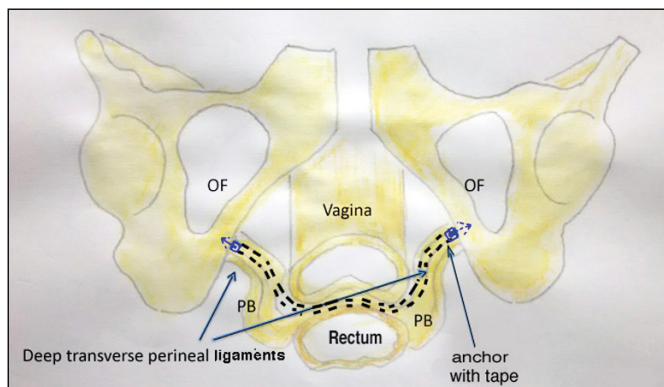
**Figure 3.** Uterine prolapse is caused by laxity of both cardinal (CL), uterosacral ligaments (USL) and adjoining fascia. Clearly both ligaments need to be shortened and reinforced in cases of uterine/apical prolapse.

Reprinted with the author's permission: Petros P. *The Female Pelvic Floor*. Springer Heidelberg. 2010; 3<sup>rd</sup> ed. Chapt. 2, pp. 17-76.

by shortening them to their correct length and creating new collagen to strengthen them, (Figure 1). Though specific repair details apply for each ligament, PUL, ATFP, CL, USL, PB (see below), the same repair principles apply to all 5 ligaments, (Figure 2): the damaged ligament is located; a tunnel is made inside or adjacent to the ligament; the applicator is inserted along the length of the ligament and the



**Figure 4.** Schematic 3D view of the uterus, vagina and cardinal ligaments (CL). CLs are shown torn from their attachment to the anterior cervical ring and prolapsed down the side of the cervix. The pubocervical fascia (PCF) of the vagina is shown torn from the cardinal ligaments and the cervical ring. The CLs are sutured 'S' back onto the cervical ring and the TFS tape is inserted via tunnels made along the anatomical line of the CLs.



**Figure 5.** The deep transversus perineal ligaments elongate to cause perineocele in turn, low rectocele or descending perineal syndrome (DPS). The TFS penetrates the 4 cm length of the perineal body (PB) to insert immediately behind the junction of the upper 2/3 and lower 1/3 of the descending ramus. The tape is then shortened and this elevates the laterally displaced PB to repair the low rectocele and DPS.

anchor is applied. The procedure is repeated on the contralateral side. The tape is tightened sufficiently to correct connective tissue laxity (resistance to tensioning signals this). The tape restores the prolapse, and the musculoelastic mechanisms which control bladder and bowel function [3].

## RESULTS

The age of our patients ranged between 36 and 98 years, mean 70 years for Kamakura and 69.7 years for Yokohama. Patients requiring midurethral sling surgery were approximately 7 years younger on average. More than 3100 TFS Amid type one TFS tapes were inserted into 960 Japanese patients between 2009 and 2019 by two units, Kamakura and Yokohama. Almost all patients were discharged in a day, indicating, in general, that complications were minimal. All repairs were concomitantly performed, a mean 3 repairs per patient. Criterion for cure: any prolapse 2<sup>nd</sup> degree or more in any organ was considered a failure. Thus, if a patient had cystocele, rectocele and uterine prolapse repaired concomitantly, a recurrence in only one compartment was counted as surgical prolapse failure. Despite this strict criterion, high anatomical cure rates (91.7%) were achieved for major prolapse (3<sup>rd</sup> and 4<sup>th</sup> degree) (Table 1). Associated chronic pelvic pain, bladder/ bowel symptoms were often significantly improved [11, 12, 13]. Long-term prolapse data in an early cohort showed

minimal deterioration for cure rates at 60 months (90% to 79% for POP) and also symptoms [12]. The operations are minimal and highly suited to aged patients. At least in our surgical cases, the success rate with age is almost unchanged. There were no statistical differences between age and successful/unsuccessful surgical procedures (P = 0.728, Student's t-test) Table 1.

The length of hospital stay is unlikely to be extended with age. No statistical correlation between hospital stay and age in successful surgical procedures was observed (correlation coefficient = 0.0994) (Table 1). The co-morbidities of those patients 80 years old or older who had undergone TFS at Kamakura hospital was 82.8% (heart disease 27.4%, hypertension 24.2%, orthopedic disease 9.7%, cancer 9.7%, neurosurgical disease or cerebral stroke 8.0%, diabetes mellitus 6.4%, lung disease 6.4%, renal failure 3.2%). In trained hands, it is possible to perform all of the TFS operations under local anesthesia [13].

Though they were performed on a day-care basis, the operations were not complication free: 44/960 POP surgeries had temporary urinary retention. These were discharged on the day of surgery with a special catheter. All retention cleared spontaneously within 7 days. There was one post-operative hematoma which required hospitalization and observation for a week with no transfusion required. There was one rectal perforation with an infected tape which required removal. Longer-term complications were

**Table 1.** Success rate and discharge rate within 2 day for POP

Age	Luna	SK	Discharge on the same day or overnight stay*		Success rate**	
	Patient no.		No. in Luna / SK	%	No. in Luna / SK	%
<40	0	1	1/1	100	1/1	100
40-44	0	2	2/2	100	2/2	100
45-49	10	5	15/15	100	15/15	93.3
50-54	13	8	20/21	95.2	20/21	95.2
55-59	25	29	52/54	96.3	48/54	88.9
60-64	60	80	136/140	97.1	125/140	89.3
65-69	89	118	201/207	97.1	195/207	94.2
70-74	96	135	225/231	97.4	211/231	91.3
75-79	84	95	167/179	92.7	160/179	89.4
80-84	37	46	81/83	97.6	77/83	92.8
85-89	12	13	24/25	96.0	25/25	100
90<	1	1	2/2	100	2/2	100
Total	427	533	926/960 = 96.5%		880/960 = 91.7%	

Successful patients (N = 709, Average  $\pm$ SD:69.87927  $\pm$ 8.268251)

Unsuccessful patients (N = 251, Average  $\pm$ SD:69.54878  $\pm$ 7.913346)

Luna – Luna Clinic; SK – Shonan Kamakura General Hospital; \*Age comparison of successful/unsuccessful surgical procedures; \*\*Correlation between hospital stay and age in successful surgical procedures; POP – pelvic organ prolapse; No. – number

P = 0.728, Student's t-test; correlation coefficient= 0.0994

3 cases of ileus which presented some months to years after the initial surgery and required surgical intervention. It was our considered opinion, that the mesh in the abdominal cavity was caused by improper insertion technique. It is necessary to be careful especially when there is an enterocele. Improper insertion can also be prevented by mesh insertion with finger assistance.

We have more recently addressed the ileus complication by plicating the USLs prior to insertion of the USL tapes to ensure reduction of enterocele.

A precise knowledge is required of how to diagnose which ligaments have been damaged, where they are and how to fix them. We have had particular problems with just one damaged ligament, repair of the deep transversus perinei ligaments which suspend the perineal body (PB) anatomy, as evidenced by an initial high erosion rate (8.2%) (Table 2). This negatively influenced our total erosion rate, 2.5% for Kamakura (Table 1) and also, Yokohama, 3.5%. The PB problem was attributed to flawed insertion technique. This has now been corrected with a good

anatomical result and lower erosion rate (2.5%). All erosions were dealt with as outpatient procedures except for two perineal body slings which needed general anesthesia for removal.

Most patients on discharge took analgesics for a few days to return to their daily lives. In an analysis of the 6 patients in the Kamakura unit who reported post-operative pain beyond a few days, the sites of the pain are detailed with duration in brackets: back pain x1 (6 weeks); upper leg x2 (4 weeks); right hip x2 (1 day, 6 weeks). One other patient had hip pain of uncertain origin, (she had a fall day 2 after surgery); this settled by 24 months. From the Yokohama unit, there were 5 patients with post-operative pain, duration of pain in brackets: pubic pain (3 days), lower back pain (3 days), pubic pain (2 months), dragging pain (1 month) pubic pain (3 months). There was a virtual absence of longer-term mesh-related complications such as mesh shrinkage, late onset pain, massive urinary incontinence. We attribute this to the low mesh volume and horizontal placement of the tapes, which means there is very minimal contact with vagina. This allows the free anterior-posterior movement required for normal function, unlike the large mesh sheets which fibrose the anterior vaginal wall with scar tissue.

**Table 2.** Ligament by ligament analysis of erosion rates from Kamakura

Sling	No. of erosion/total	%
Anterior sling	1/2	0
U sling	1/475	0.2
Cardinal sling	8/491	1.6
USL sling	3/470	0.6
Perineal body sling	31/378	8.2
Total erosion rate	43/1816	2.4

No. – number; USL – uterosacral ligament

## DISCUSSION

Our 10-year collective experience with the TFS brings two important contributions to pelvic floor science by the TFS. Firstly, ligament repair for prolapse is very different from mesh sheets placed behind the vagina; there is virtually no pain from nerve entrapment. Secondly, cure rates are high for over-

**Table 3.** Lower and upper 95% – confidence intervals for the observed relative frequencies of prolapse, urgency, nocturia, dragging pain and fecal incontinence. The results of testing the hypothesis have been entered in parallel Ho:  $p \leq 0.80$  vs H1:  $p > 0.80$

Variable	N	No. of cured	Observed cure rate (%)	95% – lower CI	96% – upper CI	Test results Ho : $p \leq 0.80$ vs H1 : $p > 0.80$
Prolapse	278	257	92.10	0.891	0.952	*
Urgency	133	124	93.20	0.879	0.971	*
Nocturia	86	62	72.10	0.597	0.809	ns
Day time frequency	132	120	90.10	0.935	0.999	*
Dragging pain	56	52	92.90	0.862	0.998	*
Fecal incontinence	52	46	88.50	0.798	0.977	ns

\* means significant p-values, i.e. the observed cure rates are significantly higher than 0.80 ( $p < 0.05$ ; Binomial Tests)

ns – means non- significant p-values

Table 3. Reproduced with permission from: Inoue, H. The TFS minisling restores major pelvic organ prolapse and symptoms in aged Japanese women by repairing damaged suspensory ligaments- 12-48 month data. *Pelvipiperineology*. 2015; 34: 79-83.

active bladder 'OAB' (frequency, urge, nocturia) and chronic pelvic pain (Tables 3 and 3a).

### Ligament repair by tapes is different from mesh sheet implants behind vagina

A recent editorial [14] outlined the crisis regarding surgical options for SUI and prolapse repair in the UK, where every mesh product has been banned. Against the recommendations of almost every learned body in the world, the most validated operation in the history of surgery, the midurethral sling was also banned in the UK, where only 'native tissue' vaginal repair remains for prolapse repair [14]. However, the results for such vaginal repairs as reported by the PROSPECT TRIAL were extremely poor, up to 75% failure at 12 months [15]. How could our results be so superior to the PROSPECT TRIAL [15], 90% cure at 12 months for ligament surgery vs 25% for vaginal repair [15]? We repaired the main supports for organs, the ligaments [8], breaking strain 300 mg/mm<sup>2</sup> [16]. In contrast, the vagina, breaking strain 60 mg/mm<sup>2</sup> [16], is a functional, not structural organ [3]; the vagina transmits

muscle forces from the 3 reflex directional muscles to regulate opening and closure of the urethral tube [3]. Why ligaments should be repaired, not the vagina, is evident after examining Figure 3. The uterus is suspended by CL and USL, not by the vagina.

Did we need to insert a tape to reinforce the ligaments? Shkarupa et al. from the University of St Petersburg Russia compared two groups of women, who had cardinal and uterosacral ligament plication (no tapes). Shkarupa's data [17], emphatically proved that ligament repair alone was not strong enough in post-menopausal women such as ours. The post-menopausal group suffered a marked parallel deterioration in anatomical repair and symptoms; by 18 months, prolapse cure was 15.4% for post-menopausal women, against 79.6% for pre-menopausal women. Shkarupa's data confirms our view that a tape is necessary to reinforce the suspensory ligaments in older women. Unlike native tissue ligament repair, repair with tapes is long lasting. An early cohort from the Kamakura hospital, mean age 70 years, showed minimal deterioration in anatomical cure rate with time, from 90% at 12 months to 79% at 60 months [12].

**Table 3a.** Lower and upper 95% – confidence intervals for the observed relative frequencies of prolapse, urgency, nocturia, dragging pain and fecal incontinence after certain time intervals with the tests results by the testing Ho :  $p \leq 0.80$  vs H1 :  $p > 0.80$

Time after TFS	Cure of prolapse	Cure of urgency	Cure of nocturia	Cure of day time frequency	Cure of dragging pain	Cure of dysuria	Cure of fecal incontinence
12 months	62/68	30/31	17/18	30/32	13/14	35/38	16/18
observed cure rate (in %)	91.2%	96.8%	94.4%	93.8%	92.9%	92.1%	88.9%
95% (lower CI; upper CI)	0.877	0.936	0.890	0.895	0.860	0.877	0.815
	0.946	0.999	0.998	0.980	0.997	0.965	0.963
Test results of							
Ho : $p \leq 0.80$ vs H1 : $p > 0.80$	*	*	*	*	*	*	*
24 months	57/65	25/30	11/17	26/29	14/15	26/28	12/15
observed cure rate (in %)	87.7%	82.3%	64.7%	89.7%	93.3%	92.9%	80%
95% (lower CI; upper CI)	0.836	0.765	0.531	0.840	0.869	0.880	0.697
	0.918	0.901	0.763	0.953	0.998	0.977	0.903
Test results of							
Ho : $p \leq 0.80$ vs H1 : $p > 0.80$	*	ns	ns	*	*	*	ns
36 months	48/58	23/24	14/23	27/30	9/10	25/26	6/7
observed cure rate (in %)	82.7%	95.8%	60.9%	90.0%	90.0%	96.2%	85.7%
95% (lower CI; upper CI)	0.778	0.918	0.507	0.845	0.805	0.924	0.725
	0.877	0.999	0.710	0.955	0.995	0.999	0.989
Test results of							
Ho : $p \leq 0.80$ vs H1 : $p > 0.80$	ns	*	ns	*	*	*	ns
48 months	42/50	18/20	8/17	13/19	6/6	22/23	5/5
observed cure rate (in %)	84%	90.0%	47.1%	68.4%	100%	95.6%	100%
95% (lower CI; upper CI)	0.788	0.833	0.350	0.578	1.000	0.914	1.000
	0.892	0.967	0.592	0.791	1.000	0.999	1.000
Test results of							
Ho : $p \leq 0.80$ vs H1 : $p > 0.80$	ns	*	ns	ns	*	*	*

\*means significant p-values, i.e. the observed cure rates are significantly higher than 0.80 ( $p < 0.05$ ; Binomial Tests)

Ns – means non-significant p-values

TFS – tissue fixation system; CI- confidence interval

Table 3a Reproduced with permission from: Inoue, H. The TFS minisling restores major pelvic organ prolapse and symptoms in aged Japanese women by repairing damaged suspensory ligaments- 12-48 month data. *Pelvipiperineology*. 2015; 34: 79-83.

What is the pathway to ligament deterioration, lengthening and prolapse as per Figure 3? Collagen, the main structural component of ligaments [3], breaks down after menopause. The excretion of one breakdown product, hydroxyproline, doubles after menopause and continues to excrete at that rate afterwards [18]. This process brings irreversible changes to the ligaments which provide organ support. The ligaments lose collagen, elastin and glycoproteins [19]. Tapes create the new collagen required to reinforce the ligaments to provide the required support [4] (Figure 1).

### Cure of overactive bladder and underactive bladder (Posterior Fornix Syndrome) by posterior ligament repair

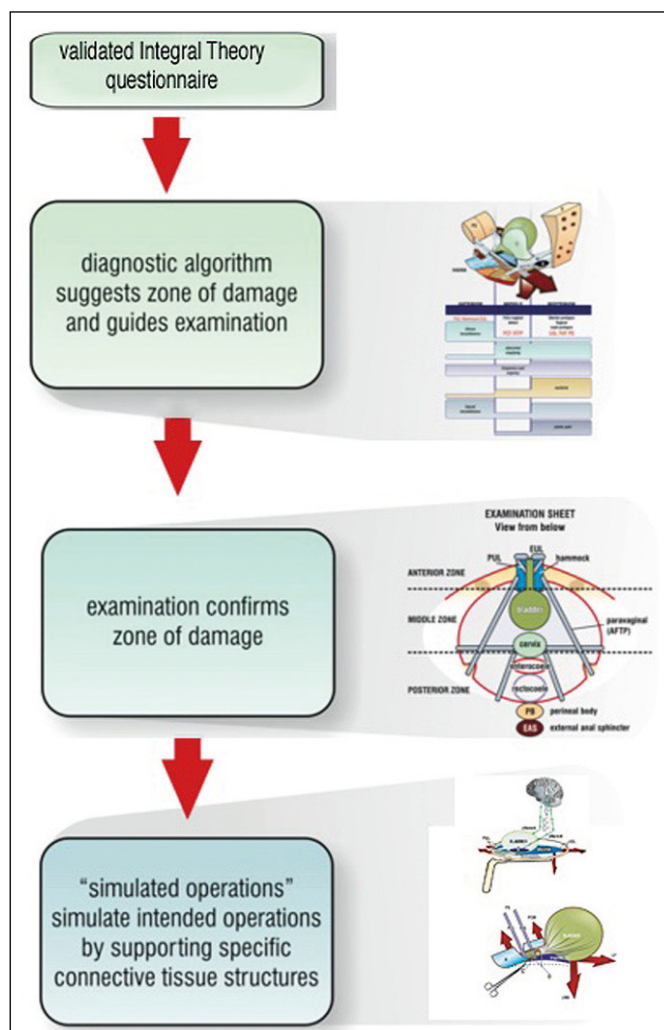
According to peak incontinence bodies such as the Fifth International Consultation on Incontinence [20], bowel, bladder, and pain symptoms are major problems in up to 30% of women, and the causation is essentially unknown [21, 22]. Such conditions are major reasons for patient disability, costs to the community, and admission to nursing homes. Other than SUI, these conditions are not considered surgically curable. Indeed, few prospective trials even address these issues [23, 24]. The conclusion from these trials is always the same: pathogenesis is unknown; no cure is possible [23, 24].

Though our principal aim was to present TFS prolapse repair data in 960 patients, we have, from time to time, published prospective symptom cure data; collaboratively in a multicentre 12-month trial of 611 women in this journal [25], which reported 85% cure for OAB (frequency, urge incontinence), 77% for chronic pelvic pain, 68% for nocturia, and 90% for apical prolapse in a 70-year-old group; our own prospective trials, reviewed at 12–48 months repaired all damaged ligaments concomitantly as necessary (Figure 2, Tables 3 and 3a) [11]. These and other data from this journal and others [9–13, 26–41] confirm chronic pelvic pain, OAB and even UAB (underactive bladder) are curable, both surgically and in younger patients, non-surgically [42, 43].

### Pathogenesis and cure following the Integral System

How does application of the Integral Theory System [44] bring high bladder/bowel/ chronic pelvic pain (CPP) cure rates, when ‘consensus group’ recommendations from more traditional expert associations [21] such as the European Urology Association [22] invariably conclude that pathogenesis is unknown and no cure is possible? [23, 24].

Thomas Kuhn, in his book ‘The Structure of Scientific Revolutions’ [45] would describe such comments [21, 22] as ‘normal science’, conclusions drawn from following an existing paradigm for treatment. However, the Integral Theory System [44] which we follow, is what Kuhn called a ‘new paradigm’. He stated new paradigms are ‘non-commensurable’ with the old, i.e., they cannot be reconciled as they each follow a different system with different rules. Figure 6 summarizes the diagnostic rules (protocol) for the Integral System [44].



**Figure 6.** Integral System diagnostic pathway. Specific symptoms in the Integral Theory System Questionnaire (ITSQ) indicate which ligaments/fascias may be damaged. The symptoms are transferred to the diagnostic algorithm; the diagnosis from the algorithm is checked by vaginal examination; the causative ligaments are then checked by ‘simulated operations’, mechanical support of mainly pubourethral and uterosacral ligaments to observe change in symptoms.

Reprinted with the author’s permission: Petros P. *The Female Pelvic Floor*. Springer Heidelberg. 2010; 3<sup>rd</sup> ed. Chapt. 2, pp. 17-76.

Control of normal function (Figure 7), upper part, shows the 3 reflex directional forces (large arrows) which contract against competent pubourethral (PUL) and uterosacral (USL) ligaments. The 3 reflex forces have 3 functions: 1. To close urethra and anus; 2. To open urethra and anus immediately prior to evacuation so as to reduce the resistance to empty the bladder and rectum; 3. To stretch the organs in opposite directions to provide support for the stretch receptors from below. This action decreases the afferent impulses which warn the brain that the organ is full and evacuation is required. In this way, the reflex muscles control unwanted evacuation (urge incontinence).

### Pathogenesis of dysfunction

Simplistically, if ligaments are weak or loose, all three functions may be compromised and the patient may suffer the dysfunctions in the 3 zones of Figure 7.

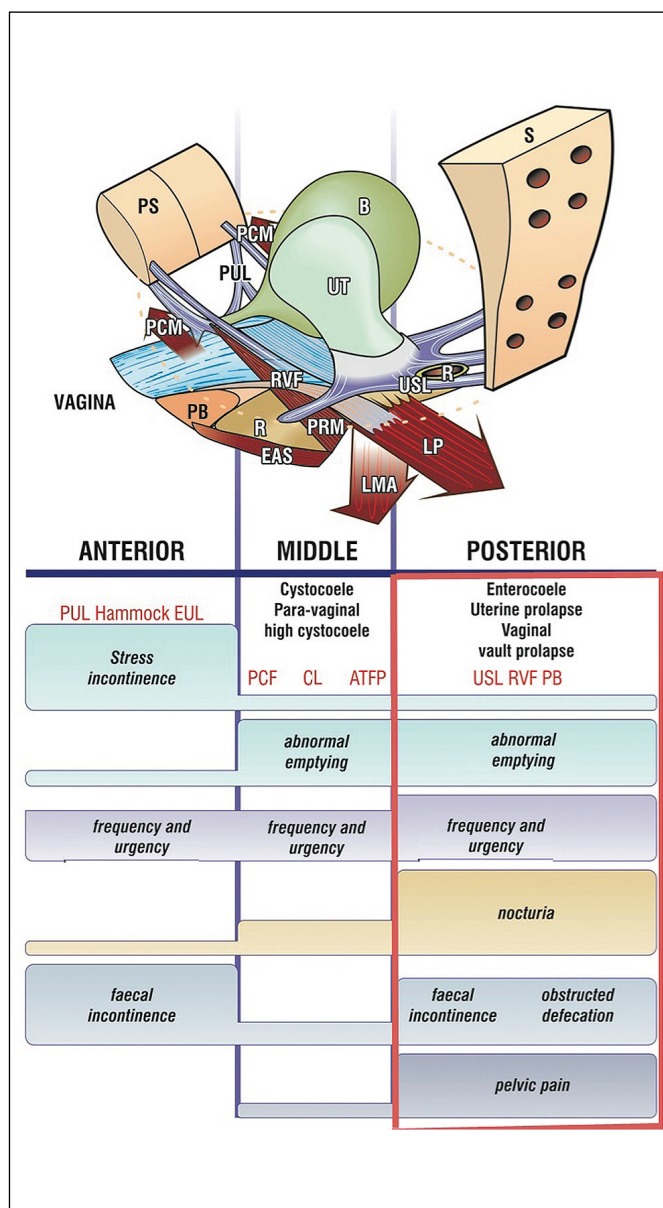
### Surgical cure

Simplistically, repair of the relevant ligaments can reverse the pathogenesis summarized in the algorithm (Figure 7), and cure the dysfunctions (Tables 3, 3a) [9–13, 25–43].

### CONCLUSIONS

Though similar in principle to the original TVT sling, the TFS tensioned minisling is a significant advance. It is safer, inserts less tape and can repair all of the 5 ligaments which can cause prolapse or symptoms (Figure 7). Our collective experience indicates longer term cure rates in older women [26, 38]. The success rate and the length of hospital stay are not affected by age. Our data emphatically supports our contention that ligament repair surgery for prolapse is very different from mesh sheets placed behind the vagina. Mesh sheets fibrose the whole vaginal wall to block organ descent. Ligament repair with minislings works differently, restoring ligaments which provide 3 level organ support [8]. We attribute virtual absence of mesh sheet complications such as pain and massive de novo incontinence to tapes having very little contact with the vagina. They attach the organs directly to the skeleton.

“Is it of benefit to the ageing Japanese population suffering from prolapse and incontinence?”. Our 10-year experience emphatically indicates that it is, 3100 operations were performed in 960 women, mainly day surgery, with good cure rates and few major complications.



**Figure 7.** The diagnostic algorithm. A ‘shorthand’ method where symptoms indicate which ligaments are causing which prolapse and which symptoms. The connective tissue structures fall naturally into 3 zones of causation Anterior zone; external meatus to bladder neck: external urethral ligament (EUL); pubourethral ligament (PUL); suburethral vaginal hammock. Middle zone: bladder neck to anterior cervical ring; pubocervical fascia (PCF); cardinal ligament (CL); arcus tendinous fascia pelvis (ATFP). Posterior zone: uterosacral ligament (USL); rectovaginal fascia (RVF); perineal body (PB). The height of the bar indicates probability of causation. For example, nocturia and pelvic pain are almost exclusively caused by uterosacral ‘USL’: laxity; stress incontinence, by pubourethral laxity ‘PUL’.

Reprinted with the author’s permission: Petros P. The Female Pelvic Floor. Springer Heidelberg. 2010; 3<sup>rd</sup> ed, Chapt. 2, pp. 17-76.



## VIDEO

### **PUL repair for stress urinary incontinence, Figure 2, Video 1**

Video can be found at: [http://ceju.online/baza/tmp/man/man\\_2178/video1.php](http://ceju.online/baza/tmp/man/man_2178/video1.php)

The operation is performed under spinal or local anesthetic infiltration. With an 18 Fr Foley catheter in situ, the urethral length is first checked. A longitudinal 1 cm incision is made in the vagina at midurethra as in TVT. Using Metzenbaum scissors, a tunnel is made pointing towards the shoulder. When resistance is met (perineal membrane), the scissors are guarded and then pushed forwards to penetrate the membrane 1.5 cm. The applicator is inserted into the tunnel, anchor released and tested for gripping. The 'frenulum' (attachment of urethra to vaginal fascia) is gently snipped so as to allow the tape to fit snugly on the urethra. The tunnelling and anchor insertion are repeated on the contralateral side. Prior to releasing the anchor, the tape is tightened until it just touches (but does not indent) the urethra. The bladder is filled with 300 ml saline. A cystoscopy is performed to check for bladder perforation. The catheter is removed and the patient asked to cough. If urine leaks, an 8 mm Hegar dilator is inserted and the tape is tightened slightly over the dilator. The patient is asked to cough and the procedure is repeated until only a small drop is lost.

The incision is now extended to within 0.5 cm of the external meatus. The catheter is re-inserted. The laterally situated external urethral ligament (EUL) is located. A No. 2 vicryl suture is placed, in turn, into the left EUL, into the inner layer of vagina ('fascia') on the left side, then on the right side, then into the right EUL. The suture is gently tightened without tension over the catheter.

### **Cardinal ligament TFS, Figure 2, Video 2**

Video can be found at: [http://ceju.online/baza/tmp/man/man\\_2178/video2.php](http://ceju.online/baza/tmp/man/man_2178/video2.php)

A 5 cm wide full thickness vaginal incision is made at the junction of bladder to cervix, usually, 1 cm above the internal os of the cervix. The bladder is dissected off the cervix with sharp then blunt dissection. The anchor is placed on the applicator and inserted directly into the pelvic side wall into the obturator fascia, approximately 2 cm above and just forward of the ischial spine. The anchor is released and the insertion is repeated on the contralateral side. The one-way system is tightened until a resistance is felt and the long ends of the tape are

trimmed. Excess vaginal laxity is reduced (without vaginal excision) with an 2-0 vicryl suture applied as a 'purse-string' suture to the pubocervical fascial layer of vagina which is then secured to the tape with the same 2-0 suture. The vaginal incision is closed with 00 vicryl without excision.

### **Uterosacral (USL) TFS repair, Figure 2, Video 2**

Video can be found at: [http://ceju.online/baza/tmp/man/man\\_2178/video2.php](http://ceju.online/baza/tmp/man/man_2178/video2.php)

First the uterus is stretched downwards and turned upwards to check the insertion of USLs so as to locate the endpoint of any elongated cervix. The elongated cervix is then cleanly amputated with cutting diathermy as per Video 2. The cut ends of the vagina are brought down without tension, sutured to the anterior surface of the amputated cervix while haemostasis is assured. A full thickness transverse incision 5 cm wide is made in the posterior vaginal wall 1–2 cm below the cervix. The USLs are located and secured with Allis forceps. Using Metzenbaum scissors, a tunnel about 5 cm long is made lateral and close to the USL towards the sacrum. The applicator, loaded with a TFS anchor, is pressed into the tunnel, the anchor is released and tested for grip. The procedure is repeated on the contralateral side. The tape is tightened until a resistance is felt. The vagina incision is sutured with a purse string suture, without excision of vaginal tissue.

### **TFS USling (ATFP) repair, Figure 2, Video 3**

Video can be found at: [http://ceju.online/baza/tmp/man/man\\_2178/video3.php](http://ceju.online/baza/tmp/man/man_2178/video3.php)

Though designated as a repair of a damaged ATFP, this operation actually re-attaches a dislocated pubococcygeus/puborectalis muscle to the soft tissue of the pubic symphysis. This defect invariably occurs in association with a 'transverse defect', itself caused by CL tearing off the anterior cervical ring. With an 18 Fr Foley catheter in situ, a full thickness longitudinal incision is made beginning 1 cm distal to the transverse CL incision stopping 1 cm short of the bladder neck. The bladder is dissected off the vagina. Metzenbaum scissors penetrate the perineal membrane and continues almost to the symphysis. A TFS applicator, anchor attached, is placed into the tunnel, the tunneler pushed to penetrate the perineal membrane. The anchor is released and tested for grip. The same is repeated on the contralateral side. The tape is tightened until a resistance is felt. Excess tape on both lateral sides cut. Vagina is repaired without excision.

## Repair of perineocele (descending perineum syndrome), Figure 2. Video 4

Video can be found at: [http://ceju.online/baza/tmp/man/man\\_2178/video4.php](http://ceju.online/baza/tmp/man/man_2178/video4.php)

A transverse incision is made just inside the hymenal remnants. The vagina is dissected clear of the attached rectum or perineal body remnants. Almost invariably, the right and left parts of the body of the perineum have been pushed laterally by a protruding rectocele adherent to the vagina. Often, the rectal serosa is torn and also displaced laterally, so the rectal mucosa is actually adherent to the vagina. The mucosa is dissected clear and the rectal serosa is restored with 2 or 3 interrupted sutures. The displaced PB now has to be located, often just medial to the ischial tuberosity. This is best done with a strong 2.5 cm needle attached to a No. 1 vicryl suture which is held. Critically important is to ensure that what is grasped is PB and not puborectalis

muscle. Muscle has a deep red colour. PB is whitish. Pulling the No. 1 holding suture towards you confirms the PB insertion point which is exactly behind the junction of the upper 2/3 and lower 1/3 of the descending ramus. If it is not felt, it is possible you have placed the suture into the puborectalis muscle. That being so, the pulling is felt immediately below the pubic symphysis. Once both PBs have been brought into the incision, and properly identified, a tunnel is made through the PB right to its insertion point behind the upper 2/3 and lower 1/3 of the ramus. The applicator armed with an anchor is inserted. The anchor is released and tested for grip. The same is done on the contralateral side. The anchor is released and the tape tensioned until a resistance is felt. The lateral ends of the tape are trimmed. The vagina is closed without excision.

### CONFLICTS OF INTEREST

The authors declare no conflicts of interest.

## References

1. <http://www.stat.go.jp/index.htm> 2019, Ministry of Internal Affairs and Communications.
2. Abrams P, Andersson KE, Birder L. 4th International Consultation on Incontinence Recommendations of the International Scientific Committee 2009: Evaluation and Treatment of Urinary Incontinence, Pelvic Organ Prolapse and Faecal Incontinence, pp. 1767-1820.
3. Petros PE, Ulmsten U. An Integral Theory of female urinary incontinence. *Acta Obstet Gynecol Scand.* 1990; 153: 7-31.
4. Petros PE, Ulmsten U, Papadimitriou J. The Autogenic Neoligament procedure: A technique for planned formation of an artificial neo-ligament. *Acta Obstet Gynecol Scand.* 1990; 153: 43-51.
5. Ulmsten U, Petros P. Intravaginal slingplasty (IVS): an ambulatory surgical procedure for treatment of female urinary incontinence. *Scand J Urol Nephrol.* 1995; 29: 75-82.
6. Petros PE. New ambulatory surgical methods using an anatomical classification of urinary dysfunction improve stress, urge, and abnormal emptying. *Int Urogynecol J Pelvic Floor Dysfunct.* 1997; 8: 270-277.
7. Petros PE. Vault prolapse II: Restoration of dynamic vaginal supports by the infracoccygeal sacropexy, an axial day-care vaginal procedure. *Int Urogynecol J Pelvic Floor Dysfunct.* 2001; 12: 296-303.
8. DeLancey JO. Anatomic aspects of vaginal eversion after hysterectomy. *Am J Obstet Gynecol.* 1992; 166 (6 Pt 1): 1717-1724.
9. Nakamura R, Yao M, Maeda Y, Fujisaki A, Sekiguchi Y. Outpatient mid-urethral tissue fixation system sling for urodynamic stress urinary incontinence: 3-year surgical and quality of life results. *Int Urogynecol J.* 2017; 28: 1733-1738.
10. Nakamura R, Yao M, Maeda Y, Fujisaki A, Sekiguchi Y. Retropubic tissue fixation system tensioned mini-sling carried out under local anesthesia cures stress urinary incontinence and intrinsic sphincter deficiency: 1-year data. *Int J Urol.* 2017; 24: 532-537.
11. Inoue H, Kohata Y, Sekiguchi Y, Kusaka T, Fukuda T, Monnma M. The TFS minisling restores major pelvic organ prolapse and symptoms in aged Japanese women by repairing damaged suspensory ligaments- 12-48 month data. *Pelvipereineology.* 2015; 34: 79-83.
12. Inoue H, Kohata Y, Fukuda T, et al. Repair of damaged ligaments with tissue fixation system minisling is sufficient to cure major prolapse in all three compartments: 5-year data *J Obstet Gynaecol Res.* 2017; 43: 1570-1577.
13. Sekiguchi Y, Kinjo M, Maeda Y, Kubota Y. Reinforcement of suspensory ligaments under local anesthesia cures pelvic organ prolapse: 12-month results. *Int Urogynecol J.* 2014; 25: 783-789.
14. Chien P. The mess of mesh BJOG. 2020; 127: 1-2
15. Glazener CMA, Breeman S, Elders A, et al. Mesh, graft, or standard repair for women having primary transvaginal anterior or posterior compartment prolapse surgery: two parallel-group, multicentre, randomised, controlled trials (PROSPECT). *Lancet.* 2017; 389: 381-392.
16. Yamada H. Ageing rate for the strength of human organs and tissues. *Strength of Biological Materials.* 1970; Williams & Wilkins Co, Balt. (ed) Evans F; pp. 272-280.
17. Shkarupa D, Zaytseva A, Kubin N, Kovalev G, Shapovalova E. Native tissue repair of cardinal/uterosacral ligaments cures overactive bladder and prolapse, but only in pre-menopausal women. *Cent European J Urol.* 2021; 74: 372-378.
18. Miyake M, Takeda N, Fukunaga M. Urinary excretion of type I collagen crosslinked N-telopeptides in Healthy Japanese adults: Age- and sex-related changes and reference limits *Bone.* 1995; 17: 335-339.
19. Goepel C. Differential elastin and tenascin immunolabeling in the uterosacral

- ligaments in postmenopausal women with and without pelvic organ prolapse. *Acta Histochem.* 2008; 110: 204-209.
20. Petros PE. *The female Pelvic Floor.* 3rd Ed Springer Heidelberg; 2010.
  21. Koelbl H, Igawa TY, Salvatore S, et al. Pathophysiology of urinary incontinence, faecal incontinence and pelvic organ prolapse. In: Abrams P, Cardozo L, Khoury S, Wein A, eds. *Fifth International Consultation on Incontinence.* Bristol, UK: International Consultation on Urological Diseases; 2013: pp. 261-360.
  22. Engeler DS, Baranowski AP, Dinis-Oliveira P, et al. The 2013 EAU guidelines on chronic pelvic pain: is management of chronic pelvic pain a habit, a philosophy, or a science? 10 years of development. *Eur Urol.* 2013; 64: 431-439.
  23. Persu C, Braschi E, Lavelle J. A review of prospective Clinical Trials for neurogenic bladder: Pharmaceuticals. *Cent European J Urol.* 2014; 67: 264-269.
  24. Persu C, Braschi E, Lavelle J. A review of prospective Clinical Trials for neurogenic bladder: The place of surgery, experimental techniques and devices. *Cent European J Urol.* 2014, 67: 270-276.
  25. Liedl B, Inoue H, Sekiguchi Y, et al. Is overactive bladder in the female surgically curable by ligament repair? *Cent European J Urol.* 2017; 70: 53-59.
  26. Petros PE, Abendstein B, Swash M. Retention of urine in women is alleviated by uterosacral ligament repair: implications for Fowler's syndrome. *Cent European J Urol.* 2018; 4: 436-443.
  27. Petros PE, Abendstein B. Knowledge of urethral closure mechanics helps to optimize surgical methodology of the midurethral sling operation. *Cent European J Urol.* 2018; 71: 334-337.
  28. Petros P, Goeschen K, Inoue H. Underactive bladder may be caused by uterosacral ligament laxity - a critical review of two paradigms. *Cent European J Urol.* 2018; 71: 444-447.
  29. Petros P. A ligamentous explanation for overactive bladder symptoms as defined by International Continence Society in the female. *Cent European J Urol.* 2018; 71: 105-107.
  30. Petros P. A watershed paper for surgical cure of overactive bladder and nocturia. Editorial comment to: Shkarupa D, Zaytseva A, Kubin N, Kovalev G, Shapovalova E. Native tissue repair of cardinal/uterosacral ligaments cures overactive bladder and prolapse, but only in pre-menopausal women. *Cent European J Urol.* 2021; 74: 372-378.
  31. Petros P, Abendstein B. Mini Review. Pathways to causation and surgical cure of chronic pelvic pain of unknown origin, bladder and bowel dysfunction - an anatomical analysis. *Cent European J Urol.* 2018; 71: 448-452.
  32. Piñango-Luna S, Level-Córdova L, Petros PE, Yassouridis A. A low cost artisan tension-free tape technique cures pelvic organ prolapse and stress urinary incontinence - proof of concept. *Cent European J Urol.* 2020; 73: 490-497.
  33. Enache T, Bratila E, Abendstein B. Chronic pelvic pain of unknown origin may be caused by loose uterosacral ligaments failing to support pelvic nerve plexuses - a critical review. *Cent European J Urol.* 2020; 73: 506-513.
  34. Petros PEP, Richardson PA. TFS posterior sling improves overactive bladder, pelvic pain and abnormal emptying, even with minor prolapse- a prospective urodynamic study. *Pelvipereineology.* 2010; 29: 52-55.
  35. Sivaslioglu AA, Eylem U, Serpi A, et al. A prospective randomized controlled trial of the transobturator tape and tissue fixation minisling in patients with stress urinary incontinence: 5-year results. *J Urol.* 2012; 188: 194-199.
  36. Haverfield M. Tissue fixation system (TFS) neoligament pelvic organ repair procedures- 12 and 24 month results. *Pelvipereineology.* 2015; 34: 70-74.
  37. Abendstein B, Brugger BA, Furtschegger A, Rieger M, Petros PE. Role of the uterosacral ligaments in the causation of rectal intussusception, abnormal bowel emptying, and fecal incontinence. A prospective study. *J Pelvipereineology.* 2008; 27: 118-121.
  38. Petros PE. Severe chronic pelvic pain in women may be caused by ligamentous laxity in the posterior fornix of the vagina. *Pelvipereineology.* 2017; 36: 71-73.
  39. Sekiguchi Y, Inoue H, Liedl B, et al. Gold D Is Chronic Pelvic Pain in the female surgically curable by uterosacral/cardinal ligament repair? *Pelvipereineology.* 2017; 36: 74-78.
  40. Wagenlehner FM, Del Amo E, Santoro GA, Petros P. Perineal body repair in patients with third degree rectocele: a critical analysis of the tissue fixation system. *Colorectal Dis.* 2013; 15: e760-765.
  41. Nambiar A, Cody JD, Jeffery ST. Single-incision sling operations for urinary incontinence in women. *Cochrane Database Syst Rev.* 2014; CD008709.
  42. Skilling PM, Petros PE. Synergistic non-surgical management of pelvic floor dysfunction: second report. *Int Urogynecol J.* 2004; 15: 106-110.
  43. Garcia-Fernandez A, Petros PE. A four month squatting-based pelvic exercise regime cures day/night enuresis and bowel dysfunction in children aged 7-11 years. *Cent European J Urol.* 2020; 73: 307-314.
  44. Petros PEP. Review. Petros PE. The Integral System. *Cent European J Urol.* 2011; 64: 111-119.
  45. Kuhn T. *The structure of scientific revolutions*, ed. 3. Chicago, IL: University of Chicago Press; 1996. ■