

# Hemorrhagic colloid cyst: Case report and review of the literature

Diyora Batuk, Nayak Naren, Kukreja Sanjay, Sharma Alok

Department of Neurosurgery, L. T. M. G. Hospital, Mumbai, Maharashtra, India

## ABSTRACT

Colloid cysts are cystic lesions located at the anterior part of third ventricle, close to foramen of Monro and contain colloid material. Hemorrhage in a colloid cyst is very rare. On literature review, we found only six cases of hemorrhagic colloid cyst; among them, four were diagnosed at postmortem examination. We report a rare case of a hemorrhagic colloid cyst in a young lady who presented with sudden onset severe headache and vomiting. Computed tomography (CT) scan showed isodense lesion located at foramen of Monro with hyperdense areas suggestive of hemorrhage with foraminal obstruction. The lesion was not enhancing on contrast. Magnetic resonance imaging (MRI) brain revealed a well-defined cystic mass lesion located at the foramen of Monro which was hyperintense on T1 and hypointense on T2-weighted images. Excision of the colloid cyst was performed which revealed hemorrhagic clot instead of colloid material. Histopathological examination revealed a colloid cyst with hemorrhage. We believe that this is the first such reported case of successful clinical outcome following early diagnosis and excision of a hemorrhagic colloid cyst in an adult.

**Key words:** Colloid cyst, hemorrhage, third ventricle

## Introduction

Colloid cysts of third ventricle are rare intracranial lesions. They comprise about 0.5% to 1 % of all intracranial tumors.<sup>[1]</sup> The clinical presentation is disparate, varying from incidentally found cysts to sudden death due to acute hydrocephalus. A sudden increase in the size of the cyst due to hemorrhage has been rarely reported. The cysts usually consist of a thin walled capsule with grayish translucent gelatinous amorphous material containing necrotic leucocytes or cholesterol. The cyst wall is composed of cuboidal, columnar, or pseudostratified epithelial lining with interspersed mucosal goblet cells. Rarely, a colloid cyst wall is thickened, vascular, and consists of organized hematoma of varying ages. We describe a case of hemorrhage in a colloid cyst with good outcome in a young female. We highlight difficulties in excision of lesion and review the literature of this rare pathology.

## Case Report

A 20-year-old lady presented with a 6 months history of progressive headache and memory disturbances. Few days prior to presentation, she had three episodes of generalized tonic clonic seizures. She also had gait disturbances and severe giddiness. Higher mental function examination revealed impaired recent memory. Fundoscopic examination showed bilateral papilloedema. Cranial nerve examination, motor and sensory examination was normal. Plantar reflexes were extensor on both sides and Romberg's sign was positive. Computed tomography (CT) scan of the brain showed isodense lesion located at foramen of Monro with hyperdense areas suggestive of hemorrhage with foraminal obstruction. The lesion was not enhancing on contrast [Figure 1]. Magnetic resonance imaging (MRI) brain revealed obstructive hydrocephalus due to a large lesion in the third ventricle which was homogeneously hyperintense on T1-weighted images and homogeneously hypointense on T2-weighted images [Figure 2].

Right lateral ventricle was entered via right frontoparietal craniotomy and an interhemispheric transcalsal approach. A grayish red, well-defined, soft to firm lesion was reached through the interforaminal approach. Needle aspiration was attempted but was unsuccessful. The surface of the cyst was vascular, so it was coagulated. The cyst wall was thickened and its separation from surrounding tissue was difficult. On opening the cyst, there was no colloid material, but a brownish yellow organized clot was found which was removed piecemeal. The clot was easily separated from the inner cyst

### Access this article online

#### Quick Response Code:



#### Website:

www.asianjns.org

#### DOI:

10.4103/1793-5482.121689

### Address for correspondence:

Dr. Diyora Batuk, Department of Neurosurgery, 2<sup>nd</sup> Floor, L.T.M.G.Hospital, Sion (W), Mumbai – 400 022, India.  
E-mail: bddiyora@hotmail.com

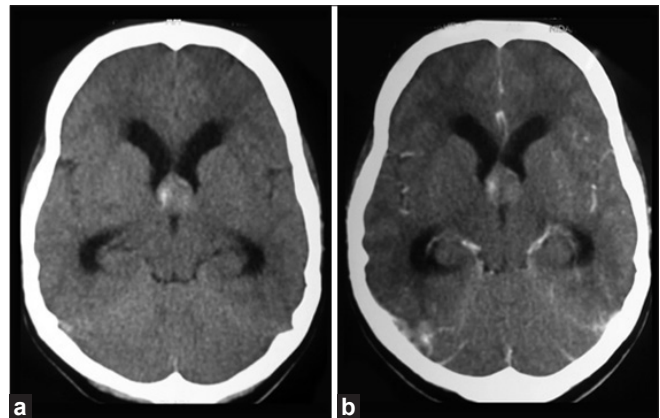
wall. After almost complete evacuation of cyst content, the thick wall was held with biopsy forceps with one hand and with the other hand it was dissected from the surrounding parenchymal tissue. A complete excision of the cyst was ensured. Both internal cerebral veins were seen and found intact. Pathological examination confirmed hemorrhage within the colloid cyst. Microscopic examination also showed blood clots containing hemosiderin laden macrophages and many rhomboid cholesterol crystals and chronic inflammatory cells [Figure 3]. Post-operatively she had no seizures. Her memory function completely improved over a 3 week period.

## Discussion

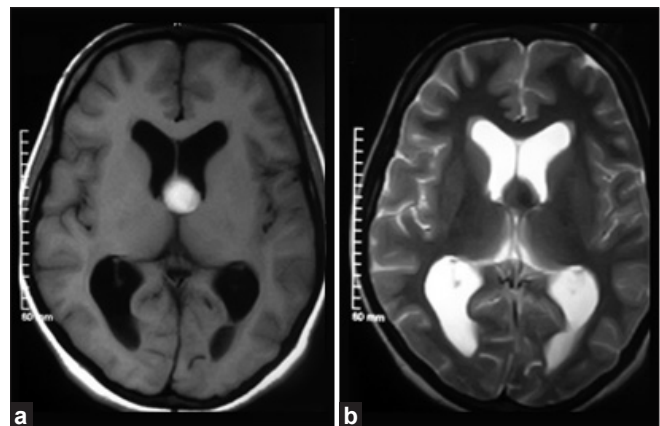
Colloid cysts are benign thin walled cystic lesions located at the anterior part of third ventricle, close to foramen of Monro and contain colloid material.<sup>[2]</sup> These are rare cystic lesions with incidence of 1% per million person-years in epidemiological studies and about 1 per 8500 persons in post-mortem series which suggest that a small percentage become symptomatic.<sup>[3-8]</sup> Although colloid cysts are congenital tumors, their presentation in childhood is rare. They are usually symptomatic in patients aged 20-50 years. They consist of about 0.5-1% of primary brain tumor and 15-20% of intraventricular masses.<sup>[1]</sup> The origin of these cysts continues to be uncertain. Diencephalic ependymoma, invagination of neuroepithelium of the ventricle, or the respiratory epithelium of endodermal origin are the other etiological possibilities.

With the advent of CT/MRI, the numbers of asymptomatic colloid cysts have increased. The natural history is varied and most of the patients have an insidious course. These epithelium lined cysts are troublesome because of their location; they can create serious morbidity and occasionally mortality due to acute obstructive hydrocephalus, and very rarely due to intracystic hemorrhage.<sup>[9-11]</sup> Treatment of asymptomatic and insidiously diagnosed cyst is debatable. Most neurosurgeons advise intervention to prevent life-threatening complications, even though a long-term follow-up study of 68 subjects with asymptomatic colloid cysts suggests that only a few (8%) subjects go on to develop symptoms at 10 years.<sup>[12]</sup>

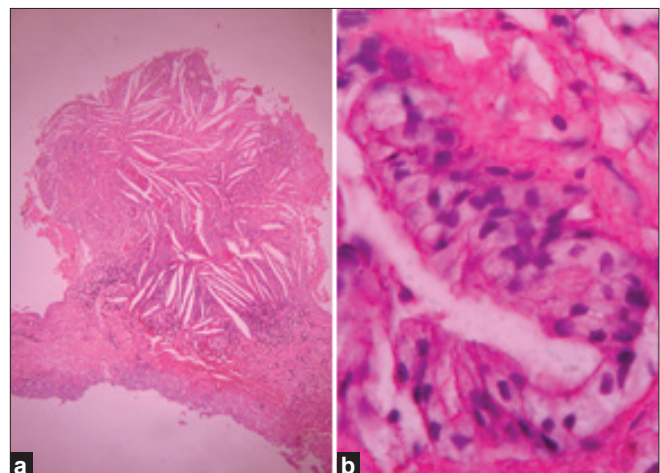
Memory deficit, headache, and cognitive disturbances are most usual symptoms. Dementia, gait disturbances, and urinary incontinence are other modes of presentation. These symptoms are mostly explained by associated hydrocephalus caused by CSF flow obstruction at the level of foramen of Monro. This non-communicating hydrocephalus is the most widely accepted explanation for the cases with acute death. It is not clear why colloid cysts should give rise to an acute and complete obstruction. A sudden change in the pressure/volume compliance in the cranial cavity may result in change in the size and location of the cyst. This might be the reason for sudden bilateral blockade of foramen Monro and sudden neurological deterioration. Although hemorrhagic changes



**Figure 1:** CT brain (axial view). (a) Isodense lesion located at foramen of Monro with hyperdense areas suggestive of hemorrhage with foraminal obstruction. (b) No evidence of enhancement on contrast.



**Figure 2:** MRI brain (axial view). (a) Homogeneously hyperintense lesion at foramen of Monro in T1-weighted sequence. (b) Lesion appears uniformly hyperintense on T2-weighted sequence



**Figure 3:** Photomicrograph. (a) Pseudostratified columnar epithelial cells with occasional ciliated and goblet cells with a thin capsule of fibrous connective tissue suggestive of colloid cyst presence of red blood cells, hemosiderin laden macrophages, rhomboid cholesterol crystals, and chronic inflammatory cells suggestive of hemorrhage in colloid cyst (H and E staining, Magnification 10x). (b) showing cuboidal-to-pseudostratified columnar epithelial cells (H and E staining, Magnification 40x).

of colloid cysts can give rise to an acute increase of cyst dimension resulting in an acute and complete obstruction of CSF circulation, the cause of hemorrhage is not known. In our case, besides headache and vomiting, no life-threatening clinical symptoms were observed. It implies that it is not necessary that hemorrhage will increase in size of cyst and that will induce hydrocephalus and deterioration in clinical condition.

Hemorrhagic colloid cysts are rare. On literature review, we found only six cases of a hemorrhagic colloid cyst; among them four were diagnosed at post-mortem examination.<sup>[1,13-17]</sup>

Beems *et al* described the first clinically diagnosed hemorrhagic colloid cyst with a disastrous clinical course.<sup>[1]</sup> They reported a 35-year-female patient, a diagnosed case of a colloid cyst, who had sudden deterioration one day prior to surgery because of acute hemorrhage in a colloid cyst. In spite of emergency ventriculostomy and endoscopic subtotal excision of cyst, outcome remained relatively poor. The authors concluded that the possibility of hemorrhagic changes in a colloid cyst should be weighted in treatment decisions. Farooq *et al* reported a rare case of hemorrhage in a colloid cyst in 9-year-old girl who presented with headache, nausea, and sudden deterioration in mental status.<sup>[13]</sup> She underwent emergency ventriculostomy, craniotomy, and resection of cyst. She had an excellent recovery. Besides these two cases, four post-mortem proven cases of the hemorrhagic colloid cyst have been published [Table 1].<sup>[14-17]</sup>

The optimal surgical management of colloid cysts continues to be a matter of debate. There are various approaches for the management of symptomatic colloid cysts. The operative procedures usually consist of open microsurgical excision techniques.<sup>[9,10,18-20]</sup> Open microsurgical excision was traditionally considered the "gold standard" treatment. However, operative approaches are not without risks. A transcallosal approach avoids the potential risks of a cortical incision, but still it is associated with occasionally serious

morbidity. The reported complications of this approach include cortical venous infarct, forniceal damage, and injury to the deep venous system, subdural hematoma, disconnection syndromes, ventriculitis, and meningitis.<sup>[9,19,21,22]</sup>

Less invasive procedures like stereotactic aspiration or stereotactic-guided surgeries as well as an endoscopic approach have also been described.<sup>[21,23-25]</sup> The later has an advantage of excellent visualization and minimally invasive corridor through the naturally dilated ventricular system. The quest for less invasive approaches to manage these lesions led to the introduction of aspiration techniques for decompression of the cyst.

The minimally invasive approach to deal with this lesion includes free-hand aspiration which was first described in 1957 by Gutierrez-Lara *et al.*<sup>[26]</sup> Accuracy of this procedure was enhanced by the help of the stereotaxy device, and it was used first by Bosch and co-workers.<sup>[27]</sup> Powell *et al* are credited with the first successful endoscopic aspiration of the colloid cysts.<sup>[28]</sup> Auer *et al* used a neodymium:yttrium-aluminum-garnet laser to endoscopically coagulate the cyst wall.<sup>[29]</sup> Lewis and Kohler have compared craniotomy and endoscopic procedures for colloid cyst resection and have found shorter operative times and hospital stay in patients undergoing endoscopic surgery.<sup>[18]</sup> However, Kondziolka and colleagues found that cysts which are hypodense or isodense on plain CT may only be amenable to successful aspiration.<sup>[25]</sup> Endoscopic transventricular resection strikes a fine balance between the morbidity of open surgery and the low efficacy of needle aspiration. Moreover, leaving the mucin-secreting wall behind after aspiration increases the possible risk of recurrence.<sup>[23]</sup>

A hemorrhagic colloid cyst can create a management problem as it cannot be considered similar to a simple colloid cyst. A thickened cyst wall and the content of the cyst preclude needle aspiration. Manipulation of well-defined solid mass without decompression is always at the cost of damage to surrounding vital structures. The solid adherent clot cannot be sucked out

**Table 1: Reported cases of post-mortem-proven hemorrhagic colloid cyst**

Authors	Age/sex	Presentation	Nature of death	Autopsy findings
Zeitlin H, 1937	42 F	Periodic headache for 12 years, seizures, hypersomnia	Sudden coma followed by death	Colloid cyst with large old and recent hemorrhage
Shuangshoti S, 1965	32 F	Intermittent headache for many years	Died after insertion of Torkildsen's shunt for hydrocephalus	Colloid cyst containing degenerated blood consisting of many degenerating erythrocytes, neutrophils, and iron-containing particles
Malik G, 1980	63 M	Headaches, impaired memory, unsteady gait, and systemic hypertension	Torkildsen's shunt for hydrocephalus. Patient died after two years	The cyst consisted of hemorrhagic amorphous material, abundant clefts of cells, disintegrated neutrophils and erythrocytes
Hadar E, 1999	60 M	Case of follicular mixed lymphoma experienced acute nonlymphocytic leukemia with chronic thrombocytopenia	Unexpected sudden death	Well-circumscribed dark brown and black mass, well adherent to roof of third ventricles. Microscopically hemorrhagic colloid cyst containing large amount of hemorrhage of varying ages

and piecemeal removal is inevitable. We feel that even though endoscope may have several advantages over the microscope, an open microsurgical technique should be considered the best treatment option for a hemorrhagic colloid cyst.

## References

1. Beems T, Menovsky T, Lammens M. Hemorrhagic colloid cyst: case report and review of the literature. *Surg Neurol* 2006;65:84-6.
2. Brun A, Egund N. The pathogenesis of cerebral symptoms in colloid cysts of the third ventricle: a clinical and pathoanatomical study. *Acta Neurol Scand* 1973;49:525-35.
3. de Witt Hamer PC, Verstegen MJ, De Haan RJ, Vandertop WP, Thomeer RT, Mooij JJ, *et al.* High risk of acute deterioration in patients harboring symptomatic colloid cysts of the third ventricle. *J Neurosurg* 2002;96:1041-5.
4. Di Maio TM, Di Maio DJ. Sudden death due to colloid cysts of third cerebralventricle. *N Y State J Med* 1974;74:1832-4.
5. DiMaio SM, DiMaio VJ, Kirkpatrick JB. Sudden, unexpected deaths due to primary intracranial neoplasms. *Am J Forensic Med Pathol* 1980;1:29-45.
6. Gezelius C, Eriksson A. Neoplastic disease in a medicolegal autopsy material. A retrospective study in northern Sweden. *Z Rechtsmed* 1988;101:115-30.
7. Katzman GL, Dagher AP, Patronas NJ. Incidental findings on brain magnetic resonance imaging from 1000 asymptomatic volunteers. *JAMA* 1999;282:36-9.
8. Yue NC, Longstreth WT Jr, Elster AD, Jungreis CA, O'Leary DH, Poirier VC. Clinically serious abnormalities found incidentally at MR imaging of the brain: data from the Cardiovascular Health Study. *Radiology* 1997;202:41-6.
9. Hernesniemi J, Leivo S. Management outcome in third ventricular colloid cysts in a defined population: A series of 40 patients treated mainly by transcallosal microsurgery. *Surg Neurol* 1996;45:2-14.
10. Camacho A, Abernathy CD, Kelly PJ, Laws ER Jr. Colloid cysts: Experience with the management of 84 cases since the introduction of computed tomography. *Neurosurgery* 1989;24:693-700.
11. Buttner A, Winkler PA, Eisenmenger W, Weis S. Colloid cysts of the third ventricle with fatal outcome: A report of two cases and review of literature. *Int J Legal Med* 1997;110:260-6.
12. Pollock BE, Huston J 3rd. Natural history of asymptomatic colloid cysts of the third ventricle. *J Neurosurg* 1999;91:364-9.
13. Farooq MU, Bhatt A, Chang HT. Hemorrhagic colloid cyst in a 9-year-old girl. *Pediatr Neurol* 2008;38:443-4.
14. Zeitlin H, Lichtenstein BW. Cystic tumor of the third ventricle containing colloid material. *Arch Neurol Psychiatry* 1937;38:268-87.
15. Shuangshoti S, Roberts MP, Netsky MG. Neuroepithelial (Colloid) Cysts: Pathogenesis and relation to choroid plexus and ependyma. *Arch Pathol* 1965;80:214-24.
16. Malik GM, Horoupian DS, Boulos RS. Hemorrhagic (colloid) cyst of the third ventricle and episodic neurologic deficits. *Surg Neurol* 1980;13:73-7.
17. Hadar EJ, Schmunk GA, Salamat MS. Hemorrhagic colloid cyst in a patient with leukemia. Case illustration. *J Neurosurg* 1999;91:516.
18. Lewis AI, Crone KR, Taha J, van Loveren HR, Yeh HS, Tew JM Jr. Surgical resection of third ventricle colloid cysts: Preliminary results comparing transcallosal microsurgery with endoscopy. *J Neurosurg* 1994;81:174-8.
19. Apuzzo ML, Chikovani OK, Gott PS, Teng EL, Zee CS, Giannotta SL, *et al.* Transcallosal, interfornicial approaches for lesions affecting the third ventricle: Surgical considerations and consequences. *Neurosurgery* 1982;10:547-54.
20. Gokalp HZ, Yuceer N, Arasil E, Erdogan A, Dincer C, Baskaya M. Colloid cyst of the third ventricle: Evaluation of 28 cases of colloid cyst of the third ventricle operated on by transcortical/transventricular (25 cases) and transcallosal/transventricular (3 cases) approaches. *Acta Neurochir (Wien)* 1996;138:45-9.
21. Mathiesen T, Grane P, Lindgren L, Lindquist C. Third ventricle colloid cysts: A consecutive 12-year series. *J Neurosurg* 1997;86:5-12.
22. Antunes JL, Louis KM, Ganti SR. Colloid cysts of the third ventricle. *Neurosurgery* 1980;7:450-5.
23. Mathiesen T, Grane P, Lindquist C, von Holst H. High recurrence rate following aspiration of colloid cysts in the third ventricle. *J Neurosurg* 1993;78:748-52.
24. Kondziolka D, Lunsford LD. Stereotactic techniques for colloid cysts: Roles of aspiration, endoscopy, and microsurgery. *Acta Neurochir Suppl* 1994;61:76-8.
25. Kondziolka D, Lunsford LD. Stereotactic management of colloid cysts: Factors predicting success. *J Neurosurg* 1991;74:45-51.
26. Gutierrez-Lara F, Patiño R, Hakim S. Treatment of tumors of the third ventricle: A new and simple technique. *Surg Neurol* 1975;3:323-5.
27. Bosch DA, Rdhn T, Backlund EO. Treatment of colloid cysts of the third ventricle by stereotactic aspiration. *Surg Neurol* 1978;9:15-8.
28. Powell MP, Torrens MJ, Thomson JL, Horgan JG. Isodense colloid cysts of the third ventricle: A diagnostic and therapeutic problem resolved by ventriculoscopy. *Neurosurgery* 1983;13:234-7.
29. Auer LM, Holzer P, Ascher PW, Heppner F. Endoscopic neurosurgery. *Acta Neurochir (Wien)* 1988;90:1-14.

**How to cite this article:** Diyora B, Nayak N, Kukreja S, Sharma A. Hemorrhagic colloid cyst: Case report and review of the literature. *Asian J Neurosurg* 2013;8:162-5.

**Source of Support:** Nil, **Conflict of Interest:** None declared.