

Diffuse Dermal Angiomatosis: A Clue to the Diagnosis of Atherosclerotic Vascular Disease

Tueboon Sriphojanart Vasanop Vachiramon

Division of Dermatology, Faculty of Medicine, Ramathibodi Hospital, Mahidol University, Bangkok, Thailand

Key Words

Atherosclerosis · Diffuse dermal angiomatosis · Reactive angiomatosis

Abstract

Diffuse dermal angiomatosis (DDA) is a benign, acquired, reactive vascular proliferation. DDA is clinically characterized by painful purpuric plaque with central ulceration. The histopathologic hallmark is diffuse proliferation of endothelial cells that are arranged interstitially between collagen bundles of the reticular dermis. DDA has been reported in association with peripheral atherosclerotic disease, arteriovenous fistula and heavy smoking. We report the case of a 49-year-old Asian male with DDA who presented with a painful stellate-shaped purpuric patch on the right thigh. Histopathologic examination showed proliferation of CD34-positive spindle cells in the dermis. Our patient underwent vascular bypass surgery along with tight control of cardiovascular risk factors, which yielded successful results.

© 2015 S. Karger AG, Basel

Introduction

Diffuse dermal angiomatosis (DDA) is a benign, acquired, reactive vascular proliferation; it is a variant of reactive angioendotheliomatosis. DDA is characterized by painful, violaceous, purpuric and occasionally ulcerated plaques mainly on the lower extremities of patients with peripheral vascular atherosclerotic disease.

Case Report

A 49-year-old Asian male presented with a painful lesion on right thigh. It had gradually become larger and markedly painful. During the previous 6 months, he had also had intermittent claudication of both legs, the right being worse. His medical history was significant for coronary artery disease, diabetes mellitus, dyslipidemia, hypertension and heavy smoking. Medications included aspirin (325 mg/day), isosorbide dinitrate, glipizide, simvastatin, carvedilol and hydralazine. No other pertinent symptoms were found in systems review. He had no history of previous surgery or trauma on either leg.

Physical examination revealed a solitary, well-defined, stellate-shaped purpuric patch, 10 × 12 cm, on the right thigh, with a superficial central ulceration covered by a hemorrhagic crust (fig. 1). Femoral, popliteal, posterior tibial and dorsalis pedis pulses were absent on both sides. No gangrene or clinical signs of chronic venous insufficiency were observed. There was no lymphadenopathy. A biopsy specimen was obtained from the edge of the lesion. Histopathology showed interstitial proliferation of spindle cells in association with extravasated red blood cells and sparse perivascular inflammatory cell infiltration in the dermis without intravascular proliferation (fig. 2). These spindle cells were positive for CD31 and CD34 (fig. 3) and negative for HHV-8. Computed tomography angiography showed total occlusion of the right infrarenal aorta extending to the aortic bifurcation, both common iliac arteries and the internal and external iliac arteries (fig. 4). Coagulogram was within normal limits.

The diagnosis was DDA. Our patient underwent right axillo-femoral and left femoro-femoral bypass surgery, along with tight control of cardiovascular risk factors, which yielded successful results. The painful lesion rapidly disappeared within 1 week after the operation, leaving postinflammatory hyperpigmentation and a central reticulate scar.

Discussion

DDA is a benign vascular disorder of the skin, classified in the group of cutaneous reactive angiomatosis [1]. It has been described in association with atherosclerotic peripheral vascular disease [2]. It is hypothesized that ischemia or inflammation generates a local hypoxic stimulus, which results in increased vascular endothelial growth factor, endothelial proliferation and neovascularization. In addition, vascular occlusion caused by atherosclerotic plaques may be a source of emboli to distal cutaneous vessels, where they could induce neoangiogenesis [3].

The clinical presentations of DDA consist of erythematous to violaceous, livedoid patches, often with central ulceration [1]. The lesions may be solitary or multiple and are typically found on the lower extremities in patients with severe atherosclerotic disease. DDA has been reported on the forearm secondary to iatrogenic arteriovenous fistulas in chronic hemodialysis patients and in women with nonhealing, ulcerating lesions on the breast [3, 4]. In addition, this cutaneous reactive pattern has also been reported in association with a variety of diseases that cause vasculopathy, including calciphylaxis [5, 6], monoclonal gammopathy [7, 8] and cutis marmorata telangiectatica congenita [9]. The differential diagnosis of DDA includes vasculopathy, medium to large vessel vasculitis, acroangiokeratosis and benign or malignant vascular tumor.

Histologically, DDA is characterized by diffuse proliferation of endothelial cells interstitially arranged between collagen bundles within the dermis [1]. Frequently, the proliferating cells may show a spindled morphology, vacuolated cytoplasm and formation of small vascu-

lar channels, suggesting neoangiogenesis. Scattered extravasated red blood cells and hemosiderin deposition may be apparent. Atypical mitotic figures are always absent.

Immunohistochemistry shows positivity of endothelial cells for *Ulex europaeus* agglutinin-1, factor VIII-associated antigen, CD31 and CD34 [3, 5]. The histologic differential diagnosis includes Kaposi sarcoma, well-differentiated angiosarcoma and acroangiokeratosis. However, cytologic atypia, diffuse slit-like lumen formation and the promontory sign along with the inflammatory component are lacking. Acroangiokeratosis, by contrast, exhibits slight endothelial proliferation and formation of new thick-walled vessels in a lobular arrangement in the dermis.

We performed a PubMed search using the term 'diffuse dermal angiomatosis' and found 29 cases in the English language literature, of which 11 were associated with peripheral artery disease (table 1). The characteristic clinical features of the reported patients were reticulated, erythematous to purpuric plaque with central necrotic area. The medial thigh was most frequently reported. In addition, all reported patients had multiple atherosclerotic comorbidities such as hypertension, dyslipidemia, diabetes mellitus, chronic kidney disease and heavy smoking. Most of them had undergone revascularization procedures, and all lesions rapidly healed shortly after the procedures [2, 10–17]. However, one reported patient who received conservative medical therapy, which included oral prednisolone and colchicine, died from severe sepsis.

The management of DDA generally requires improving underlying tissue hypoxia and ischemia. Revascularization, such as vascular surgery for correcting and bypassing the vascular occlusion, is the most efficient method, particularly in cases caused by vaso-occlusive disease, and generally results in complete or near-complete lesion resolution [11]. The treatment also includes strict control of cardiovascular risk factors. Systemic steroids and isotretinoin have been successfully used as well, based on their inhibitory effect on neoangiogenesis [4].

Summary

DDA is not an uncommon benign vascular condition. It should be considered in a patient who presents with painful, nonhealing purpuric plaque with central ulceration on the upper thigh. Prompt recognition is important as surgical intervention is often curative, thereby limiting the associated morbidity.

Statement of Ethics

We state that our patient gave informed consent. The research complies with all ethical guidelines for human studies.

Disclosure Statement

The authors declare that they have no conflict of interest and that they received no funding.

References

- 1 Rongioletti F, Rebora A: Cutaneous reactive angiomatoses: patterns and classification of reactive vascular proliferation. *J Am Acad Dermatol* 2003;49:887–896.
- 2 Kimyai-Asadi A, Nousari HC, Ketabchi N, Henneberry JM, Costarangos C: Diffuse dermal angiomatosis: a variant of reactive angioendotheliomatosis associated with atherosclerosis. *J Am Acad Dermatol* 1999;40:257–259.
- 3 Requena L, Fariña MC, Renedo G, Alvarez A, Yus ES, Sanguenza OP: Intravascular and diffuse dermal reactive angioendotheliomatosis secondary to iatrogenic arteriovenous fistulas. *J Cutan Pathol* 1999;26:159–164.
- 4 McLaughlin ER, Morris R, Weiss SW, Arbiser JL: Diffuse dermal angiomatosis of the breast: response to isotretinoin. *J Am Acad Dermatol* 2001;45:462–465.
- 5 Prinz Vavricka BM, Barry C, Victor T, Guitart J: Diffuse dermal angiomatosis associated with calciphylaxis. *Am J Dermatopathol* 2009;31:653–657.
- 6 Steele KT, Sullivan BJ, Wanat KA, Rosenbach M, Elenitsas R: Diffuse dermal angiomatosis associated with calciphylaxis in a patient with end-stage renal disease. *J Cutan Pathol* 2013;40:829–832.
- 7 Ferrelli C, Atzori L, Pinna AL, Pau M, Aste N, Ricotti C, Rongioletti F: Diffuse dermal angiomatosis: a clinical mimicker of vasculitis associated with calciphylaxis and monoclonal gammopathy. *G Ital Dermatol Venereol* 2015;150:115–121.
- 8 Quatresooz P, Fumal I, Willemaers V, Cornil F, Piérard GE: Diffuse dermal angiomatosis: a previously undescribed pattern of immunoglobulin and complement deposits in two cases. *Am J Dermatopathol* 2006;28:150–154.
- 9 Halbesleben JJ, Cleveland MG, Stone MS: Diffuse dermal angiomatosis arising in cutis marmorata telangiectatica congenita. *Arch Dermatol* 2010;146:1311–1313.
- 10 Draper BK, Boyd AS: Diffuse dermal angiomatosis. *J Cutan Pathol* 2006;33:646–648.
- 11 Morimoto K, Iioka H, Asada H, Kichikawa K, Taniguchi S, Kuwahara M: Diffuse dermal angiomatosis. *Eur J Vasc Endovasc Surg* 2011;42:381–383.
- 12 Krell JM, Sanchez RL, Solomon AR: Diffuse dermal angiomatosis: a variant of reactive cutaneous angioendotheliomatosis. *J Cutan Pathol* 1994;21:363–370.
- 13 Kim S, Elenitsas R, James WD: Diffuse dermal angiomatosis: a variant of reactive angioendotheliomatosis associated with peripheral vascular atherosclerosis. *Arch Dermatol* 2002;138:456–458.
- 14 Kirkland CR, Hawayek LH, Mutasim DF: Atherosclerosis-induced diffuse dermal angiomatosis with fatal outcome. *Arch Dermatol* 2010;146:684–685.
- 15 Crickx E, Saussine A, Vignon-Pennamen MD, Cordoliani F, Mouly F, Bagot M, Rybojad M: Diffuse dermal angiomatosis associated with severe atherosclerosis: two cases and review of the literature. *Clin Exp Dermatol* 2015, Epub ahead of print.
- 16 Bauer J, Maroon M, Rodenhaver T: Diffuse dermal angiomatosis: characterization of a rare and evolving proliferative vascular endothelial process. *J Am Acad Dermatol* 2007;56(suppl 2):AB81.
- 17 Walton K, Liggett J: Diffuse dermal angiomatosis: a case report. *J Am Acad Dermatol* 2012;66(suppl 1):AB49.

Table 1. Reported cases of peripheral artery disease associated with DDA

Reference (first author), year	Cases, n	Age, years	Sex	Clinical presentation	Location	Underlying diseases	Angiogram	Treatment	Outcome
Krell [12], 1994	2	47	F	large ulcer with erythematous border	rt. medial thigh	PAD	NA	rt. axillo-femoral bypass graft	re-epithelialized ulcer
		63	F	large painful EP, central erosions	lt. medial thigh	PAD	NA	revision of occluded graft	completely healed
Kimyai-Asadi [2], 1999	1	57	F	blanchable, reticulated, EP with a 3-cm purpuric and necrotic area	lt. upper medial thigh	HT, smoking, PAD, CKD	complete occlusion of the lt. renal artery and the infrarenal aorta with collateral flow to the lower extremities	aortobifemoral bypass surgery	completely cleared
Kim [13], 2002	1	58	F	violaceous plaque	lt. medial thigh	HT, DM, heavy smoking	bilateral ischemic disease (Doppler ultrasound)	NA	NA
Draper [10], 2006	1	53	M	violaceous EP with focal ulcerations	lt. lateral leg	PAD, HT, CAD, COPD	80% stenosis of the lt. external iliac artery	revascularization procedure	complete healing
Bauer [16], 2007	1	57	F	adherent 6-mm eschar, surrounding erythema	rt. medial thigh	HT, protein C deficiency, anti-thrombin III deficiency, CKD, AF	NA	NA	NA
Kirkland [14], 2010	1	58	F	violaceous, indurated and reticulated patches with central necrosis	lt. inner thigh, lt. buttock and lt. lower quadrant of the abdomen	heavy smoking, HT, PAD treated with bilateral iliac stents	decreased blood flow distal to lt. iliac stent (Duplex scan)	re-stent the lt. common iliac artery	failed
Morimoto [11], 2011	1	65	M	painful, erythematous lesion with central necrosis	rt. lower leg	HT and heavy smoking	occlusion of the rt. superficial femoral artery	oral prednisolone, catheter recanalization, balloon angioplasty	improved
Walton [17], 2012	1	58	M	nonhealing, painful, ulcerating plaques	bilateral thighs and buttocks	–	severe arterial disease	stent revascularization	improved
Crickx [15], 2015	2	71	F	violaceous, ill-defined, maculonodular eruption with livedoid plaques, painful necrotic ulcerations	trunk and extremities	DM, HT, CKD and AF	atherosclerotic infiltration of the aorta and its branches without occlusion	colchicine, oral prednisolone and oxygen	failed
		81	M	bluish EP with telangiectasia	rt. shoulder	heavy smoking, severe PAD, HT, dyslipidemia	NA	NA	NA

AF = Atrial fibrillation; CAD = coronary artery disease; CKD = chronic kidney disease; COPD = chronic obstructive pulmonary disease; DM = diabetes mellitus; EP = erythematous plaque; HT = hypertension; lt. = left; NA = not available; PAD = peripheral artery disease; rt. = right.

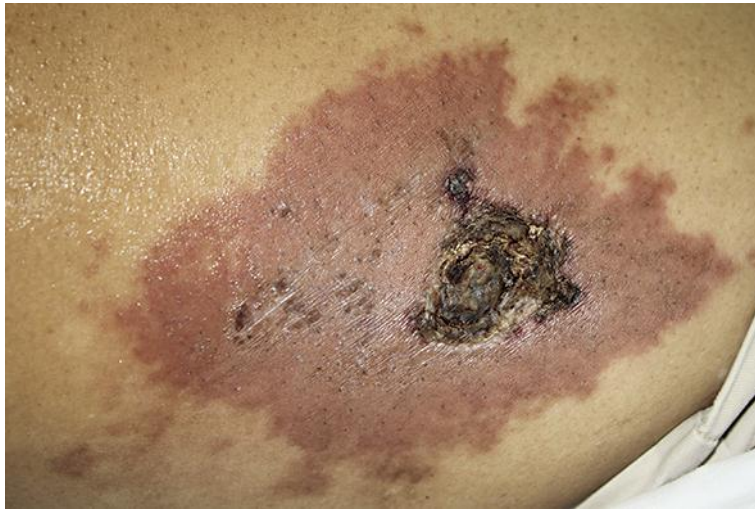

Fig. 1. Serrated purpuric patch on the right thigh, with a superficial central ulceration covered by a hemorrhagic crust.

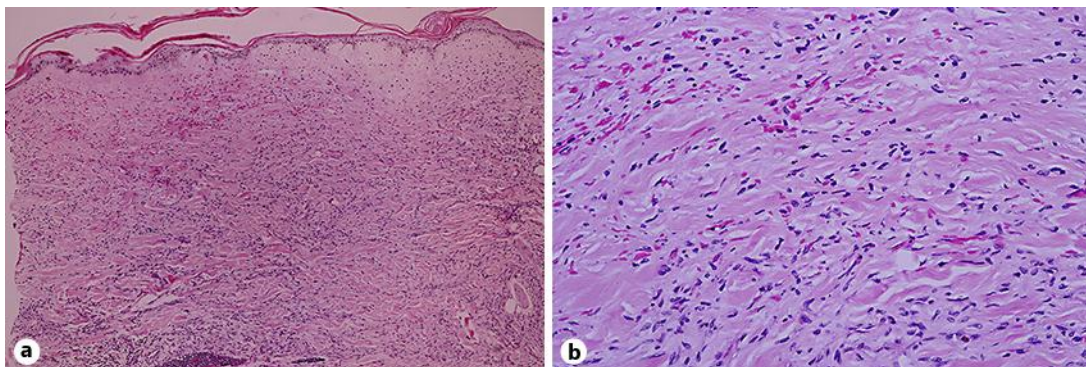


Fig. 2. Interstitial proliferation of spindle cells in association with extravasated red blood cells and sparse perivascular inflammatory cell infiltration in the dermis. Hematoxylin and eosin, original magnification $\times 100$ (a), $\times 400$ (b).

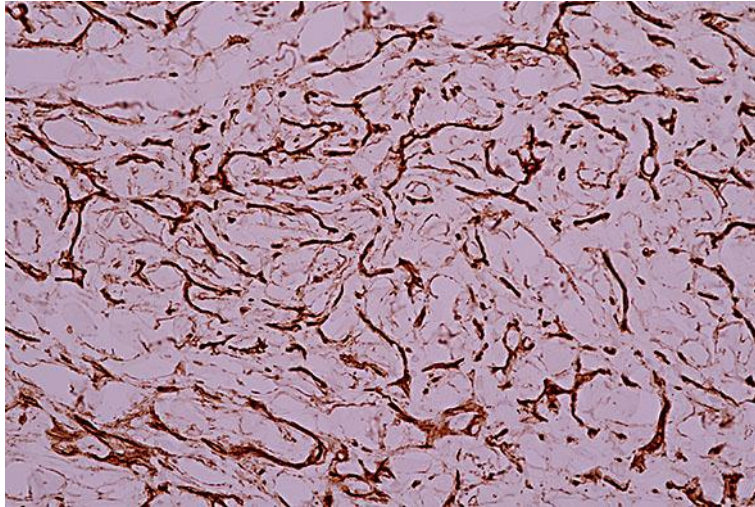


Fig. 3. Spindle cells were positive for CD34, suggesting vascular proliferation. CD34, original magnification $\times 400$.

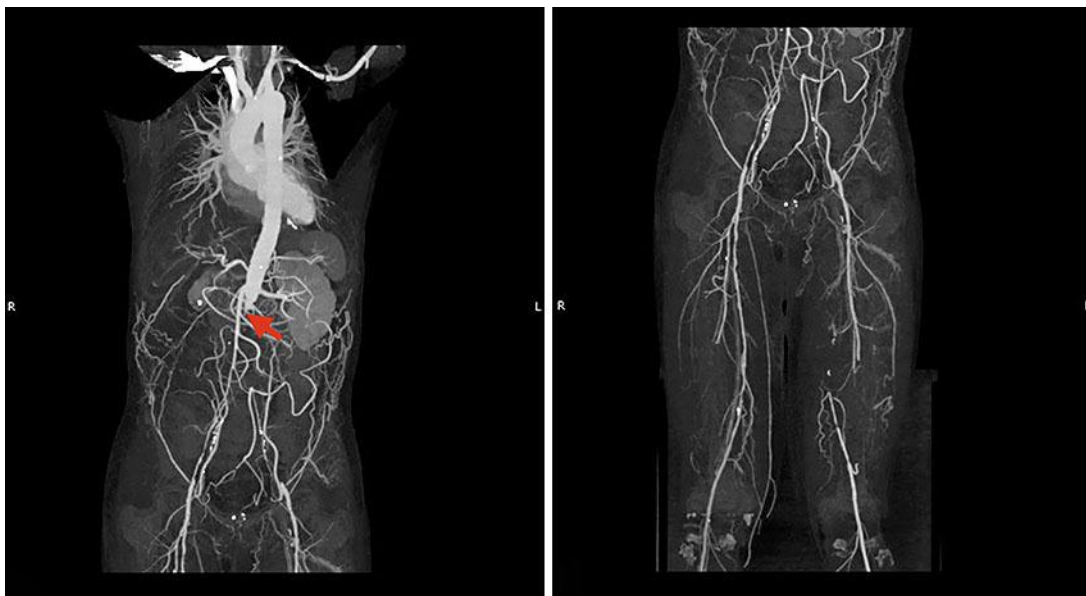

Fig. 4. Computed tomography angiography showing total occlusion of the right infrarenal aorta extending to the aortic bifurcation (arrow), both common iliac arteries and the internal and external iliac arteries.