

Hemorrhagic Macular Infarction after Intravitreal Bevacizumab for Chronic Multifocal Central Serous Chorioretinopathy

Aditya Kelkar^a Poonam Gandhi^a Winfried Amoaku^b Jai Kelkar^a
Shreekant Kelkar^a Priyanka Raut^a Rachana Shah^a

^aNational Institute of Ophthalmology, Pune, India; ^bQueens Medical Centre, Nottingham, UK

Key Words

Hemorrhagic macular infarction · Intravitreal bevacizumab · Central serous chorioretinopathy

Abstract

We hereby report a case of hemorrhagic macular infarction after intravitreal bevacizumab for chronic multifocal central serous chorioretinopathy (CSC). Issues regarding safety and adverse effects of bevacizumab are discussed. To the best of our knowledge, this is the first reported case of hemorrhagic macular infarction after intravitreal bevacizumab for chronic multifocal CSC.

© 2014 S. Karger AG, Basel

Introduction

Central serous chorioretinopathy (CSC) is characterized by an idiopathic serous detachment of the neurosensory retina at the macula resulting from deficient pumping and altered barrier function at the level of the retinal pigment epithelium (RPE). The disease often resolves spontaneously but sometimes recurs or becomes chronic [1].

Chronic CSC occurs more frequently in elderly patients and is often bilateral. It is characterized by multifocal, irregularly distributed and often widespread RPE changes associated with varying degrees of low-grade leakage. Persistent subretinal fluid in chronic CSC can produce severe and irreversible visual loss [2]. Chronic CSC may be associated with persistent subretinal exudation, extensive RPE atrophy, cystoid macular degeneration, and choroidal neovascularization. These factors lead to a less favorable visual prognosis [3, 4].

Aditya Kelkar
National Institute of Ophthalmology
1187/30, off Ghole road, Shivaji nagar
Pune 411005 (India)
E-Mail adityapune4@gmail.com

Vascular endothelial growth factor (VEGF) has been thought to be involved in fluid leakage in patients with chronic CSC. Anti-VEGFs, through their antipermeability characteristics and hence leakage reduction, may be useful in the treatment of cases with refractory CSC and may be helpful as an alternative management [5].

Early studies indicated that intravitreal injections of bevacizumab (Avastin) appeared to be safe and effective for the management of chronic CSC. However, clinical and experimental investigations have reported possible circulatory changes as a complication of intravitreal bevacizumab, consisting of significant depletion of choriocapillaries in primate eyes, progression of capillary nonperfused areas in rabbit eyes, and multiple retinal hemorrhages in eyes with diabetic retinopathy [6, 7].

Here, we report a case of hemorrhagic macular infarction after intravitreal bevacizumab for chronic multifocal CSC.

Case Report

A 56-year-old male presented with complaints of gradual loss of vision and distortion in the right eye which had started 2 years before. He had no significant ocular or medical history. His best-corrected visual acuity (BCVA) in the right eye was 20/40 on Snellen's chart and intraocular pressure was 10 mm Hg. Anterior segment findings on slit-lamp examination showed immature cataract in both eyes, the rest was within normal limits.

Dilated fundus examination (fig. 1) of the right eye showed presence of retinal pigmentary changes and absence of foveal reflex. The left eye fundus showed mottled retinal pigment alteration. OCT showed a shallow RPE elevation, with reflectivity under the RPE layer suggestive of nonserous pigment epithelial detachment (PED), along with minimal subretinal fluid.

Fundus fluorescein angiography (fig. 1) of the right eye revealed a 2.5-mm disc diameter of mottled hyperfluorescence increasing in size and intensity in the macular area – diagnostic of chronic multifocal CSC – and the left eye showed mottled hyperfluorescence that was not increasing in size or intensity. The patient was scheduled for a right-eye intravitreal injection of bevacizumab.

After obtaining signed informed consent, the patient received an intravitreal injection of 0.05 ml bevacizumab under all aseptic precautions, and prophylactic antibiotic eye drops were given for 7 days subsequently. No intraoperative or early postoperative complications were observed. One-day and one-week follow-up visits showed stable fundus with a right-eye BCVA of 20/40 on Snellen's chart.

One month after the injection, the patient presented with a sudden diminution of vision in the right eye starting 1 week before. The BCVA in the right eye was counting fingers at 1 m and intraocular pressure in the right eye was 10 mm Hg. The left eye was quiet. On fundus examination of the right eye (fig. 2), there were multiple hemorrhages, PED and extensive hard exudates at the macula, inferior to the arcade as well as nasal to the disc. The fundus of the left eye was unchanged.

Right-eye OCT (fig. 2) showed an increase in the sensory detachment with fluid accumulation in the sensory retina and a small PED. Fluorescein angiography (fig. 2) showed a large area of capillary nonperfusion with adjacent mottled hyperfluorescence. Small areas of blocked fluorescence were also noted, which was suggestive of hemorrhagic macular infarction.

Discussion

The reported case shows the clinical and angiographic findings of hemorrhagic macular infarction after intravitreal bevacizumab for chronic multifocal CSC. Bevacizumab is not currently approved by the FDA for intravitreal injection; however, several reports state that off-label intravitreal bevacizumab for chronic CSC results in an overall improvement in visual acuity and macular anatomy and appears to be safe and effective in the short term.

In recent years, choroidal hyperpermeability has been assumed to be the cause of CSC based upon indocyanine green angiography and has been considered a basis of photodynamic treatment. VEGF is one of the major cytokines that induce vascular hyperpermeability. An intraocular injection of anti-VEGF bevacizumab may improve the symptoms of CSC by blocking the activity of VEGF. To date, however, no studies have demonstrated a correlation between hyperpermeability of the choroidal vessel and VEGF.

The effectiveness of this treatment method has been described previously. In a case series on 12 eyes, Schaal et al. [5] showed that in cases with chronic CSC, intravitreal bevacizumab injection improved BCVA and reduced central macular thickness and recurrence did not occur in any case during the follow-up period.

There are also case reports discussing hemorrhagic macular infarction after intravitreal bevacizumab for macular edema in vascular occlusions and age-related macular degeneration [8–10]. In all these cases, patients had one or more significant medical history (i.e. hypertension, diabetes, IHD, etc.) and they were on a number of medicines (i.e. aspirin, anticoagulants, other antiplatelet and antithrombotic agents, etc.), which, along with Avastin, could increase the possibility of drug-induced hemorrhagic infarct.

The peculiarity of our case is that our patient had had no significant ocular or medical history until the time he visited us for the first time. So the possibility of any systemic event or other medicine as causality is ruled out. The apparent explanation for the event in our case could be bevacizumab.

Clinical trials for bevacizumab in the treatment of metastatic colon cancer demonstrated increased risk of arterial thromboembolic events, hypertension, proteinuria and congestive heart failure. Even the FDA has reported severe adverse events with Avastin such as serious or fatal hemoptysis in patients with adenocarcinoma (4% incidence rate) and gastrointestinal perforation in patients with colorectal cancer (2% incidence rate). However, there is no substantial data on the safe use of intravitreal bevacizumab and it remains off-label for ocular use.

To conclude, we have hereby reported a case of hemorrhagic macular infarction after intravitreal bevacizumab for chronic multifocal CSC, which has not been reported before to the best of our knowledge. We urge clinicians to carefully evaluate their patients before giving bevacizumab for ocular indications, and we hope that the medical community will take time to report such events if they come across them in practice. We might find a warning sign, and we may prevent any unintended harm to our patients.

References

- 1 Gilbert CM, Owens SL, Smith PD, Fine SL: Long-term follow-up of central serous chorioretinopathy. *Br J Ophthalmol* 1984;68:815–820.
- 2 Huang WC, Chen WL, Tsai YY, Chiang CC, Lin JM: Intravitreal bevacizumab for treatment of chronic central serous chorioretinopathy. *Eye* 2009;23:488–489.
- 3 Iida T, Yannuzzi LA, Spaide RF, et al: Cystoid macular degeneration in chronic central serous chorioretinopathy. *Retina* 2003;23:1–7.

- 4 Wang M, Munch IC, Hasler PW, Prünke C, Larsen M: Central serous chorioretinopathy. *Acta Ophthalmol Scand* 2008;86:126–145.
- 5 Schaal KB, Hoeh AE, Scheuerle A, Schuett F, Dithmar S: Intravitreal bevacizumab for treatment of chronic central serous chorioretinopathy. *Eur J Ophthalmol* 2009;19:613–617.
- 6 Peters S, Heiduschka P, Jullien S, Ziemssen F, Fietz H, Bartz-Schmidt KU; Tübingen Bevacizumab Study Group, Schraermeyer U: Ultrastructural findings in the primate eyes after intravitreal injection of bevacizumab. *Am J Ophthalmol* 2007;143:995–1002.
- 7 Lee CS, Koh HJ: Multiple retinal hemorrhages in diabetic retinopathy after adjunctive intravitreal bevacizumab (Avastin) with pars plana vitrectomy. *Acta Ophthalmol* 2008;86:812–813.
- 8 Shimura M, Yasuda K: Macular ischaemia after intravitreal bevacizumab in patients with central retinal vein occlusion and a history of diabetes and vascular disease. *Br J Ophthalmol* 2010;94:381–383.
- 9 Isola V, Pece A, Massironi C, Reposi S, Dimastrogiovanni F: Accelerated ischemic vascular retinopathy after intravitreally injected bevacizumab for central retinal vein occlusion in elderly patients. *Clin Ophthalmol* 2013;7:455–460.
- 10 Chieh JJ, Fekrat S: Large subretinal hemorrhage after intravitreal bevacizumab (Avastin) for age-related macular degeneration. *Ann Ophthalmol (Skokie)* 2007;39:51–52.

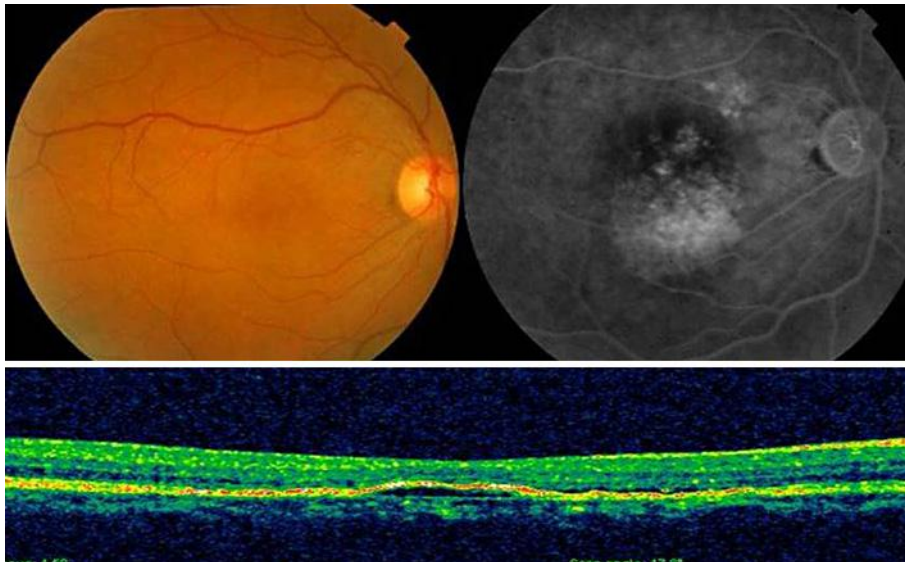


Fig. 1. Right-eye fundus preinjection showing pigmentary changes at the fovea with blunted foveal reflex. Right-eye OCT: shallow RPE elevation with reflectivity under the RPE layer suggestive of nonserous PED, along with minimal subretinal fluid. Right-eye fluorescein angiography preinjection: mottled hyperfluorescence of 2.5-mm disc diameters.

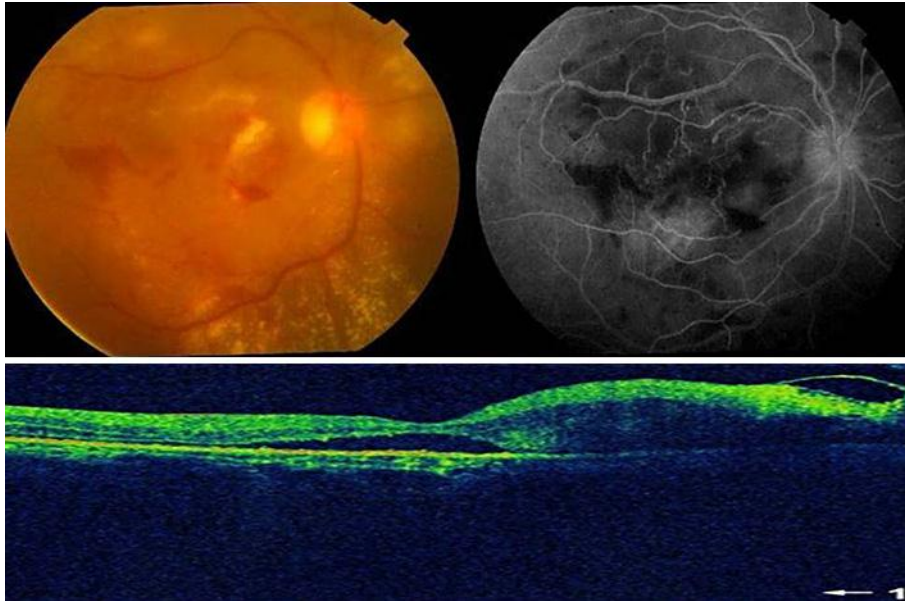


Fig. 2. Right-eye fundus 1 month postinjection showing multiple hemorrhages, PED and extensive hard exudates at the macula, inferior to the arcade as well as nasal to the disc. OCT: increase in sensory detachment with fluid accumulation in the sensory retina. Fluorescein angiography: areas of capillary nonperfusion with adjacent mottled hyperfluorescence.