


CASE REPORT

Cutaneous squamous cell carcinoma in an autosomal-recessive Adams–Oliver syndrome patient with a novel frameshift pathogenic variant in the *EOGT* gene

Meyer-Landolt Lukas¹ | Gaspar Harald² | Javier Sanz² | Mafalda Trippel³ |
Gallati Sabina² | Rössler Jochen¹ 

¹Division of Pediatric Hematology & Oncology, Department of Pediatrics, Inselspital, University Hospital, University of Bern, Bern, Switzerland

²Department of Human Genetics, Inselspital, Bern University Hospital, University of Bern, Bern, Switzerland

³Institute of Pathology, University of Bern, Bern, Switzerland

Correspondence

Rössler Jochen, Division of Pediatric Hematology & Oncology, Department of Pediatrics, Inselspital, University Hospital, University of Bern, Freiburgstrasse 15, 3010 Bern, Switzerland.

Email: jochen.roessler@insel.ch

Present address

Gaspar Harald, Medical Genetics Mainz, Mainz, Germany.

Abstract

Aplasia cutis congenita (ACC) of the scalp and terminal transverse limb defects (TTLD) are the characteristic findings of Adams–Oliver syndrome (AOS). The variable clinical spectrum further includes cardiac, neurologic, renal, and ophthalmological findings. Associated genes in AOS are in the Notch and the CDC42/Rac1 signaling pathways. Both autosomal-dominant and autosomal-recessive inheritances have been reported, the latter with pathogenic variants in *DOCK6* or *EOGT*. The *EOGT*-associated recessive type of AOS has been postulated to present a more favorable prognosis. We here report a 12-year-old girl from a refugee family of Iraq with consanguineous parents. She was born with a severe phenotype of AOS presenting a large ACC of the scalp with an underlying skull defect, which was often infected and inflamed. Afterward, additional ulceration developed. Furthermore, the girl showed microcephaly, TTLD on both hands and feet, and neurological findings: spastic paresis, epilepsy and suspicion of intellectual deficit. Molecular genetic analysis (next-generation sequencing) revealed a novel frameshift mutation in the *EOGT* gene in Exon 13 in homozygous constellation: c.1013dupA p.(Asn338Lysfs*24). A biopsy within an ulceration at the scalp ACC showed a cutaneous squamous cell carcinoma (cSCC) with local invasive growth into the dura, the meninges, and the cortex. Treatment including surgical resection and focal irradiation was not curative and the girl deceased 6 months after initial diagnosis. This report on a patient with AOS and an autosomal-recessive *EOGT* gene variant dying of a local aggressive cSCC at an ACC lesion shows that close monitoring of ACC is essential.

KEYWORDS

Adams–Oliver syndrome, *EOGT* gene, squamous cell carcinoma

This is an open access article under the terms of the [Creative Commons Attribution-NonCommercial](https://creativecommons.org/licenses/by-nc/4.0/) License, which permits use, distribution and reproduction in any medium, provided the original work is properly cited and is not used for commercial purposes.

© 2022 The Authors. *American Journal of Medical Genetics Part A* published by Wiley Periodicals LLC.

1 | INTRODUCTION

Adams–Oliver syndrome (AOS) is defined by aplasia cutis congenita (ACC) of the scalp and terminal transverse limb defects (TTLD), referring to the first description in 1945 (Adams and Oliver, 1945). The clinical findings are variable with a spectrum of mildly to severely affected individuals. In addition, there can be cardiac, neurologic, renal, and ophthalmological findings (Hassed et al., 2017). Several genes have been identified: *ARHGAP31* (Southgate et al., 2011), *DLL4*, *NOTCH1* (Southgate et al., 2015; Stittrich et al., 2014), and *RBPJ* are associated with autosomal-dominant inheritance, *DOCK6* and *EOGT* with autosomal-recessive inheritance (Meester et al., 2018). In autosomal-dominant families, the penetrance can be reduced and neurologic findings are very rare. Autosomal-recessive phenotypes are related to large ACC and minor limb and other organ involvement (Schroder et al., 2019). An association with an increased risk for tumor development is not known in AOS.

We here report a female case of AOS with a novel homozygous frameshift mutation in the *EOGT* gene leading to an uncommonly severe phenotype and the development of a lethal cutaneous squamous cell carcinoma (cSCC).

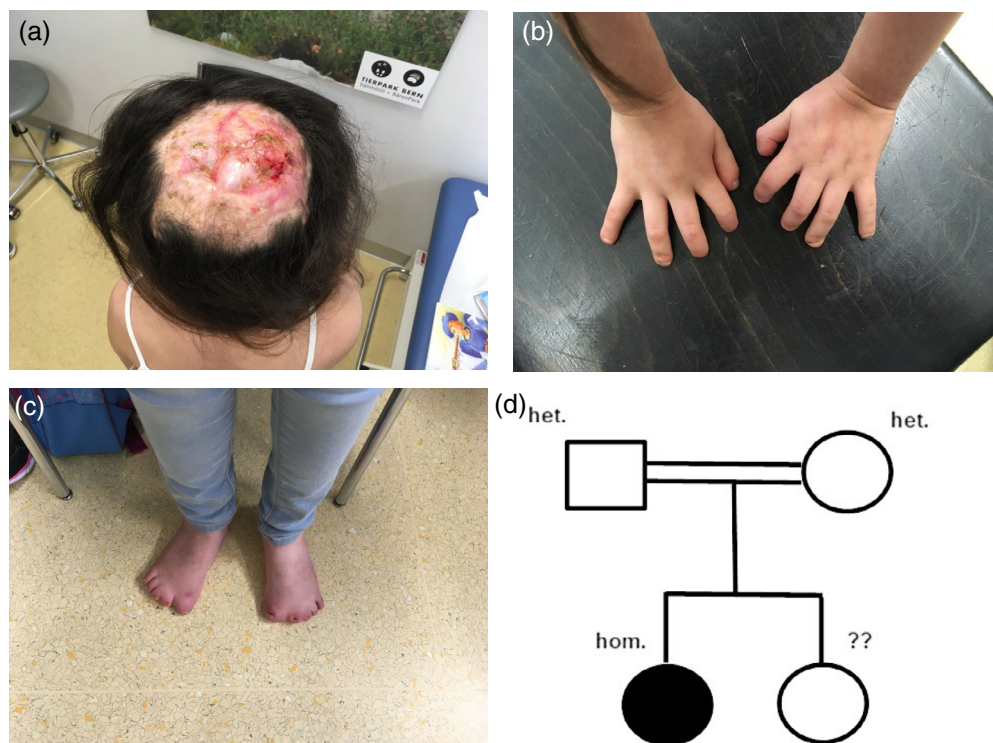
2 | CLINICAL REPORT

A 12-year-old girl presented in our clinic with the clinical diagnosis of AOS. She was the first daughter of a refugee family from Middle Eastern origin with consanguineous parents (first cousins) and had grown

up in her home country Iraq. Since birth, an ACC with very sensitive skin was known, which had been often infected and inflamed. In addition, she had developmental delay and seizures starting at the age of 5 years. On clinical examination, she showed a large area of ACC on the skull with several small ulcerative lesions (Figure 1a) and a bone defect of 10 × 10 cm underneath the skin defect, microcephaly, a spastic paresis, and brachydactyly of hands (Figure 1b) and brachysyndactyly of the feet (Figure 1c) in terms of TTLD as well as hypoplastic nails. Echocardiography was normal. Other family members, especially the parents and the healthy sister, did not show any hints for neither ACC, TTLD, nor other findings typical for AOS (Figure 1d).

The ulcerated lesions on the ACC have been present for several years and were treated topically by different creams. Two months after referral, spontaneous leaking of cerebrospinal fluid from such an ulcerated lesion developed (Figure 2a). Evaluation by magnetic resonance imaging showed a solid lesion infiltrating the dura and possibly the meninges (Figure 2b). Finally, a biopsy revealed the diagnosis of a poorly differentiated cSCC with infiltration into the soft tissue and the adjacent brain parenchyma (Figure 3). Due to this complicated localization, complete resection of the cSCC was not possible and partial excision of the tumor with intraoperative radiotherapy with 10 Gy of the tumor bed and placement of a reconstructive skin graft was performed according to current guidelines for inoperable cSCC (Stratigos et al., 2020). Histologically, the cSCC infiltrated the brain cortex, leading to final TNM-classification as pT4b pN0 (0/1) L0 V0 Pn0 G3 R1. Due to multiple complications with the skin graft, several re-operations were necessary, and a planned adjuvant radiotherapy had to be postponed. Shortly thereafter, the patient presented with

FIGURE 1 Phenotypic findings of the AOS patient with (a) large ACC of the scalp and TTLD as well as hypoplastic nails on both hands (b) and feet (c). Pedigree of the family (d) with the homozygous (hom.) mutated *EOGT* patient and the heterogeneous (het.) parents. The healthy sister was not screened. ACC, aplasia cutis congenita; AOS, Adams–Oliver syndrome; TTLD, terminal transverse limb defects



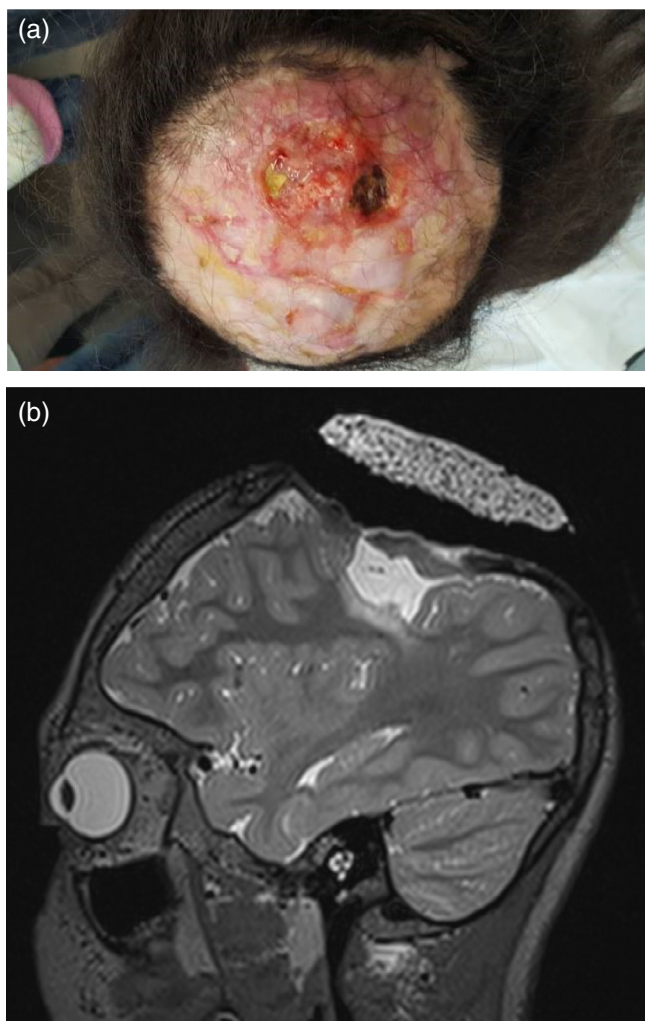


FIGURE 2 cSCC at the (a) ulcerated and inflamed ACC defect of the scalp. (b) Magnetic resonance imaging of the brain with signs of meningeal infiltration by the cSCC. ACC, aplasia cutis congenita; cSCC, cutaneous squamous cell carcinoma

vomiting and headache. MRI scan showed local progressive growth of the tumor along the medulla oblongata and the cranial nerves. In this palliative setting, we performed whole brain irradiation with 20 Gy for symptom control and a systemic therapy with PD1-inhibitors evaluated according to recent promising results for medical therapy of cSCC (Stratigos et al., 2020). However, further clinical deterioration occurred and the patient died at home 6 months after initial diagnosis at the age of 13 years.

Molecular genetic analysis (next-generation sequencing) with panel analysis of the genes *ARHGAP31*, *DLL4*, *NOTCH1*, *RBPJ*, *DOCK6*, and *EOGT* (TruSight One Expanded, Illumina) revealed a novel frameshift mutation in the *EOGT* gene in Exon 13 in homozygous constellation: c.1013dupA p.(Asn338Lysfs*24). This was classified as a pathogenic variant, according to the ACMG criteria. Both parents were heterozygous for this variant, adequate to the consanguineous relationship between the parents. This variant confirmed the clinical diagnosis AOS.

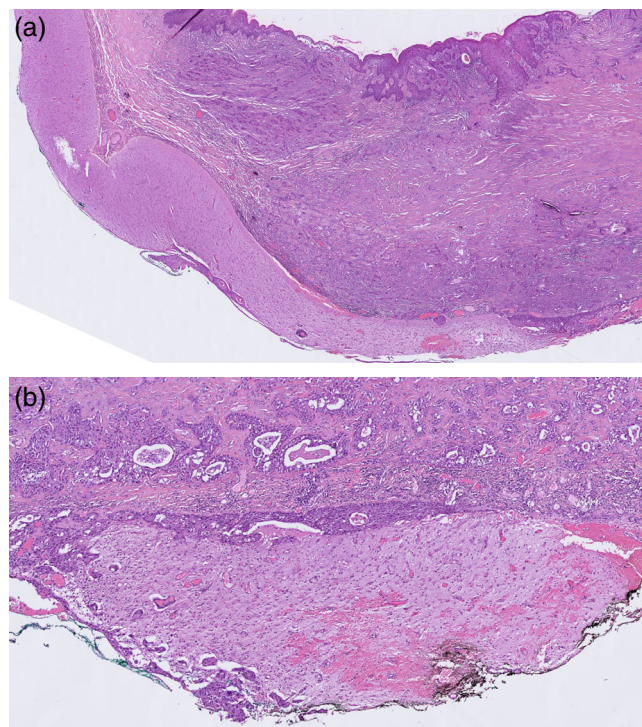


FIGURE 3 Histopathology of cutaneous squamous cell carcinoma (cSCC). (a) Poorly differentiated cSCC with infiltration into the soft tissue (right side of image) and adjacent brain parenchyma (left side of image; HE, $\times 1.77$ magnification). (b) Infiltration of the adjacent brain parenchyma (base of image; HE, $\times 5$ magnification).

3 | DISCUSSION

Pathogenic variants in *EOGT* are a very rare autosomal recessive cause of AOS and only a limited number of families have been described to date (Cohen et al., 2014; Meester et al., 2018; Schroder et al., 2019; Shaheen et al., 2013). Seven causative variants have been described so far: c.1130G>A, c.620G>C, c.1074delA, c.404G>A, c.311+1G>T, c.78_81delTCAC, c.1335-1G>A, suggesting a founder mutation in consanguineous families of Arabic ancestry (Table 1).

Molecular genetic analysis in our patient revealed a novel frameshift mutation in the *EOGT* gene in Exon 13 in homozygous constellation: c.1013dupA p.(Asn338Lysfs*24). This variant was classified as a pathogenic variant, according to the ACMG criteria (PVS1, PM2, PP4). The variant leads to a premature stop-codon and shortened protein with complete or significant loss of function or nonsense-mediated mRNA decay. So far, it is listed as a very rare variant in population databases with a frequency of about 0.00076%. The consanguineous parents were both heterozygous for this variant.

An association between cSCC and AOS has not been described in the literature so far. Probably, the development of the cSCC was fostered by recurrent inflammation of the ACC and the delay in treatment initiation (Figure 1). Wounds in the area of ACC have been described previously (Sezgin et al., 2017) as well as infections (Udayakumaran et al., 2013) and cerebral fluid leakage (Trops

TABLE 1 Overview on phenotype and genetics of published AOS cases with mutations in *EOGT* gene

	Sex	Mutation in <i>EOGT</i> gene	ACC, TTLD		Neurologic finding		References
			Nail anomalies CMTC	Heart defect	Developmental delay	Death	
Patient #1 Turkish origin	M	Homozygous c.404G>A	Large parieto-occipital scalp ACC with a bony defect and herniation of brain Small finger and toenails	No	No	No	Schroder et al. (2019)
Patient #2 German origin	M	Homozygous c.311+1G>T	ACC form occiput to forehead (8 cm) with an underlying bony defect CMTC	No	No	No	Schroder et al. (2019)
Patient 3# German origin Sibling of patient 2#	M	n.d.	ACC with two bony defects (8 cm) TTLD Rudimentary nails of the left foot	No	n.d. n.d.	Still birth	Schroder et al. (2019)
Patients #4 to #11 Three pedigrees of Israeli Bedouins	M (n = 4) F (n = 3)	Homozygous c.1074delA	ACC (n = 6) TTLD (n = 4)	No	n.d. n.d.	Yes (n = 2)	Cohen et al. (2014)
Patients #12 to #19 Five pedigrees of Israeli Bedouins (same clan as Patients #4 to #11)	M (n = 3) F (n = 4)	Homozygous c.1074delA	ACC (n = 7) TTLD (n = 6)	No (n = 6) VSD (n = 1)	Convulsions and basal ganglia ischemic changes (n = 1)	Yes (n = 1)	Cohen et al. (2014)
Patient #20	F	Homozygous c.620G>C	Parietal scalp defect (15 cm) TTLD Hypoplastic nails	ASD-II	n.d.	n.d.	Shaheen et al. (2013)
Patient #21	M	Homozygous c.1074delA	Scalp defect (5 cm) TTLD Hypoplastic nails CMTC	VSD PDA	Left temporal and occipital lobe infarcts (presumed prenatal origin) Speech and fine-motor delays	n.d.	Shaheen et al. (2013)
Patient #22	F	Homozygous c.1130G>A	Small bony defect (5 cm) in the skull vault involving both parietal bones and covered with hairless scalp skin TTLD Hypoplastic nails	n.d.	n.d.	n.d.	Shaheen et al. (2013)
Patient #23	F	Homozygous c.1130G>A	Small midline bony defect (1 cm) in the skull vault	n.d.	n.d.	n.d.	Shaheen et al. (2013)

(Continues)

TABLE 1 (Continued)

Sex	Mutation in <i>EOGT</i> gene	ACC, TTLD	Heart defect	Neurologic finding		References	
		Nail anomalies CMTC		Developmental delay	Death		
		covered with sparsely haired scalp skin TTLD Dysplastic nails in all toes					
Patient #24	M	Homozygous c.1130G>A	Large midline skull defect (5 cm) involving both parietal bones and is covered with hairless scalp skin TTLD Severe dysplastic nails	n.d.	n.d.	n.d.	Shaheen et al. (2013)
Patient #25	M	Compound heterozygous c.78_81delTCAC c.1335-1G>A	ACC and TTLD, cryptorchidism, small penis	n.d.	Severe developmental delay	n.d.	Meester et al. (2018)
Patient #26	n.d.	Homozygous c.78_81delTCAC	n.d.	n.d.	n.d.	n.d.	Meester et al. (2018)

Abbreviations: ACC, aplasia cutis congenital; AOS, Adams–Oliver syndrome; CMTC, cutis marmorata teleangiectatica congenital; n.d., not determined; TTLD, terminal transverse limb defect; VSD, ventricle septum defect; PDA, persistent ductus arteriosus.

et al., 2010). However, reports on cSCC are missing. This is in contrast to the well-known risk for cSCC in epidermolysis bullosa (EB) patients where the majority occur in the recessive dystrophic EB (RDEB) form at the upper and lower extremities, particularly over bony prominences, and typically in areas of chronic nonhealing ulceration(s) (Montaudie et al., 2016). The cSCC in RDEB are the most common cause of death as they generally become very aggressive and thus yield a poor prognosis.

The six genes found to be causally related to AOS function in the CDC42/RAC1 pathway ($n = 2$) or are important in the Notch signaling ($n = 4$). It seems that the basic underlying problems of these variants are related to abnormalities in blood vessel development. Importantly, tumor predisposition has not been reported so far. The *EOGT* gene encodes for an enzyme, the eukaryotic growth factor (EGF) domain-specific O-linked N-acetylglucosamine transferase, that acts in the lumen of the endoplasmic reticulum and modifies proteins containing EGF-like domains, including the Notch receptor. A possible mechanism of malignant transformation could be the activation of Notch signaling by the mutated *EOGT*. However, this remains speculative, we cannot rule out that other factors might have led to malignant transformation and that the findings are coincidental. Chronic inflammation will have been an important input, and as the parents are consanguineous, additional variants in tumor predisposition genes might also have occurred.

In conclusion, this case report suggests and highlights the importance of regular monitoring of ACC in AOS patients, especially with *EOGT* variants.

ACKNOWLEDGMENTS

The authors thank the family for their kind cooperation and all members of the interdisciplinary therapy team. Open access funding provided by Inselspital Universitatsspital Bern.

CONFLICT OF INTEREST

The authors declare no conflict of interest.

DATA AVAILABILITY STATEMENT

Data sharing is not applicable to this article as no new data were created or analyzed in this study.

ORCID

Rössler Jochen  <https://orcid.org/0000-0003-4022-4917>

REFERENCES

Adams, F. H., & Oliver, C. P. (1945). Hereditary deformities in man. *Journal of Heredity*, 36(1), 3–7. <https://doi.org/10.1093/oxfordjournals.jhered.a105415>

- Cohen, I., Silberstein, E., Perez, Y., Landau, D., Elbedour, K., Langer, Y., Kadir, R., Volodarsky, M., Sivan, S., Narkis, G., & Birk, O. S. (2014). Autosomal recessive Adams–Oliver syndrome caused by homozygous mutation in EOGT, encoding an EGF domain-specific O-GlcNAc transferase. *European Journal of Human Genetics*, 22(3), 374–378.
- Hassed, S., Li, S., Mulvihill, J., Aston, C., & Palmer, S. (2017). Adams–Oliver syndrome review of the literature: Refining the diagnostic phenotype. *American Journal of Medical Genetics. Part A*, 173(3), 790–800.
- Meester, J. A. N., Sukalo, M., Schroder, K. C., Schanze, D., Baynam, G., Borck, G., Bramswig, N. C., Duman, D., Gilbert-Dussardier, B., Holder-Espinasse, M., Itin, P., Johnson, D. S., Joss, S., Koillinen, H., McKenzie, F., Morton, J., Nelle, H., Reardon, W., Roll, C., ... Wuyts, W. (2018). Elucidating the genetic architecture of Adams–Oliver syndrome in a large European cohort. *Human Mutation*, 39(9), 1246–1261.
- Montaudie, H., Chiaverini, C., Sbidian, E., Charlesworth, A., & Lacour, J. P. (2016). Inherited epidermolysis bullosa and squamous cell carcinoma: A systematic review of 117 cases. *Orphanet Journal of Rare Diseases*, 11(1), 117.
- Schroder, K. C., Duman, D., Tekin, M., Schanze, D., Sukalo, M., Meester, J., Wuyts, W., & Zenker, M. (2019). Adams–Oliver syndrome caused by mutations of the EOGT gene. *American Journal of Medical Genetics. Part A*, 179(11), 2246–2251.
- Sezgin, B., Sibar, S., Findikcioglu, K., Sencan, A., Emmez, H., Baykaner, K., & Ozmen, S. (2017). Use of an epidermal growth factor-infused foam dressing in a complicated case of Adams–Oliver syndrome. *Journal of Wound Care*, 26(6), 342–345.
- Shaheen, R., Aglan, M., Keppler-Noreuil, K., Faqeih, E., Ansari, S., Horton, K., Ashour, A., Zaki, M. S., Al-Zahrani, F., Cueto-Gonzalez, A. M., Abdel-Salam, G., Temtamy, S., & Alkuraya, F. S. (2013). Mutations in EOGT confirm the genetic heterogeneity of autosomal-recessive Adams–Oliver syndrome. *American Journal of Human Genetics*, 92(4), 598–604.
- Southgate, L., Machado, R. D., Snape, K. M., Primeau, M., Dafou, D., Ruddy, D. M., Branney, P. A., Fisher, M., Lee, G. J., Simpson, M. A., He, Y., Bradshaw, T. Y., Blaumeiser, B., Winship, W. S., Reardon, W., Maher, E. R., FitzPatrick, D. R., Wuyts, W., Zenker, M., ... Trembath, R. C. (2011). Gain-of-function mutations of ARHGAP31, a Cdc42/Rac1 GTPase regulator, cause syndromic cutis aplasia and limb anomalies. *American Journal of Human Genetics*, 88(5), 574–585.
- Southgate, L., Sukalo, M., Karountzos, A. S. V., Taylor, E. J., Collinson, C. S., Ruddy, D., Snape, K. M., Dallapiccola, B., Tolmie, J. L., Joss, S., Brancati, F., Digilio, M. C., Graul-Neumann, L. M., Salviati, L., Coerdts, W., Jacquemin, E., Wuyts, W., Zenker, M., Machado, R. D., & Trembath, R. C. (2015). Haploinsufficiency of the NOTCH1 receptor as a cause of Adams–Oliver syndrome with variable cardiac anomalies. *Circulation. Cardiovascular Genetics*, 8(4), 572–581.
- Stittrich, A. B., Lehman, A., Bodian, D. L., Ashworth, J., Zong, Z., Li, H., Lam, P., Khromykh, A., Iyer, R. K., Vockley, J. G., Baveja, R., Silva, E. S., Dixon, J., Leon, E. L., Solomon, B. D., Glusman, G., Niederhuber, J. E., Roach, J. C., & Patel, M. S. (2014). Mutations in NOTCH1 cause Adams–Oliver syndrome. *American Journal of Human Genetics*, 95(3), 275–284.
- Stratigos, A. J., Garbe, C., Dessinioti, C., Lebbe, C., Bataille, V., Bastholt, L., Dreno, B., Concetta Farnoli, M., Forsea, A. M., Frenard, C., Harwood, C. A., Hauschild, A., Hoeller, C., Kandolf-Sekulovic, L., Kaufmann, R., Kelleners-Smeets, N. W. J., Malvehy, J., Del Marmol, V., Middleton, M. R., ... European Dermatology Forum (EDF), the European Association of Dermato-Oncology (EADO) and the European Organization for Research and Treatment of Cancer (EORTC). (2020). European interdisciplinary guideline on invasive squamous cell carcinoma of the skin: Part 2. Treatment. *European Journal of Cancer*, 128, 83–102.
- Trobs, R. B., Barenberg, K., Hemminghaus, M., Gunther, M., & Neid, M. (2010). Herniation of the brain after conservative treatment of a large congenital skull defect in an infant with Adams–Oliver syndrome. *Journal of Pediatric Surgery*, 45(10), 2064–2067.
- Udayakumaran, S., Mathew, J., & Panikar, D. (2013). Dilemmas and challenges in the management of a neonate with Adams–Oliver syndrome with infected giant aplasia cutis lesion and exsanguination: A case-based update. *Child's Nervous System*, 29(4), 535–541.

How to cite this article: Lukas, M.-L., Harald, G., Sanz, J., Trippel, M., Sabina, G., & Jochen, R. (2022). Cutaneous squamous cell carcinoma in an autosomal-recessive Adams–Oliver syndrome patient with a novel frameshift pathogenic variant in the EOGT gene. *American Journal of Medical Genetics Part A*, 188A:3318–3323. <https://doi.org/10.1002/ajmg.a.62961>