

Mandibular guidance prosthesis: Conventional and innovative approach: A case series

Ranjoy Hazra, Ayush Srivastava, Dinesh Kumar

Department of Prosthodontics and Crown and Bridge, Army Dental Center (Research and Referral), New Delhi, India

Abstract

Surgical resection of the lower jaw due to the presence of a benign or malignant tumor is the most frequent cause of mandibular deviation. Location and extent of the tumor decide the surgical modality of mandibulectomy to be performed. The clinician must wait for an adequate span of time for completion of the healing and acceptance of the osseous graft before considering a definitive prosthesis. During the inceptive healing period, prosthodontic intervention is of utmost priority for preventing the mandibular deviation. A corrective appliance termed “guide flange prosthesis (GFP)” is indicated to limit this clinical manifestation. The basic intention of rehabilitation is to train the mandibular muscles and to re-establish an acceptable occlusal relationship so that the patient can adequately control the opening and closing movements. This case series describes early prosthodontic management of three patients who had undergone hemimandibulectomy, with different techniques of fabrication of a GFP. The three techniques described consist of two conventional methods of fabrication while the third technique is a new innovative approach.

Keywords: Deviation of mandible, guide flange prosthesis, hemimandibulectomy, mandibular guidance therapy

Address for correspondence: Dr. Ranjoy Hazra, Department of Prosthodontics and Crown and Bridge, Army Dental Center (Research and Referral), New Delhi - 110 010, India.
E-mail: rj.razr@gmail.com

Submitted: 10-Jan-2021, **Revised:** 30-Mar-2021, **Accepted:** 03-Apr-2021, **Published:** 28-Apr-2021

INTRODUCTION

Benign or malignant neoplasms which are associated with the lower jaw usually require surgical excision of the pathologic lesion and extensive resection of the lower jaw.^[1,2] Mandibular resection following surgical treatment for neoplastic lesions of the oral cavity leads to numerous complications including altered mandibular movements, disfigurement, difficulty in swallowing, impaired speech and articulation, and deviation of the mandible toward the resected site. The resection of a portion of the mandible without loss of mandibular

continuity is usually not as debilitating as a resection that includes mandibular continuity.^[2] Loss of continuity causes deviation of remaining segment(s) toward the defect and rotation of the mandibular occlusal plane downwards. After a segmental mandibulectomy surgery, masticatory function is compromised because of muscular imbalance due to unilateral muscle removal, altered maxillomandibular relationship, and decreased tooth-to-tooth contacts. Although immediate mandibular reconstruction aims to restore facial symmetry, arch alignment, and stable occlusion, masticatory function

Access this article online	
Quick Response Code:	Website: www.j-ips.org
	DOI: 10.4103/jips.jips_12_21

This is an open access journal, and articles are distributed under the terms of the Creative Commons Attribution-NonCommercial-ShareAlike 4.0 License, which allows others to remix, tweak, and build upon the work non-commercially, as long as appropriate credit is given and the new creations are licensed under the identical terms.

For reprints contact: WKHLRPMedknow_reprints@wolterskluwer.com

How to cite this article: Hazra R, Srivastava A, Kumar D. Mandibular guidance prosthesis: Conventional and innovative approach: A case series. *J Indian Prosthodont Soc* 2021;21:208-14.

usually remains compromised.^[3,4] Loss of the proprioceptive sense of occlusion following mandibular resection leads to the uncoordinated movements of the mandible. The basic rehabilitation goal is to re-educate muscles to re-establish an acceptable occlusal relationship. Guide flange prosthesis (GFP) is a mandibular conventional prosthesis designed for those patients who are able to achieve an appropriate mediolateral maximum intercuspal position of the mandible without much effort but are unable to repeat this position consistently for adequate mastication and also to limit further deviation.^[5]

Cantor and Curtis have classified the mandibular defects into six categories.^[6]

- Class I: Mandibular resection involving alveolar defect with preservation of mandibular continuity
- Class II: Resection defects involve loss of mandibular continuity distal to the canine area
- Class III: Resection defect involves loss up to the mandibular midline region
- Class IV: Resection defect involves the lateral aspect of the mandible, but is augmented to maintain pseudo articulation of the bone and soft tissues in the region of the ascending ramus
- Class V: Resection defect involves the symphysis and parasymphysis region only, augmented to preserve bilateral temporomandibular articulations
- Class VI: Similar to class V, except that the mandibular continuity is not restored.

CASE REPORTS

Case 1

In our 1st case, A 43-year-old jawan reported to the department of prosthodontics after he underwent partial resection of the mandible due to squamous cell carcinoma in the floor of the mouth on the left side.

On examination, the patient had a 5.7 mm deviation of mandible toward the left side from the midline with a mouth opening of 25 mm [Figure 1]. The defect did not cross the midline and hence could be classified as Cantor and Curtis classification-II. The patient was unable to approximate his teeth during mastication and speech with associative symptoms of drooling of saliva and halitosis.

- Primary impressions were made in irreversible hydrocolloid (Zelgan 2002; Dentsply, Delhi) and casts were made in Type III dental stone. (Kalstone; Kalabhai Karson, Mumbai)
- Recording of a tentative maximal intercuspation position and casts are mounted in the same relation [Figure 2]

- A 0.7 mm wire was adapted onto the mandibular cast on the fourth quadrant to form the framework of the prosthesis
- Autopolymerizing polymethylmethacrylate (DPI Clear; Dental Products of India, Mumbai) was adapted over the wire framework which was subsequently removed, finished, and polished [Figure 3]
- The Guide Flange was inserted and the patient was trained to achieve full closure [Figure 4] He was instructed to wear it in all times other than having food and 2 months follow-up showed signs of a satisfactory resolution of the deviation without the guiding prosthesis.

Case 2

In our 2nd case, A 47-year-old serving soldier reported to the Department of Prosthodontics, he underwent partial resection of the mandible due to squamous cell carcinoma of the floor of the mouth on the left side.

On examination, the patient had an 8.5 mm deviation of the mandible and toward the left side from the midline with a mouth opening of 22 mm [Figure 5]. The defect did not cross the midline and hence could be classified as Cantor and Curtis classification-II. The patient was unable to approximate his teeth for chewing food and had difficulty in swallowing.

- Primary impressions were made in irreversible hydrocolloid (Zelgan 2002; Dentsply, Delhi) casts were made in Type III dental stone (Kalstone; Kalabhai Karson, Mumbai)
- Recording of a tentative maximal intercuspation position in the bite registration silicone and casts are mounted in the same relation
- A complete palatal coverage prosthesis is constructed first by autopolymerizing acrylic resin (DPI Clear; Dental Products of India, Mumbai). Adams and embrasure Clasps were placed bilaterally for retention. Moreover, then it is fitted and adjusted in the mouth. The prosthesis is removed and a modeling wax ramp is prepared and added to the desired position. The mandible is manipulated laterally toward the desired position and the occlusal contact noted and the mandible is manipulated to get a definite pathway or trail on the palatal ramp [Figure 6]
- Then, the prosthesis is constructed in heat cure Polymethylmethacrylate resin (DPI Heat Cure; Dental Products of India, Mumbai). in the conventional method [Figure 7]
- The patient was recalled and trained and the finished maxillary prosthesis was inserted [Figure 8 and 9]

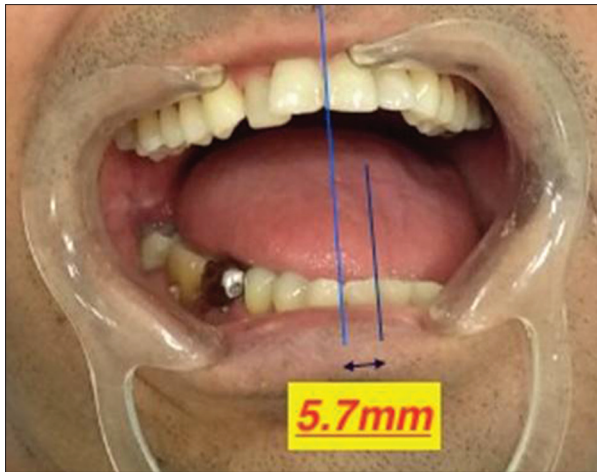

Figure 1: Preoperative deviation



Figure 2: Wire components in casts mounted in tentative maximal intercuspation

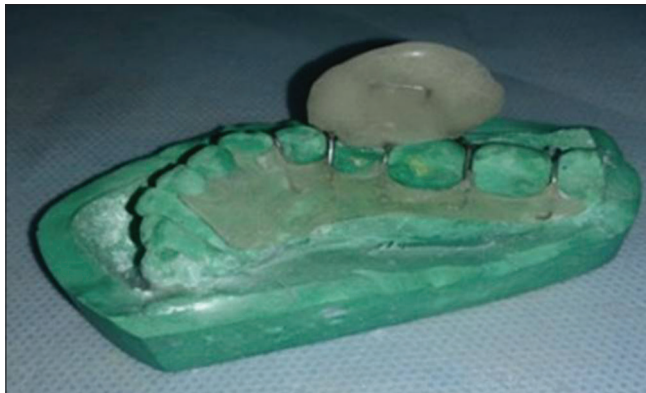

Figure 3: Finished prosthesis

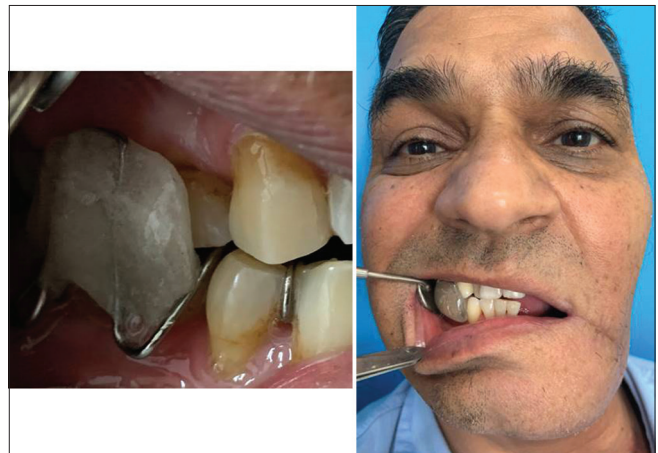


Figure 4: Postoperative intraoral and extraoral view

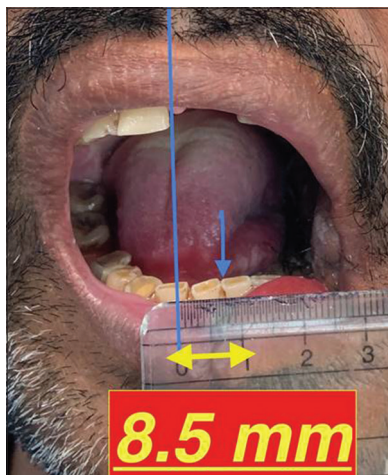

Figure 5: Postoperative deviation

- Three months postinsertion follow-up showed signs of a satisfactory resolution of the deviation.

Case 3

In our 3rd case, a new innovative variant of the GFP was designed in our department.

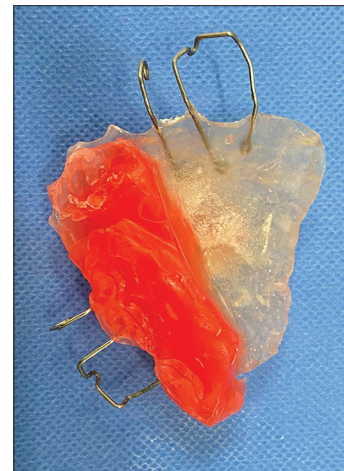


Figure 6: Occlusal registration in wax palatal ramp

A 48-year-old man reported to the department of prosthodontics, after he underwent hemimandibulectomy subsequent to squamous cell carcinoma of the left alveolus.

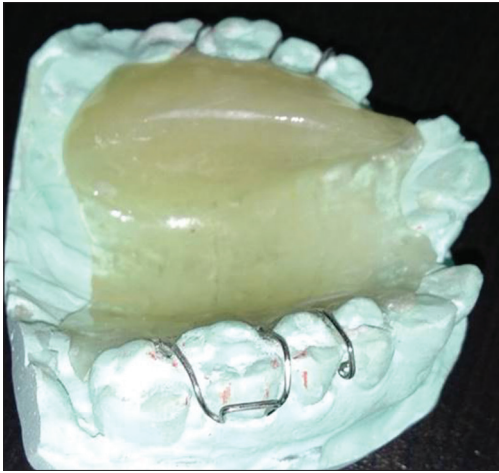

Figure 7: Finished prosthesis

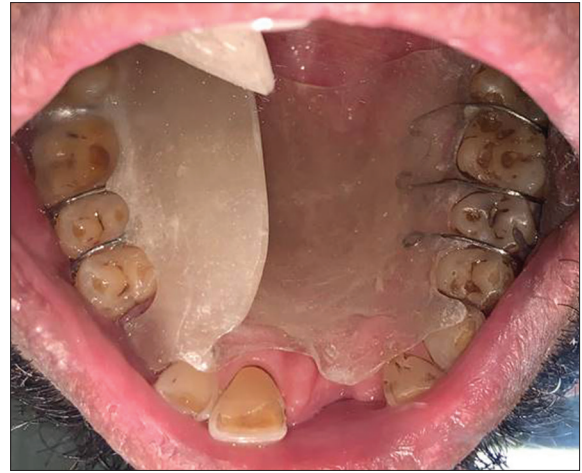

Figure 8: Postoperative intraoral view

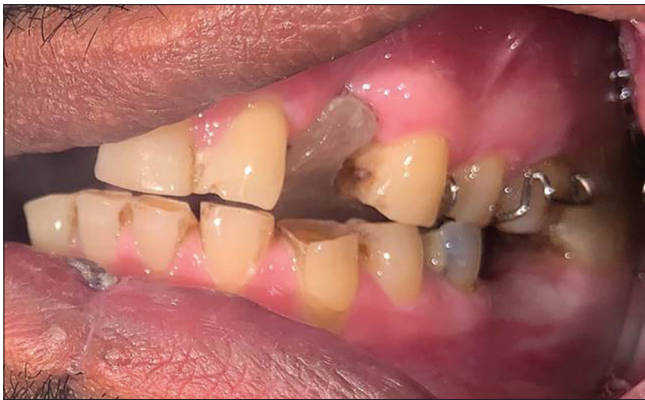

Figure 9: Postoperative occlusion

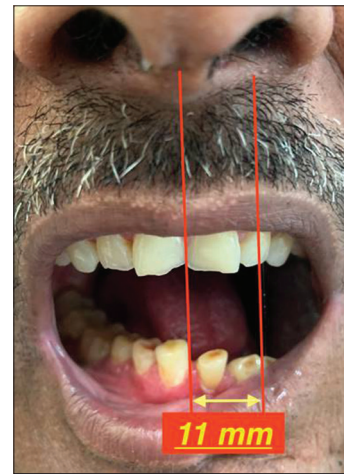

Figure 10: Preoperative deviation

On examination, patient had an 11 mm deviation of the mandible toward the left side from the midline had a mouth opening of 18 mm [Figure 10] Patient was unable to approximate his teeth for chewing food and had severe cosmetic disfigurement.

- First, a corkscrew was given to the patient for 2 weeks to improve the mouth opening and facilitate prosthesis fabrication
- Primary impressions were made in irreversible hydrocolloid (Zelgan 2002; Dentsply, Delhi) and casts were made in Type III dental stone (Kalstone; Kalabhai Karson, Mumbai)
- Recording of a tentative maximal intercuspation position in the bite registration silicone and casts were mounted in the same relation
- A sandwich foil vacuum formed sheet (Durasoft PD 1.8 mm × 125 mm; SCHEU, Germany) with a 0.8 mm hard and a 1 mm soft side was adapted over the mandibular cast in a thermoplastic Biostar press machine. The soft side was toward the tooth surface. The hard side of the sandwich foil has a property of chemically bonding to acrylic [Figures 11 and 12].

This was then trimmed to be kept from the mesial of the canine to the distal of the second molar and equigingivally. Holes were made on the buccal surface of the adapted sheet to increase the mechanical retention with acrylic. This was placed on the mounted cast and articulator was closed. Clear auto polymerizing acrylic (DPI Clear; Dental Products of India, Mumbai) was adapted and built up on the buccal surface of the vacuum sheet and superiorly till the gingival level of the maxillary occluding teeth [Figures 13]

- The prosthesis was then finished, adjusted, and polished following which the patient was trained in inserting and removal the prosthesis and was instructed in wearing it at all times other than eating [Figures 14 and 15]
- Postinsertion 3 month follow-up showed signs of a satisfactory resolution of the deviation.

DISCUSSION

Depending upon the location and extent of the tumor in the mandible, various surgical treatment modalities

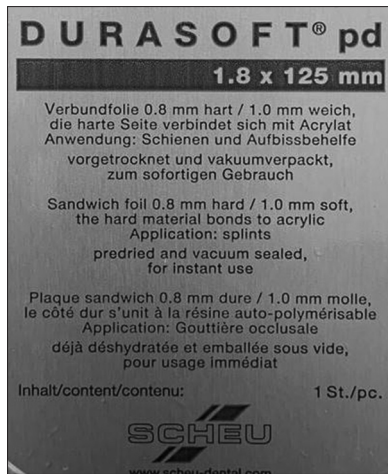

Figure 11: Sandwich foil vacuum formed sheet

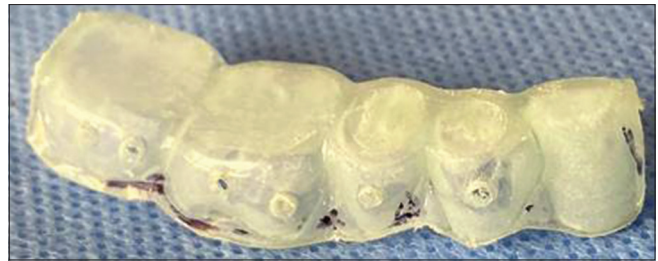


Figure 12: Adapted Durasoft sheet




Figure 13: Acrylic flange added after mounting in tentative intercuspation

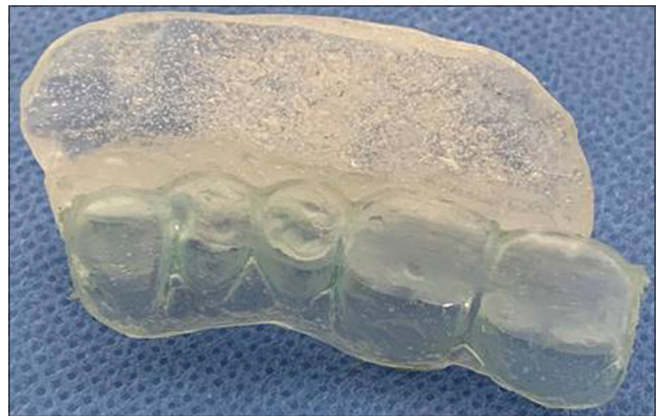

Figure 14: Finished prosthesis

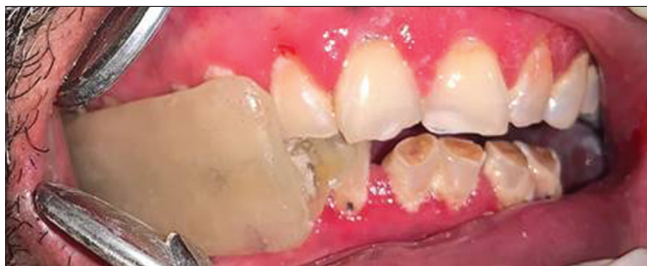

Figure 15: Postoperative intraoral view

such as marginal, segmental, hemi, subtotal, or total mandibulectomy are undertaken.^[2] Mandibular deviation toward the defect side occurs primarily because of the loss of tissue involved in the surgery.^[1] When a segment of the mandible is removed, immediate reconstruction is usually recommended to improve both facial symmetry and masticatory function. Although techniques for reconstructive surgery and prosthodontic rehabilitation have improved, more than 50% of reconstructed head-and-neck cancer

patients still report with impaired mastication.^[7] Recent advancements in facial reconstructive surgery and osseointegrated endosseous dental implants provide a treatment modality that may adequately rehabilitate oral cancer patients so that they can return to a healthy, productive life.^[8]

Although dental implants are the definitive solution for replacing the missing teeth for reconstructed mandibulectomy patients, the clinicians must wait for extensive period of time for completion of healing. During this period early prosthodontic intervention by guide flange serves the purpose of reducing the mandibular deviation, preventing extrusion of the maxillary teeth, and improving the masticatory efficiency.

The GFP can be regarded as a training type of prosthesis. If the patient can successfully repeat the position, the GFP can often be discontinued. Some patients, however, may have to continue indefinitely, and the stress generated to the remaining teeth must then be carefully monitored. All of our cases reported in this article required short-term therapy and so there were less chances of damaging forces in the opposing teeth and hence no stabilization appliance was planned.

The earlier the mandibular guidance therapy is initiated in the course of treatment the more successful the patients

definitive occlusal relationship is restored.^[1] The basic rehabilitation objective, in this case, was to re-educate mandibular muscles to re-establish an acceptable occlusal relationship and to restore the mastication.^[2] The most common treatment modalities for such patients are maxilla mandibular fixation, implant-supported prosthesis, removable mandibular GFP, and palatal-based guidance restorations.^[1]

This mandibular guidance prosthesis consists of a removable partial denture framework with a flange extending 7–10 mm laterally and superiorly on the buccal aspect of the premolars and molars on the nondefect side.^[1] This flange engages the maxillary teeth during mandibular closure, thereby directing the lower jaw to an appropriate intercuspal position.

While in the palatal-based guide flange the index should not extend below the level of the upper teeth.^[9] If it does, it may interfere with speech, deglutition, and other oral functions requiring tongue movements. In selected patients with limited tongue motion, this observance may not be necessary.

The guidance flange may be constructed of cast chrome-cobalt metal or acrylic resin. The material of choice will depend on the existing occlusal relationship of the patient and the need for adjustment. All of our cases were rehabilitated with acrylic resin GFP as all were planned to be used for a shorter duration of time and needed frequent adjustment.

Compared to the conventional GFP, the innovative technique has the following advantages:

- It tends to induce lesser orthodontic forces so a maxillary framework is not usually necessary for protection
- The discomfort caused by the wire components repeatedly interfering on the occlusal table and risk of wire breakage is eliminated in this design
- It is an entirely tooth-supported prosthesis, not placing any additional pressure on the gingiva and abrading it, especially in cases with thin friable mucosa
- The fabrication of the new design was lesser technique sensitive and same-day insertion of the prosthesis was done
- It was a much easier learning curve for the patient to insert and remove the prosthesis as the indentations of the teeth guide its seating
- The lack of any wire component makes it much more aesthetically pleasing for the patient

- It is much more compact than the other conventional designs.

The success of mandibular guidance therapy varies and depends on the nature of the surgical defect, the early initiation of guidance therapy, patient cooperation, and other factors.^[2] Patients with extensive posterior base of the tongue lesions that have resulted in significant soft-tissue resection and have required radiation therapy are frequently unable to achieve useful intercuspal relationships. Mandibular guidance therapy is most successful in patients in whom the resection involves only bony structures with minimal adjacent soft tissues.

The absence of a radical neck dissection and radiation therapy also improves the prognosis for mandibular guidance therapy.

CONCLUSION

Every patient should maintain centric occlusion for mastication, and this may be accomplished by a GFP. When an acceptable intercuspal position is achieved, occlusal equilibration is generally necessary to maintain the mandibular position. The patient should be informed that, as mandibular deviation is reduced, the facial disfigurement on the defect side will be aggravated because the deviation of the mandible toward the surgical side will tend to camouflage the defect. Ensuing the resection, restoration of function is routinely not possible and prolonged disfigurement is unavoidable, but providing a guide flange initially followed by prosthetic rehabilitation, functions such as speech and mastication can be restored to normal physiological limits with the slightest disfigurement.

Declaration of patient consent

The authors certify that they have obtained all appropriate patient consent forms. In the form, the legal guardian has given his consent for images and other clinical information to be reported in the journal. The guardian understands that names and initials will not be published and due efforts will be made to conceal identity, but anonymity cannot be guaranteed.

Financial support and sponsorship

Nil.

Conflicts of interest

There are no conflicts of interest.

REFERENCES

1. Beumer J 3rd, Curtis TA, Marunick MT. Maxillofacial rehabilitation. In: Prosthodontic and Surgical Consideration. St. Louis, Euro America: Ishiyaku; 1996. p. 113-224.

2. Taylor TD. Clinical Maxillofacial Prosthetics. Illunios: Quintessence Publication Co.; 1997. p. 171-88.
3. Marathe AS, Kshirsagar PS. A systematic approach in rehabilitation of hemimandibulectomy: A case report. J Indian Prosthodont Soc 2016;16:208-12.
4. Branchi R, Fancelli V, Desalvador A, Durval E. A Clinical Report for Corrective Mandibular Movement Therapy. Available from: <http://www.odontostudio.net/pub003n.htm>. [Last accessed on 2020 Dec 25].
5. Desjardins RP. Relating examination findings to treatment procedures. In: Laney WR, editor. Maxillofacial Prosthetics. Littleton: PSG Publishing; 1979. p. 69-114.
6. Fonsica RJ, Davis WH. Reconstruction Preprosthetic Oral and Maxillofacial Surgery. 2nd ed. Philadelphia: WB Saunders Company; 1986. p. 1063-7.
7. Curtis DA, Plesh O, Miller AJ, Curtis TA, Sharma A, Schweitzer R, *et al.* A comparison of masticatory function in patients with or without reconstruction of the mandible. Head Neck 1997;19:287-96.
8. Maroulakos G, Nagy WW, Ahmed A, Artopoulou II. Prosthetic rehabilitation following lateral resection of the mandible with a long cantilever implant-supported fixed prosthesis: A 3-year clinical report. J Prosthet Dent 2017;118:678-85.
9. Kadain P. Prosthodontic rehabilitation of a hemimandibulectomy patient. J Indian Prosthodont Soc 2020;20 Suppl S1:26-7.