

Ultrasound biomicroscopic findings of the iridocorneal angle in live healthy and glaucomatous dogs

Takashi HASEGAWA^{1)*}, Manabu KAWATA¹⁾ and Mitsuharu OTA²⁾

¹⁾Laboratory of Advanced Diagnosis and Treatment, Department of Advanced Clinical Medicine, Course of Veterinary Sciences, Graduate School of Life and Environmental Sciences, Osaka Prefecture University, North 1–58, Rinku-orai, Izumisano, Osaka 598–8531, Japan

²⁾Animal Eye Center, Ichigahora 3–101, Nagakute, Aichi 480–1131, Japan

(Received 25 May 2015/Accepted 13 July 2015/Published online in J-STAGE 24 July 2015)

ABSTRACT. By using ultrasound biomicroscopy (UBM), the cross-sectional structures of the entire iridocorneal angle (ICA) which are unable to assess with gonioscopic examination were evaluated objectively and quantitatively in live healthy and glaucomatous dogs. The ICAs of normotensive eyes in healthy dogs with normal open angle (NOR), a predisposition to primary closed angle glaucoma (PCAG) (PREDIS) and suffering from unilateral PCAG (UNI), as well as the ICAs of hypertensive eyes with acute and chronic PCAG (ACG and CRG), were assessed. The opening of the ciliary cleft in PREDIS was smaller than that in NOR. In UNI, the opening and area of the ciliary cleft were significantly decreased compared with those of NOR and PREDIS. ACG had widespread structural abnormalities including marked decrease in the ciliary cleft and scleral venous plexus, and a thinner sclera than those in normotensive eyes, whereas the ICA collapsed in CRG with the thinnest sclera. Medical therapy-responsive glaucomatous cases had wider ciliary cleft and scleral venous plexus than unresponsive ones. These findings suggest that the ciliary cleft and scleral venous plexus of the ICA are key structures contributing to not only the pathophysiology of canine glaucoma but also the responsiveness to medical therapy in glaucomatous eyes, and cross-sectional entire structures of the ICA should be evaluated quantitatively with UBM when diagnosing and managing canine glaucoma.

KEY WORDS: canine iridocorneal angle, glaucoma, healthy, microstructures, ultrasound biomicroscopy

doi: 10.1292/jvms.15-0311; *J. Vet. Med. Sci.* 77(12): 1625–1631, 2015

Canine glaucoma is associated with structural abnormalities of the iridocorneal angle (ICA) including pectinate ligament dysplasia and narrow/closed angles; these abnormalities are evaluated using a gonioscope and slitlamp biomicroscopy in clinical practice [4, 8, 16, 18, 21]. A gonioscopic examination has some problems: for instance, it is a subjective test, and cannot evaluate abnormalities in the deep ICA and quantify its structural abnormalities [2, 11, 15, 18, 20, 23, 24]. Veterinary ophthalmologists use a grading system that was proposed by Ekesten *et al.* [7] to classify the angle as open, narrow or closed, although the system is still defective, such as an imperfect quantitative system, that is, semi-quantitative evaluation of the ICA. Hence, a simpler procedure is needed to evaluate abnormalities of the entire ICA objectively and quantitatively for the diagnosis and management of canine glaucoma.

Ultrasound biomicroscopy (UBM), which can provide cross-sectional images of ocular tissues at low-power microscopic resolution by using high-frequency ultrasound

probes, has been introduced into veterinary ophthalmology and applied to basic and clinical research for evaluation of the ocular anterior segment including the ICA [1–3, 5, 6, 8, 10, 13, 14, 18]. This advanced imaging technique is expected to be clinically useful for clarifying unknown pathophysiology, selecting accurate management approaches and improving the prognosis in ocular disorders [1–3, 5, 6, 8, 10, 18]. However, there have been few reports dealing with comparison of microstructures of the ICA between live healthy and glaucomatous dogs [18]. In addition, antemortem structural and quantitative information on the abnormalities of canine ICA is still obscure. The aim of this study is to evaluate cross-sectional structures of the entire ICA and quantify its microstructures of live healthy and glaucomatous dogs via UBM examination.

MATERIALS AND METHODS

Animals: Two hundred and eighty-seven dogs that were presented at Osaka Prefecture University Veterinary Medical Center (OPUVMC), Animal Eye Center and Izumi Animal Hospital for examination and treatment of ophthalmic, medical and surgical diseases were used in this study. All the dogs underwent a general ophthalmologic examination including gonioscopy with a Goldmann two-mirror lens and slitlamp biomicroscopy to confirm ocular conditions. Laboratory examinations including blood works, urinalysis and diagnostic imagings were also carried out to exclude systemic disorders, if necessary. Animals suspected of having secondary glaucoma, which was indicated by their history and ophthal-

*CORRESPONDENCE TO: HASEGAWA, T., Laboratory of Advanced Diagnosis and Treatment, Department of Advanced Clinical Medicine, Course of Veterinary Sciences, Graduate School of Life and Environmental Sciences, Osaka Prefecture University, North 1–58, Rinku-orai, Izumisano, Osaka 598–8531, Japan.
e-mail: hsst56@vet.osakafu-u.ac.jp

©2015 The Japanese Society of Veterinary Science

This is an open-access article distributed under the terms of the Creative Commons Attribution Non-Commercial No Derivatives (by-nc-nd) License <<http://creativecommons.org/licenses/by-nc-nd/3.0/>>.

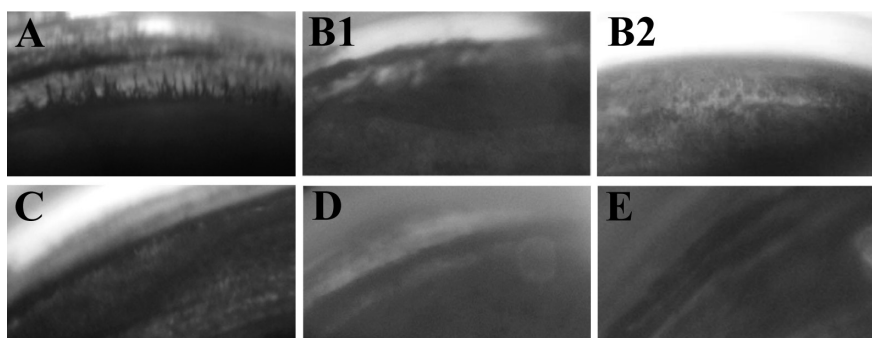


Fig. 1. Typical canine iridocorneal angles in the five ocular groups examined in this study: (A) wide open angle in a normal normotensive eye; (B1) open angle with goniodysgenesis in a primary closed angle glaucoma (PCAG)-predisposed normotensive eye; (B2) narrow angle with severe goniodysgenesis in a PCAG-predisposed normotensive eye; (C) very narrow angle in a normotensive fellow eye of unilateral PCAG; (D) closed angle in an acute glaucomatous eye; and (E) closed angle in a chronic glaucomatous eye.

mic conditions, such as the presence of uveitis, cataract, lens luxation, ocular neoplasia and infections including systemic diseases, were excluded from the study.

The examined eyes were divided into 5 groups as follows:

(i) normal ocular group (NOR) including 336 normotensive eyes of 168 dogs (57 Beagle, 18 Miniature Dachshund, 15 Shih Tzu, 12 Pembroke Welsh Corgi, 11 Chihuahua, 9 mongrel and Labrador Retriever, 8 Yorkshire Terrier, 6 Papillon, 5 Pomeranian, 4 Shetland Sheepdog, 3 Cavalier King Charles Spaniel and Miniature Schnauzer, 2 Bernese Mountain Dog, Doberman Pinscher and Pug, and 1 Afghan Hound and French Bulldog) with normal open angle (Fig. 1A), normal intraocular pressure (IOP) of 10–25 mmHg and no ocular disorders up to the date of UBM examination;

(ii) primary closed angle glaucoma (PCAG)-predisposed ocular group (PREDIS) including 116 normotensive eyes of 58 dogs (18 Shiba, 14 American Cocker Spaniel, 13 Toy Poodle, 7 Golden Retriever, 2 Maltese Terrier, and 1 Akita, English Springer Spaniel, Flat-Coated Retriever and Newfoundland, which were recognized as breeds with PCAG [9, 18, 19]) with some kind of ICA abnormalities containing goniodysgenesis and open to narrow angles (Figs. 1-B1 and 2), normal IOP of 10–25 mmHg and no ocular disorders up to the date of UBM examination;

(iii) normotensive fellow ocular group in unilateral PCAG (UNI) including 22 normotensive eyes of 22 dogs suffering from unilateral PCAG (6 Shiba, 5 Shih Tzu, 3 American Cocker Spaniel, 2 Flat-Coated Retriever, Miniature Dachshund and mongrel, and 1 Chihuahua and Welsh Terrier), which had narrow angle with moderate to severe ICA abnormalities (Fig. 1C), normal IOP of 10–25 mmHg and no clinical signs of glaucoma up to the date of UBM examination;

(iv) acute glaucomatous eye group (ACG) including 19 hypertensive non-buphthalmic eyes of 19 dogs (6 Shiba, 3 Miniature Dachshund and Shih Tzu, 2 American Cocker Spaniel, and 1 Chihuahua, English Setter, Flat-Coated Retriever, mongrel and Welsh Terrier) with closed angle (Fig. 1D), IOP of over 25 mmHg (31–58 mmHg) and signs of

acute glaucoma, such as tenderness about the head and eyes, ocular pain (blepharospasm), serous discharge, episcleral congestion (red eye), corneal edema, dilated pupil and mild depression of optic nerve head [21], in which their clinical signs were observed less than 24 hr after the onset of symptoms on the date of UBM examination;

(v) chronic glaucomatous eye group (CRG) including 20 hypertensive buphthalmic eyes of 20 dogs (6 Miniature Dachshund, 5 American Cocker Spaniel, 3 Shiba, 2 mongrel and Shih Tzu, and 1 Flat-Coated Retriever and Welsh Terrier) with closed angle (Fig. 1E), IOP of over 25 mmHg (42–78 mmHg) and signs of chronic glaucoma, such as globe enlargement with or without Descemet streaks, mydriasis, tapetal hyperreflectivity with vascular attenuation, optic nerve cupping and blindness [21] on the date of UBM examination.

Examination procedure: Ultrasonographic images of the ICA were obtained with UBM by using a UD-1000 with 40-MHz probes (Tomey Corp., Nagoya, Japan) with background room illuminance of 1,200–1,300 lux in a general examination room. Non-anesthetized or non-sedated dogs were examined using manual restraints in sternal recumbency. When sedation was required, it was achieved following a protocol described previously [14]; these animals were assessed in a lateral recumbent position. UBM examination was also performed by a procedure described previously [14], and the following 7 parameters were evaluated with the measurement software of the UBM: (i) SLD [the distance between Schwalbe's line (the borderline between the cornea and sclera) and the anterior lens capsule] (Fig. 2B); (ii) the width of the ciliary cleft (CCW), measured from the superior surface of the root of the iris to the inner surface of the sclera on a perpendicular line (Fig. 2B); (iii) the area of the ciliary cleft (CCA), measured as the area surrounded by the width of the ciliary cleft, the line of the inner scleral side of the ciliary cleft from the inner surface of the sclera to the angle recess and the line of the superior side of the root of the iris from the angle recess to the superior surface of the root of

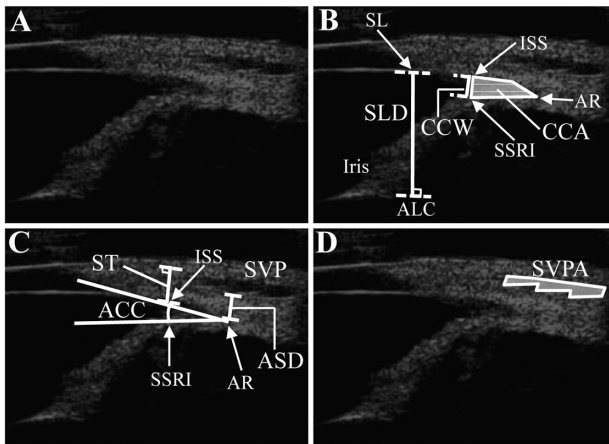


Fig. 2. Typical canine images of ultrasound biomicroscopy (UBM) on the iridocorneal angle (ICA, A) and the same images of the ICA with indication of UBM parameters evaluated in this study (B to D). The following 7 parameters were evaluated with the measurement software included in the UD-1000: (i) SLD [the distance between Schwalbe's line (SL), the borderline between the cornea and sclera] and the anterior lens capsule (ALC)]; (ii) the width of the ciliary cleft (CCW), measured from the superior surface of the root of the iris (SSRI) to the inner surface of the sclera (ISS) on a perpendicular line; (iii) the area of the ciliary cleft (CCA), measured as the area surrounded by the width of the ciliary cleft, the line of the inner scleral side of the ciliary cleft from the inner surface of the sclera to the angle recess (AR) and the line of the superior side of the root of the iris from the angle recess to the superior surface of the root of the iris; (iv) the angle of the ciliary cleft (ACC), the angle of the inner surface of the sclera to the angle recess and the superior surface of the root of the iris to the angle recess; (v) the scleral thickness at the position of the width of the ciliary cleft (ST), as measured from the inner surface of the sclera on a perpendicular line to the outer surface of the sclera; (vi) the minimum distance between the angle recess and the scleral venous plexus (SVP) [ASD]; and (vii) the total area of the scleral venous plexus (SVPA) on the UBM image of the ICA.

the iris (Fig. 2B); (iv) the angle of the ciliary cleft (ACC), the angle of the inner surface of the sclera to the angle recess and the superior surface of the root of the iris to the angle recess (Fig. 2C); (v) the scleral thickness at the position of the width of the ciliary cleft (ST), as measured from the inner surface of the sclera on a perpendicular line to the outer surface of the sclera (Fig. 2C); (vi) the minimum distance between the angle recess and the scleral venous plexus (ASD, Fig. 2C); and (vii) the total area of the scleral venous plexus (SVPA) on the UBM image of the ICA (Fig. 2D). Raw UBM measurements were detected from all obtained images in the examined dogs. In order to exclude differences of raw UBM values caused by taking different breeds with varied ocular size, the UBM measurements except for the angle of the ciliary cleft were corrected by using the ratio with SLD on the distance/length, that is, CCW/SLD , ST/SLD and ASD/SLD , or SLD^2 on the area, that is, CCA/SLD^2 and $SVPA/SLD^2$ [14]. The mean of UBM values was calculated to obtain a UBM measurement of each parameter of the ICA in an individual eye.

Nineteen ACG cases received first medical therapy including an intravenous injection of 20% mannitol (Yoshindo, Toyama, Japan) at a dose of 1.5 g/kg on the first admission and administrations of 0.005% latanoprost (Xalatan[®], Pfizer, Tokyo, Japan), 1% dorzolamide hydrochloride (Trusopt[®], Santen Pharmaceutical Co., LTD., Osaka, Japan) and 0.5% timolol maleate (Timoptol[®], Santen Pharmaceutical Co., LTD., Osaka, Japan) on OPUVMC. Then, the responsiveness to the therapy, which means keeping reduction in normal IOP of under 25 mmHg, and the seven parameters of the ICA structures described above were evaluated simultaneously.

Statistical analysis: To exclude unexpected bias effects of pooling UBM measurements of right and left eyes, the average UBM values calculated from both eyes were used as UBM measurements in NOR and PREDIS [22]. Comparison between ocular groups was performed using non-repeated measurement one-way analysis of variance (ANOVA) or Kruskal-Wallis H test followed by Scheffe's test (Statcel 2nd ed.; OMS Publishing Co., Tokyo, Japan). A *P*-value less than 0.05 was considered to be statistically significant.

Reference ranges of UBM measurements in NOR and PREDIS were calculated by iterative truncation method with correction (Usui's method) using STSS/EXCEL Ver. 8.8 (<http://www.chiringi.or.jp/soft/soft.html>) [25].

RESULTS

As shown in Fig. 3, cross-sectional microstructures of the entire ICA could be observed clearly by UBM examination in all ocular groups. Abnormal structures of the ICA were not found in NOR. The width of the ciliary cleft of PREDIS was narrower than that of NOR. It was difficult to identify the width of the ciliary cleft of UNI, and the area of the ciliary cleft of UNI would be smaller than those of NOR and PREDIS. The ciliary cleft was almost collapsed, and it was very difficult to detect the width and area of the ciliary cleft in ACG. The ciliary cleft was completely collapsed in CRG. The scleral venous plexus could be observed in UBM images of most ACG, although it was not found in CRG. The basal iris of the anterior part of the ciliary cleft was slightly inserted into the sclera of ACG, whereas it was inserted into the sclera in CRG.

The data of each UBM parameter are shown in Fig. 4, and Table 1 shows reference ranges of each UBM measurement in NOR and PREDIS. In PREDIS, UBM measurements of the corrected width of the ciliary cleft and the angle of the ciliary cleft were significantly lower than those of NOR. In UNI, significantly low values were found for the corrected width and area of the ciliary cleft, and the angle of the ciliary cleft, when compared with those in NOR and PREDIS. In ACG, the corrected width and area of the ciliary cleft, the total area of the scleral venous plexus and the scleral thickness, and the angle of the ciliary cleft were significantly smaller than those of NOR and PREDIS. The corrected width and area of the ciliary cleft, the total area of the scleral venous plexus and the scleral thickness in ACG were also significantly decreased compared with those of UNI. In CRG, the anatomical structures of the sclerociliary cleft in-

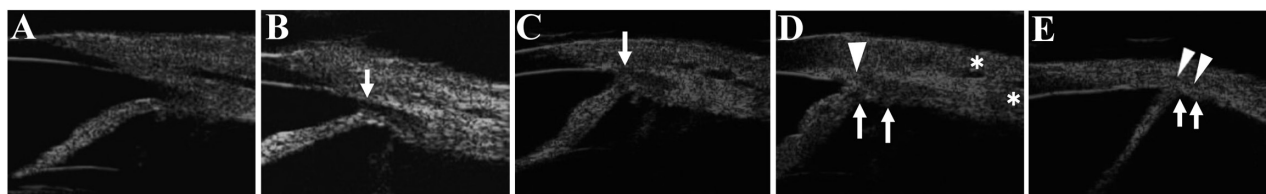


Fig. 3. Typical images of the iridocorneal angle (ICA) detected by ultrasound biomicroscopy (UBM) in (A) normotensive eyes with no ocular disorders, intraocular pressure (IOP) of 10–25 mmHg and normal open angle (NOR), (B) normotensive eyes of primary closed angle glaucoma (PCAG)-predisposed dogs with no ocular disorders, IOP of 10–25 mmHg, open to narrow angle and some kind of abnormalities of the ICA (PREDIS), (C) normotensive fellow eyes of dogs suffering from unilateral PCAG, which had IOP of 10–25 mmHg, narrow angle with moderate to severe abnormalities of the ICA and no clinical signs of glaucoma (UNI), (D) hypertensive non-buphthalmic eyes with acute PCAG having IOP of over 25 mmHg, closed angle and clinical signs of acute glaucoma (ACG) and (E) hypertensive buphthalmic eyes with chronic PCAG having IOP of over 25 mmHg, closed angle and clinical signs of chronic glaucoma (CRG). Abnormal structures of the ICA were not found in NOR. The width of the ciliary cleft (CCW) of PREDIS was narrower than that of NOR (an arrow in B). The area of the ciliary cleft (CCA) of UNI was smaller than those of NOR and PREDIS, and significantly narrow CCW was observed in the case of UNI (an arrow in C). The ciliary cleft was almost or completely collapsed, and it was difficult or impossible to detect CCW and CCA in ACG and CRG (arrows in D and E). Although the scleral venous plexus could be observed in UBM images of ACG (asterisks in D), it was not found in a dog with CRG. The basal iris of the anterior part of the ciliary cleft would be slightly inserted into the sclera of ACG (an arrowhead in D). The sclera became thin, and the basal iris was inserted into the sclera in CRG (arrowheads in E).

Table 1. Reference ranges of corrected ultrasound biomicroscopic values in healthy dogs

	Corrected CCW (CCW/SLD)	ACC (°)	Corrected CCA (CCA/SLD ²)	Corrected ASD (ASD/SLD)	Corrected SVPA (SVPA/SLD ²)	Corrected ST (ST/SLD)
NOR (n=168)	0.064–0.149	8.3–22.2	0.019–0.042	0.110–0.317	0.014–0.058	0.253–0.384
PREDIS (n=58)	0.028–0.131	4.8–19.0	0.006–0.043	0.118–0.302	0.012–0.052	0.224–0.339

NOR; normotensive eyes in normal open angle, PREDIS; normotensive eyes in predisposition to primary closed angle glaucoma. CCW; the width of the ciliary cleft, SLD; the distance between Schwalbe's line (the borderline of the cornea and sclera) and the anterior lens capsule, ACC; the angle of the ciliary cleft, CCA; the area of the ciliary cleft, ASD; the minimum distance between the angle recess and the scleral venous plexus, SVPA; the total area of the scleral venous plexus on the ultrasound biomicroscopic image of the iridocorneal angle, ST; the scleral thickness at the CCW. Data are presented as lower and upper limits of reference ranges.

cluding the scleral venous plexus completely collapsed, and all UBM values except the corrected scleral thickness were zero or undetectable. There were significant differences for the corrected width and area of the ciliary cleft, and the total area of the scleral venous plexus between CRG and NOR, PREDIS and UNI. The angle of the ciliary cleft in CRG was significantly lower than those of NOR and PREDIS. The corrected scleral thickness of CRG was significantly smaller than those of NOR, PREDIS, UNI and ACG, as a result of the buphthalmos.

Nineteen cases received first medical therapy on OPU-VMC, and the responsiveness to the therapy and the ICA structures were evaluated simultaneously. Twelve dogs showing no response to the first medical therapy had significant decrease of the corrected width and area of the ciliary cleft, and the total area of the scleral venous plexus, compared with 7 cases responding to the therapy (Fig. 5).

DISCUSSION

Glaucoma is a leading cause of blindness in dogs, and there are no perfect therapies for prevention of vision impairment in glaucomatous dogs [16, 26]. This may be attributable to inadequate assessment of entire structural changes within the ICA and lack of a predictive system of canine

glaucoma. Hence, anatomical structures of the ICA were evaluated by UBM for comparison of its cross-sectional microstructures in healthy and glaucomatous live dogs. UBM clearly revealed abnormalities deep within the ICA, especially on the ciliary cleft and the scleral venous plexus, in not only glaucomatous dogs but also in healthy canines with a predisposition to PCAG, which were anatomical changes similar to those described in previous reports [4, 6, 8, 10, 16, 18]. In PREDIS, UBM values of the width and angle of the ciliary cleft were significantly lower than those of NOR, although there were no significant differences in terms of the area of the ciliary cleft, the minimum distance between the angle recess and the scleral venous plexus, the total area of the scleral venous plexus and the scleral thickness between PREDIS and NOR, indicating that the pathway of the aqueous humor in the PCAG-predisposed dogs would function as well as that in dogs with a normal open angle, despite the presence of structural abnormalities of the angular aperture (the opening of the ciliary cleft).

Significant differences were found for UBM measurements related to the ciliary cleft between non-glaucomatous healthy dogs and animals with unilateral glaucoma (Fig. 4). The width, angle and area of the ciliary cleft of UNI were decreased significantly compared with those of NOR and PREDIS, and the 75th percentile values of the corrected

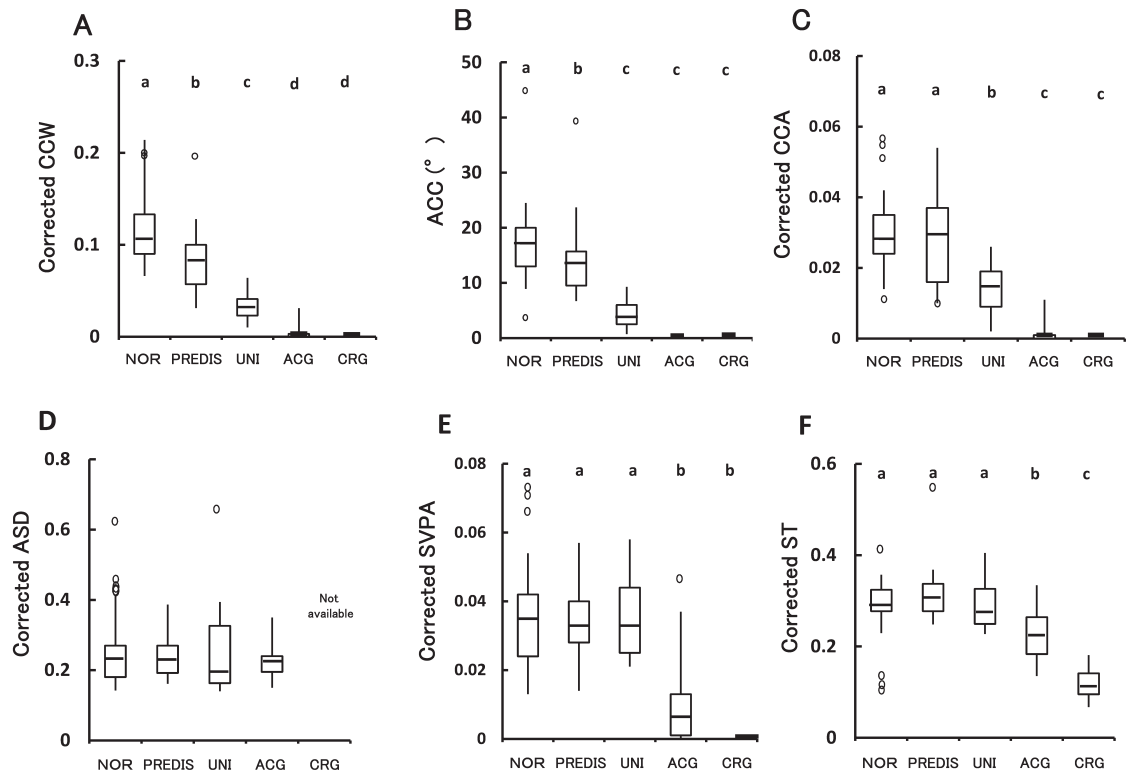


Fig. 4. Box-plots of each ultrasound biomicroscopic measurement in the five ocular groups: (A) corrected width of the ciliary cleft (CCW) [CCW/SLD (the distance/length of Schwalbe's line to the anterior lenticular capsule)]; (B) the angle of the ciliary cleft (ACC); (C) corrected area of the ciliary cleft (CCA) [CCA/SLD²]; (D) corrected minimum distance/length from the angle recess to the scleral venous plexus (ASD) [ASD/SLD]; (E) corrected total area of the scleral venous plexus on the ultrasound biomicroscopic image of the iridocorneal angle (SVPA) [SVPA/SLD²]; (F) corrected scleral thickness (ST) [ST/SLD]. The boxes define the 25th and 75th percentiles, with the median value indicated by a horizontal bar. The whiskers delineate the 5th and 95th percentiles, with outliers indicated as open circles. Not available means no detectable data due to complete collapse of the ciliary cleft and/or the scleral venous plexus. Different letters/alphabets indicate statistically significant differences between groups ($P < 0.05$).

width (0.041) and angle (6.0°) of the ciliary cleft in UNI were smaller than the lower limits of their reference ranges in NOR. These quantitative results suggest unilateral PCAG has decreased capacity of aqueous outflow from the anterior chamber in the eyes. However, the aqueous outflow might be able to retain a normal level, because there were no differences in the minimum distance between the angle recess and the scleral venous plexus, the total area of the scleral venous plexus and the scleral thickness between UNI and healthy normotensive eye groups (NOR and PREDIS). Therefore, aqueous humor production should be restricted to decrease the aqueous outflow from the anterior chamber, thereby maintaining the balance of the aqueous inflow and outflow in the ciliary cleft to prevent onset of glaucoma. This proposal has already been accepted as prophylactic therapy in the management of canine glaucoma [17, 18, 26]. Prophylactic medical treatment from the time of confirmed or presumed glaucoma in the first eye is helpful for delaying or preventing the onset of the disease in the second normotensive eye, although the median delay was about 22 months, less than 2 years [17]. Greater delay of the onset of glaucoma

may be provided by early start of prophylactic treatment in dogs with a predisposition to PCAG or unilateral type. UBM evaluation of the ICA is helpful for providing objective criteria regarding the start of prophylactic treatment in dogs with a risk of glaucoma onset. Judging from our results presented here, glaucomatous prophylaxis is suggested for cases in which the UBM value of the corrected width, angle or area of the ciliary cleft decreases and is less than the lower limit of the reference range in dogs with normotensive eyes with open angle (NOR).

In glaucomatous dogs, UBM also revealed ICA abnormalities that were available for management of canine glaucoma. There were UBM parameters associated with responsiveness to medical therapies (Fig. 5), namely, the opening of the ciliary cleft and the total area of the scleral venous plexus. Both the opening of the ciliary cleft (width and area of the ciliary cleft) and the total area of the scleral venous plexus would represent valuable information for prediction of the responsiveness to medical therapies, because the opening of the ciliary cleft and the scleral venous plexus in cases that were responsive to the medical therapies were significantly

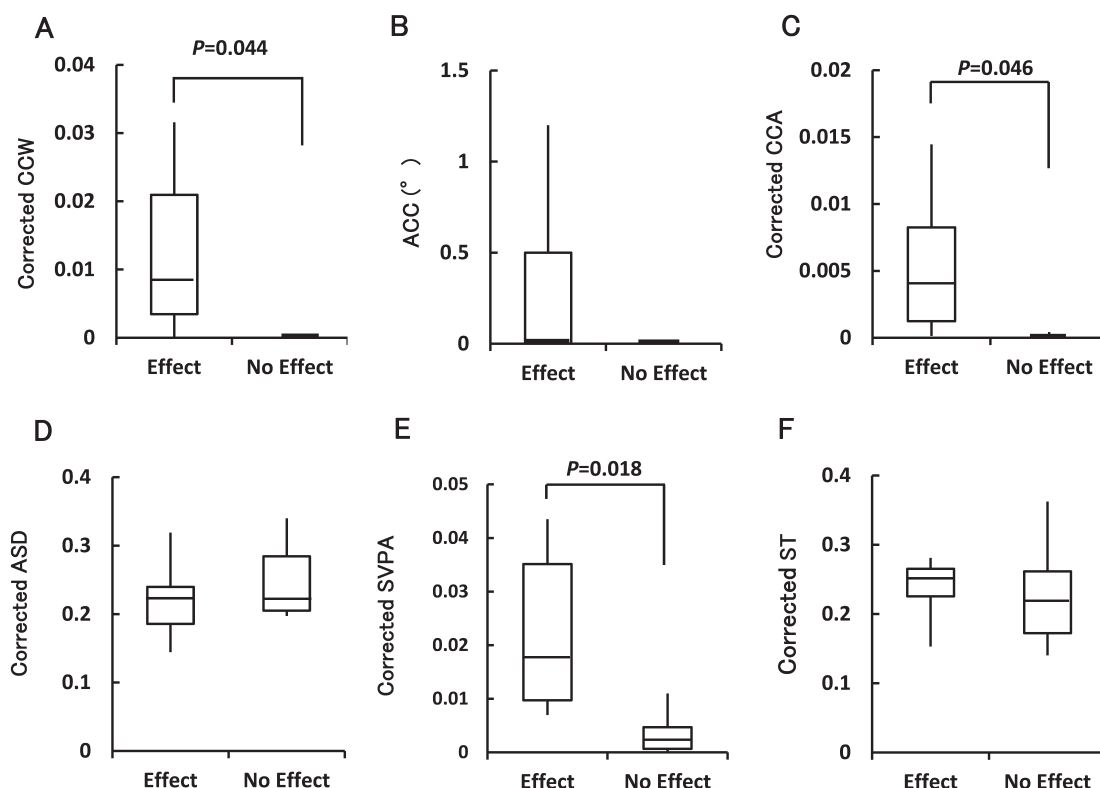


Fig. 5. Box-plots of each ultrasound biomicroscopic measurement in 7 dogs responding to first medical therapy (Effect) and 12 dogs showing no response to the therapy (No Effect): (A) corrected width of the ciliary cleft (CCW) [CCW/SLD (the distance/length of Schwalbe's line to the anterior lenticular capsule)]; (B) the angle of the ciliary cleft (ACC); (C) corrected area of the ciliary cleft (CCA) [CCA/SLD²]; (D) corrected minimum distance/length from the angle recess to the scleral venous plexus (ASD) [ASD/SLD]; (E) corrected total area of the scleral venous plexus on the ultrasound biomicroscopic image of the iridocorneal angle (SVPA) [SVPA/SLD²]; (F) corrected scleral thickness (ST) [ST/SLD]. The boxes define the 25th and 75th percentiles, with the median value indicated by a horizontal bar. The whiskers delineate the 5th and 95th percentiles. Data of ASD in the group of no effect were calculated from 3 cases, because it could not be detected in the other 9 cases due to complete collapse of the ciliary cleft and/or the scleral venous plexus.

larger than in dogs that were unresponsive (Fig. 5). These findings suggest that the presence of observable ciliary cleft and scleral venous plexus is important for maintaining aqueous outflow from the anterior chamber in the eye. These UBM parameters are useful for prediction of the effects of medical therapies with ocular hypotensive agents. The opening of the ciliary cleft and the scleral venous plexus are key structures contributing to not only the pathophysiology of canine glaucoma [4, 8, 16, 18, 21] but also the responsiveness to medical therapy in glaucomatous eyes.

The minimum distance between the angle recess and the scleral venous plexus was only measured in 10 of 19 hypertensive eyes in ACG, because it could not be detected in the nine eyes with loss of the angle recess due to complete collapse of the ciliary cleft. No significant differences of the corrected minimum distance between the angle recess and the scleral venous plexus, and the scleral thickness were detected between ACG and the other ocular groups, such as NOR, PREDIS and UNI (Fig. 4), suggesting that the minimum distance between the angle recess and the scleral

venous plexus may only contribute to the aqueous outflow resistance in canine eyes, but may not be involved in the causes of increased IOP. Meanwhile, there were statistically significant differences in the corrected scleral thickness between ACG and CRG (Fig. 4). These abnormalities might be associated with structural changes, such as scleral stretching or buphthalmos, induced by increased IOP in the long term [12, 16, 18].

Although gonioscopic examination is an essential diagnostic tool as a conventional procedure for assessing abnormalities of the ICA in the field of veterinary ophthalmology, objective and quantitative information of the ICA is needed to establish new diagnostic criteria for improving strategies of glaucomatous managements in animals. Since UBM can provide objective and quantitative data of entire ICA abnormalities which are unable to assess with classical gonioscopic examination, UBM examination should be more widely applied for detecting quantitative abnormalities of the ICA in dogs, especially in glaucoma-predisposed dogs or cases suffering from unilateral glaucoma. The potential

for UBM examinations to contribute to analysis of glaucomatous mechanisms and provide advanced diagnosis and management of glaucoma warrants further investigation in canine patients.

ACKNOWLEDGMENT. The authors thank Dr. Hitoshi Nakanishi, Izumi Animal Hospital, for his assistance in gathering clinical data on glaucomatous dogs.

REFERENCES

- Aubin, M. L., Powell, C. C., Gionfriddo, J. R. and Fails, A. D. 2003. Ultrasound biomicroscopy of the feline anterior segment. *Vet. Ophthalmol.* **6**: 15–17. [Medline] [CrossRef]
- Bentley, E., Miller, P. E. and Diehl, K. A. 2003. Use of high-resolution ultrasound as a diagnostic tool in veterinary ophthalmology. *J. Am. Vet. Med. Assoc.* **223**: 1617–1622. [Medline] [CrossRef]
- Bentley, E., Miller, P. E. and Diehl, K. A. 2005. Evaluation of intra- and interobserver reliability and image reproducibility to assess usefulness of high-resolution ultrasonography for measurement of anterior segment structures of canine eyes. *Am. J. Vet. Res.* **66**: 1775–1779. [Medline] [CrossRef]
- Brooks, D. E. 1990. Glaucoma in the dog and cat. *Vet. Clin. North Am. Small Anim. Pract.* **20**: 775–797. [Medline] [CrossRef]
- Crumley, W., Gionfriddo, J. R. and Radecki, S. V. 2009. Relationship of the iridocorneal angle, as measured using ultrasound biomicroscopy, with post-operative increases in intraocular pressure post-phacoemulsification in dogs. *Vet. Ophthalmol.* **12**: 22–27. [Medline] [CrossRef]
- Dietrich, U. M. 2007. Ophthalmic examination and diagnostics. Part 3: Diagnostic ultrasonography. pp. 507–519. *In: Veterinary Ophthalmology*, 4th ed. (Gelatt, K. N. ed.), Blackwell Publishing, Ames.
- Ekesten, B. and Narfström, K. 1991. Correlation of morphologic features of the iridocorneal angle to intraocular pressure in Samoyeds. *Am. J. Vet. Res.* **52**: 1875–1878. [Medline]
- Gelatt, K. N., Brooks, D. E. and Källberg, M. E. 2007. The canine glaucomas. pp. 753–811. *In: Veterinary Ophthalmology*, 4th ed. (Gelatt, K. N. ed.), Blackwell Publishing, Ames.
- Genetics Committee of the American College of Veterinary Ophthalmologists 2009. *In: Ocular Disorders; Presumed to be inherited in purebred dogs*, 5th ed. American College of Veterinary Ophthalmologists. Meridian. ISBN # 0-96 35163-2-0.
- Gibson, T. E., Roberts, S. M., Severin, G. A., Steyn, P. F. and Wrigley, R. H. 1998. Comparison of gonioscopy and ultrasound biomicroscopy for evaluating the iridocorneal angle in dogs. *J. Am. Vet. Med. Assoc.* **213**: 635–638. [Medline]
- Kashiwagi, K., Tokunaga, T., Iwase, A., Yamamoto, T. and Tsukahara, S. 2005. Agreement between peripheral anterior chamber depth evaluation using the van Herick technique and angle width evaluation using the Shaffer system in Japanese. *Jpn. J. Ophthalmol.* **49**: 134–136. [Medline] [CrossRef]
- Kato, K., Sasaki, N., Matsunaga, S., Mochizuki, M., Nishimura, R. and Ogawa, H. 2006. Possible association of glaucoma with pectinate ligament dysplasia and narrowing of the iridocorneal angle in Shiba Inu dogs in Japan. *Vet. Ophthalmol.* **9**: 71–75. [Medline] [CrossRef]
- Kawata, M., Tsukizawa, H., Nakayama, M. and Hasegawa, T. 2010. Rectification of width and area of the ciliary cleft in dogs. *J. Vet. Med. Sci.* **72**: 533–537. [Medline] [CrossRef]
- Kawata, M. and Hasegawa, T. 2013. Evaluation of the distance between Schwalbe's line and the anterior lens capsule as a parameter for the correction of ultrasound biomicroscopic values of the canine iridocorneal angle. *Vet. Ophthalmol.* **16**: 169–174. [Medline] [CrossRef]
- Lister, A. 1950. Discussion on gonioscopy. *Proc. R. Soc. Med.* **43**: 1024–1025. [Medline]
- Martin, C. L., Carmichael, K. P., Vygantas, K. R. and Whitley, R. D. 2010. Glaucoma. pp. 337–368. *In: Ophthalmic Disease in Veterinary Medicine*, Manson Publishing, London.
- Miller, P. E., Schmidt, G. M., Vainisi, S. J., Swanson, J. F. and Herrmann, M. K. 2000. The efficacy of topical prophylactic antiglaucoma therapy in primary closed angle glaucoma in dogs: a multicenter clinical trial. *J. Am. Anim. Hosp. Assoc.* **36**: 431–438. [Medline] [CrossRef]
- Miller, P. E. 2008. The glaucomas. pp. 230–257. *In: Slatter's Fundamentals of Veterinary Ophthalmology*, 4th ed. (Maggs, D. J., Miller, P. E. and Ofri, R. eds.), Saunders Elsevier, St. Louis.
- Miller, P. E. 2008. Breed predisposition to eye disorders. pp. 442–454. *In: Slatter's Fundamentals of Veterinary Ophthalmology*, 4th ed. (Maggs, D. J., Miller, P. E. and Ofri, R. eds.), Saunders Elsevier, St. Louis.
- Narayanaswamy, A., Vijaya, L., Shantha, B., Baskaran, M., Sathidevi, A. V. and Baluswamy, S. 2004. Anterior chamber angle assessment using gonioscopy and ultrasound biomicroscopy. *Jpn. J. Ophthalmol.* **48**: 44–49. [Medline] [CrossRef]
- Pickett, J. P. 2004. Glaucoma. pp. 516–517. *In: The 5-Minutes Veterinary Consult Canine and Feline*, 3rd ed. (Tilley, L. P. and Smith, Jr F. W. K. eds.), Lippincott Williams & Wilkins, Philadelphia.
- Ray, W. A. and O'Day, D. M. 1985. Statistical analysis of multi-eye data in ophthalmic research. *Invest. Ophthalmol. Vis. Sci.* **26**: 1186–1188. [Medline]
- Richardson, K. T. 1972. Functional status of the glaucoma patient. *Invest. Ophthalmol.* **11**: 103–107. [Medline]
- Schirmer, K. E. 1967. Gonioscopy and artefacts. *Br. J. Ophthalmol.* **51**: 50–53. [Medline] [CrossRef]
- Shiga, S., Koyanagi, I., Ohsaga, J., Ichiyama, S. and Kannagi, R. 1999. [Clinical reference values for laboratory hematology tests calculated using the iterative truncation method with correction: Part 2, Reference values for white blood cell (WBC) count, WBC differential including segmented neutrophil, band neutrophil, lymphocyte, monocyte, eosinophil, basophil, platelet count and mean platelet volume]. *Rinsho Byori* **47**: 281–288 (in Japanese). [Medline]
- Willis, A. M. 2004. Ocular hypotensive drugs. *Vet. Clin. North Am. Small Anim. Pract.* **34**: 755–776. [Medline] [CrossRef]