

Osteoid osteoma of the pisiform: A case report



Gokhan Kaynak^{a,*}, Mehmet Fatih Guven^a, Ozan Ali Erdal^a, Huseyin Botanlioglu^a,
Muharrem Babacan^a, Sergulen Dervisoglu^b

^a Department of Orthopedics and Traumatology, Istanbul University Cerrahpasa Medical Faculty, Istanbul, Turkey

^b Department of Pathology, Istanbul University Cerrahpasa Medical Faculty, Istanbul, Turkey

ARTICLE INFO

Article history:

Received 16 May 2014

Received in revised form

1 September 2014

Accepted 24 December 2014

Available online 21 August 2016

Keywords:

Osteoid osteoma

Pisiform

ABSTRACT

Background: Osteoid osteoma is an uncommon benign bone-forming tumor of the musculoskeletal system but it is the most common primary bone tumor of the carpal region. However, only seven cases of its pisiform involvement have been described.

Case: We present a 19 year-old male patient with osteoid osteoma of the pisiform which initially could not be detected in any diagnostic study for long standing wrist pain. The patient was treated with excision and curettage. In 1 year of follow-up, the patient was asymptomatic without recurrence.

Conclusion: In cases with long standing ulnar wrist pain, one should consider osteoid osteoma of the pisiform in differential diagnosis. If an OO is suspected, thin slice CT scan in initial evaluation would be valuable in preventing the patient from misdiagnosis or delay in diagnosis.

© 2016 Turkish Association of Orthopaedics and Traumatology. Publishing services by Elsevier B.V. This is an open access article under the CC BY-NC-ND license (<http://creativecommons.org/licenses/by-nc-nd/4.0/>).

Osteoid osteoma (OO), first described by Jaffe HL, et al in 1935,^{1–3} is an uncommon benign bone-forming tumor of the musculoskeletal system with uncertain etiology.^{1,4} It accounts for 3%–4% of all primary bone tumors,^{1,5} and 10%–14% of all benign bone tumors.^{1,6} OO most commonly involves long bones,^{2,4,6,7} especially proximal femur and tibia.^{5,8} It is seen predominantly in the second and third decades of life,^{5,6,8} especially males.^{1,8} Male:female ratio is 2:1.^{2,5,6} OO constitutes 25% of all primary bone tumors of the carpal region,^{2,9} although only 19%–31% of all OO cases involve the upper extremity.⁵ 10% of all OO involves the hand,¹ often metacarpals and proximal phalanges.² Although quite rare (2%),¹ common sites of OO in the carpal region are scaphoid and capitate bones.^{1,2,9} Seven cases and six articles was reported in literature about OO of the pisiform.^{1,3,9–12}

We present case of OO of the pisiform which has diagnosis as late as 8 months.

* Corresponding author. Cerrahpasa Tıp Fakültesi Ortopedi ve Travmatoloji Anabilim Dalı Kocamustafapasa, Fatih, Istanbul 34098, Turkey.

E-mail addresses: kaynak95@yahoo.com (G. Kaynak), mfguven@yahoo.com (M.F. Guven), ozanaerdal@yahoo.com (O.A. Erdal), huseyinbotanlioglu@yahoo.com (H. Botanlioglu), muharrem.babacan@gmail.com (M. Babacan), serguled@yahoo.com (S. Dervisoglu).

Peer review under responsibility of Turkish Association of Orthopaedics and Traumatology.

<http://dx.doi.org/10.1016/j.aott.2016.07.005>

1017-995X/© 2016 Turkish Association of Orthopaedics and Traumatology. Publishing services by Elsevier B.V. This is an open access article under the CC BY-NC-ND license (<http://creativecommons.org/licenses/by-nc-nd/4.0/>).

Case report

19 year-old right-handed male was admitted to our institution with constant pain and decreased grip strength in his left wrist. Pain had continued for a few months and worsened after participating sports about 1 month before his admission. Symptoms aggravated at night and were partially relieved with non-steroid anti-inflammatory drugs (NSAIDs).

Pain was localized over ulnar styloid and pisiform bone by palpation. Initial X-rays did not detect any abnormality. After 1 month of rest, cold compression and NSAIDs, his complaints were the same and became resistant to NSAIDs. Magnetic Resonance Imaging (MRI) was ordered and signal intensity increase in triangular fibrocartilage complex (TFCC) along with medullary edema of the pisiform was reported. Although conservative treatment was started, the patient did not come back for 8 months. Then, he was admitted again to our institution because of unrelieved pain and progressively decreased ability to use his wrist in daily activities. Anteroposterior, lateral and 30° of supination X-rays (Fig. 1) and Computed Tomography (CT) with 3-D reconstruction (Fig. 2) revealed a sclerotic lesion surrounded by lucent area in dorsal and radial part of the pisiform suggestive of OO. MRI of the wrist revealed regression of medullary edema of the pisiform and normal appearing TFCC. Open excision and curettage of the lesion was decided.

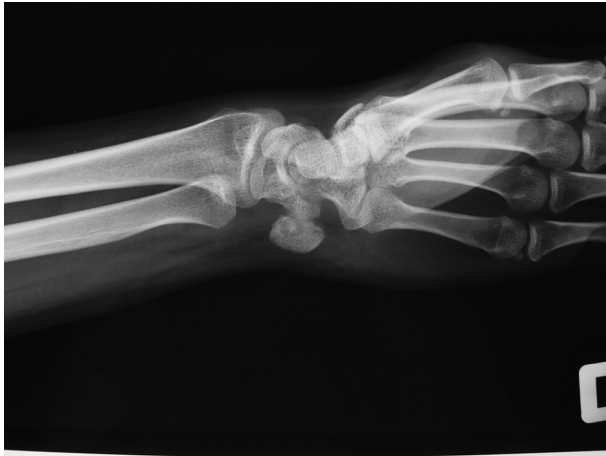

Fig. 1. 30° of supination view of the pisiform before the operation.

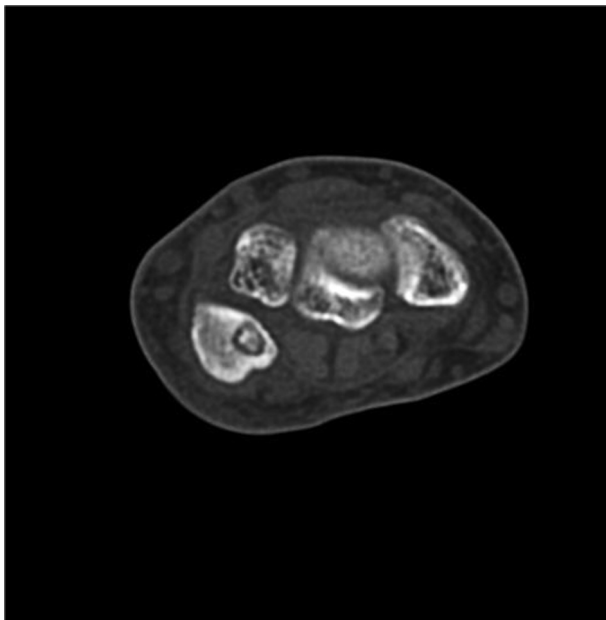


Fig. 2. Transverse section of the pisiform in CT scan before the operation.

The operation was done through a 3 cm longitudinal incision centralized over pisiform. Through the cortical window about 1 cm, a sclerotic mass of 0.5 cm diameter was easily detected and extracted under fluoroscopic control.

Radiographies after the operation confirmed total removal of the mass. Histology of the excised tissue was consistent with

osteoid osteoma. After receiving approval from the Ethical Committee of our institution, we decided to report this case.

Shortly after the initial postoperative period, symptoms of the patient dramatically improved and he was satisfied with the operation and resumed recreational activities. During 1 year follow-up, there was not any recurrence of symptoms or any related complications.

Discussion

The most common manifestation of OO is nocturnal pain which is usually improved with salicylate or NSAID therapy.^{1,4,6,13} Local tenderness, soft tissue swelling, warm skin, and resting pain may be present at the time of initial evaluation.^{1,8}

Depending on location of the lesion, OO involvement of carpal bones produces nonspecific symptoms like exertional pain, loss of grip strength and reduced range of motion that mimics synovitis,^{1,14} tenosynovitis,^{1,2} triangular fibrocartilage complex injuries,⁵ or arthritis.^{5,14} In addition to these physical examination findings history of a wrist injury may ease misleading diagnosis.^{1,3,15} Nonspecific symptoms and this rare location frequently cause 12–24 months overdue diagnosis,^{5,10,14,15} misdiagnosis,^{5,16} and insufficient or unnecessary treatment.^{5,16,17}

Imaging studies are essential in diagnosing OO. Radiographies are frequently not helpful and up to 25% of cases can be missed because of bony superposition in the carpal region or its nonspecific appearance.^{1,3,5,16}; although it is the major imaging modality for other localizations.⁸ But particularly for the pisiform, 30° of supination relative to the X-ray beam with the ulnar side of the hand on the table can clearly visualize an OO.¹⁸ MRI is the most sensitive imaging modality,¹ while CT scan is the most specific.^{1,3} In MRI, OO is seen as a low signal intensity area with a centrally localized signal increase of nidus.¹ The typical CT scan of OO is composed of sclerosis surrounding a lucent nidus with variable degrees of central mineralization.^{1,2} Thin slice CT is particularly important because thicker slices may result in missing small lesions.¹ Bone scan is also a valuable diagnostic modality helping to localize the lesion with a non-specific hot spot.¹

There are a few treatment choices. NSAID treatment alone can be a definitive treatment after 3–4 years of therapy.^{2,5,8} Its success rates, however, are lower than excision⁵ and it is not recommended if the lesion is intra-articular.¹⁴ Radiofrequency ablation therapy is an alternative but it is not recommended in carpal region because of utilized thermal ablation that affects an area of 1 cm diameter and proximity of neurovascular structures.^{1,8} Open surgeries such as curettage or en bloc resection are more common alternatives,^{2,17} and called the gold standard treatment for OO.⁵

OO of the pisiform was reported in other articles before (Table 1). It was reported first by Kernohan J, et al in 1985. They presented two cases treated with excision of the pisiform.¹⁰ One

Table 1
Reported cases of OO involving pisiform bone.

Article	Age/sex of cases	Diagnostic method	Method of treatment	Follow-up period	Complication/recurrence
Kernohan J, et al ¹⁰ (1985)	48/Female, 60/male	X-ray	En bloc resection of pisiform	14 years, N/A for male patient	None
Miller RF, et al ¹¹ (1990)	17/Male	Excision	Excision	2 years	None
Murray PM, et al ⁹ (1999)	22/Male	N/A	N/A	N/A	N/A
Wiesner W, et al ¹² (2007)	33/Female	MRI, MRA	N/A (patient refused operation)	N/A	N/A
Thomsen L, et al ¹ (2011)	21/Male	X-ray, MRI, CT	Excision	6 weeks	None
Papachristos IV, et al ³ (2014)	13/Female	X-ray, CT	En bloc resection of pisiform	15 years	None
Erdal OA, et al (2014)	19/Male	X-ray, MRI, CT	Excision	1 year	None

N/A: not available or not applicable; MRI: Magnetic resonance imaging; MRA: Magnetic resonance angiography; CT: computerized tomography.

case was diagnosed with X-ray changes after delay of three years. The other case was operated five times for different diagnoses like synovitis or neuroma until excision of the pisiform which relieved his complaints. Later, Miller RF, et al reported excellent results of one case treated with complete excision of the pisiform.¹¹ Diagnosis was delayed by 6 months until pathology report, after excision of the pisiform because of long standing pain and worsening of radiographic appearance of the bone. Initially, case was misdiagnosed as a pisiform fracture. In their study to determine the prevalence of primary bone tumors of the carpus, Murray PM, et al mentioned a case of OO of the pisiform in 44 primary tumors of carpal bones out of 26,800 bone neoplasms in their clinic.⁹ Wiesner W, et al reported for the first time the light bulb sign in MR angiography of an osteoid osteoma in the pisiform, which would help to avoid confusion of an osteoid osteoma with vascular lesions like aneurysms in MR angiography.¹² Since the patient refused any operation, diagnosis was not verified by pathology. In 2011, Thomsen L, et al reported excellent results of a man 6 weeks after excision of nidus in the pisiform.¹ They did not report any delay in diagnosis. Recently, Papachristos IV, et al presented the youngest case ever with an OO of the pisiform.³ There was not any delay in diagnosis. In our 19-year-old case, diagnosis was delayed for 8 months because of nonspecific findings in X-rays, MRI and CT scans. OO was suggested by repeating the same imaging modalities 8 months later. Patient was treated with excision of the nidus. Results were excellent at the end of 1 year follow-up.

In conclusion, in cases with long standing ulnar wrist pain, one should consider osteoid osteoma of the pisiform in differential diagnosis. If an OO is suspected, thin slice CT scan in initial evaluation would be valuable in preventing the patient from misdiagnosis or delay in diagnosis.

References

1. Thomsen L, Dumontier C. Osteoid osteoma of the pisiform: a case report. *Chir Main.* 2011;30:76–79.
2. Shaikhi AA, Hebert-Davies J, Moser T, Maillot E, Danino AM. Osteoid osteoma of the capitate: a case report. *ePlasty.* 2009;9:351–356.3.
3. Papachristos IV, Pasparakis D. Osteoid osteoma of the pisiform. Can it exist in a child? *J Pediatr Orthop B.* 2014;23:172–175.
4. Weber KL, Morrey BF. Osteoid osteoma of the elbow: a diagnostic challenge. *J Bone Jt Surg Am.* 1999;81:1111–1119.
5. Lamo-Espinosa JM, Gonzalez A, Amillo S. Osteoid osteoma mimicking triangular fibrocartilage complex injury. *Case Rep Surg.* 2012:1–4.
6. Beck SE, Schwab JH, Rosenthal DI, Rosenberg AE, Grottkau BE. Metachronous osteoid osteoma of the tibia and the T7 vertebral body. *J Bone Jt Surg Am.* 2011;93:1–5.
7. Girard J, Basten K, Kreitner KF, Degreif J. Osteoma osteoid of the trapezoid bone: a case-report and review of the literature. *Chir Main.* 2005;24:35–38.
8. Heck RK, Toy PC. Benign bone tumors and nonneoplastic conditions simulating bone tumors. In: Canale ST, Beaty JH, eds. *Campbell's Operative Orthopaedics.* 12th ed. 1. Philadelphia: Elsevier; 2013:859–864.
9. Murray PM, Berger RA, Inwards CY. Primary neoplasms of the carpal region. *J Hand Surg Am.* 1999;24:1008–1013.
10. Kernohan J, Beacon JP, Dakin PK, Helal B. Osteoid osteoma of the pisiform. *J Hand Surg Br.* 1985;3:411–414.
11. Miller RF, Fox Jr AL. Osteoid osteoma of the pisiform. *Iowa Orthop J.* 1990;10:124–126.
12. Wiesner W, Wischer T, Steinbrich W. Medullary osteoidosteoma of the os pisiform. *Prax (Bern 1994).* 2007;96:1209–1213.
13. Chotel F, Francka F, Solla F, et al. Osteoid osteoma transformation into osteoblastoma: fact or fiction. *Orthop Traumatol Surg Res.* 2012;98S:98–104.
14. Bhardwaj P, Sharma C, Sabapathy SR. Synovitis of the wrist joint caused by an intraarticular perforation of an osteoid osteoma. *Indian J Orthop.* 2012;46:599–601.
15. Themistocleous GS, Chloros GD, Benetos IS, Efstathopoulos DG, Gerostathopoulos NE, Soucacos PN. Osteoid osteoma of the upper extremity. A diagnostic challenge. *Chir Main.* 2006;25:69–76.
16. Kalb K, Schlor U, Meier M, Schmitt R, Lanz U. Osteoid osteoma of the hand and wrist. *Handchir Mikrochir Plast Chir.* 2004;36:405–410.
17. Marcuzzi A, Acciaro AL, Landi A. Osteoid osteoma of the hand and wrist. *J Hand Surg Br.* 2002;27:440–443.
18. Saffar PH, Pigeau I. Radiographic imaging of the hand, wrist and elbow. In: Berger RA, Weiss APC, eds. *Hand Surgery.* 1st ed. Philadelphia: Lippincott Williams and Wilkins; 2004:82–83.