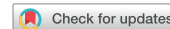
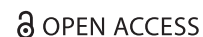
CASE REPORT



Closed extensor tendon rupture following neck fracture of the fifth metacarpal (Boxer's fracture): a case report

Sacha Lardenoye, Pascal F. W. Hannemann and Jan A. Ten Bosch

Department of Trauma Surgery, Maastricht University Medical Center, Maastricht, the Netherlands

ABSTRACT

Boxer's fractures are common injuries. This report describes a case of a rupture of both small finger extensor tendons, following a closed neck fracture of the fifth metacarpal bone. This complication has not been reported before and emphasizes the importance of good clinical examination to rule out additional damage.

ARTICLE HISTORY

Received 24 December 2019
Accepted 19 January 2020

KEYWORDS

Hand; metacarpal fracture;
extensor tendon rupture;
Boxer's fracture



Introduction

Metacarpal neck fractures represent 40% of all hand fractures. Fifth metacarpal neck fractures (Boxer's fractures) account for 25% of all metacarpal fractures [1,2]. A fracture at the neck of the metacarpal bone is usually the result of the energy caused by axial forces to a clenched fist. This typically results in apex dorsal deformity mainly due to forces of the interosseous muscles. The majority of fractures are closed injuries and do not require surgical treatment [2,3]. Neck fractures of the fifth metacarpal with apex dorsal angulation as high as 70° can be treated conservatively with good functional results [4]. Poor cosmetic result and malunion with shortening and with subsequent minimal extension lag are known complications. Literature shows no statistically significant differences in functional outcome between conservative and surgical treatment of displaced fractures of neck of the fifth metacarpal bone in terms of grip strength or range of motion at the metacarpophalangeal joint (MCP) [5]. In open fifth metacarpal neck fractures and other open direct clenched-fist traumas (for instance fight bites), extensor tendon injury is described [6]. However, as far as we know, no literature is available describing extensor tendon rupture following closed metacarpal neck fractures. This report describes one case of a complete rupture of the extensor tendons following a closed fifth metacarpal neck fracture.

Case report

A 26-year-old man presented at the emergency department (ED) of our university hospital 4 days after hitting a wall with his dominant right clenched-fist. Physical examination showed diffuse swelling on the ulnar side of the hand- and loss of knuckle prominence (Figure 1(a)). The skin was intact. Rotational deformity was excluded by inspection during flexion at the MCP and proximal interphalangeal (PIP) joints. Surprisingly, the patient was not able to fully extend the small finger in the MCP, PIP and distal interphalangeal (DIP) joint (Figure 1(b)). Rupture of the small finger extensor tendons was suspected.

The initial standard AP and oblique X-rays of the hand showed a comminuted neck fracture of the fifth metacarpal bone (Figure 2) with slight apex dorsal angulation. Subsequent dynamic ultrasound examination showed local hematoma with suggestion of a total rupture of the fifth extensor digitorum communis (EDC) and the extensor digiti minimi (EDM) tendons just proximal to the MCP joint, known as zone V (Figure 3). A splint was applied at the ED and 3 days later the patient was admitted to the operating theater for exploration and primary tendon repair. Complete rupture of both the EDC and the EDM was confirmed (Figure 4). Tendon repair suturing was performed using a 4-strand core suture technique. The fracture was treated conservatively. A volar splint in

CONTACT Sacha Lardenoye  s.lardenoye@mumc.nl  Department of Trauma Surgery, Maastricht University Medical Center, PO Box 5800, 6206 AZ Maastricht, the Netherlands

© 2020 The Author(s). Published by Informa UK Limited, trading as Taylor & Francis Group.

This is an Open Access article distributed under the terms of the Creative Commons Attribution-NonCommercial License (<http://creativecommons.org/licenses/by-nc/4.0/>), which permits unrestricted non-commercial use, distribution, and reproduction in any medium, provided the original work is properly cited.

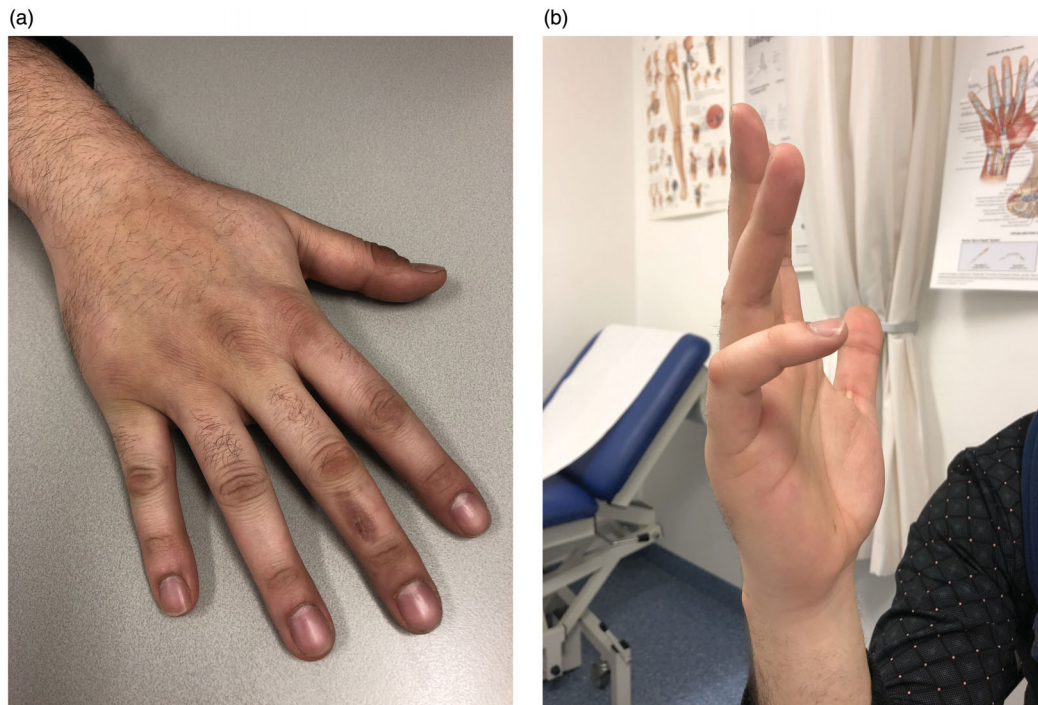


Figure 1. (a) Photo at the emergency department showing loss of knuckle contour. (b) Photo at the emergency department showing extension lag.

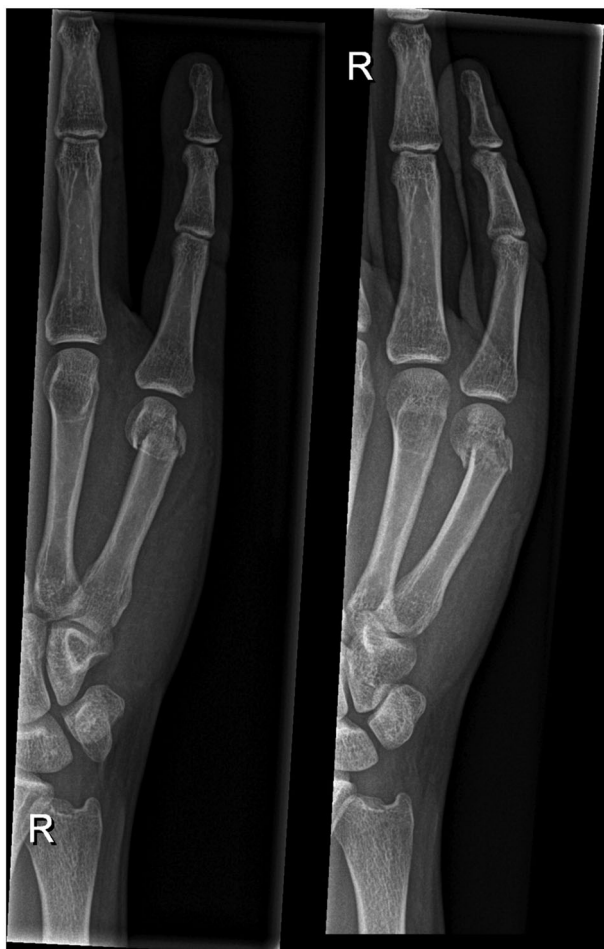

Figure 2. Standard AP (left) and oblique X-ray (right) of the hand.

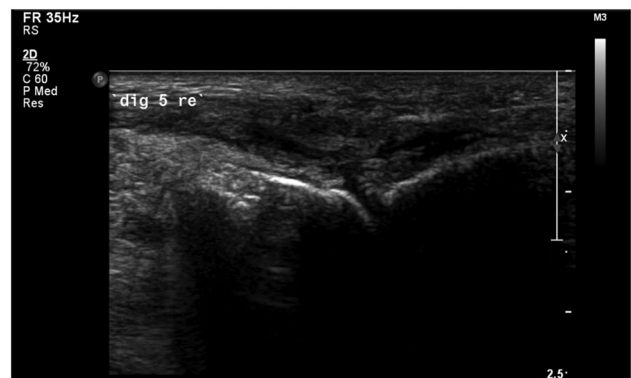

Figure 3. Ultrasound demonstrating a rupture of the tendon.

intrinsic plus position was applied for 2 weeks. After 2 weeks the plaster was removed and the patient was referred to hand therapy. Three months after surgery, the patient showed excellent functional outcome with full range of active flexion and extension of the MCP, PIP and DIP joint (Figure 5) and normal grip strength. The patient has returned to work and sports. There were no complications.

Discussion

Boxer's fractures are relatively common, 13.6 per 100,000 person-years in the United States [1].

Most of them are isolated closed injuries and show good functional outcomes when treated non-operatively. In open fractures or fight bites, extensor tendon

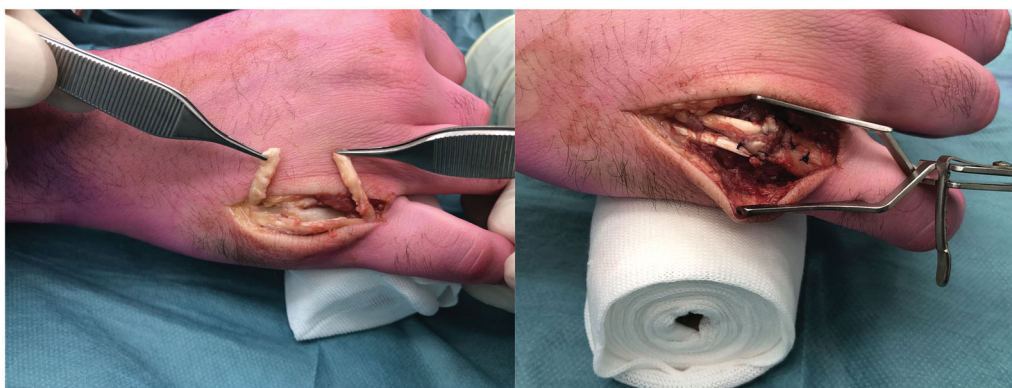

Figure 4. Intraoperative photograph demonstrating a rupture of the tendons (left photo) and sutured tendons (right photo).

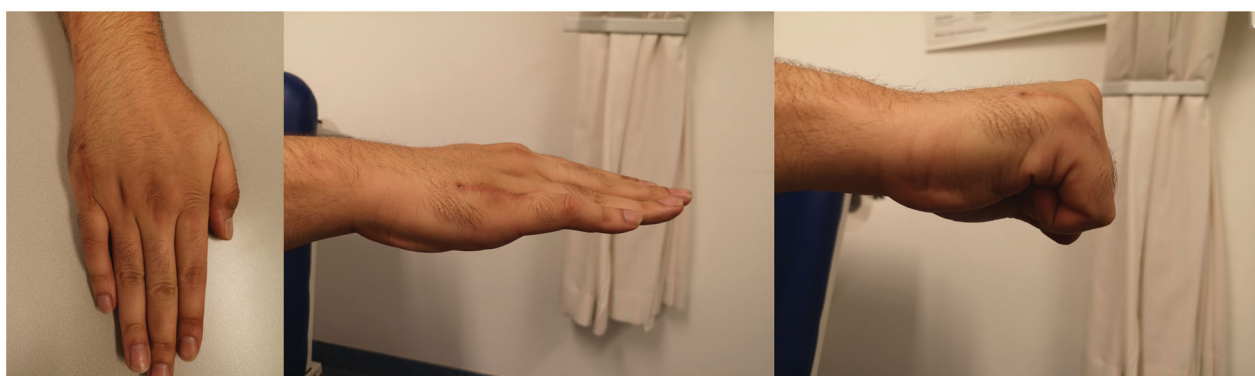

Figure 5. Photos at three months follow up, AP view (left) extension (middle) and flexion (right).

laceration or subluxation caused by lacerations of the radial sagittal band is common [7]. Closed rupture of extensor tendons is previously reported in patients with risk factors, such as rheumatoid arthritis or osteoarthritis. However, these ruptures normally take place at the myotendinous junction level in zone 8 [8–10]. To our knowledge, case reports concerning extensor tendon rupture in a closed fifth metacarpal neck fracture (zone V) has not been described in literature so far. The traumatic rupture as described in this report might have been occurred due to the direct mechanism where the tendon gets caught between the bone and the wall or by the sharp bone edge due to the forced apex dorsal angulation of the metacarpal neck.

Closed fifth metacarpal neck fractures are common and benign injuries, but without systematic clinical examination injured structures can be missed. Darwish et al. performed a prospective case series to find the frequency of missed injuries in the hand [11]. Eight hundred and sixty patients attended the ED, of which 360 with closed hand injuries. The proportion of missed injuries was 7.5% among patients with closed hand injury. In those with a closed injury the most common missed structure was the extensor tendon (66.7%). Mahdavian et al. analyzed hand and wrist

injuries and related liability claims in the Netherlands between 1993 and 2007 [12]. Data were collected from 743 hand and wrist claims of which 64.9% concerned treatment at the ED. One of the most common causes for filing a claim was a missed diagnosis (33.8%), mostly due to improper examination in minor injuries.

This case report addresses the need, even in a common benign fracture, to perform a systematic clinical examination and when in doubt, ultrasound can be of great diagnostic benefit.

Statement of informed consent

Written informed consent was obtained from the patient for publishing photos and case report.

Disclosure statement

The authors declare that they have no conflict of interest.

References

- [1] Malik S, Rosenberg N. Fifth metacarpal fractures (Boxer's Fracture). Treasure Island (FL): StatPearls Publishing; 2019.

- [2] Shuang-Le Zong MD, Gang Zhao MD, Li-Xin Su MD, et al. Treatments for the fifth metacarpal neck fractures. A network meta-analysis of randomized controlled trials. *Medicine*. 2016;95(11):e3059.
- [3] Sletten IN, Hellund JC, Olsen B, et al. Conservative treatment has comparable outcome with bouquet pinning of little finger metacarpal neck fractures: a multicentre randomized controlled study of 85 patients. *J Hand Surg Eur Vol*. 2015;40(1):76–83.
- [4] Kollitz KM, Hammert WC, Vedder NB, et al. Metacarpal fractures: treatment and complications. *Hand*. 2014; 9(1):16–23.
- [5] Strub B, Schindele S, Sonderegger J, et al. Intramedullary splinting or conservative treatment for displaced fractures of the little finger metacarpal neck? A prospective study. *J Hand Surg Eur Vol*. 2010; 35(9):725–729.
- [6] Shewring DJ, Trickett RW, Subramanian KN, et al. The management of clenched fist ‘fight bite’ injuries of the hand. *J Hand Surg Eur*. 2015;40(8):819–824.
- [7] Rayan GM, Murray D. Classification and treatment of closed sagittal band injuries. *J Hand Surg*. 1994;19A: 590–594.
- [8] Mackay I, Simpson RG. Closed rupture of extensor digitorum communis tendon following fracture of the radius. *Hand*. 1980;12(2):214–216.
- [9] Komura S, Yokoi T, Nonomura H. Traumatic closed index extensor tendon rupture at the musculotendinous junction: a report of two cases. *Hand*. 2011;6(1): 90–92.
- [10] Tabrizi A, Afshar A. Closed extensor digitorum communis tendons rupture at the musculotendinous junction: a case report. *J Hand Microsurg*. 2016;08(02): 120–121.
- [11] Darwish F, Haddad W, Oudat Z, et al. Missed injured structures in acutely injured hand. *Int J Hand Surg*. 2013;4(1):1–6.
- [12] Mahdavian Delavary B, Cremers JE, Ritt MJ. Hand and wrist malpractice claims in The Netherlands:1993–2008. *J Hand Surg Eur Vol*. 2010;35(5):381–384.