



Traumatic arterial thoracic outlet syndrome after multiple rib fractures not including the first rib in Korea: a case report

Seock Yeol Lee, MD

Department of Cardiothoracic and Vascular Surgery, Soonchunhyang University Cheonan Hospital, Cheonan, Korea

Received: November 10, 2023

Revised: March 7, 2024

Accepted: March 15, 2024

Correspondence to

Seock Yeol Lee, MD
Department of Cardiothoracic and
Vascular Surgery, Soonchunhyang
University Cheonan Hospital, 31
Suncheonhyang 6-gil, Dongnam-gu,
Cheonan 31151, Korea
Tel: +82-41-570-3843
Email: csdoctor@schmc.ac.kr

Arterial thoracic outlet syndrome (TOS) resulting from thoracic trauma is an exceedingly rare condition, typically caused by a fracture of the first rib or clavicle. In this report, the author presents a case of traumatic arterial TOS precipitated by multiple left rib fractures, notably excluding the first rib, following a fall from a 2-m high stepladder. The patient was treated successfully with first rib resection via a transaxillary approach, and the postoperative course was uneventful. The literature includes no known reports of traumatic arterial TOS in patients with multiple fractures that spare the first rib, making this the first documented case of its kind. In this instance, the patient sustained fractures to the fourth and fifth ribs. The TOS was likely not a direct result of the multiple rib fractures, which were located some distance from the thoracic outlet. Rather, it is hypothesized that the trauma from these fractures caused a soft tissue injury within the thoracic outlet, which ultimately led to the development of TOS.

Keywords: Thoracic outlet syndrome; Rib fractures; Arteries; Pathologic constriction; Case reports

INTRODUCTION

Thoracic outlet syndrome (TOS) arises from the compression of the neurovascular bundle in the thoracic outlet area. This condition is classified into three types: neurogenic, venous, and arterial TOS. Neurogenic TOS, the most common form, accounts for 95% of cases and results from compression of the brachial plexus. Venous TOS, caused by compression of the subclavian vein, represents 4% of cases. Arterial TOS, stemming from compression of the subclavian artery, is exceedingly rare, making up less than 1% of cases. Trauma—particularly to the clavicle or the first rib—can also trigger TOS, though such instances are very rare. In this

report, the author discusses a case of traumatic arterial TOS triggered by multiple rib fractures that did not involve the first rib.

CASE REPORT

A 48-year-old woman presented with a tingling sensation in her left upper extremity when it was elevated. She had sustained a fracture of her left fourth and fifth ribs 1 month earlier after falling from a 2-m high stepladder (Fig. 1). Following the accident, she experienced worsening chest pain and tingling sensation, particularly when raising her left arm. On evaluation, computed tomography (CT) angiography of the left upper extremity re-

vealed severe stenosis of the left proximal subclavian artery (Fig. 2A). Angiography of the left upper extremity demonstrated that normal blood flow in the left subclavian artery was maintained when the left arm was lowered (Fig. 2B). However, severe stenosis was observed proximal to the left subclavian artery when the left arm was elevated (Fig. 2C). Nerve conduction study results were within normal limits.

Consequently, the patient was diagnosed with traumatic arterial TOS and subsequently underwent physical therapy for 4 weeks. Despite this intervention, her symptoms did not improve.

Surgery was performed under general anesthesia. Partial resec-

tion of the first rib was carried out from anterior to posterior, near the transverse process, via a left transaxillary incision. The patient's symptoms disappeared immediately following the operation. Postoperative CT angiography revealed that the stenosis of the left proximal subclavian artery had also been resolved and the first rib had been successfully resected (Fig. 3). The patient's postoperative course was uneventful.

Ethics statement

Written informed consent for publication of the research details

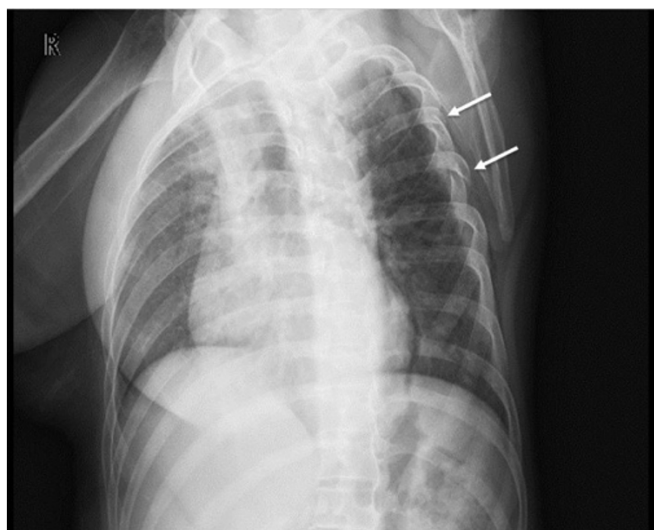


Fig. 1. Chest x-ray depicting multiple rib fractures of the left fourth and fifth ribs (arrows).

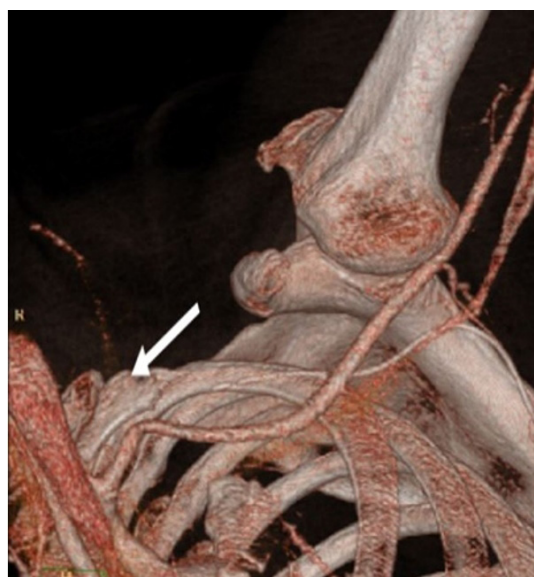


Fig. 3. Computed tomography angiography demonstrating the resolution of stenosis in the left proximal subclavian artery and the resection of the first rib (arrow).

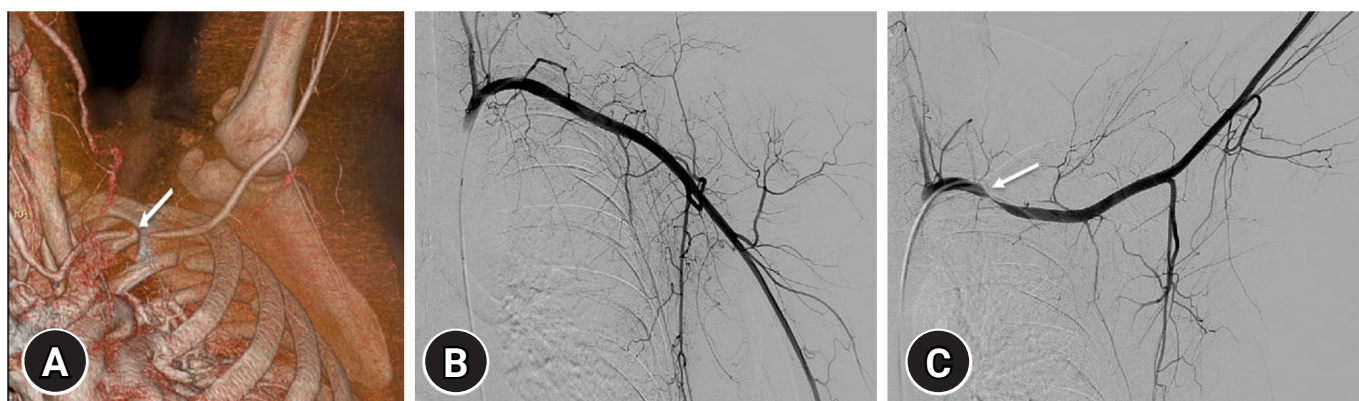


Fig. 2. Patient images upon evaluation. (A) Computed tomography angiography reveals severe stenosis of the left proximal subclavian artery when the left arm is raised (arrow). (B) Left upper extremity angiography demonstrates that normal blood flow is maintained in the left subclavian artery when the left arm is lowered. (C) However, severe stenosis is observed proximal to the left subclavian artery when the left arm is raised (arrow).

and clinical images was obtained from the patient.

DISCUSSION

TOS is characterized by excessive compression of the neurovascular bundle in the space between the clavicle and the first rib. This condition can be classified into three types: neurogenic, which accounts for approximately 95% of cases; venous, comprising about 4%; and arterial, which makes up less than 1% [1].

Arterial TOS is a rare condition typically caused by an anomalous cervical rib [2]. Cases of traumatic TOS resulting from clavicular or first rib fractures have been infrequently reported [3]. However, this report presents a unique instance of traumatic arterial TOS in a patient with multiple rib fractures not involving the first rib, which has not been previously documented in the literature. In this case, the patient sustained fractures to the fourth and fifth ribs. These multiple rib fractures, which occurred relatively far from the thoracic outlet, likely were not the direct cause of TOS. Rather, it is hypothesized that the impact associated with the multiple rib fractures contributed to a soft tissue injury at the thoracic outlet, subsequently leading to TOS.

TOS is challenging to diagnose due to the lack of unique symptoms and the absence of a universal confirmatory test. Nevertheless, this condition can be diagnosed through various methods, including magnetic resonance imaging, ultrasound, angiography, and nerve conduction studies, in addition to physical examination. In the present case, surgery was performed due to the lack of symptom improvement after 4 weeks of physical therapy.

The goal of surgical intervention for TOS is to alleviate the compression of the nerves and blood vessels by removing the first rib. Three surgical techniques are used to address TOS: transaxillary, supraclavicular, and infraclavicular approaches. The supraclavicular and transaxillary methods are the most frequently employed for first rib resection, but each approach has achieved favorable outcomes. To date, no technique has been established as definitively superior [4,5]. More recent developments include minimally invasive options, such as robotic and thoracoscopically assisted approaches [5]. Regardless of the surgical method selected, it is imperative to ensure complete decompression of the structures compressing the neurovascular bundle in the thoracic outlet. Inadequate decompression can result in suboptimal treatment outcomes or the possibility of symptom recurrence [6].

In conclusion, this author presents a case of traumatic arterial TOS resulting from multiple rib fractures not involving the first

rib. Prior to this report, the literature contained no known descriptions of traumatic arterial TOS associated with multiple rib fractures that spared the first rib. In this case, the patient sustained fractures of the fourth and fifth ribs. It is improbable that TOS was directly caused by the multiple rib fractures, as these were located relatively far from the thoracic outlet. Instead, the impact from the fractures likely affected the soft tissue within the thoracic outlet, ultimately leading to TOS. Accurate and timely diagnosis is crucial in cases of traumatic arterial TOS, as is the provision of appropriate treatment to alleviate arterial compression.

ARTICLE INFORMATION

Conflicts of interest

The author has no conflicts of interest to declare.

Funding

The author received no financial support for this study.

Data availability

Data sharing is not applicable as no new data were created or analyzed in this study.

REFERENCES

1. Sanders RJ. Thoracic outlet syndrome: general considerations. In: Cronenwett JL, Johnston KW, editors. *Rutherford's vascular surgery*. 7th ed. Saunders Elsevier; 2010. p. 1865–77.
2. Jiang S, Shen H, Tan WQ, Lu H. Arterial thoracic outlet syndrome caused by cervical ribs-an unusual case report. *Medicine (Baltimore)* 2019;98:e14778.
3. Dubuisson A, Lamotte C, Foidart-Dessalle M, et al. Post-traumatic thoracic outlet syndrome. *Acta Neurochir (Wien)* 2012;154:517–26.
4. Burt BM. Thoracic outlet syndrome for thoracic surgeons. *J Thorac Cardiovasc Surg* 2018;156:1318–23.
5. Jones MR, Prabhakar A, Viswanath O, et al. Thoracic outlet syndrome: a comprehensive review of pathophysiology, diagnosis, and treatment. *Pain Ther* 2019;8:5–18.
6. Suzuki T, Kimura H, Matsumura N, Iwamoto T. Surgical approaches for thoracic outlet syndrome: a review of the literature. *J Hand Surg Glob Online* 2023;5:577–84.