

Vancomycin Ophthalmic Ointment 1% for methicillin-resistant *Staphylococcus aureus* or methicillin-resistant *Staphylococcus epidermidis* infections: a case series

Chie Sotozono,¹ Masahiko Fukuda,² Masao Ohishi,³ Keiko Yano,⁴ Hideki Origasa,⁵ Yoshinori Saiki,⁶ Yoshikazu Shimomura,² Shigeru Kinoshita¹

To cite: Sotozono C, Fukuda M, Ohishi M, *et al.* Vancomycin Ophthalmic Ointment 1% for methicillin-resistant *Staphylococcus aureus* or methicillin-resistant *Staphylococcus epidermidis* infections: a case series. *BMJ Open* 2013;**3**:e001206. doi:10.1136/bmjopen-2012-001206

► Prepublication history for this paper are available online. To view these files please visit the journal online (<http://dx.doi.org/10.1136/bmjopen-2012-001206>).

Received 11 June 2012
Revised 29 October 2012
Accepted 14 December 2012

This final article is available for use under the terms of the Creative Commons Attribution Non-Commercial 2.0 Licence; see <http://bmjopen.bmj.com>

For numbered affiliations see end of article.

Correspondence to

Chie Sotozono;
csotozon@koto.kpu-m.ac.jp

ABSTRACT

Objectives: To investigate the efficacy and safety of Vancomycin Ophthalmic Ointment 1% (Toa Pharmaceutical Co., Ltd, Toyama, Japan) in patients with external ocular infections caused by methicillin-resistant *Staphylococcus aureus* (MRSA) or methicillin-resistant *Staphylococcus epidermidis* (MRSE).

Design: A case series.

Setting: This study was a multicentre, open-label, uncontrolled study in Japan approved as orphan drug status.

Participants: Patients with MRSA or MRSE external ocular infections unresponsive to the treatment of fluoroquinolone eye drops.

Interventions: Vancomycin Ophthalmic Ointment 1% was administered four times daily.

Primary and secondary outcome measures:

The subjective and objective clinical scores and bacterial cultures were collected at days 0 (baseline), 3, 7 and 14. The primary outcome was clinical response evaluation (efficacy rate) determined as *complete response*, *partial response*, *no response* and *worsening*. Secondary outcome was the eradication of the bacteria. Safety was assessed by adverse events including cases in which neither MRSA nor MRSE was detected.

Results: Twenty-five cases with MRSA (20) or MRSE (5) infections were enrolled. Of these 25 cases, 4 discontinued the treatment due to the negative results for bacterial culture during screening or at baseline. Of the 21 cases with conjunctivitis (14), blepharitis (3), meibomitis (1), dacryocystitis (2) or keratitis (1), 14 (66.7%) cases were evaluated as being excellently (*complete response*, 2 cases) or well (*partial response*, 12 cases) treated. The eradication rates were 68.4% in MRSA (13 of 19 cases) and 100% in MRSE (2 of 2 cases). Ten adverse events occurred in 7 (28.0%) of 25 cases at the local administration site.

Conclusions: Vancomycin Ophthalmic Ointment 1% was considered to be useful for the treatment of intractable ocular MRSA/MRSE infections.

ARTICLE SUMMARY

Article focus

- Ophthalmic solution prepared by in-house prescription from bulk powder with saline is unstable and acidic.
- Since vancomycin exerts its actions time dependently, an ophthalmic ointment with high tissue retentivity is well suited for clinical use.
- The aim of this study was to examine the effects of Vancomycin Ophthalmic Ointment 1% for the treatment of external ocular methicillin-resistant *Staphylococcus aureus* (MRSA) or methicillin-resistant *Staphylococcus epidermidis* (MRSE) infections.

Key messages

- Vancomycin Ophthalmic Ointment 1% is useful for the treatment of external ocular MRSA or MRSE infections.

Strengths and limitations of this study

- Although a randomised control trial is ideal, this is an open-label, uncontrolled study.
- Due to strict inclusion criteria, the number of patients enrolled is small. Most of the cases were chronic and/or prolonged mild infections in elderly patients.

INTRODUCTION

Methicillin-resistant *Staphylococcus aureus* (MRSA) was first reported in 1960, the same year that methicillin was developed,¹ and it is still a bacteria that is frequently detected in hospitals worldwide.² In the field of ophthalmology, ocular infections such as dacryocystitis, conjunctivitis and keratitis are often reported,^{3–7} and infectious keratitis and endophthalmitis caused by MRSA are increasing problems throughout the world.^{8–10} In recent years, the number of multidrug-resistant MRSA strains showing resist-

ance to other antibiotics such as aminoglycosides, minocycline and fluoroquinolones has been on the rise.^{11–15} *Staphylococcus epidermidis* has developed the same bacterial resistance as *S aureus* and has now been termed as methicillin-resistant *S epidermidis* (MRSE). Moreover, previous reports have shown that MRSE can cause ophthalmic infections and blindness.^{4 16}

Vancomycin, a glycopeptide antibiotic, is known to be effective for treating MRSA infections. Since its injection formulation was first approved for the indication of infectious disease due to Gram-positive bacteria in 1958 in the USA, vancomycin has become an approved antibiotic throughout the world and is highly valued particularly for the treatment of MRSA infections.^{9 15} In the therapy of ocular infections, a topical application of vancomycin solutions prepared by in-house prescription is often used.^{16 17} However, vancomycin is unstable in an aqueous solution. In addition, vancomycin solutions prepared by in-house prescription using saline are acidic, and the irritation of the solutions to tissues causes patient compliance problems.¹⁷

We first prepared vancomycin ophthalmic ointments for the treatment of destructive MRSA keratitis postlamellar keratoplasty and found that the infectious keratitis healed dramatically.^{4 18} Considering the fact that vancomycin is a drug that exerts its actions time dependently,¹⁹ an ophthalmic ointment with high tissue retentivity, is well suited for clinical use. Indeed, vancomycin ophthalmic ointments remained at least 3 h after administration in a 5-year-old boy with severe MRSA keratitis. It has been suggested that vancomycin ophthalmic ointments remain longer on the ocular surface compared with vancomycin solutions.¹⁸ However, those ointments have proved to be difficult to prepare, and a commercially made product with long-term stability that can be distributed at an effective concentration to the site of an infection has been in demand.

Vancomycin Ophthalmic Ointment 1% (Toa Pharmaceutical Co., Ltd, Toyama, Japan) was developed for the treatment of MRSA/MRSE ocular infections.²⁰ In 2001, it was designated as an orphan drug for the treatment of 'ocular infections, such as blepharitis, conjunctivitis and keratitis caused by MRSA and MRSE' (Grant No. 13–152, dated 23 April 2001). Thereafter, a phase I study confirmed the safety and tolerability of vancomycin ophthalmic ointment in healthy adult volunteers. In this study, we investigated the efficacy and safety of Vancomycin Ophthalmic Ointment 1% in patients with external ocular infections caused by MRSA or MRSE.

MATERIALS AND METHODS

Study design

This study was a multicentre, open-label, uncontrolled study approved as orphan drug status. The study protocol was designed to evaluate the efficacy and safety of Vancomycin Ophthalmic Ointment 1% in patients with MRSA or MRSE external ocular infections. The study

included a 3-day (or more) screening period with the treatment of fluoroquinolone eye drops, and a 14-day treatment period during which patients received Vancomycin Ophthalmic Ointment 1% (four times daily; figure 1). It was approved by the institutional review board at each study site. The study was carried out in accordance with the tenets set forth in the Declaration of Helsinki and in compliance with the 'Good Clinical Practice (GCP)' stipulated by the Ministry of Health, Labour and Welfare of Japan. Written informed consent was obtained from each patient at the respective institution before the initiation of the study protocol.

Screening and eligibility

The subjects involved in this study were patients with external ocular infections caused by MRSA or MRSE who were diagnosed with conjunctivitis, blepharitis, hordeolum, meibomitis, dacryocystitis and keratitis after presentation at 1 of 20 medical institutions in Japan between February 2006 and February 2007. Patient inclusion and exclusion criteria are shown in box 1. Only the patients who met all of the inclusion criteria were enrolled in this study.

Dosage regimen of the study drug

Vancomycin Ophthalmic Ointment 1% (containing 10 mg (potency) of vancomycin hydrochloride per gram) was administered at a dose of around 1 cm (approximately 50 mg) four times (morning, noon, evening and before bedtime) daily. The study treatment was started in the morning. The maximum treatment period was 14 days, and the treatment was terminated before 14 days in cases with diminishing subjective and objective findings of ocular infection.

Evaluation methods

Efficacy

The results of the bacteriological evaluation and clinical symptom assessment at days 3, 7 and 14 after the study

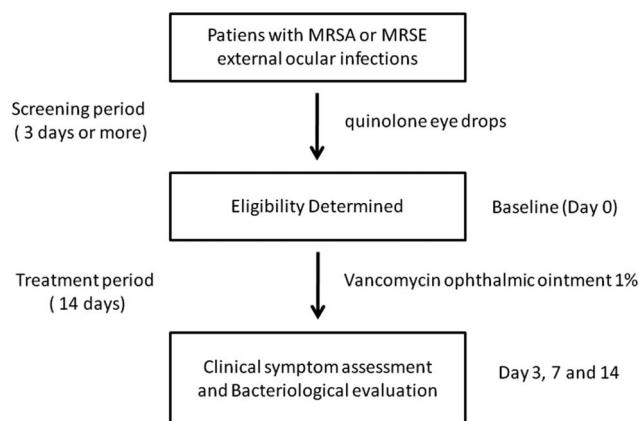


Figure 1 Study design. External ocular infections caused by methicillin-resistant *Staphylococcus aureus* or methicillin-resistant *Staphylococcus epidermidis* and cases in which fluoroquinolone eye drops showed no clinical effect were enrolled.

Box 1 Inclusion/exclusion criteria.*Inclusion criteria**

- ▶ Age: 20 years or older and 90 years or younger (at the time of informed consent)
- ▶ Ocular infections due to MRSA or MRSE including the following target diseases: conjunctivitis, blepharitis, hordeolum, meibomianitis, dacryocystitis, keratitis and corneal ulcer
- ▶ Patients whose symptoms did not improve after local treatment with a fluoroquinolone antibacterial agent for the eyes for 3 days or more

*Exclusion criteria**

- ▶ Prior episode of hypersensitivity to vancomycin hydrochloride
- ▶ Prior episode of hypersensitivity to teicoplanin, peptide antibiotics or aminoglycoside antibiotics
- ▶ Patients who were on vancomycin hydrochloride or drugs of the same class and with the same effect (arbekacin sulfate and teicoplanin)
- ▶ Patients with a clinically significant disease of the autoimmune, cardiovascular, haematological, nervous, endocrine, hepatic, renal or digestive system
- ▶ Pregnant women, women of childbearing potential and lactating women

MRSA, methicillin-resistant *Staphylococcus aureus*; MRSE, methicillin-resistant *Staphylococcus epidermidis*.

* Pertains to study eyes, except where otherwise noted.

treatment initiation, and at study treatment completion or discontinuation, were evaluated and judged in comparison with those at the study treatment initiation (day 0; baseline). In cases with bilateral infection, either the severely affected eye or the right eye was evaluated.

In the clinical symptom assessment, symptoms and findings were scored according to the evaluation criteria, and the course of clinical symptoms at screening, at day 0 (baseline) and at days 3, 7 and 14 after the study treatment initiation, and study treatment completion or discontinuation were evaluated. Eye discharge, eye pain, foreign body sensation, photophobia and lacrimation as symptoms and redness (hyperaemia) and oedema (swelling), swelling of the eyelid, lacrimal-sac fluid reflux and keratitis as objective findings were classified into four levels and recorded as follows: notably severe (+++), 3 points; marked (++), 2 points; obvious (+), 1 point; and none (–), 0 points.

In the bacteriological evaluation, samples for bacterial culture and identification were collected with sterile swabs from the eyes of patients at screening, at day 0 (baseline) and at days 3, 7 and 14 after the study treatment initiation, and at study treatment completion or discontinuation. These samples were inoculated into aerobic media, and the antibiotic sensitivity of the isolated bacterial strains was tested at the central laboratory for microbial testing (Research Foundation for Microbial Diseases of Osaka University). The effect

towards negative conversion at days 3, 7 and 14 was calculated and evaluated.

The efficacy was determined as *complete response* (eradication of detected bacteria (estimated causative bacteria, hereinafter referred to as 'the bacteria') within 4 days and the disappearance of main symptoms within 1 week), *partial response* (1) eradication of the bacteria within 1 week and the disappearance of main symptoms within 2 weeks, (2) eradication of the bacteria within 4 days and a symptom score changed to $\geq 1/4$ to $\leq 1/2$ within 1 week or (3) no eradication of the bacteria but a symptom score changed to $\leq 1/3$ within 1 week), *no response* (efficacy not corresponding to partial response or better) and *worsening* (deterioration of the main symptoms or symptom score compared with those at baseline).

Safety evaluation

All adverse drug reactions (ADRs) were recorded, and the frequency and incidence of the ADRs were then evaluated.

Analysis methods**Efficacy**

The main efficacy analysis population was defined as a 'full analysis set (FAS)' not including patients with major GCP violations. Analyses in a 'per protocol set (PPS)', the population meeting the protocol criteria, were also performed. The results of the bacteriological evaluation and clinical symptom assessment were classified into five levels (complete response, partial response, no response, worsening and indeterminate) and a frequency table was then prepared. In addition, the percentage of patients with complete response and a partial response was calculated as an 'efficacy rate' that was evaluated by a one-sample exact test (two-sided significance level of 0.05: null hypothesis, efficacy rate: 10%) based on a binomial distribution. The 95% CIs for the efficacy rates were also calculated. In the bacteriological evaluation, the percentages of patients with eradication of MRSA or MRSE at the treatment completion or discontinuation were calculated as eradication rates.

Safety

In a 'safety population (SP)', patients who received at least one dose of the study drug and excluding those with major GCP violations, the frequency (number of patients with ADRs, number of ADRs and incidence) was tabulated by a system organ. Causal relationship, severity and outcomes in each ADR were judged by the attending physician.

RESULTS**Disposition of patients**

In regard to the analysis populations, 25 patients, not including a patient with a major GCP violation, were adopted to the SP. Of the 25 patients in the SP, 4 patients

Table 1 Frequency tabulation of patient background characteristics: FAS, PPS and SP

Analysis population Item	FAS Number of patients (%)	PPS Number of patients (%)	SP Number of patients (%)
Number of patients	21 (100.0)	18 (100.0)	25 (100.0)
Sex			
Male	8 (38.1)	8 (44.4)	9 (36.0)
Female	13 (61.9)	10 (55.6)	16 (64.0)
Age (years)			
20≤ to <40	1 (4.8)	1 (5.6)	1 (4.0)
40≤ to <60	1 (4.8)	1 (5.6)	2 (8.0)
60≤ to <75	7 (33.3)	6 (33.3)	8 (32.0)
75≤ to ≤90	12 (57.1)	10 (55.6)	14 (56.0)
Bacterial strain			
MRSA	19 (90.5)	16 (88.9)	20 (80.0)
MRSE	2 (9.5)	2 (11.1)	5 (20.0)
Diagnosis (target disease)			
Blepharitis	3 (14.3)	3 (16.7)	3 (12.0)
Hordeolum	0 (0.0)	0 (0.0)	0 (0.0)
Meibomianitis	1 (4.8)	1 (5.6)	1 (4.0)
Conjunctivitis	14 (66.7)	11 (61.1)	16 (64.0)
Dacryocystitis	2 (9.5)	2 (11.1)	2 (8.0)
Keratitis	1 (4.8)	1 (5.6)	3 (12.0)
Severity			
Mild	19 (90.5)	16 (88.9)	21 (84.0)
Moderate	2 (9.5)	2 (11.1)	4 (16.0)
Severe	0 (0.0)	0 (0.0)	0 (0.0)

FAS, full analysis set; PPS, per protocol set; SP, safety population.

with treatment discontinuation due to negative results for bacterial culture during screening or at baseline were excluded, and 21 patients were included in the FAS. Of the 21 patients adopted into the FAS, 3 patients with protocol deviations were excluded and 18 patients were included in the PPS (table 1). As to the demographic characteristics of the patients, the mean age was 72.1±14.0 years (hereinafter: mean±SD).

Efficacy

In the clinical response evaluation (efficacy rate) defined as the primary endpoint, the efficacy rate was 66.7% in both the FAS and PPS. It was significantly higher in both populations as compared with the efficacy rate of 10% specified in the null hypothesis ($p<0.001$). The 95% CIs for the efficacy rate were 43–85.4% in the FAS and 41–86.7% in the PPS. In the evaluation by bacterial

strain, the efficacy rates for MRSA were 63.2% in the FAS and 62.5% in the PPS. The efficacy rates for MRSE were 100% in both the FAS and PPS. In the evaluation by disease, conjunctivitis was most frequent, and the efficacy rates were 71.4% in the FAS and 72.7% in the PPS (table 2). In the bacteriological evaluation, the eradication rates were 68.4% (13 of 19 cases) for MRSA and 100% (2 of 2 cases) for MRSE in the FAS (figure 2).

Safety

Ten ADRs occurred in seven (28%) patients, and all the ADRs occurred at the local administration site. The main ADRs were eyelid oedema in three (12%) patients and conjunctival hyperaemia in three (12%) patients. Eyelid oedema, increased eye discharge and swelling of the face were moderate, and the other events such as conjunctival hyperaemia, abnormal sensation in the eye

Table 2 Clinical response evaluation by disease (full analysis set, FAS)

Target disease	Number of patients	Clinical response					Efficacy rate (%)
		Complete response	Partial response	No response	Worsening	Indeterminate	
Conjunctivitis	14	2 (14.3%)	8 (57.1%)	3 (21.4%)	0	1 (7.1%)	71.4
Blepharitis	3	0	2 (66.7%)	1 (33.3%)	0	0	66.7
Meibomianitis	1	0	1 (100.0%)	0	0	0	100.0
Dacryocystitis	2	0	1 (50.0%)	1 (50.0%)	0	0	50.0
Keratitis	1	0	0	1 (100.0%)	0	0	0.0

Efficacy rate: (number of patients with 'complete response' or 'partial response'/number of patients studied)×100.

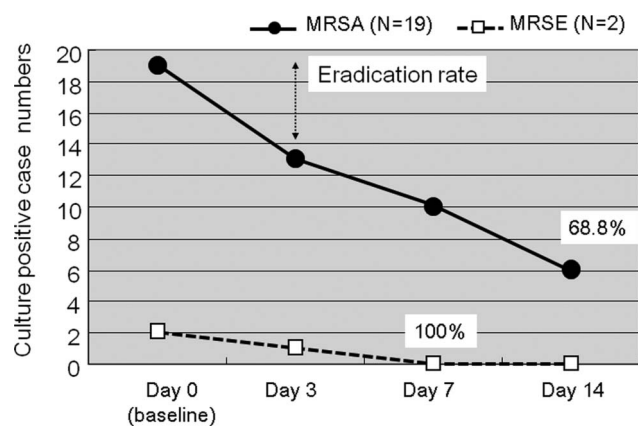


Figure 2 Bacteriological evaluation at 3, 7 and 14 days after initiation of treatment.

and pruritus at the application site were mild. Treatment was discontinued only in one patient with atopic dermatitis who developed swelling of the face and bilateral swelling of the eyelid. All the ADRs were confirmed to have resolved after the study completion.

DISCUSSION

In recent reports on drug-susceptibility of detected bacteria in the field of ophthalmology, the resistance rates of MRSA to ophthalmic antibiotics such as levofloxacin, cefmenoxime and erythromycin have risen. In contrast, the susceptibility rate of MRSA to vancomycin is reportedly still 100%.^{2 11 13–15} Physicians in the clinical setting use ophthalmic solutions prepared by in-house prescription from bulk powder for injection, and their efficacy for MRSA or MRSE ocular infections has been previously reported.^{4 16 17} Nonetheless, vancomycin for local ophthalmic use has yet to become available on the open market.

Since vancomycin exerts its actions time dependently,¹⁹ an ophthalmic ointment with high tissue retentivity is well suited for clinical use. Vancomycin Ophthalmic Ointment 1% is a product with good stability achieved by creating an ophthalmic ointment in which vancomycin is dispersed in an oily base.^{20 21} This case series showed that Vancomycin Ophthalmic Ointment 1% is useful for the treatment of external ocular MRSA or MRSE infections.

In this study, the subjects were defined as patients in whom MRSA or MRSE was detected in a bacterial test, and moreover, whose symptoms did not improve after local treatment with fluoroquinolone eye drops. Due to such strict inclusion criteria, the number of patients enrolled is small. It was difficult to obtain participants in whom acutely severe infections occurred. In most of the hospitals involved in this study, vancomycin solutions prepared by in-house prescription had already been used for sight-threatening severe infections such as severe MRSA keratitis. Most of the cases in this study were chronic and/or prolonged mild infections in elderly patients.

Of the total 25 patients, 10 ADRs occurred in 7 (28%) patients, and all the ADRs occurred at the local

administration site. The main ADRs were eyelid oedema in three (12%) patients and conjunctival hyperaemia in three (12%) patients. All of the ADRs were confirmed to have resolved after the study completion. In terms of the systemic distribution following the administration of vancomycin ophthalmic ointment, plasma concentrations after administration were below the detection limit in all subjects in the phase I study. Vancomycin ophthalmic ointment was presumably a product that would be quite unlikely to cause systemic ADRs based on its pharmacokinetics.

The proportion of MRSA in conjunctival bacterial flora is reportedly high in elderly individuals and in patients with atopic dermatitis or neonates.^{22–24} Postoperative endophthalmitis or keratitis can occur in these MRSA carriers, and the application of vancomycin in conjunctival MRSA carriers might be effective in preventing MRSA infections.

There has been concern about the growing resistance of *S aureus* to vancomycin.²⁵ Particular attention should be paid to not facilitate the growth of bacterial resistance to vancomycin. MRSA isolated from ocular infections is often susceptible to chloramphenicol, fourth-generation fluoroquinolones and other antibiotics.^{15 26} Thus, it is preferable to use Vancomycin Ophthalmic Ointment 1% only for a short period of time and only for patients who specifically require this new drug.

Author affiliations

¹Department of Ophthalmology, Kyoto Prefectural University of Medicine, Kyoto, Japan

²Department of Ophthalmology, Kinki University Faculty of Medicine, Osaka, Japan

³Shiranekeisei Hospital, Niigata, Japan

⁴Yata Eye Clinic, Shizuoka, Japan

⁵Division of Biostatistics and Clinical Epidemiology, University of Toyama School of Medicine, Toyama, Japan

⁶Toa Pharmaceuticals Co, Ltd, Toyama, Japan.

Acknowledgements We would like to thank Toa Pharmaceutical Co, Ltd, Toyama, Japan, and all of the following doctors and institutes who participated in the study: Dr Atsushi Moriguchi at the Hanwa the Second Hospital, Senboku Kinsyu Medical Corporation, Dr Hiroshi Shioda from Tokushima University Hospital, Dr Yoshitsugu Inoue at Tottori University Hospital, Dr Toshihiko Uno at Ehime University Hospital, Dr Tomoko Goto at Takanoko Hospital, Dr Shoichi Sawaguchi at the University Hospital, University of the Ryukyus, Dr Kenji Matsuo at Tomakomai City Hospital, Dr Masaaki Ohashi at Tokyo Metropolitan Geriatric Medical Center, Dr Kazuya Inamochi at Asahi Central Hospital, Dr Kaori Hirai at the Hoshi General Hospital Foundation, Dr Shigeki Okamoto at Kozuka Eye Clinic, Dr Shusaku Ishikawa at Chibana Clinic, Dr Toshio Kodama at Matsuyama Red Cross Hospital, Dr Momoyo Shinjo at Oroku Hospital, Dr Kazunori Miyata at Miyata Eye Hospital, Dr Yoshitsugu Tagawa at Hokkaido University Hospital, Dr Tomohiro Iida at Fukushima Medical University Hospital, Dr Shigeto Kumakura at Tokyo Medical University Hospital. We also wish to thank Mr John Bush at Kyoto Prefectural University of Medicine for his assistance with the preparation of the manuscript.

Funding This study was supported by Toa Pharmaceuticals Co. Ltd in study design, conducting the study and data collection management.

Competing interests YS is an employee of Toa Pharmaceuticals Co Ltd.

Patient consent Obtained.

Provenance and peer review Not commissioned; externally peer reviewed.

Data sharing statement No additional data are available.

REFERENCES

- Jevons MP, Coe AW, Parker MT. Methicillin resistance in staphylococci. *Lancet* 1963;1:904–7.
- Maple PA, Hamilton-Miller JM, Brumfitt W. World-wide antibiotic resistance in methicillin-resistant *Staphylococcus aureus*. *Lancet* 1989;1:537–40.
- Brennen C, Muder RR. Conjunctivitis associated with methicillin-resistant *Staphylococcus aureus* in a long-term-care facility. *Am J Med* 1990;88:14N–7N.
- Sotozono C, Inagaki K, Fujita A, *et al*. Methicillin-resistant *Staphylococcus aureus* and methicillin-resistant *Staphylococcus epidermidis* infections in the cornea. *Cornea* 2002;21:S94–101.
- Forster W, Becker K, Hungermann D, *et al*. Methicillin-resistant *Staphylococcus aureus* keratitis after excimer laser photorefractive keratectomy. *J Cataract Refract Surg* 2002;28:722–4.
- Shanmuganathan VA, Armstrong M, Buller A, *et al*. External ocular infections due to methicillin-resistant *Staphylococcus aureus* (MRSA). *Eye* 2005;19:284–91.
- Sahu DN, Thomson S, Salam A, *et al*. Neonatal methicillin-resistant *Staphylococcus aureus* conjunctivitis. *Br J Ophthalmol* 2006;90:794–5.
- Wroblewski KJ, Pasternak JF, Bower KS, *et al*. Infectious keratitis after photorefractive keratectomy in the United States army and navy. *Ophthalmology* 2006;113:520–5.
- Solomon R, Donnenfeld ED, Perry HD, *et al*. Methicillin-resistant *Staphylococcus aureus* infectious keratitis following refractive surgery. *Am J Ophthalmol* 2007;143:629–34.
- Shimada H, Nakashizuka H, Hattori T, *et al*. Incidence of endophthalmitis after 20- and 25-gauge vitrectomy causes and prevention. *Ophthalmology* 2008;115:2215–20.
- Maffett M, O'Day DM. Ciprofloxacin-resistant bacterial keratitis. *Am J Ophthalmol* 1993;115:545–6.
- Cimolai N. Ciprofloxacin and multiresistant staphylococci. *Lancet* 1997;349:1030.
- Marangon FB, Miller D, Muallem MS, *et al*. Ciprofloxacin and levofloxacin resistance among methicillin-sensitive *Staphylococcus aureus* isolates from keratitis and conjunctivitis. *Am J Ophthalmol* 2004;137:453–8.
- Cavuoto K, Zutshi D, Karp CL, *et al*. Update on bacterial conjunctivitis in South Florida. *Ophthalmology* 2008; 115:51–6.
- Elsahn AF, Yildiz EH, Jungkind DL, *et al*. In vitro susceptibility patterns of methicillin-resistant *Staphylococcus aureus* and coagulase-negative staphylococcus corneal isolates to antibiotics. *Cornea* 2010;29:1131–5.
- Goodman DF, Gottsch JD. Methicillin-resistant staphylococcus epidermidis keratitis treated with vancomycin. *Arch Ophthalmol* 1988;106:1570–1.
- Fleischer AB, Hoover DL, Khan JA, *et al*. Topical vancomycin formulation for methicillin-resistant *Staphylococcus epidermidis* blepharoconjunctivitis. *Am J Ophthalmol* 1986;101:283–7.
- Fujita A, Sotozono C, Inatomi T, *et al*. Severe MRSA infection of the eye treated with vancomycin ointment. *Atarashii Ganka* 2000; 17:93–5.
- Chua K, Howden BP. Treating Gram-positive infections: vancomycin update and the whys, wherefores and evidence base for continuous infusion of anti-Gram-positive antibiotics. *Curr Opin Infect Dis* 2009;22:525–34.
- Fukuda M, Hanazome I, Sasaki K. The intraocular dynamics of vancomycin hydrochloride ophthalmic ointment (TN-011) in rabbits. *J Infect Chemother* 2003;9:93–6.
- Eguchi H, Shiota H, Oguro S, *et al*. The inhibitory effect of vancomycin ointment on the manifestation of MRSA keratitis in rabbits. *J Infect Chemother* 2009;15:279–83.
- Kato T, Hayasaka S. Methicillin-resistant *Staphylococcus aureus* and methicillin-resistant coagulase-negative staphylococci from conjunctivas of preoperative patients. *Jpn J Ophthalmol* 1998;42:461–5.
- Nakata K, Inoue Y, Harada J, *et al*. A high incidence of *Staphylococcus aureus* colonization in the external eyes of patients with atopic dermatitis. *Ophthalmology* 2000;107:2167–71.
- Hori Y, Nakazawa T, Maeda N, *et al*. Susceptibility comparisons of normal preoperative conjunctival bacteria to fluoroquinolones. *J Cataract Refract Surg* 2009;35:475–9.
- Hiramatsu K, Aritaka N, Hanaki H, *et al*. Dissemination in Japanese hospitals of strains of *Staphylococcus aureus* heterogeneously resistant to vancomycin. *Lancet* 1997;350:1670–3.
- Fukuda M, Ohashi H, Matsumoto C, *et al*. Methicillin-resistant *Staphylococcus aureus* and methicillin-resistant coagulase-negative *Staphylococcus* ocular surface infection efficacy of chloramphenicol eye drops. *Cornea* 2002;21:S86–9.