




Original Article

Facet joint thickness and lumbar instability documented on myelo-computed tomography studies in patients with lumbar degenerative disease

Shunsuke Ikeda¹, Hidetoshi Ooigawa¹, Tatsuki Kimura¹, Hideki Tanabe², Hiroki Kurita¹

¹Department of Neurosurgery, International Medical Center, Saitama Medical University, Hidaka, Saitama, ²Department of Neurosurgery, Tanabe Neurosurgical Hospital, Osaka, Japan.

E-mail: Shunsuke Ikeda - work250trshun@yahoo.co.jp; *Hidetoshi Ooigawa - ho24811@5931.saitama-med.ac.jp; Tatsuki Kimura - tatsukimu1205@gmail.com; Hideki Tanabe - tanabe@machida-ns.clinic; Hiroki Kurita - hk0836@5931.saitama-med.ac.jp



***Corresponding author:**

Hidetoshi Ooigawa,
Department of Neurosurgery,
International Medical Center,
Saitama Medical University,
Hidaka, Saitama, Japan.

ho24811@5931.saitama-med.
ac.jp

Received: 03 August 2023

Accepted: 29 August 2023

Published: 22 September 2023

DOI

10.25259/SNI_652_2023

Quick Response Code:



ABSTRACT

Background: Various indicators of vertebral instability in patients with lumbar degenerative disease can be identified in myelo-computed tomography (CT) studies.

Methods: Of 120 patients, 45 with lumbar degenerative spondylolisthesis (LDS; 53 lumbar lesions) and 75 with lumbar spinal stenosis alone (LSS; 105 lesions) (2015–2019) myelo-CT studies and surgery confirmed the presence of lumbar instability. Myelo-CT findings indicative of instability included facet joint thickness (FJT), fluid in the facet joint, facet tropism, and air in the facet and/or disc.

Results: For the 120 study patients, FJT was significantly elevated in both the LDS and LSS groups.

Conclusion: FJT on myelo-CT is more specific for lumbar instability than other imaging parameters when evaluating LDS. An increase in FJT suggests vertebral instability likely warranting fusion.

Keywords: Facet, Lumbar degenerative disease, Lumbar degenerative spondylolisthesis, Lumbar spinal stenosis, Spine

INTRODUCTION

Facet joint thickness (FJT),^[5,7,8] facet fluid signs (FFS),^[1,2,3,8] facet tropism,^[4,6] air in the facet joint, and air in the disc seen on lumbar MR or computed tomography (CT)/myelo-CT studies often reflect the presence of significant segmental instability. Here, we analyzed the clinical outcomes and radiological findings for 120 patients whose myelo-CT studies documented significant changes in the facet joints consistent with lumbar instability likely warranting fusion.

MATERIALS AND METHODS

Study population

The study was approved by our Institutional Review Board. It included 120 patients, 45 with lumbar degenerative spondylolisthesis [LDS >25% slip or >3 mm, Figure 1] (53 lumbar lesions), and 75 with lumbar spinal stenosis (LSS) (105 lesions) aged 60 or older, who underwent presurgical

This is an open-access article distributed under the terms of the Creative Commons Attribution-Non Commercial-Share Alike 4.0 License, which allows others to remix, transform, and build upon the work non-commercially, as long as the author is credited and the new creations are licensed under the identical terms.

©2023 Published by Scientific Scholar on behalf of Surgical Neurology International

myelo-CT studies of the lumbar spine (2015–2019) confirming instability warranting fusion [Table 1].

Myelo-CT documentation of instability

Myelo-CT criteria for lumbar instability included the assessment of FJT, FFS, facet tropism, air in the facet, and

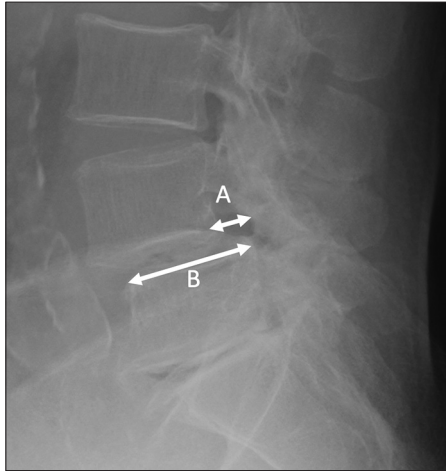


Figure 1: Measurement of vertebral slip. (A) The distance between the tangents drawn on the posterior surface of the upper vertebral body and the posterior surface of the lower vertebral body was measured. (B) The anterior-posterior diameter of the lower vertebral body was measured. $A/B \times 100(\%) >25(\%)$ or $A >3$ mm was defined as slippage.

Table 1: Clinical characteristics of 120 patients.

	LDS	LSS	P-value
Number of patients	45	75	
Age (years), mean \pm SD	70.9 \pm 6.0	73.2 \pm 6.2	0.033*
Male sex (%)	29 (64.4)	44 (58.7)	0.53
Number of vertebral slip (%)	53 (58.9)	105 (70.0)	0.079
L3/4 (%)	9 (20)	59 (78.7)	<0.001*
L4/5 (%)	44 (97.8)	46 (61.3)	<0.001*

LDS: Lumbar degenerative spondylolisthesis, LSS: Lumbar spinal stenosis without vertebral slip, SD: Standard deviation. *Statistically significant

Table 2: Definition of each radiological indicator.

Indicator	Definition	Image
FJT	Maximum distance between the inferior and superior articular processes	Axial Myelo-CT
FFS	Measurable, curvilinear, high-intensity signal in the facet joint that matched CCF	Axial MRI T2WI
Facet tropism	Difference between bilateral facet joint angles	Axial Myelo-CT
Air in the facet	Existence of the air density in the facet	Axial Myelo-CT
Air in the disc	Existence of the air density in the disc	Sagittal Myelo-CT

FJT: Facet joint thickness, CT: Computed tomography, FFS: Facet fluid sign, CCF: Cerebrospinal fluid, MRI: Magnetic resonance imaging, T2WI: T2-weighted image

air in the disc [Table 2]. FJT was defined as the maximum distance between the inferior and superior articular processes of the level [Figure 2]. FFS was defined as a measurable, curvilinear, and high-intensity signal in the facet joint that matched that of cerebrospinal fluid on axial T2-weighted MRI [Figure 3]. Facet tropism measurements were carried out as previously described by Ko *et al.* [Figure 4].^[6] Surgery included decompressions alone for the LSS group, while those with LDS underwent additional fusions.

Statistical analysis

Student's *t*-test, Pearson's Chi-square test and multivariate analysis with multiple logistic regression analysis were carried out. The level of significance was set at 5% ($P \leq 0.05$), and all analyses were performed using SPSS, version 23.0 (IBM, Armonk, NY).

RESULTS

Neuroradiological indices

FJT was significantly elevated (2.6 ± 1.1 mm) in the LDS group versus the LSS group (1.7 ± 0.8 mm) [Table 3]. FFS was more frequently recognized in the LDS group (40 [75%] patients) versus the LSS group 61 [58%] patients); univariate and multivariate analysis confirmed that FJT was significantly related to LDS [Tables 3 and 4]. The LDS group ($12.2 \pm 6.6^\circ$) also had significantly greater facet joint angles versus the LSS group ($9.5 \pm 7.1^\circ$) [Table 3]. However, air in the facet was found in 21 (39.6%) in the LDS group and 38 (36.2%) in the LSS group, and air in the disc in 35 (66.0%) in the LDS group and 61 (58.0%) in the LSS group, with no significant differences between the two groups.

DISCUSSION

FJT major myelo-CT indicator of lds instability warranting fusion

This study demonstrated that FJT was elevated especially in patients with LDS and was thus a crucial sign of dynamic vertebral instability and the need for fusion. Hasegawa *et al.* verified that an increased facet joint volume was associated

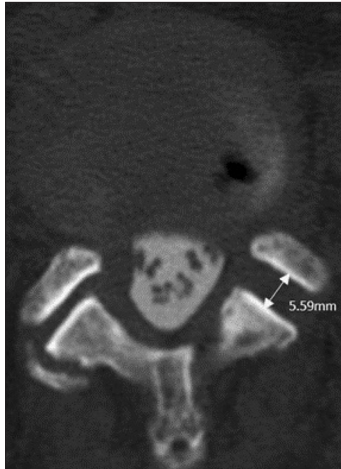


Figure 2: Measurement of facet joint thickness. The measurement was performed at the site where the joint fissure was the maximum width. The distance between the superior articular process and the articular process cortical bone was measured.

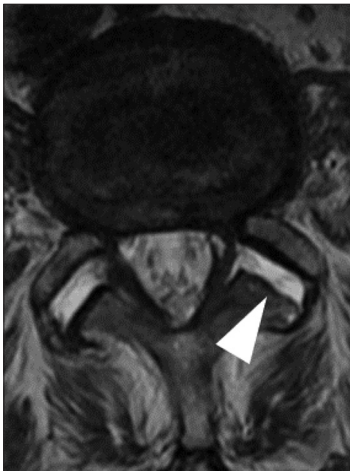

Figure 3: Facet fluid sign. Water intensity in facet on T2-weighted magnetic resonance imaging was defined as facet fluid sign (white arrowhead).

with lumbar segmental instability.^[5] Here, we showed that FJT was significantly elevated in patients with LDS (> 3 mm or >25% olisthy).

FSS additional myelo-CT finding for instability

FFS has become an important indicator of lumbar instability. Yamada *et al.* defined significant facet joint opening as >2 mm as (FJO); 70% of patients with FJO had FFS.^[8] Chaput *et al.* reported a combination of normal curvature and FFS on MRI as reliable findings of LDS (i.e., high positive predictive value [93.22%]).^[2]

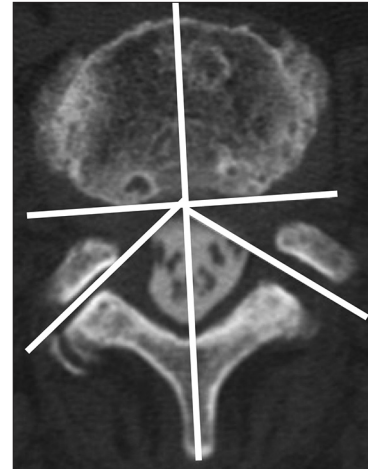


Figure 4: Measurement of facet tropism. A line parallel to the posterior surface of the vertebral body was drawn, and a line perpendicular to this line and passing through the base of the spinous process was drawn. The angle between this line and facet was measured on the left and right, and the difference was taken as facet tropism.

Table 3: Comparison of neuroradiological parameters among groups.

	LDS	LSS	P-value
FJT, mean±SD	2.6±1.1	1.7±0.8	<0.001*
FFS (%)	40 (75)	61 (58)	0.032*
Facet tropism, mean±SD	12.2±6.6	9.5±7.1	0.023*
Air in the facet (%)	21 (39.6)	38 (36.2)	0.67
Air in the disc (%)	35 (66.0)	61 (58.0)	0.33

LDS: Lumbar degenerative spondylolisthesis, LSS: Lumbar spinal stenosis without vertebral slip, FJT: Facet joint thickness, SD: Standard deviation, FFS: Facet fluid sign. *Statistically significant

Table 4: Multiple logistic regression analyses of association with LDS.

	P-value	OR	95% CI
FJT	<0.001*	2.8	1.8–4.5
FFS	0.265	1.6	0.7–3.7
Facet tropism	0.132	1	1.0–1.1

LDS: Lumbar degenerative spondylolisthesis, OR: Odds ratio, CI: Confidence interval, FJT: Facet joint thickness, FFS: Facet fluid sign. *Statistically significant

Facet tropism consistent with instability

Facet tropism is indicative of degeneration within a facet joint and is also predominantly associated with the LDS group.^[4,6]

Fusion rates

We performed decompression or fusion largely based on dynamic myelo-CT studies confirming significant instability (i.e., >3 mm or 25% olisthy) in LDS patients, while 97.3% of LSS patients without these findings underwent decompressions alone.

CONCLUSION

In patients with LDS, FJT on myelo-CT studies most specifically confirmed lumbar instability warranting fusion versus any other imaging parameter.

Ethical Approval

The author(s) declare that they have obtained ethical approval from IRB/IEC to 'The authors declare that they have obtained ethical approval from our institution's IRB' in the Ethical Approval section.

Declaration of patient consent

Patient's consent not required as there are no patients in this study.

Financial support and sponsorship

Nil.

Conflicts of interest

There are no conflicts of interest.

Use of artificial intelligence (AI)-assisted technology for manuscript preparation

The author(s) confirms that there was no use of artificial intelligence (AI)-assisted technology for assisting in the writing or editing of the manuscript and no images were manipulated using AI.

REFERENCES

1. Caterini R, Mancini F, Bisicchia S, Maglione P, Farsetti P. The correlation between exaggerated fluid in lumbar facet joints and degenerative spondylolisthesis: Prospective study of 52 patients. *J Orthop Traumatol* 2011;12:87-91.
2. Chaput C, Padon D, Rush J, Lenehan E, Rahm M. The significance of increased fluid signal on magnetic resonance imaging in lumbar facets in relationship to degenerative spondylolisthesis. *Spine (Phila Pa 1976)* 2007;32:1883-7.
3. Cho BY, Murovic JA, Park J. Imaging correlation of the degree of degenerative L4-5 spondylolisthesis with the corresponding amount of facet fluid. *J Neurosurg Spine* 2009;11:614-9.
4. Gao T, Lai Q, Zhou S, Liu X, Liu Y, Zhan P, *et al.* Correlation between facet tropism and lumbar degenerative disease: A retrospective analysis. *BMC Musculoskelet Disord* 2017;18:483.
5. Hasegawa K, Kitahara K, Shimoda H, Hara T. Facet joint opening in lumbar degenerative diseases indicating segmental instability. *J Neurosurg Spine* 2010;12:687-93.
6. Ko S, Chae S, Choi W, Kim JY, Kwon J, Doh J. The prevalence of facet tropism and its correlation with low back pain in selected community-based populations. *Clin Orthop Surg* 2019;11:176-82.
7. Yamada K, Toyoda H, Takahashi S, Tamai K, Suzuki A, Hoshino M, *et al.* Facet joint opening on computed tomography is a predictor of poor clinical outcomes after minimally invasive decompression surgery for lumbar spinal stenosis. *Spine (Phila Pa 1976)* 2022;47:405-13.
8. Yamada K, Toyoda H, Takahashi S, Tamai K, Suzuki A, Hoshino M, *et al.* Relationship between facet joint opening on CT and facet joint effusion on MRI in patients with lumbar spinal stenosis: Analysis of a less invasive decompression procedure. *J Neurosurg Spine* 2022;36:376-84.

How to cite this article: Ikeda S, Ooigawa H, Kimura T, Tanabe H, Kurita H. Facet joint thickness and lumbar instability documented on myelo-computed tomography studies in patients with lumbar degenerative disease. *Surg Neurol Int* 2023;14:342.

Disclaimer

The views and opinions expressed in this article are those of the authors and do not necessarily reflect the official policy or position of the Journal or its management. The information contained in this article should not be considered to be medical advice; patients should consult their own physicians for advice as to their specific medical needs.