

Bilateral neuralgic amyotrophy in a patient with livestock-associated hepatitis E virus infection

Nicholas J. Miller MD, Davyd R. Hooper MD, Aditya Sharma MD

■ Cite as: *CMAJ* 2022 April 4;194:E495-9. doi: 10.1503/cmaj.211679

For a first-person account of this condition, see www.cmaj.ca/lookup/doi/10.1503/cmaj.220382

A 52-year-old, previously healthy, right-handed male livestock trader woke in the middle of the night with acute, 9/10 right shoulder and forearm pain. He was unable to go back to sleep because of the pain, despite taking analgesics. The following day, he noticed weakness in his right hand and presented to the emergency department. He was found to have severe right shoulder pain and decreased active range of motion. Hand weakness was not documented. A presumptive diagnosis of inflammatory arthritis was made. Blood work showed normal complete blood count, electrolytes, creatinine kinase and erythrocyte sedimentation rate and elevated hepatic enzymes: aspartate aminotransferase 205 (normal range 16–51) U/L, alanine aminotransferase 472 (normal < 52) U/L, lactate dehydrogenase 861 (normal range 230–490) U/L, γ -glutamyl transferase 442 (normal range 5–38) U/L, and alkaline phosphatase 186 (normal range 36–144) U/L. The elevated hepatic enzymes were felt to be unrelated to the working diagnosis. The patient was prescribed prednisone 50 mg orally daily and analgesics and instructed to follow up with his family physician.

The following day, he presented to the emergency department again. Pain had spread to his left arm and right-hand weakness had progressed, leading to difficulty performing activities of daily living. An examination showed that he was unable to flex the first or second digits of his right hand; no other neurologic abnormalities were noted. Radiographs of the upper extremity were unremarkable. The case was discussed over the phone with the on-call neurologist, who felt the symptoms were likely related to the peripheral nervous system. Referral to neuromuscular medicine was recommended.

We assessed the patient in the neuromuscular medicine clinic 6 days after symptom onset. He had discontinued prednisone after 1 dose owing to perceived ineffectiveness. He described a constant, deep, aching 8/10 pain in both shoulders and forearms. He said he had no neck pain or sensory symptoms. Examination showed weakness in multiple nerve territories (Table 1), most notably in the anterior interosseous nerve (AIN) distribution, a branch of the median nerve. The patient could not flex the distal interphalangeal joints of digits 1 or 2 on the right (Figure 1) and had bilateral scapular winging (Figure 2). He had decreased sensation in the right axillary nerve territory. Reflexes were present (2+) and symmetric.

Key points

- Neuralgic amyotrophy is an underrecognized condition that pathognomonically involves acute pain in the arm or shoulder or both, followed by weakness, often in the long thoracic, suprascapular or anterior interosseous nerve territories.
- The diagnosis is made clinically; early recognition and initiation of high-dose oral corticosteroids may improve long-term outcomes.
- Hepatitis E virus infection has an unknown incidence in Canada, but locally acquired infections are increasing in developed countries and should be suspected in people who are in contact with pigs.
- Hepatitis E virus infection may present with peripheral neurologic manifestations, including neuralgic amyotrophy and Guillain-Barré syndrome, with or without symptoms of hepatitis.

Table 1: Manual muscle testing in our patient*

Motion (nerve)	Right	Left
Shoulder abduction (axillary and suprascapular)	4	4
Shoulder external rotation (suprascapular)	4	5
Elbow flexion (musculocutaneous)	5	5
Elbow extension (radial)	5	5
Wrist and finger extension (radial)	5	5
Wrist flexion (median)	5	5
Thumb extension (radial)	4	5
Thumb abduction (median and radial)	5	5
Forearm pronation (AIN)	2	4
Forearm supination (radial and musculocutaneous)	5	5
PIP joint flexion (median)	5	5
DIP joint flexion to thumb and index finger (AIN)	0	5
DIP joint flexion to middle, ring and small fingers (AIN — middle finger and ulnar— ring and small)	5	5
Finger abduction (ulnar)	5	5

Note: AIN = anterior interosseous nerve, DIP = distal interphalangeal, PIP = proximal interphalangeal.
*Strength graded 0–5 on Medical Research Council scale.

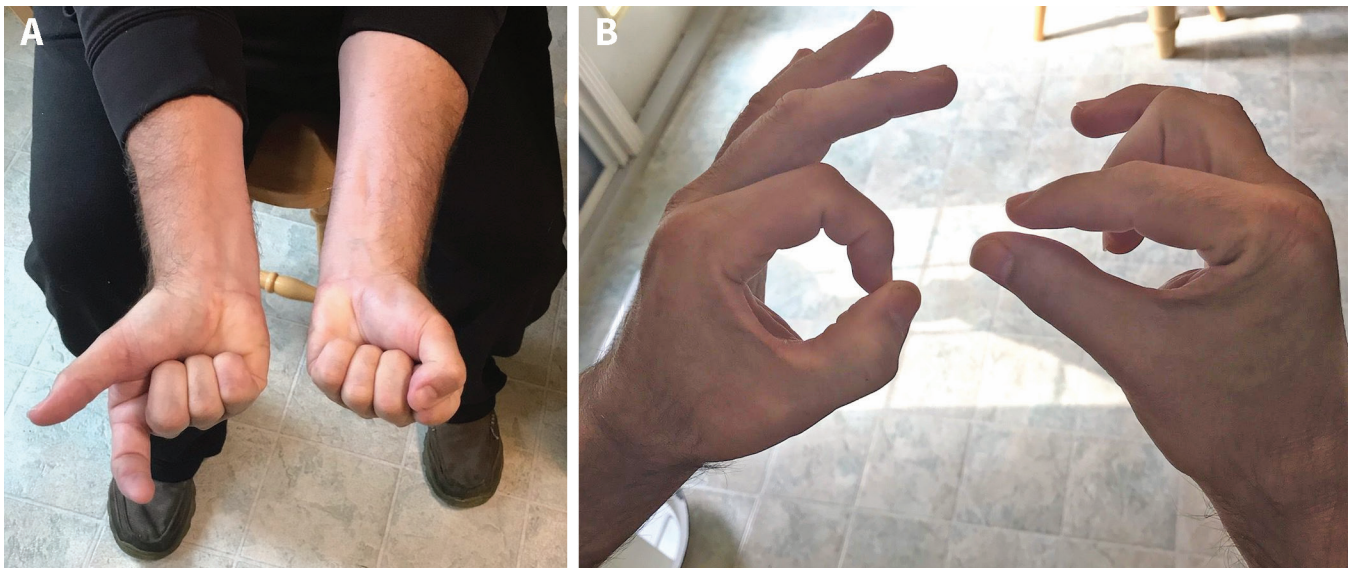


Figure 1: Presentation of distribution of weakness in the right anterior interosseous nerve (AIN) of a 52-year-old man. The left hand is shown as a normal comparison. A) The patient is attempting to make a fist but is unable to flex the distal interphalangeal (DIP) joints of the thumb and index finger on the right. B) After being asked to make an “okay” sign, the patient is unable to flex the right DIP joints of the thumb and index finger. When weakness is less severe, the examiner should provide resistance by attempting to pull their finger through the patient’s thumb and index finger. Classic AIN syndrome results in weakness of flexor digitorum profundus to digits 2 and 3, flexor pollicis longus and pronator quadratus. The sparing of digit 3 flexion shows a fascicular pattern of injury.

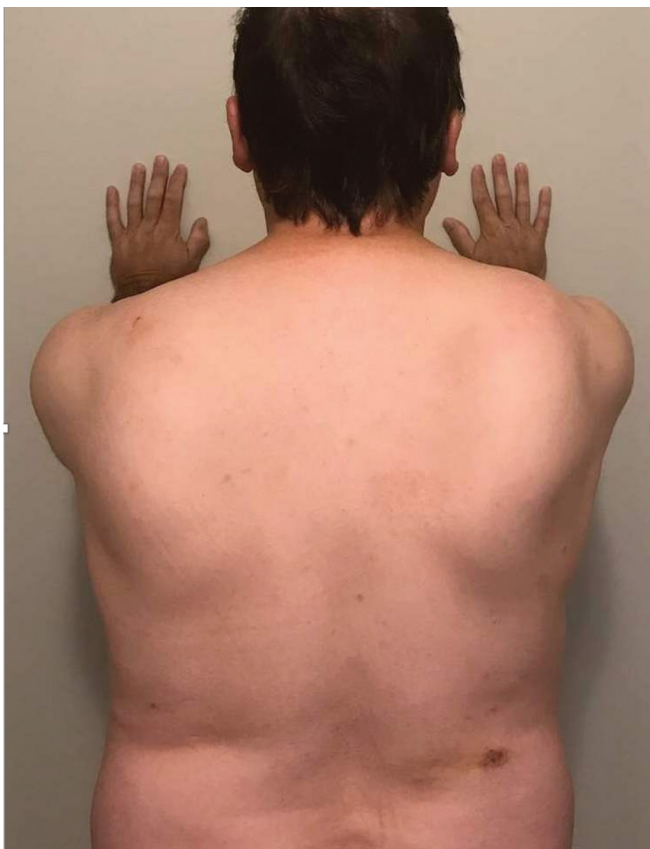

Figure 2: Bilateral medial scapular winging in our patient, worse on the right than on the left. The medial border of the scapula is observed to protrude from the thorax (which may be associated with lateral displacement of the scapula). Medial scapular winging is caused by weakness of serratus anterior due to injury to the long thoracic nerve and is best seen by having the patient push against a wall.

Acute pain followed by weakness involving the AIN, long thoracic and suprascapular nerves suggested neuralgic amyotrophy (NA). We considered cervical radiculopathy to be less likely, given the patient’s weakness in multiple myotomes and absence of neck pain and paresthesia. Testing for vasculitic mononeuritis multiplex showed negative antineutrophil cytoplasm antibodies and normal C-reactive protein. Neuralgic amyotrophy may be provoked by infections. Given the bilateral involvement, elevated liver enzymes and occupational risk factor, we tested only for hepatitis E virus (HEV); HEV immunoglobulin M (IgM) and G (IgG) antibodies were positive. We started the patient on prednisone 60 mg orally daily for treatment of NA, with a 5-week taper. Within 1 week, his pain had resolved.

At 5-month follow-up, he reported no improvement in hand strength. Electromyography was performed for prognostication, which showed no evidence of reinnervation to AIN muscles.

Discussion

Neuralgic amyotrophy, also known as brachial plexus neuritis or Parsonage–Turner syndrome,^{1,2} is an underrecognized syndrome affecting the brachial plexus. A hereditary form of NA shows subtle differences in presentation; this review focuses only on idiopathic NA. The typical presentation of NA is acute and severe pain in the shoulder or arm or both,¹⁻³ often beginning overnight, waking the patient from sleep.³ Arm weakness develops hours to days later, but may not be recognized initially owing to the severity of pain.¹⁻⁴ The classic phenotype of weakness, observed in 70% of patients, involves muscles innervated by either 1 or a combination of the suprascapular, long thoracic and anterior interosseous nerves (Figure 3).^{1,2} Involvement of these nerves manifests with 1 or more of scapular winging, weakness of shoulder abduction and external rotation or weakness of pinch grip in

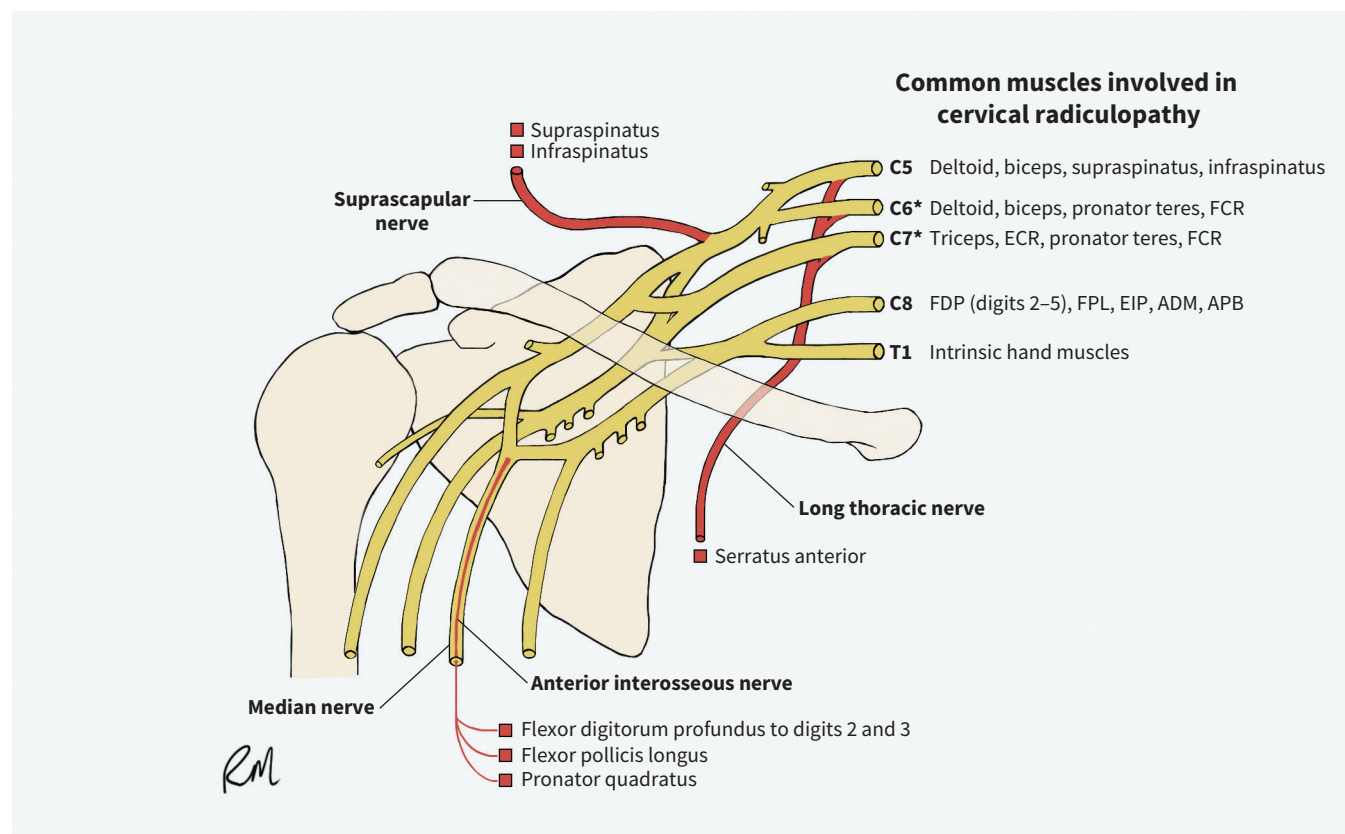


Figure 3: Motor innervation of muscles affected in amyotrophic neuralgia and cervical radiculopathy. Nerves commonly involved in neuralgic amyotrophy are highlighted in red. Inflammation to these nerves may occur proximally in the plexus, selectively involving fascicles that will become these terminal branches, or distally in the terminal nerve. The anterior interosseous nerve is a branch of the median nerve that splits off in the forearm. Muscles commonly involved in radiculopathy are listed. A C6 radiculopathy may take the pattern of either a C5 or C7 radiculopathy. Note: ADM = abductor digiti minimi, APB = abductor pollicis brevis, ECR = extensor carpi radialis, EIP = extensor indicis proprius, FCR = flexor carpi radialis, FDP = flexor digitorum profundus, FPL = flexor pollicis longus. *Most common levels of cervical radiculopathy. Image courtesy of R. MeiMei Miller.

digits 1–3 and arm pronation. Sensory symptoms are less prominent, although paresthesias or sensory loss can occur, especially in the superficial radial or axillary nerve territory.^{1,2} Neuralgic amyotrophy associated with HEV infection (HEV-NA) tends to be more severe than non-HEV-NA. It is more likely to be bilateral (80% v. 8.6%),⁵ and more likely to involve the phrenic nerve, manifesting with orthopnea (24.5% v. 2.5%).⁵

Neuralgic amyotrophy occurs in a 2:1 ratio of men to women, with median age of onset at 40 years.¹ The prevalence is typically referenced at 1–3/100 000 patients.^{1,2} However, a 2015 trial in which primary care physicians were trained to evaluate for NA found a 1-year incidence of 1/1000.² The pathophysiology of NA, although not completely known, involves an autoimmune process affecting the brachial plexus. Mechanical factors likely contribute, as people involved in sports or labour have a higher risk of developing NA.¹ Infections including HEV, parvovirus B19, human cytomegalovirus and herpes simplex virus are potential triggers for NA.^{1,3–5} The first description of HEV-NA was in 2009;⁴ subsequent studies have implicated HEV in 10% of cases of NA.¹ Recently, NA occurring after SARS-CoV-2 infection and following SARS-CoV-2 vaccination has been reported.⁶

Neuralgic amyotrophy is a clinical diagnosis. The classic presentation of NA is pathognomonic if it is recognized, yet other diagnoses must be considered in patients presenting with arm or

shoulder pain and weakness. Weakness from NA can occur in multiple patterns, but is typically multifocal. Weakness, pain and sensory loss, each occurring in different nerve root or peripheral nerve territories, suggests NA as the diagnosis.¹ When the presentation is atypical, nerve conduction studies and electromyography aid in the diagnosis. Although MRI is not necessary to diagnose NA, it may show edema, T2 hyperintensity or gadolinium enhancement of the brachial plexus and affected nerves.¹

Cervical radiculopathy, with an incidence of 6/1000 per year,³ is more common than NA, which is often misdiagnosed as radiculopathy given shared features.^{1,3} Deficits from a radiculopathy occur in a single dermatome or myotome corresponding to the level of injury, unless multiple nerve roots are involved (Figure 3). Weakness in several myotomes makes radiculopathy less likely. Classic myotomal evaluation (arm flexion, arm extension, wrist extension, grip strength, finger abduction) does not evaluate the most common deficits of NA. Scapular winging is not as common in radiculopathy and can be assessed by having the patient push against a wall (Figure 2). Anterior interosseous nerve function can be assessed by asking the patient to make an “okay” sign with their fingers (Figure 1). Testing the infraspinatus muscle with resisted external shoulder rotation evaluates the suprascapular nerve.

Upper extremity muscles are innervated by multiple nerve roots; therefore, a lesion affecting a single nerve root causes weakness, but complete paralysis of a muscle is uncommon. Sensory features are often prominent in radiculopathy, which further differentiates it from NA.

The suprascapular, long thoracic and anterior interosseous nerves do not carry cutaneous sensation; thus, lesions affecting these nerves will not exhibit sensory deficits.

Other conditions sharing features with NA include mono-neuritis multiplex, rotator cuff tear and glenohumeral arthritis^{1,3} (Table 2).

Hepatitis E virus infection

Most (70%) patients with HEV infection are asymptomatic, and the remainder have an acute, self-limited hepatitis.⁸ Pregnancy and pre-existing liver disease are risk factors for developing acute liver failure.⁸ Neurologic manifestations occur in 16.5%–30% of patients diagnosed with HEV, including NA and, less commonly, Guillain-Barré syndrome, encephalitis and transverse myelitis.⁸ HEV-NA presents with active or recent HEV infection, yet patients are unlikely to be jaundiced and have milder hepatic features than symptomatic patients with HEV and without NA.^{5,8} Testing includes HEV serology for IgM and IgG, and serum HEV

Table 2: Differential diagnosis of neuralgic amyotrophy*^{1,3}

Diagnosis	Pain	Weakness	Sensory	Associated risk factors or features	Onset	Special tests	Investigation results
Neuralgic amyotrophy	++ Shoulder, arm or both Severe, analgesic resistant	++ in peripheral nerve distribution May develop hours to days after pain onset	+ in different peripheral nerves than weakness May not be noticed by patient	Male, middle age, physically active, risk factors for HEV or preceding infection, shoulder surgery, other viral infections, vaccinations	Acute to subacute, monophasic course	Scapular winging, “okay” sign, shoulder abduction or external rotation weakness. No passive ROM restriction	Blood work, including inflammatory markers, is negative. Exception is elevated hepatic enzymes in HEV-associated NA. MRI brachial plexus positive, NCS and EMG positive†
Cervical radiculopathy (secondary to herniated disk)	+ neck, shoulder, radiating down arm	+ myotome distribution	+ dermatome distribution	May be provoking event such as physical exertion or injury	Acute	Spurling manoeuvre, ⁷ relief with shoulder abduction ⁷	MRI cervical spine positive (high false positivity) EMG positive; NCS normal
Mononeuritis multiplex	++ Multifocal and asymmetric, but pain, weakness and sensory loss in the same peripheral nerve territory	+ 	+ 	Features of vasculitis and systemic symptoms	Progressive, stepwise	Not applicable	Inflammatory markers elevated; NCS and EMG positive
Rotator cuff tear	+ Shoulder	+ Of torn muscles, no other weakness	–	Traumatic injury	Acute	Drop arm sign, ⁷ Jobe (empty can) test, ⁷ external rotation weakness, Hornblower or Patte test ⁷	MRI shoulder positive; NCS and EMG normal
Glenohumeral arthritis or adhesive capsulitis	+ Shoulder	–	–	Age > 50 yr, with associated stiffness	Gradual	Decreased active and passive ROM	XR shoulder — may show osteoarthritis; NCS and EMG normal

Note: + = may be present or noted, ++ = significant or present substantially, – = absent, CT = computed tomography, EMG = needle electromyography, HEV = hepatitis E virus, MRI = magnetic resonance imaging, NCS = nerve conduction studies, ROM = range of motion, XR = radiograph.

*This table summarizes main features but the lists are not exhaustive.

†MRI, NCS and EMG are not required to make the diagnosis of NA.

RNA. Hepatitis E virus RNA is present in many patients,^{5,8} but was negative in ours.

The hepatitis E virus is common worldwide, infecting 20 million people per year.⁸ In resource-poor areas, HEV is transmitted through contaminated water, and is common in parts of southern Asia, Africa, rural China and Latin America.⁸ The incidence of locally acquired HEV infection is increasing in developed countries.⁵ Risk factors for locally acquired HEV infection in Canada include working with pigs and consumption of HEV-contaminated pork.^{8,9} Risk from pork consumption is low but greatest if consuming undercooked pork liver.⁹

The greatest risk is contact with pigs aged 2–4 months, which shed the most virus.^{9,10} Farmers who do not have contact with pigs of this age and those who work in pork production have less risk for HEV, although higher than the general population.⁹ Provincial estimates are unknown but meta-analysis estimates HEV prevalence among pigs in Canadian farms at 61.1%.⁹

The incidence of HEV in Canadians is unknown but it is likely underdiagnosed and underreported.^{9,11} Seroprevalence of HEV in Canadian blood donors is 5.8%, higher than would be anticipated by the number of documented HEV cases.¹¹ Seroprevalence among individuals who work with pigs is greater: reported to be as high as 26.4%.¹⁰

Neuralgic amyotrophy treatment and prognosis

Observational studies have shown that prednisone, prescribed for a minimum of 2 weeks and started within 2 weeks of symptom onset, decreases duration of pain. Prednisone may lead to better motor recovery,¹¹ highlighting the need for timely diagnosis. Pain or weakness or both persist for many patients.^{1,4} Our patient had a rapid improvement in pain after administration of corticosteroids, but persistent hand weakness. Electromyography that showed complete disruption of the AIN makes spontaneous recovery unlikely; therefore, our patient underwent nerve transfer surgery.

Conclusion

Neuralgic amyotrophy has unique clinical features. Clinical evaluation can usually confirm the diagnosis and differentiate NA from other causes of shoulder or arm pain and weakness. It can be associated with HEV infection, and the combination should be suspected as a cause of acute shoulder or arm pain and weakness among returning travellers and those at risk for locally acquired HEV infection.

References

1. Van Eijk JJJ, Groothuis JT, Van Alfen N. Neuralgic amyotrophy: an update on diagnosis, pathophysiology, and treatment. *Muscle Nerve* 2016;53:337-50.
2. van Alfen N, van Eijk JJ, Ennik T, et al. Incidence of neuralgic amyotrophy (Parsonage Turner syndrome) in a primary care setting: a prospective cohort study. *PLoS One* 2015;10:e0128361.
3. van Alfen N. The neuralgic amyotrophy consultation. *J Neurol* 2007;254:695-704.
4. Fong F, Illahi M. Neuralgic amyotrophy associated with hepatitis E virus. *Clin Neurol Neurosurg* 2009;111:193-5.
5. van Eijk JJJ, Dalton HR, Ripellino P, et al. Clinical phenotype and outcome of hepatitis E virus-associated neuralgic amyotrophy. *Neurology* 2017;89:909-17.
6. Coffman JR, Randolph AC, Somerson JS. Parsonage–Turner syndrome after SARS-CoV-2 BNT162b2 vaccine: a case report. *JBJS Case Connect* 2021;11:e21.00370.
7. Malanga GA, Mautner K. *Musculoskeletal physical examination: an evidence-based approach*. 2nd ed. Philadelphia: Elsevier; 2016.
8. Webb GW, Dalton HR. Hepatitis E: an expanding epidemic with a range of complications. *Clin Microbiol Infect* 2020;26:828-32.
9. Wilhelm B, Fazil A, Rajić A, et al. Risk profile of hepatitis E virus from pigs or pork in Canada. *Transbound Emerg Dis* 2017;64:1694-708.
10. Hofmeister MG, Foster MA, Teshale EH. Epidemiology and transmission of hepatitis A virus and hepatitis E virus infections in the United States. *Cold Spring Harb Perspect Med* 2019;9:a033431.
11. Fearon MA, O'Brien SF, Delage G, et al. Hepatitis E in Canadian blood donors. *Transfusion* 2017;57:1420-5.
12. van Alfen N, van Engelen BGM, Hughes RAC. Treatment for idiopathic and hereditary neuralgic amyotrophy (brachial neuritis). *Cochrane Database Syst Rev* 2009;(3)CD006976.

Competing interests: Aditya Sharma reports owning stocks in Contrafact and Enstasis Therapeutics. No other competing interests were declared.

This article has been peer reviewed.

The authors have obtained patient consent.

Affiliations: Departments of Physical Medicine and Rehabilitation (Miller, Hooper) and Internal Medicine (Sharma), Faculty of Medicine, University of Manitoba, Winnipeg, Man.

Contributors: All of the authors contributed to the conception and design of the work. Nicholas Miller drafted the manuscript. Davyd Hooper and Aditya Sharma revised it critically for important intellectual

content. All of the authors gave final approval of the version to be published and agreed to be accountable for all aspects of the work.

Content licence: This is an Open Access article distributed in accordance with the terms of the Creative Commons Attribution (CC BY-NC-ND 4.0) licence, which permits use, distribution and reproduction in any medium, provided that the original publication is properly cited, the use is noncommercial (i.e., research or educational use), and no modifications or adaptations are made. See: <https://creativecommons.org/licenses/by-nc-nd/4.0/>

Acknowledgements: The authors thank the patient for their permission to publish this case report and for use of their photographs. They also thank R. MeiMei Miller for creating Figure 3.

Correspondence to: Nicholas Miller, ummiller@myumanitoba.ca

The section Cases presents brief case reports that convey clear, practical lessons. Preference is given to common presentations of important rare conditions, and important unusual presentations of common problems. Articles start with a case presentation (500 words maximum), and a discussion of

the underlying condition follows (1000 words maximum). Visual elements (e.g., tables of the differential diagnosis, clinical features or diagnostic approach) are encouraged. Consent from patients for publication of their story is a necessity. See information for authors at www.cmaj.ca.